

CASE REPORT

Idiopathic internal mammary artery aneurysm

Jens Heyn^{1,*}, Hanna Zimmermann², Alexander Klose³, Benjamin Luchting¹, Christian Hinske¹, and Mojtaba Sadeghi-Azandaryani³

¹Department of Anaesthesiology, Grosshadern, University of Munich (LMU), Munich, Germany,

²Department of Radiology, Grosshadern, University of Munich (LMU), Munich, Germany, and

³Department of Vascular Surgery, Erding Hospital, Erding, Germany

*Correspondence address. Department of Anaesthesiology, Grosshadern, University of Munich (LMU), Marchioninistrasse 15, 81377 Munich, Germany.
Tel: +49-89-7095-3423; Fax: +49-89-7095-8886; E-mail: jens.heyne@med.uni-muenchen.de

Abstract

Aneurysms of the internal mammary artery are extremely rare, and their presentation and treatment are variable. Since these aneurysms often tend to rupture and cause haemothorax and life-threatening conditions, the knowledge of secure treatment options is indispensable. We here report the case of an idiopathic internal mammary aneurysm in a 46-year-old man. Open surgical resection of the aneurysm was performed in this case without any complications. The postoperative course was uneventful and the patient was in a good physical condition without any vascular or neurological abnormalities during follow-up.

INTRODUCTION

Aneurysms of the internal mammary artery (IMAA) are uncommon clinical entities [1] and usually occur in patients after sternotomy, placement of a central venous catheter or pacemaker leads [2]. Less common, these aneurysms are associated with vasculitis (e.g. Kawasaki disease [3]), connective tissue disorders (e.g. Marfan syndrome [4]), chest wall infections [5] or atherosclerosis [6]. However, changes in the structure of the vascular wall at the cellular level such as cystic medial necrosis or hyperplasia lead to loss of elasticity and formation of aneurysms [6].

Since rupture of IMAA leads to haemothorax and life-threatening conditions, early diagnosis and treatment is indispensable. We here report the case of a 46-year-old man with an idiopathic IMAA.

CASE REPORT

A 46-year-old man was presented to the Department of Vascular Surgery with distinct varicosis. In the context of preparation for

vein stripping, chest X-ray was performed and revealed a nodular shadow attached to the pleural cupula (Fig. 1). Exact census of the anamnesis revealed increasing surge and numbness of the fingers depending on the load of the arm (comparable to the thoracic outlet syndrome). To further evaluate the nodular shadow on X-ray, computed tomography (CT) scan of the thorax with contrast medium has been drafted. The CT scan revealed a 3.6 × 4.4 cm inhomogeneous tumorous process dorsal of the left clavicle with impression of the neighbouring lung. Furthermore, it was suspected that the tumour infiltrated the left internal jugular and subclavian vein. Therefore, an additional phlebography was initiated. Phlebography confirmed the perceptions of the CT scan, but failed to shed any further light on the nature of the tumour (Fig. 2). Finally, magnetic resonance imaging (MRI) scan was performed in order to demonstrate the exact origin of the tumour, but also failed to obtain new findings (Fig. 3).

Due to the symptoms and the suspicion of malignant tumour, an open resection was intended. Therefore, the patient was placed in a lateral position with the right arm freely moveable. Transverse incision was made below the axillary hairline

Received: October 10, 2014. Accepted: October 20, 2014

Published by Oxford University Press and JSCR Publishing Ltd. All rights reserved. © The Author 2014.

This is an Open Access article distributed under the terms of the Creative Commons Attribution Non-Commercial License (<http://creativecommons.org/licenses/by-nc/4.0/>), which permits non-commercial re-use, distribution, and reproduction in any medium, provided the original work is properly cited. For commercial re-use, please contact journals.permissions@oup.com

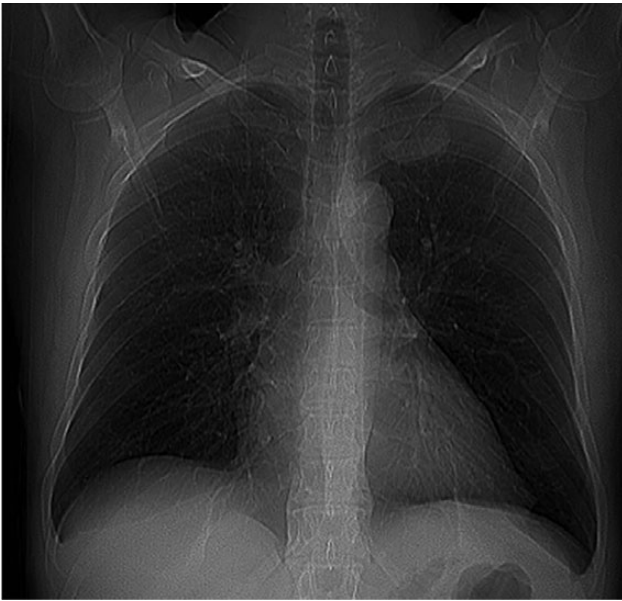


Figure 1: Chest X-ray.

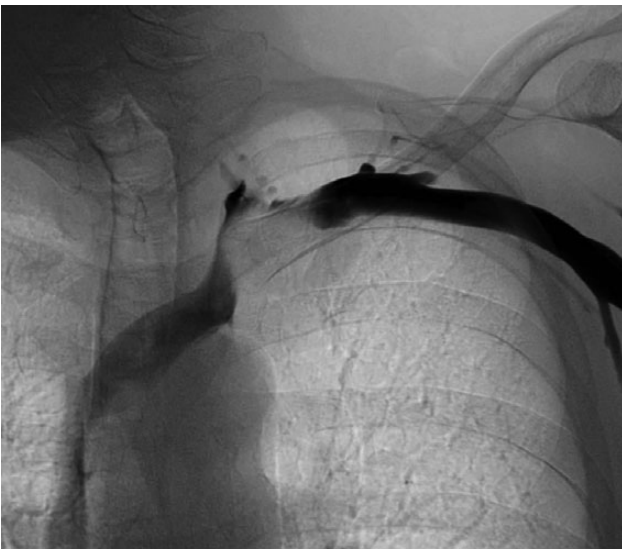

Figure 2: Phlebography reveals a compression of the left subclavian vein.

between the pectoralis major and latissimus dorsi muscle, followed by careful preparation of the first rib, layer by layer. Resection of the first rib was done among sternocostal and costovertebral joint after accurate separation from the underlying pleura. Medial of the pleural cupula a boorish tumour was palpable and the left IMA was walled by this tumour. Therefore, the tumour and the left mammary artery were removed after cautious preparation. After careful arrest of bleeding, the wound was stepwise closed with single button sutures.

Histological examination of the removed tumour revealed a thrombotic obliterated aneurysm of the IMA. After operation, the patient recovered well. The peripheral pulses were palpable postoperatively and neurological tests did not show any abnormalities. X-ray during follow-up showed normal findings. An arterial duplex scan of the left subclavian arteries showed a good vascular flow (Fig. 3). Six months after operation, the

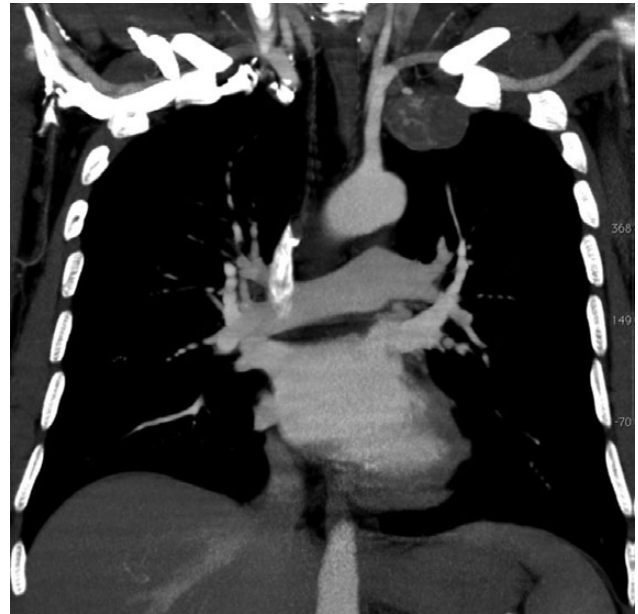

Figure 3: MRI scan of the thorax shows a tumour at the left pleural cupula.

postoperative course was uneventful and our patient was in a good physical condition.

DISCUSSION

The IMA arises from the first portion of the subclavian artery and immediately passes downwards close to the pleura within the upper intercostal space. Further distal, it proceeds anteriorly to the transversus thoracic muscle to end in the sixth intercostal space by dividing into the superior epigastric and musculophrenic artery [7]. This anatomical course makes the IMA vulnerable to severe deceleration or penetrating injuries [7].

Infections or genetic disorders are also frequent causes of IMAAs [3–5, 8]. A spontaneous development of an IMAA without a rememberable trauma or injury as described in our case is a rarity. Due to the low prevalence of IMAAs, informations regarding diagnosis and secure treatment options are scarce [1]. IMAAs typically appear with haemoptysis, cough and dyspnoea. In some patients, IMAAs only emerge as a bulging chest mass [8].

However, chest X-ray should be performed as first step when IMAA is suspected. An additional CT scan conceivably in combination with an angiography is a valuable method to localize the IMAA and to plan the surgical procedure [1]. In our patient, classical symptoms of an IMAA were missing and the IMAA was an incidental finding within routine X-ray. The compression symptoms of the IMAA were only found after accurate request and examination. The additional imaging procedures failed to confirm the diagnosis.

Prior to therapy, treatment options should be carefully considered. Open surgical repair, stent implantation or coil embolization has been described in the literature [1, 9, 10]. Even though long-term results are missing, coil embolization or stent implantation has become the treatment option of choice in minor aneurysms due to the minor invasivity of these procedures [3, 10]. Despite this advantage, we were not convinced with coil embolization or stent implantation because of the following reasons:

- (i) A malignant process could not be excluded by the imaging prior to surgery.

- (ii) Even if the diagnosis of an IMAA would have been made, the compression of the adjacent vessels and nerves (which caused symptoms) would not have been treated by an endovascular procedure.

Histological examination of the tumour revealed a thrombotic obliterated IMAA. The aneurysm was finally classified as idiopathic due to the fact that tissue disorders and inflammatory processes were not detectable, trauma or medical interventions were not rememberable, vessel anomalies could be excluded and atherosclerosis ruled out because of inconspicuous medical history and clinical examination.

An idiopathic IMAA is an extremely rare entity. The diagnosis may be difficult, when clinical symptoms are missing. When the diagnosis of IMAA is made, prompt therapy is essential in avoidance of life-threatening events. Selection of the ideal approach depends on the underlying pathogenesis. Open surgical resection represents an invasive procedure with the option of decompressions of neighbouring structures, good postoperative outcome and without complications in our case.

CONFLICT OF INTEREST STATEMENT

The authors declare no conflict of interest.

FUNDING

The author(s) received no financial support for the authorship, and/or publication of this article.

REFERENCES

- Okura Y, Kawasaki T, Hiura T, Seki H, Saito H. Aneurysm of the internal mammary artery with cystic medial degeneration. *Intern Med* 2012;51:2355–9.
- Namai A, Sakurai M, Akiyama M. Poststernotomy pseudoaneurysm of the internal mammary artery. *Gen Thorac Cardiovasc Surg* 2008;56:344–6.
- Rose JF, Lucas LC, Bui TD, Mills JL Sr. Endovascular treatment of ruptured axillary and large internal mammary artery aneurysms in a patient with Marfan syndrome. *J Vasc Surg* 2011;53:478–82.
- Ishiwata S, Nishiyama S, Nakanishi S, Seki A, Watanabe Y, Konishi T, et al. Coronary artery disease and internal mammary artery aneurysms in a young woman: possible sequelae of Kawasaki disease. *Am Heart J* 1990;120:213–7.
- Wani NA, Rawa IA, Pala NA, Kosar T. Pseudoaneurysm of internal mammary artery caused by pulmonary actinomycosis. *Br J Radiol* 2010;83:e235–8.
- Wildhirt S, Eckel L, Beyersdorf F, Satter P. Atherosclerotic aneurysm of the right internal mammary artery presenting as a mediastinal mass. *J Thorac Cardiovasc Surg* 1994;107:1535–6.
- Whigham CJ Jr, Fisher RG, Goodman CJ, Dodds CA, Trinh CC. Traumatic injury of the internal mammary artery: embolization versus surgical and nonoperative management. *Emerg Radiol* 2002;9:201–7.
- Phan TG, Sakulsaengprapha A, Wilson M, Wing R. Ruptured internal mammary artery aneurysm presenting as massive spontaneous haemothorax in a patient with Ehlers-Danlos syndrome. *Aust N Z J Med* 1998;28:210–1.
- Kim SJ, Kim CW, Kim S, Lee TH, Kim KI, Moon TY, et al. Endovascular treatment of a ruptured internal thoracic artery pseudoaneurysm presenting as a massive hemothorax in a patient with type I neurofibromatosis. *Cardiovasc Intervent Radiol* 2005;28:818–21.
- Husted JW, Stock JR, Manella WJ. Traumatic anterior mediastinal hemorrhage: control by internal mammary artery embolization. *Cardiovasc Intervent Radiol* 1982;5:268–70.