



Case Report

Multivessel Spontaneous Coronary Artery Dissection With Coronary Artery Fibromuscular Dysplasia

Franz Schweis, MD,^a Ara H. Rostomian, MD, MPH, MBA,^a Derek Phan, MD,^a Ming-Sum Lee, MD, PhD,^a Anne Ichiuji, MD,^a Albert Yuh-Jer Shen, MD,^a and Naing Moore, MD^b

^a Department of Cardiology, Kaiser Permanente Los Angeles Medical Center, Los Angeles, California, USA

^b Regional Cardiac Catheterization Lab, Kaiser Permanente Los Angeles Medical Center, Los Angeles, California, USA

ABSTRACT



A 53-year-old woman underwent a cardiac catheterization for evaluation of acute coronary syndrome. The coronary angiogram revealed evidence of spontaneous coronary artery dissection in multiple coronary arteries including the left anterior descending artery, posterior descending artery, and posterior left ventricular artery. Further diagnostic imaging revealed associated bilateral vertebral artery and renal artery fibromuscular dysplasia (FMD). Follow-up coronary angiogram 6 weeks later revealed a “string of beads” appearance of the posterior descending artery. This case highlights the importance of extra-coronary imaging for FMD and demonstrates angiogram findings suggestive of coronary FMD.

RÉSUMÉ

Une femme de 53 ans a été soumise à un examen par cathétérisme cardiaque afin d'évaluer le syndrome coronarien aigu dont elle est atteinte. L'angiographie coronarienne a révélé des signes de dissection spontanée de l'artère coronaire dans de multiples artères coronaires, y compris l'artère interventriculaire antérieure, l'artère interventriculaire postérieure et l'artère ventriculaire gauche postérieure. D'autres images diagnostiques ont révélé la présence d'une dysplasie fibromusculaire (DFM) bilatérale connexe des artères rénales et vertébrales. L'artère interventriculaire postérieure avait l'aspect d'un « collier de perles » à l'angiographie coronarienne de suivi effectué six semaines plus tard. Ce cas souligne l'importance de l'imagerie extracoronaire pour la détection d'une DFM et montre que les résultats de l'angiographie sont indicatifs d'une DFM coronaire.

Case Presentation

A 53-year-old woman with a past medical history of hypertension presented with intermittent exertional substernal chest pain for 2 days. She was hypertensive with a blood pressure of 145/99 mm Hg and a heart rate of 84 beats per minute. Physical examination was unremarkable. Labs were significant for an elevated Troponin-I of 0.12 ng/mL (normal <0.04 ng/mL). Her initial electrocardiogram (ECG) showed normal sinus rhythm without any evidence of ischemia. A regadenoson single-photon emission computed tomography myocardial perfusion imaging test was performed for risk stratification. During the recovery phase, she developed transient chest pain with associated ST-segment elevations seen on leads II, III, and

aVF. She was taken for an emergent cardiac catheterization. Coronary angiogram revealed tortuous vessels with evidence of spontaneous coronary artery dissection (SCAD) in multiple coronary arteries including the left anterior descending artery, posterior descending artery (PDA), and posterior left ventricular artery (Fig. 1, A and B; Video 1 ; view video online). Intracoronary nitroglycerin was administered during the procedure to ensure that the findings were not due to coronary vasospasm. The diagnosis of SCAD was made based on high index of suspicion of the angiographic appearance. Because of the known association of SCAD and fibromuscular dysplasia (FMD), a renal angiogram was performed, which demonstrated a “beading” appearance of the right renal artery consistent with renal artery FMD (Fig. 2A; Video 2 ; view video online). This further supported the diagnosis of SCAD. She was conservatively managed with medical therapy.

She was treated with aspirin, clopidogrel, metoprolol, and heparin. Echocardiogram showed normal left ventricular systolic function with mild inferior wall hypokinesis. A head computed tomography angiogram showed evidence of FMD of the bilateral vertebral arteries (Fig. 2B). Her hospital course was complicated by a recurrent episode of chest pain the

Received for publication November 10, 2020. Accepted December 29, 2020.

Ethics Statement: The research reported has adhered to the relevant ethical guidelines.

Corresponding author: Dr Franz Schweis, Department of Cardiology, Kaiser Permanente Los Angeles Medical Center, 1526 North Edgemont St, 2nd Floor, Los Angeles, California 90027, USA. Tel.: +1-323-783-4585.

E-mail: Franz.N.Schweis@kp.org

See page 689 for disclosure information.

Novel Teaching Points

- The association between SCAD and FMD suggests that coronary artery FMD is the etiology of SCAD. This case demonstrates further evidence to support this.
- Vascular imaging for FMD can help support the diagnosis of SCAD when the coronary angiogram findings are not definitive.
- A conservative management approach for SCAD can result in a favourable outcome, even when there are multiple coronary vessels involved.

morning after her cardiac catheterization. The chest pain was associated with ECG changes showing mild ST-segment elevations with T-wave inversions throughout the precordial leads. Her symptoms and ECG changes resolved with administration of nitroglycerin. This was thought to be related to coronary vasospasm associated with SCAD. A calcium channel blocker was added to her treatment regimen, and the patient was discharged after symptoms had completely resolved for more than 48 hours.

The patient was evaluated at an outpatient cardiology clinic visit several weeks after discharge. She endorsed rare episodes of atypical chest pain. Because of her ongoing symptoms and the uncertainty of her diagnosis, a repeat angiogram was performed 6 weeks after her initial presentation to confirm the diagnosis of SCAD. She was found to

have complete resolution of SCAD in the left anterior descending artery and posterior left ventricular artery (Fig. 1, C and D). Interestingly, the PDA displayed a “string of beads” appearance suggestive of coronary artery FMD (Figs. 1D and 2C).

Discussion

SCAD is characterized by the spontaneous formation of an intramural hematoma within the wall of a coronary artery.^{1,2} As described in this case, SCAD is frequently associated with FMD, which is a nonatherosclerotic arteriopathy that can result in stenosis, aneurysm, dissection, or occlusion that can affect nearly any arterial bed.^{3,4} The association between the 2 disease entities has led investigators to suggest that a proportion of SCAD may be due to coronary FMD.¹ However, the typical “string of beads” appearance of FMD is rarely seen in the coronary arteries.

The follow-up coronary angiogram findings of the PDA in our patient demonstrated a “string of beads” appearance; however, without advanced coronary imaging or histopathology, it is not certain that the findings are due to the pathophysiologic changes of FMD seen in extra-coronary arterial beds. Alternative explanations for the patient’s findings include a natural healing progression of the coronary artery dissection or permanent injury to the coronary vessel from the dissection event. Previous literature has suggested angiographic findings that support the diagnosis of coronary FMD, which include findings of SCAD, coronary spasm, and coronary tortuosity.³ All these clinical features were observed

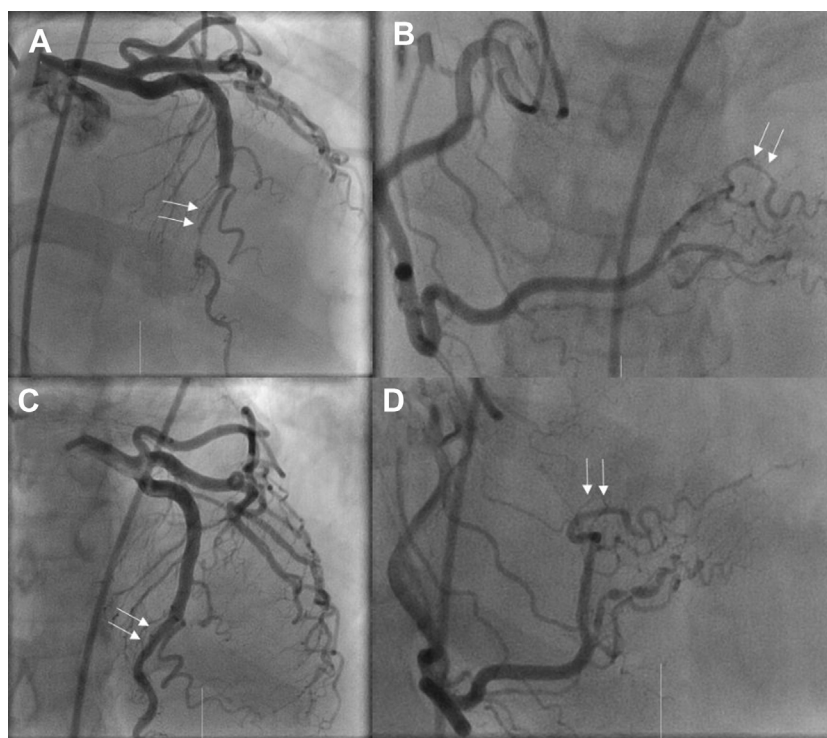


Figure 1. Spontaneous coronary artery dissection. (A, B) Coronary angiogram revealed tortuous vessels with evidence of spontaneous coronary artery dissection (SCAD) in multiple coronary arteries including the left anterior descending artery (LAD), posterior descending artery, and posterior left ventricular artery (PLV). (C, D) A repeat coronary angiogram was performed 6 weeks later. She was found to have complete resolution of SCAD in the LAD and PLV.

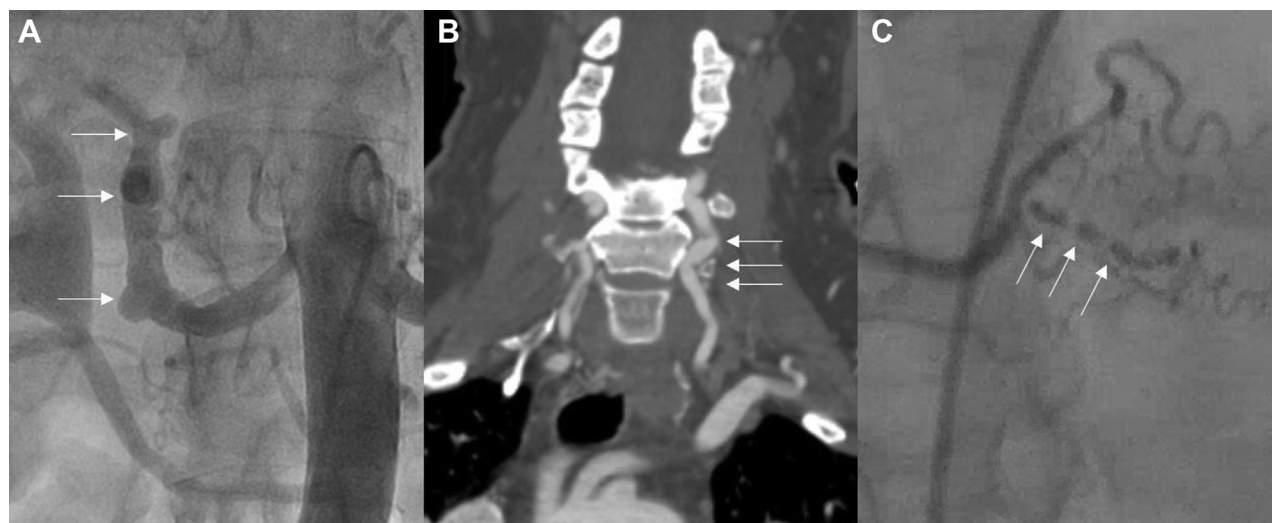

Figure 2. Fibromuscular dysplasia. **(A)** A renal angiogram was performed, which demonstrated a “beading” appearance of the right renal artery consistent with renal artery fibromuscular dysplasia (FMD). **(B)** A head computed tomography angiogram was performed, which showed evidence of FMD of the bilateral vertebral arteries. **(C)** On repeat coronary angiogram, the posterior descending artery displayed a “string of beads” appearance suggestive of coronary artery FMD.

in our patient, suggesting that coronary FMD may be the etiology of her SCAD.

Conservative management is recommended for the treatment of SCAD because most lesions heal spontaneously in 4–6 weeks.³ Medical management for SCAD includes aspirin and beta blockers. Dual antiplatelet therapy with the addition of clopidogrel may be considered to prevent associated thrombus formation, though the benefits are not well established.³ Nitrates and calcium channel blockers can be considered for patients with symptoms suggestive of coronary vasospasm or microvascular dysfunction.¹ The most recent scientific statement from the American Heart Association also suggests vascular imaging from the brain to pelvis in all patients with SCAD for evaluation of FMD.¹ Patients with FMD have been shown to have higher risk of recurrence of SCAD.⁵

Our case was instructive for several reasons. First, it demonstrates that a patient with multivessel SCAD can be managed conservatively with a favourable outcome. Second, the evolution of the SCAD lesion to a “string of beads” appearance is rarely seen and may suggest underlying coronary FMD.

Conclusion

Our case demonstrates evidence that coronary artery FMD contributes to the underlying etiology of SCAD. A conservative management approach resulted in a favourable outcome, and the patient was able to avoid unnecessary intervention and potential related complications.

Funding Sources

No funding was received for this study.

Disclosures

The authors have no conflicts of interest to disclose.

References

1. Hayes SN, Kim ESH, Saw J, et al. Spontaneous coronary artery dissection: current state of the science: a scientific statement from the American Heart Association. *Circulation* 2018;137:523–57.
2. Garcia-Guimarães M, Bastante T, Antuña P, et al. Spontaneous coronary artery dissection: mechanisms, diagnosis and management. *Eur Cardiol* 2020;15:1–8.
3. Michelis KC, Olin JW, Kadian-Dodov D, d’Escamard V, Kovacic JC. Coronary artery manifestations of fibromuscular dysplasia. *J Am Coll Cardiol* 2014;64:1033–46.
4. McNair PW, Parker A, Taylor A, et al. Spontaneous coronary artery dissection and its association with fibromuscular dysplasia and other vascular abnormalities. *Am J Cardiol* 2020;125:34–9.
5. Clare R, Duan L, Phan D, et al. Characteristics and clinical outcomes of patients with spontaneous coronary artery dissection. *J Am Heart Assoc* 2019;8:012570.

Supplementary Material

To access the supplementary material accompanying this article, visit *CJC Open* at <https://www.cjopen.ca/> and at <https://doi.org/10.1016/j.cjco.2020.12.021>.