



# Pancreatitis After Pancreaticojejunostomy Procedure? A Tale Involving the Tail of the Pancreas

Manik Aggarwal, MD<sup>1</sup>, Richard H. Cartabuke, MD<sup>1</sup>, and Carlos Roberto Simons-Linares, MD<sup>2</sup>

<sup>1</sup>Department of Internal Medicine, Cleveland Clinic, Cleveland, OH

<sup>2</sup>Department of Gastroenterology and Hepatology, Digestive Disease Institute, Cleveland Clinic, Cleveland, OH

## ABSTRACT

Recurrent acute pancreatitis (RAP) involving the tail of the pancreas after pancreaticojejunostomy (PJP) is rare, has very challenging management, and there is minimal literature. We describe a case of idiopathic RAP, complicated with chronic pancreatitis that failed medical and endoscopic management and required PJP. Unfortunately, RAP recurred after PJP, and we describe his clinical course and management.

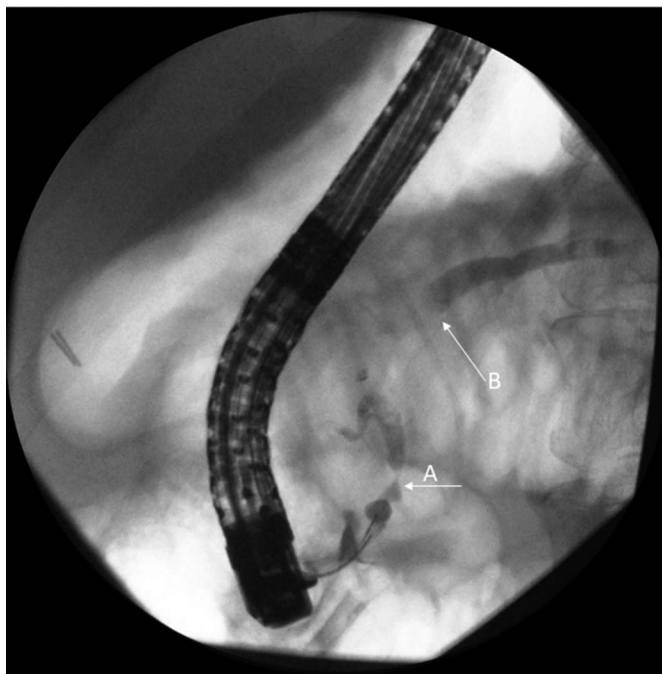
## INTRODUCTION

Chronic pancreatitis (CP) is a chronic benign inflammatory disorder of the pancreas resulting in fibrotic replacement of the pancreatic parenchyma. Clinical management of CP is challenging, given incomplete understanding of disease pathogenesis and the complexities of pain control. Initial management of CP entails risk factor modification with alcohol abstinence and tobacco cessation, treatment of pain (ideally) with supportive behavioral therapy, and nutritional optimization with pancreatic enzyme replacement.<sup>1</sup> Patients who continue to have debilitating pain despite best medical management are candidates for therapeutic intervention which include endoscopic therapies, celiac nerve block, extracorporeal shock wave lithotripsy, and surgery.<sup>2</sup> Surgical options include decompression, resection, or denervation of the pancreas depending on the size of pancreatic duct and region of pancreatic involvement.<sup>2</sup> Decompression of the pancreatic ductal system has been used to relieve symptoms with a high success rate in patients with pancreatic duct (PD) dilation.<sup>3</sup> Recurrent acute pancreatitis (RAP) after decompression procedures such as the lateral pancreaticojejunostomy (modified Puestow) procedure (PJP) has not been reported frequently in the literature. Residual disease in the pancreatic head has been postulated as the cause for recurrence of pancreatitis after PJP. We report a case of acute pancreatitis (AP) involving the tail of the pancreas after PJP performed for severe CP.

## CASE REPORT

A 52-year-old nonsmoker man presented with upper abdominal pain and nausea. He had a medical history of idiopathic RAP complicated with CP, PD stricture, and dilation, status-post PJP 9 months ago for severe and refractory chronic pain secondary to CP. Before the PJP, he underwent cholecystectomy and multiple (5 in total) PD stent placement through endoscopic retrograde cholangiopancreatography and an endoscopic celiac plexus block without improvement of the pain and continued to suffer RAP episodes, which prompted PJP. Endoscopic retrograde cholangiopancreatography before PJP revealed a dilated pancreatic duct with pancreatic head stricture (Figure 1). After PJP, he had been doing well and had only very mild abdominal pain, which was controlled with oxycodone-acetaminophen 5/325 mg twice a day and gabapentin 300 mg 3-times daily with close pain management follow-up.

On presentation, his pain was epigastric, radiating to the back, sharp quality, 10 of 10 intensity. He denied any new dietary, medication changes, alcohol, or tobacco use. On admission to the hospital, he was found to have a lipase level of 3,000 U/L. His abdominal and pelvic computed tomography with intravenous contrast revealed AP inflammation affecting the tail of the pancreas primarily with no necrosis or any fluid collection. He was diagnosed with AP and was started on intravenous fluids and pain control

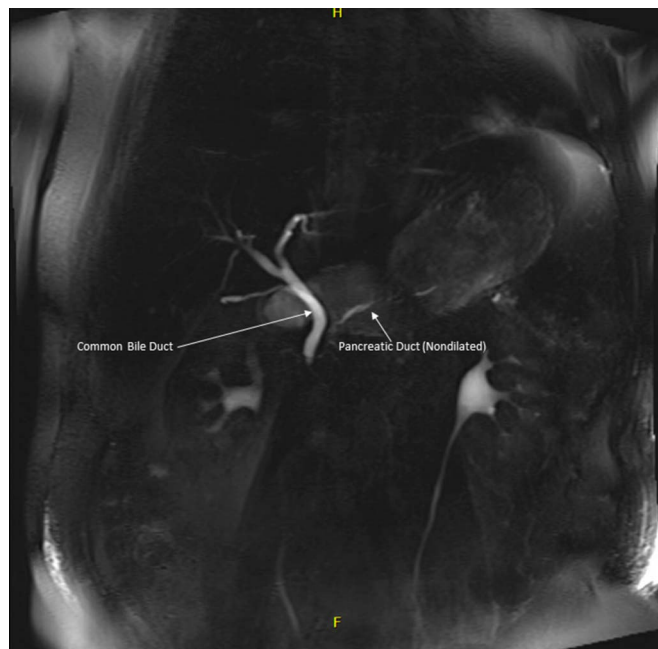

**Figure 1.** Endoscopic retrograde pancreatography revealing (A) a pancreatic head stricture and (B) a dilated pancreatic duct proximal to the stricture.

with opioids. To further evaluate the cause of AP, the patient subsequently underwent magnetic resonance imaging of the pancreas with secretin administration (Figures 2 and 3) which revealed interstitial edematous AP without complications and no PD dilation. There was fluid secretion into the jejunal limb and duodenum after secretin stimulation and mild common bile duct prominence without complication. The patient did well and was discharged from the hospital with outpatient follow-up in the pancreas clinic. Of note, since discharge, he has had 8 further episodes of AP, and an extensive workup (history of ongoing substance abuse [alcohol, smoking, and cannabis], metabolic and lipid panel, autoimmune workup, toxicology screen, IgG levels, and genetic testing for hereditary pancreatitis) did not reveal a cause for RAP. Given recurrent episodes of AP, he is being planned for a total pancreatectomy with autologous islet cell transplant.

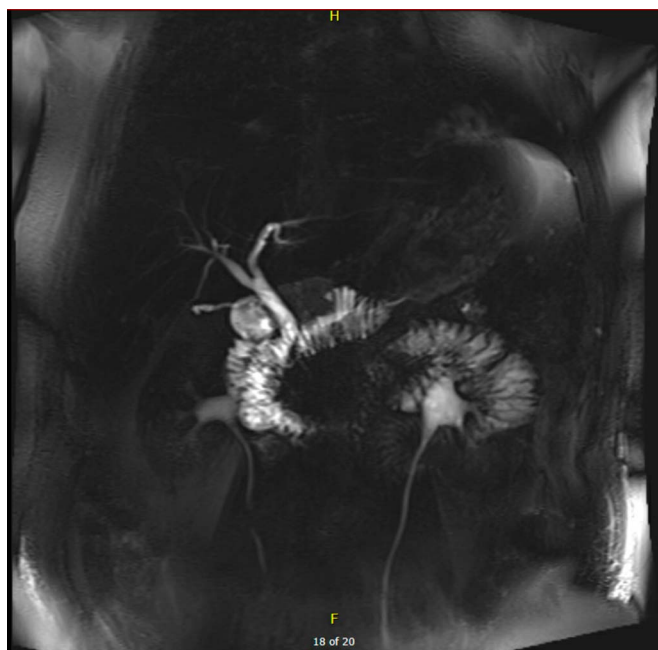## DISCUSSION

CP is characterized by chronic inflammation that can lead to impairment of endocrine and exocrine function and significant pain. Medical and endoscopic treatments are associated with severe CP pain control in 50%–80% of patients and rarely do patients end up undergoing surgical procedures to manage CP pain.<sup>4</sup> Chronic pain in this condition is believed to arise from elevated pressures in obstructed PD, and the modified PJP is one of the most common procedures to achieve decompression of the PD. It involves creating a longitudinal opening of the PD, which is anastomosed to a Roux-en-Y limb of the small intestine opened longitudinally (Figure 4).

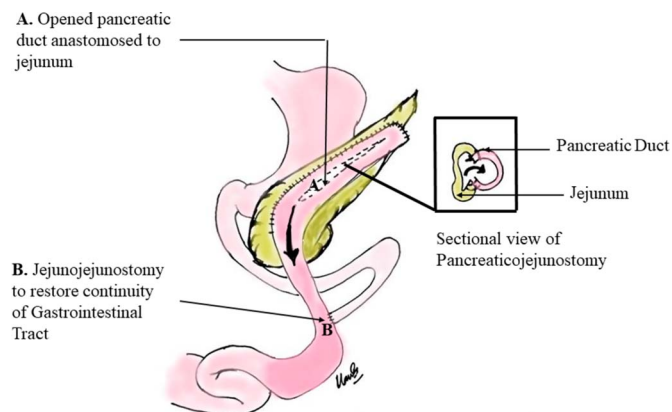


**Figure 2.** Magnetic resonance cholangiopancreatography revealing nondilated pancreatic duct without stone.

The procedure has been reported to have a good success rate with pain relief in 66%–91% of patients with a mean follow-up of 3.5–9.1 years.<sup>5</sup> However, this procedure is preferred in patients with diseases located to the left of gastroduodenal artery and is less favored for disease involving the pancreatic head.<sup>1</sup> The main reason RAP after PJP is the poor drainage of the Wirsung and/or Santorini ducts in the pancreatic head. We could not find a report of RAP involving the tail of the pancreas after PJP as seen in our patient. Of note, abstinence from alcohol after procedure is



**Figure 3.** Secretin stimulation test with normal secretin stimulation.



**Figure 4.** Lateral pancreaticojejunostomy (modified Puestow procedure).

associated with a better outcome after surgery.<sup>6</sup> Our patient had not consumed alcohol after surgery, and his magnetic resonance imaging during the most recent episode did not reveal PD dilation, strictures, or stones in the pancreatic head.

There are limited data regarding the outcomes of patients after a PJP. In a study of by Adams et al,<sup>7</sup> 25 of 85 patients were readmitted for pain/pancreatitis after a longitudinal with a follow-up ranging from 1 to 15 years. Inadequate decompression of the pancreatic head was cited to be the most common reason for recurrence of pain. In this study, 26 subjects continued consumption of alcohol; however, it is unclear whether recurrence of pain/pancreatitis was more common in these patients. Recently, Andersson et al<sup>8</sup> performed PJP on 32 patients with CP and reported that the recurrence of severe pain requiring narcotics after initial control was seen in 2 patients. RAP rate was not reported in this study. Patients not having adequate response to surgical decompression or recurrence of pain/pancreatitis after surgery are generally managed by total resection of the pancreas.

In summary, our patient has had 8 further episodes of RAP beginning within a year of PJP and is now being planned for total pancreatectomy with autologous islet cell transplant. One retrospective study in 85 patients showed improvement in pain control and decreased opiate requirement; however, data regarding pain improvement remain limited. This case highlights

that RAP soon after PJP is an uncommon but morbid phenomenon with a significant impact on patient's quality of life requiring multidisciplinary care. Long-term follow-up of such patients is lacking but needed, to assess the factors associated with RAP after PJP which will help to improve care, outcomes, and potentially better guide patient selection to provide maximum benefit of this surgical intervention.

## DISCLOSURES

**Author contributions:** All authors contributed equally to this manuscript. M. Aggarwal is the article guarantor.

**Financial disclosure:** None to report.

**Informed consent** was obtained for this case report.

Received December 30, 2020; Accepted May 7, 2021

## REFERENCES

- Schwarzenberg SJ, Uc A, Zimmerman B, et al. Chronic pancreatitis. *J Pediatr Gastroenterol Nutr.* 2019;68(4):566–73.
- Gardner TB, Adler DG, Forsmark CE, Sauer BG, Taylor JR, Whitcomb DC. ACG clinical guideline: Chronic pancreatitis. *Am J Gastroenterol.* 2020; 115(3):322–39.
- van der Gaag NA, van Gulik TM, Busch ORC, et al. Functional and medical outcomes after tailored surgery for pain due to chronic pancreatitis. *Ann Surg.* 2012;255(4):763–70.
- Dua MM, Visser BC. Surgical approaches to chronic pancreatitis: Indications and techniques. *Dig Dis Sci.* 2017;62(7):1738–44.
- Isaji S. Has the partington procedure for chronic pancreatitis become a thing of the past? A review of the evidence. *J Hepatobiliary Pancreat Sci.* 2010;17(6):763–9.
- Li S, Tan C, Tian B. Risk factors for pain after Frey's procedure in chronic pancreatitis. *Medicine (Baltimore).* 2017;96(36):e7675.
- Adams DB, Ford MC, Anderson MC. Outcome after lateral pancreaticojejunostomy for chronic pancreatitis. *Ann Surg.* 1994;219(5): 481–9.
- Andersson R, Börjesson A, Blind P-J, Tingstedt B. Pancreaticojejunostomy: A valid operation in chronic pancreatitis? *Scand J Gastroenterol.* 2008; 43(8):1000–3.

**Copyright:** © 2021 The Author(s). Published by Wolters Kluwer Health, Inc. on behalf of The American College of Gastroenterology. This is an open access article distributed under the terms of the Creative Commons Attribution-Non Commercial-No Derivatives License 4.0 (CCBY-NC-ND), where it is permissible to download and share the work provided it is properly cited. The work cannot be changed in any way or used commercially without permission from the journal.