

# Incremental benefit of SPECT + CT bone scans over conventional planar and SPECT bone scans in vertebroplasty

Kush Kumar, Raghuveer K Halkar, Scott C Bartley, David M Schuster

Department of Radiology, Division of Nuclear Medicine, Emory University Hospital, Atlanta, Georgia, USA

## ABSTRACT

**Study design:** Planar bone scans with SPECT and SPECT + CT were performed in those patients who underwent peri-operative evaluation for vertebroplasty. The scans were evaluated separately to identify the “culprit” vertebra (e) by two readers and their results were analyzed. **Objective:** Use of planar and SPECT bone scan for identifying the “culprit” vertebra (e) for vertebroplasty is well established. SPECT + CT is a relatively recent imaging tool providing co-registered fused images. Theoretical advantages of SPECT + CT over conventional SPECT imaging needs to be evaluated and documented. **Summary of Background Data:** Percutaneous stabilization of collapsed vertebra by bone cement has now become a standard procedure. However, it is essential to localize the correct vertebra. Imaging modalities like CT scan provides structural or anatomical information whereas bone scan (planar + SPECT images) provides more functional or physiological information. Combination of these two imaging modalities is expected to provide much more than information obtained by any one imaging modality separately. To the best of our knowledge, there is no reference available in the literature adopting this approach. **Materials and Methods:** Two expert readers, blinded to patient history, evaluated the scans. They independently analyzed planar + SPECT only images followed by SPECT/CT fused images with the aim to identify the acutely fractured vertebra for vertebroplasty. **Results:** Interpretations changed, on average, 50% of the time as a result of the additional information provided by SPECT + CT. SPECT + CT more precisely localizes tracer abnormalities in the vertebra compared to SPECT imaging alone. **Conclusion:** The greatest value of co-registered SPECT + CT bone scan lies in the accurate localization of affected vertebrae in complicated cases of multiple collapsed vertebrae of different ages as well as in the post-vertebroplasty setting.

**Keywords:** Kyphosis, osteoporosis, Tc99m-bone scan, vertebroplasty

## INTRODUCTION

Percutaneous stabilization of a collapsed vertebra by polymethyl methacrylate bone cement (PMMA) has now become a standard procedure. It not only helps in lowering the morbidity and mortality, it is well tolerated by elderly patients, it has low complication rate and it is also cost effective. However, it is essential to localize the correct vertebra. Several imaging modalities have been used for this purpose with each having its own advantages and limitations.

X-ray, computed tomography (CT) scans and magnetic resonance imaging (MRI) provides information about structural or anatomical details whereas bone scan (Planar + Single-photon emission computed tomography SPECT images) provides more functional or physiological information. Thus, it is logical to comprehend that combination of these two imaging modalities viz. CT scan for anatomical localization and bone scan for physiological or functional determination will provide maximum needed information. Purpose of this paper is to determine the role of combined CT and bone scanning (fused imaging) in localization of anatomical and functional changes in the vertebra. To the best of our knowledge, there is no reference available in the existing literature adopting this approach.

## MATERIALS AND METHODS

Planar bone scans with SPECT and SPECT + CT were

### Access this article online

#### Quick Response Code:



Website:  
www.ijnm.in

DOI:  
10.4103/0972-3919.106700

### Address for correspondence:

Dr. Kush Kumar, Department of Radiology and Nuclear Medicine, Carl Vinson VA Medical Center, Dublin, Georgia, USA  
E-mail: kushkumar8@hotmail.com

performed in 20 patients who underwent pre-operative evaluation for vertebroplasty. Three patients underwent more than one procedure. A total of 24 scans were studied including 17 pre-vertebroplasty scans and 7 post-vertebroplasty scans. Patients were injected with 24-30 mCi of  $^{99}\text{Tc}$ -methylene diphosphonate MDP. SPECT + CT was performed 2-4 h after injection with a dual head camera equipped with CT (VG/Hawkeye, GE Medical Systems Milwaukee, WI, USA). SPECT images were acquired using a Low Energy High-Resolution LEHR collimator, 20% window centered at 140 keV and reconstructed with ordered subsets expectation maximization OSEM. CT images were acquired using a  $128 \times 128$  pixel matrix, 120 kV tube voltage, 2.5 mA current, and a 10 mm slice width. Two expert readers, blinded to patient history, independently analyzed non-AC, SPECT only images followed by co-registered AC, SPECT/CT fused images with the aim to identify the acutely fractured vertebra for vertebroplasty.

## RESULTS

Interpretations changed, on average, 50% of the time as a result of the additional information provided by SPECT + CT. For reader #1, interpretations changed in 11/24 scans, (7% or 41% in pre-vertebroplasty scans and 4% or 57% in post-vertebroplasty scans) and for reader #2, in 13/24 scans (8% or 47% in pre-vertebroplasty scans and 5% or 71% in post-vertebroplasty scans). Types of changes included: shift in the specific level of vertebral involvement, changes in the precise location of involvement within a vertebrae as well as the inclusion or exclusion of affected vertebrae. In one case, the addition of SPECT + CT affected the independent findings of both readers, resulting in a shift in diagnosis by one vertebral body, which correlated with the history of a prior vertebral fusion confirmed on diagnostic CT. SPECT + CT localized prior vertebroplasties and aided in the diagnosis of complicated cases of post-operative back pain. In one patient, SPECT + CT localized activity to a new compression fracture immediately above a prior vertebroplasty site.

No image scattering was noted in cases of previous vertebroplasty (post-vertebroplasty cases) due to the presence of previous bone cement. In cases with incomplete previous vertebroplasty, the remaining vertebral body showed the increased radiotracer uptake. The fused images clearly identified the difference. Short history of one of the cases with illustrative images is shown in Figures 1-5.

## DISCUSSION

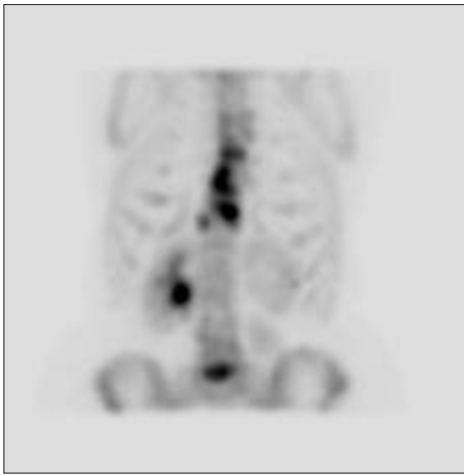Estimated incidence of only osteoporotic vertebral fracture in USA is 7,000,000 per year.<sup>[1]</sup> It has a huge economic impact. The Michigan Department of Community Health nevertheless, estimated the direct expenditure resulting from osteoporotic fractures in USA in 1995 to be greater than \$13.8 billion, or \$38 million per day. These costs are likely to escalate as the population continues to age. The projected direct cost for the year 2030 exceeds \$ 460 billion or \$164 million per day.<sup>[2]</sup> Vertebroplasty

is rapidly growing in popularity since the initial procedure done in 1984 and reported in the European literature in 1987 for the treatment of vertebral angioma.<sup>[3]</sup> It is now used in treating osteoporotic, neoplastic and traumatic vertebral body collapse. Popularity of the procedure is primarily due to the simplicity of the procedure with an easy learning curve by the physicians and few complications, cost effectiveness, early relief of pain and thus reduction in subsequent morbidity with acceptable patient compliance. These advantages led the further development of the procedure in form of “kyphoplasty” in 1998<sup>[4]</sup> Now it is being extended for the fixation of insufficiency fracture of the sacrum as “sacroplasty”<sup>[5]</sup> Somehow vertebroplasty is commonly performed by the intervention radiologists whereas kyphoplasty by the orthopedic or neurosurgeons. Irrespective to these differences, it is vital for the success of the procedure to correctly identify the acutely fractured or “culprit” vertebra.

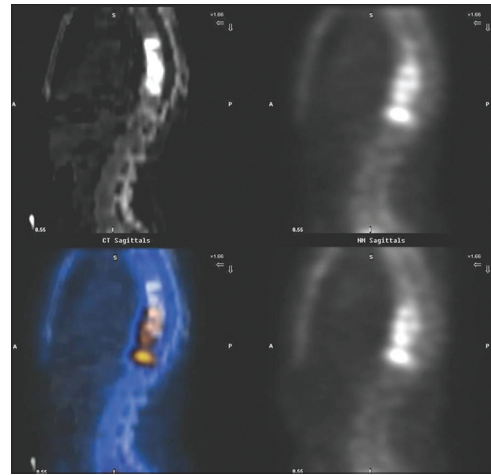
Clinical findings aided with a conventional plane radiographic evaluation has been the traditional method to identify and localize the “culprit” vertebra. For solitary and isolated vertebral fractures, it may be adequate and no further investigation may be needed. However, adjunctive imaging is required in patients with solitary or multiple fractures of uncertain age or when serial conventional radiographs are not available<sup>[6]</sup> The European Vertebral Osteoporotic Study reported three types of compression fractures in osteoporotic spine viz. wedge compression fractures, biconcave fractures, and crush fractures existing in isolation or in combination with varying severity<sup>[7]</sup> They produce different clinical manifestations thus further complicate the issue of exact identification of the “culprit” vertebra by conventional clinico-radiological means. There is little correlation between the degree of collapse of the vertebral body and the level of pain.<sup>[2]</sup>

CT scan is another imaging modality, which not only helps in exact localization of the fractured vertebra but also provides information about the vertebral architecture, the integrity of the posterior wall of the vertebral body, canal compromise and the condition of posterior elements of the vertebra. These are the crucial information necessary in planning of the vertebroplasty. However, CT does not provide information about the age of the fracture or the degree of physiological bone remodeling process. CT is very sensitive in detecting small amounts of bone cement and therefore, has also been used in post-vertebroplasty evaluation. CT has also been used in post-procedural documentation, though there is no reference in the literature to support that such a policy affects clinical practice.<sup>[6]</sup>

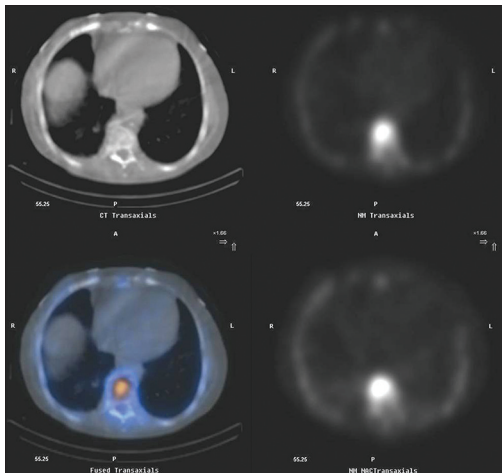
Role of MRI with short *tau* inversion recovery (STIR) sequences in the evaluation of vertebroplasty patients is still being worked out. It not only provides detailed soft tissue and bony architectural information but is also quite sensitive for detecting the acute compression fractures. It also helps in ruling out malignant tumors or other co-existing pathologies. In acute vertebral fracture, the MRI shows the geographic pattern of low-intensity-signal changes on T1 weighted images and high-intensity-signal changes



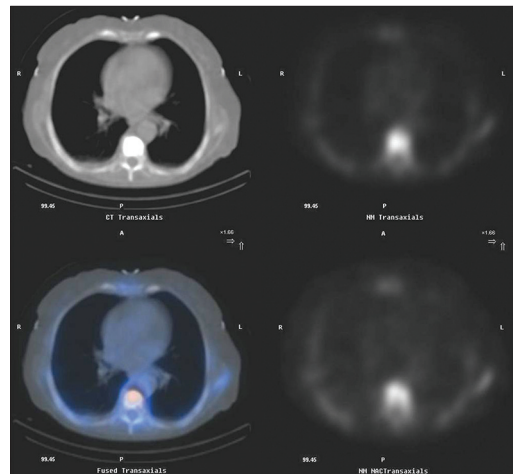
**Figure 1:** Bone scan indicated increased radiotracer uptake in several lower thoracic vertebrae and in the fifth lumbar vertebra of varying intensity suggesting fractures of different ages



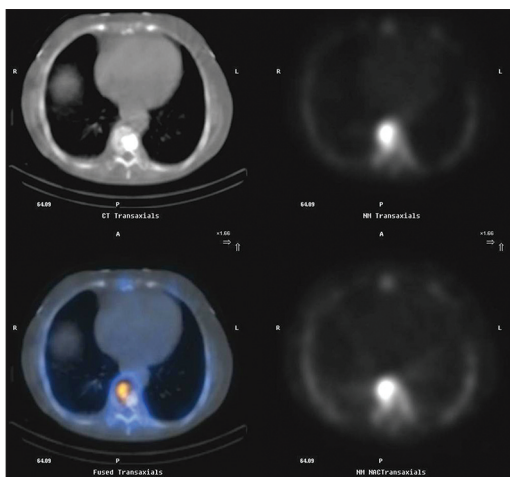
**Figure 2:** (a) Computed tomography image (upper left) showed multiple vertebral involvement (T7-T11) with bone cement in the previously treated vertebrae. (b) Bone scan images (upper right- attenuation corrected and lower right- attenuation not corrected) show mildly increased radiotracer uptake in the previously treated or old fractured vertebrae (T7-T10) and intense uptake in the T11 vertebra just below the previously treated vertebrae suggestive of fresh fracture. (c) Fused image (lower left) clearly identifies the previously treated and the newly fractured vertebra



**Figure 3:** The trans-axial images showing the extent of vertebral body involvement in fresh T11 fracture



**Figure 4:** The trans-axial images showing the complete vertebroplasty of T7 vertebra



**Figure 5:** The trans-axial images showing incomplete previous vertebroplasty of T9 vertebra with increased radiotracer uptake in the region not occupied with the bone cement

on T2 weighted images.<sup>[8]</sup> In spite of these well-established parameters, there are several instances where the abnormal fatty

marrow signal was interpreted as “normal marrow intensity” on T1 and T2 weighted images while the bone scan was clearly abnormal.<sup>[6]</sup> Edema seen on MRI is considered to be predictive of favorable response<sup>[9]</sup> but appreciation of edema in presence of multiple collapsed vertebrae at times may not be easy. MRI is also less sensitive than CT in appreciating the altered bony vertebral anatomy and in detecting the presence of small amount of bone cement. With these advantages and limitations, often the timely non-availability of the MRI and the cost are further limiting factors.

Bone scanning is often performed as a part of the pre-operative evaluation.<sup>[10]</sup> Increased activity on a bone scan of a compression fracture has been suggested to be predictive of favorable outcome following vertebroplasty.<sup>[11]</sup> It helps in identification of fractured vertebra needing cement augmentation in the setting of multiple collapsed vertebrae of varying ages. It is

also of value in post-vertebroplasty cases in detecting the fresh fractures in the adjacent vertebra existing just above or below the previously treated vertebra or in vertebra with incomplete cement augmentation and subsequent fracture. There are limitations too. Bone scan has poor anatomical localization. It may be positive only in 20% of patients with height loss <15%. It is more often positive in fractures with height loss of >25%.<sup>[12]</sup> However, it may detect fractures, which may be missed by other imaging modalities like MRI.<sup>[6]</sup> Bone scan may reveal increased activity up to 2 years after the fracture. Fractures of longer than 6 months of duration typically do not benefit from vertebroplasty.<sup>[13]</sup>

Acquiring the CT and the bone scan (planar and the SPECT) images and then analyzing the fused images for better localization of the fractured vertebra (e) is certainly advantageous as it combines the best of the two imaging modalities. In the present study, the opinion of the two readers changed in half of the cases (50%) which had a substantial impact over the management of these cases. In multiple vertebral fracture cases, it is crucial to identify the “culprit” vertebra (e) for proper results. Bone scan may remain positive for long time but the intensity of the radiotracer uptake varies with time. Recent fractures demonstrate much intense uptake than the older ones. Though there is no quantifying system (like SUV numbers in PET imaging) but experience of the interpreter and CT fusion to a great extent takes care of this short coming.

Use of polymethylmethacrylate (PMMA) bone cement has several advantages like, familiarity of use, easy handling, adequate strength, and is rather inexpensive. Additionally, no attenuation artifact was observed around previous sites of PMMA on attenuation corrected images. The hypothesis proposed was that there are similar imaging energies for SPECT and CT, 140 keV for Tc-99m and 140 keV for CT.<sup>[14,15]</sup> Attenuation artifact is somewhat problematic on PET/CT FDG systems due to differences in imaging energies. There are certain disadvantages of PMMA also like no osteoinductive or osteoconductive property, high polymerization temperature, systemic side effects of unreacted monomer and non-remodeling of the construct. It is also possible that the PMMA augmentation of the collapsed vertebra may render mechanical effects on the neighboring vertebrae. It has led several investigators to use other materials for vertebral augmentation like biodegradable products such as calcium phosphate,<sup>[16]</sup> hydroxyapatite,<sup>[17]</sup> and coral granules.<sup>[18]</sup> What will be the behavior of these new substances on various imaging/scanning methods will only be determined by time but for PMMA augmentation, the proposed strategy of CT + SPECT bone scan fused images provide much more accurate information than any single imaging modality used alone.

## CONCLUSION

Traditionally, bone scans with planar and SPECT images have been used in localization of fractured vertebrae causing localized/persistent back pain. It helps in peri-operative planning for vertebroplasty.

SPECT + CT more precisely localizes tracer abnormalities in the vertebra compared to SPECT imaging alone. The greatest value lies in the accurate localization of affected vertebrae in complicated cases of multiple collapsed vertebrae of different ages as well as in the symptomatic post-vertebroplasty setting.

## REFERENCES

1. Riggs BL, Melton LJ 3<sup>rd</sup>. Involutional osteoporosis. *N Eng J Med* 1986;314:1676-86.
2. Rao RD, Singrakhia MD. Painful osteoporotic vertebral fracture. Pathogenesis, evaluation, and roles of vertebroplasty and kyphoplasty in its management. *J Bone Joint Surg Am* 2003;85-A: 2010-22.
3. Galibert P, Deramond H, Rosat P, Le Gars D. Preliminary note on the treatment of vertebral angioma by percutaneous acrylic vertebroplasty. *Neurochirurgie* 1987;33:166-8.
4. Lieberman IH, Dudeney S, Reinhardt MK, Bell G. Initial outcome and efficacy of “kyphoplasty” in the treatment of painful osteoporotic vertebral compression fractures. *Spine (Phila Pa 1976)* 2001;26:1631-8.
5. Pommersheim W, Huang-Hellinger F, Baker M, Morris P. Sacroplasty: A treatment for sacral insufficiency fractures. *AJNR Am J Neuroradiol* 2003;24:1003-7.
6. Kallmes DF, Jensen ME. Percutaneous vertebroplasty. *Radiology* 2003;229:27-36.
7. Ismail AA, Cooper C, Felsenberg D, Varlow J, Kanis JA, Silman AJ, et al. Number and type of vertebral deformities: Epidemiological characteristics and relation to back pain and height loss. *European Vertebral Osteoporosis Study Group. Osteoporos Int* 1999;9:206-13.
8. Yamato M, Nishimura G, Kuramochi E, Saiki N, Fujioka M. MR appearance at different ages of osteoporotic compression fractures of the vertebrae. *Radiat Med* 1998;16:329-34.
9. Mathis JM, Barr JD, Belkoff SM, Barr MS, Jensen ME, Deramond H. Percutaneous vertebroplasty: A developing standard of care for vertebral compression fractures. *AJNR Am J Neuroradiol* 2001;22:373-81.
10. Maynard AS, Jensen ME, Schweickert PA, Marx WF, Short JG, Kallmes DF. Value of bone scan imaging in predicting pain relief from percutaneous vertebroplasty in osteoporotic vertebral fractures. *AJNR Am J Neuroradiol* 2000;21:1807-12.
11. Grossman RI, Yousem DM. *Neuroradiology*. 2<sup>nd</sup> ed. Pennsylvania: Mosby; 2003. p. 224-31.
12. Nelson DA, Kleerekoper M, Peterson EL. Reversal of Vertebral deformities in osteoporosis measurement error or “rebound”? *J Bone Miner Res* 1994;9:977-82.
13. Martin P. Bone scintigraphy in the diagnosis and management of traumatic injury. *Semin Nucl Med* 1983;13:104-22.
14. Burger C, Goerres G, Schoenes S, Buck A, Lonn AH, Von Schulthess GK. PET attenuation coefficients from CT images: Experimental evaluation of the transformation of CT into PET 511-keV attenuation coefficients. *Eur J Nucl Med Mol Imaging* 2002;29:922-7.
15. Kinahan PE, Townsend DW, Beyer T, Sashin D. Attenuation correction for a combined 3D PET/CT scanner. *Med Phys* 1998;25:2046-53.
16. Lim TH, Brebach GT, Renner SM, Kim WJ, Kim JG, Lee RE, et al. Biomechanical evaluation of an injectable calcium phosphate cement for vertebroplasty. *Spine (Phila Pa 1976)* 2002;27:1297-302.
17. Belkoff SM, Mathis JM, Jasper LE. *Ex vivo* biomechanical comparison of hydroxyapatite and polymethylmethacrylate cements for use with vertebroplasty. *AJNR Am J Neuroradiol* 2002;23:1647-51.
18. Cunin G, Boissonnet H, Petite H, Blanchat C, Guillemin G. Experimental vertebroplasty using osteoconductive granular material. *Spine (Phila Pa 1976)* 2000;25:1070-6.

**How to cite this article:** Kumar K, Halkar RK, Bartley SC, Schuster DM. Incremental benefit of SPECT + CT bone scans over conventional planar and SPECT bone scans in vertebroplasty. *Indian J Nucl Med* 2011;26:181-4.

**Source of Support:** Nil. **Conflict of Interest:** None declared.