

Case report:

ADRENAL INVOLVEMENT IN HISTOPLASMOSIS

Norasyikin A. Wahab*, Rozita Mohd, Suehazlyn Zainudin, Nor Azmi Kamaruddin

* corresponding author: Norasyikin A.Wahab, Department of Medicine, Pusat Perubatan Universiti Kebangsaan Malaysia (PPUKM), Jalan Yaacob Latiff, Bandar Tun Razak, 56000 Cheras, Kuala Lumpur, Malaysia. Tel: +603-91456934
E-mail: Naw8282kt@gmail.com

ABSTRACT

Histoplasmosis infection is endemic in Asia and disseminated histoplasmosis (DH) is one form of its presentation (Benevides et al., 2007). DH commonly affects both adrenal glands. We describe a case of disseminated histoplasmosis complicated with hypercalcaemia in a 75-year-old immunosuppressed patient who presented with bilateral adrenal masses. The fine needle aspiration cytology of the adrenal mass was positive for *Histoplasma capsulatum*.

Keywords: *Histoplasma capsulatum*, disseminated histoplasmosis, adrenal masses, hypo-adrenalism

INTRODUCTION

Histoplasmosis is a fungal disease caused by the dimorphic fungus *Histoplasma capsulatum* (*H. Capsulatum*). The disease is endemic in certain parts of the world including Asia (Benevides et al., 2007). Spores containing *H. capsulatum* can be found in soils contaminated by droppings from birds and bats. Patients are infected via inhalation of these spores and up to 80 % of them are skin test positive with histoplasmin (Jombo et al., 2010). Most infected patients are asymptomatic or have a self-limiting disease (Rana et al., 2011; Mahajan et al., 2000). Histoplasmosis usually presents in 2 forms; pulmonary and extrapulmonary, which is also known as disseminated histoplasmosis (DH). Disseminated histoplasmosis is uncommon but frequently (80 %) affects the adrenal glands (Goodwin et al., 1980). In such cases, patients often present with bilateral adrenal masses (Kumar et al., 2003). However, the incidence of hypoadrenalism amongst these group of patients is rare and was reported to

be ranging between 7 to 20 % (Subramanian et al., 2005; Rajesh et al., 2010). Hence, a high index of suspicion is prudent as the presentation may mimic other chronic infections or malignancy especially in the elderly or the immunosuppressed host (Jaiswal et al., 2011). We report a case of an elderly man with bilateral adrenal histoplasmosis and normal cortisol response who presented with vague symptoms and hypercalcaemia.

CASE REPORT

A 75-year-old man, with a background medical history of diabetes and hypertension for 10 years, presented to a private hospital with a history of prolonged fever, malaise and marked weight lost for a month. Computed tomography (CT) scan of the abdomen revealed bilateral adrenal masses measuring 3.4 x 2.9 cm (right) and 3.9 x 3.1 cm (left) respectively. A biopsy of the adrenal mass was inconclusive. After being treated empirically with oral fluconazole 200 mg daily for 2 months, his symp-

toms disappeared and he did not attend subsequent clinic appointments.

Six months later, he presented to our institution with similar symptoms of generalized bodyaches and 4 month's duration of significant loss of appetite and weight. On further questioning, he revealed a history of contact with birds. Clinically, he was dehydrated with no lymphadenopathy or organomegaly. He had normocytic anaemia (hemoglobin $10.6 \times 10^9/L$), mild thrombocytopenia ($133 \times 10^9/L$) and acute kidney injury with urea of 17.8 mmol/L, potassium 4.4 mmol/L, sodium 144 mmol/L and creatinine 365 mmol/L. Both corrected serum calcium and alkaline phosphates were elevated with levels of 3.40 mmol/L and 319 U/L respectively. Diabetic control was good with HbA1c of 5.6%. His random serum cortisol was normal (467 nmol/L) with adequate responses on synacthen test. Serology for syphilis, hepatitis A, B, C, toxoplasma antibodies and tumour markers (alpha fetoprotein, CEA 125, CA 19-9) were negative. Serum iron and TIBC were low with levels of 8.7 $\mu\text{mol/L}$ and 35 $\mu\text{mol/L}$ respectively. Sputum samples stained for acid fast bacilli were negative. Multiple myeloma workouts and HIV screening were also negative. Chest radiograph was unremarkable. A repeated CT scan of the adrenals showed persistent bilateral adrenal masses measuring 5 x 4 cm on the left and 4 x 3.6 cm on the right respectively (Figure 1 and 2). Fine needle aspiration cytology of the left adrenal gland was consistent with histoplasmosis infection (Figure 3).

The patient was treated with liposomal form of amphotericin B 180 mg daily for 2 weeks followed by oral itraconazole 200 mg bd. His serum calcium normalised and creatinine level stabilized at 171 mmol/L after adequate rehydration. The patient was discharged home after 2 months of hospital stay with oral itraconazole which was continued for a total of 1 year duration of treatment. On his subsequent clinic appointments, he was asymptomatic, gained weight and tolerated his

treatment well. Repeated CT scan showed a significant reduction in sizes of his adrenal masses.

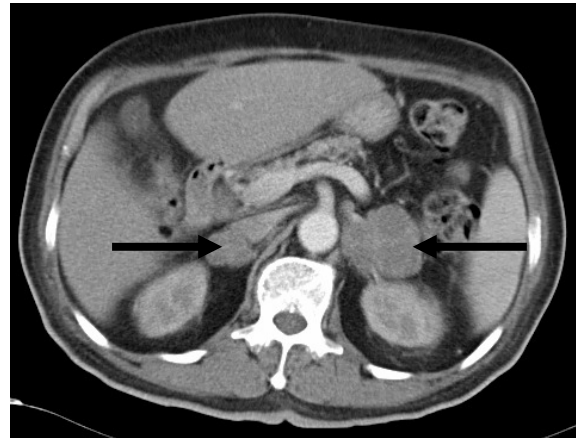


Figure 1: Axial computed tomography scan showed heterogenous enhancing bilateral adrenal enlargement (arrow) measuring 5.0 x 4.0 cm on the left (attenuation value, 30-40 HU) and 4 x 3.6cm on the right (attenuation value, 40-50 HU) with peripheral enhancement and septations.

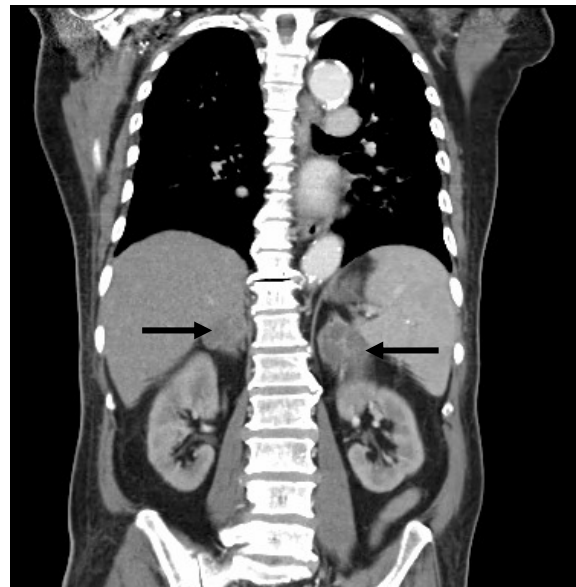


Figure 2: Sagittal computed tomography scan showed heterogenous enhancing bilateral adrenal enlargement (arrow).

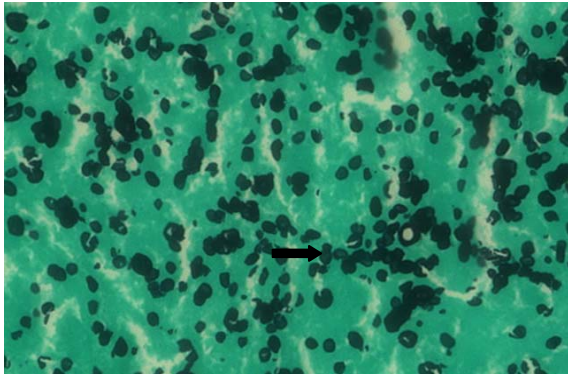


Figure 3: Histopathology of biopsy specimen from the left adrenal mass which showed numerous thin-walled rounded yeast like bodies and some with budding (arrow), seen especially within the necrotic area (Grocott stain, x 1000).

DISCUSSION

The presentation of disseminated histoplasmosis usually mimics other chronic infections or malignancy as illustrated in this case. The differential diagnoses that should be considered include tuberculosis, histoplasmosis, sarcoidosis, adrenal haemorrhage, metastatic carcinoma and lymphoma (Mukherjee et al., 2005; Narang et al., 2009).

Inhalation of *H. capsulatum* leading to pulmonary infection is usually asymptomatic or without any sequelae. However, previous study had shown that the reactivation of infection can manifest in severe forms and usually occurs in extreme age and in an immunocompromised or immunosuppressed state such as in a diabetic patient (Jaiswal et al., 2011). Our patient is an elderly man with underlying diabetes and had history of contact with pigeons. Once infected, the period of latency may extend up to 60 years (Jaiswal et al., 2011).

Hypoadrenalism is rarely reported in disseminated histoplasmosis with adrenal involvement. Kauffman showed only 12 out of 58 elderly patients with histoplasmosis were found to have adrenal involvement and none of them had adrenal failure (Kauffman, 2001). This was consistent with the findings in our patient.

Typically, patients with adrenal histoplasmosis present with bilateral adrenal en-

largement with normal configuration, peripheral enhancement and central hypodensity as a result of necrosis or haemorrhage on the CT scan (Mukherjee et al., 2005). However, bilateral adrenal enlargement with similar characteristics may be also seen in adrenal haemorrhage, lymphoma, metastatic or disseminated infections such as histoplasmosis, tuberculosis, cryptococcosis, blastomycosis, or aspergilosis (Mukherjee et al., 2005).

The presence of central necrosis and peripheral rim enhancements of the adrenals would narrow down the above differentials to tuberculosis and histoplasmosis. Hence, cytology or histopathological examination of the adrenal mass after a fine needle aspiration or percutaneous biopsy which exhibits typical microscopic features of *H. capsulatum* would be the best method to differentiate these two diagnoses especially in the absence of conclusive supporting history which would point to either one. *H. capsulatum* is an intracellular dimorphic fungus which is usually seen in the macrophages cytoplasm and exhibits narrow based budding (Fitzhugh et al., 2010; Gopal et al., 2010). Our patient underwent adrenal biopsies twice as the earlier biopsy was unsuccessful. Histopathological examination from the repeat adrenal biopsy done a year later was consistent with histoplasmosis.

The mortality in untreated DH patients was as high as 80-100 % but if treated with antifungal, this very high mortality rate is remarkably reduced to less than 25 % (Subramanian et al., 2005). The recommended treatment for adrenal histoplasmosis is similar to the disseminated histoplasmosis by using amphotericin B. Previous study recommended a total dose of 3 to 4 g of amphotericin B (Johnston et al., 1996). Once the condition improves, the therapy can be switched to itraconazole 200 mg bd. In our patient, the primary antifungal therapy instituted was liposomal amphotericin B for 2 weeks. Upon discharge, it was changed to itraconazole and was continued for one year. Apart from less nephrotoxicity, the liposomal amphotericin B achieves

the cumulative target dose faster than regular amphotericin B, resulting in shortened hospital stay. Recurrence of disease has been reported after 9 years after cessation of therapy (Rana et al., 2011). A treatment duration of between 1 to 2 years is recommended to reduce recurrence (Rana et al., 2011).

CONCLUSION

When faced with a patient with bilateral adrenal masses, physicians should always be suspicious of adrenal histoplasmosis especially in endemic areas. It is prudent to obtain a cytological or histopathological examination to confirm the diagnosis so that the appropriate treatment can be instituted to avoid fatal complications.

REFERENCES

- Benevides CF, Duraes RO, Aquino B, Schiavon Lde L, Narciso-Schiavon JL, Buzzoleti Fda C. Bilateral adrenal histoplasmosis in an immunocompetent man. *Rev Soc Brasil Med Trop* 2007;40:230-3.
- Fitzhugh VA, Maniar KP, Kim MK, Chen H, Schainker BA. Adrenal histoplasmosis. *Diagn Cytopathol* 2010;38:188-9.
- Goodwin RA Jr., Shapiro JL, Thurman GH, Thurman SS, Des Prez RM. Disseminated histoplasmosis: clinical and pathologic correlations. *Medicine* 1980;59:1-33.
- Gopal K, Singh S, Gupta R. Fine needle aspiration cytology in bilateral adrenal masses in a 58-year-old man. *Acta Cytol* 2010;54:234-6.
- Jaiswal S, Vij M, Chand G, Misra R, Pandey R. Diagnosis of adrenal histoplasmosis by fine needle aspiration cytology: an analysis based on five cases. *Cytopathology: official journal of the British Society for Clinical Cytology* 2011;22:323-8.
- Johnston AW, Brown PA, Ewen SW. Histoplasmosis - a ten year follow-up. *J Infect* 1996;33:111-3.
- Jombo GTA, Denen Akaa P, Banwat EB, Dauda M. A review of literature on unusual clinical presentations and potential challenges in diagnosis of histoplasmosis. *J Clin Med Res* 2010;2:159-66.
- Kauffman CA. Fungal infections in older adults. *Clin Infect Dis* 2001;33:550-5.
- Kumar N, Singh S, Govil S. Adrenal histoplasmosis: clinical presentation and imaging features in nine cases. *Abdom Imag* 2003;28:703-8.
- Mahajan R, Sharma U, Trivedi N, Prasad M, Kansra U, Bhandari S et al. Histoplasma capsulatum in adrenal gland aspirate--a case report. *Ind J Pathol Microbiol* 2000;43:165-8.
- Mukherjee JJ, Villa ML, Tan L, Lee KO. Bilateral adrenal masses due to histoplasmosis. *J Clin Endocrinol Metabol* 2005;90:6725-6.
- Narang V, Sinha T, Sandhu AS, Karan SC, Srivastava A, Sethi GS et al. Clinically inapparent bilateral adrenal masses due to histoplasmosis. *Europ Urol* 2009;55:518-21.
- Rajesh KF, Warriar V, Gayathri R, Chellenton J, Geetha P, Thulaseedharan NK. A case of histoplasmosis. *Calicut Med J* 2010;8(2):e7.
- Rana C, Kumari N, Krishnani N. Adrenal histoplasmosis: a diagnosis on fine needle aspiration cytology. *Diagn Cytopathol* 2011;39:438-42.
- Subramanian S, Abraham OC, Rupali P, Zachariah A, Mathews MS, Mathai D. Disseminated histoplasmosis. *J Assoc Physicians India* 2005;53:185-9.