



## Pneumoretroperitoneum from a gas-containing retroperitoneal abscess

Ta-Pin Lee<sup>a,\*†</sup>, Wen-Chih Huang<sup>b,c,†</sup>

<sup>a</sup>Department of Radiology, Wei-Gong Memorial Hospital, Miaoli, Taiwan, <sup>b</sup>Department of Anatomic Pathology, Far Eastern Memorial Hospital, New Taipei, Taiwan, <sup>c</sup>Department of Nursing, College of Nursing, National Taipei University of Nursing and Health Sciences, Taipei, Taiwan

<sup>†</sup>Both authors contributed equally to this work.

Received : 02-Jan-2017

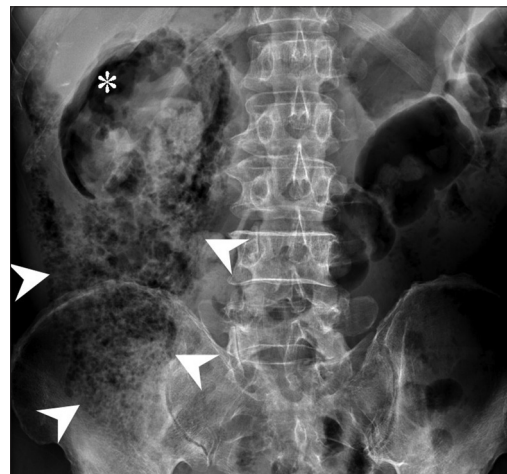
Revised : 04-Jan-2017

Accepted : 10-Jan-2017

A 57-year-old man with diabetes mellitus presented with abdominal pain, fever, and chills for 3 days. Laboratory examinations revealed leukocytosis, hyperglycemia, and decreased renal function (blood urea nitrogen: 53.0 mg/dL, creatinine: 2.9 mg/dL). An elevated serum level of HbA1c (18.0%) was also noted. A plain abdominal radiograph disclosed a large area of mottled air on the right side of the abdomen and a crescent-shaped area of air in the right upper quadrant of the abdomen [Figure 1]. Abdominal computed tomography showed a 5 mm-sized stone in the right ureterovesical junction and right hydronephrosis. Right renal parenchymal and pelvicalyceal defects were also noted. In addition, fluid and air accumulation indicating a gas-containing abscess were noted in the right side of the retroperitoneum [Figure 2]. Based on these findings, a right ureterovesical junction stone with obstruction and hydronephrosis, renal pelvicalyceal and parenchymal rupture, and retroperitoneal abscess were diagnosed. Abscess drainage was conducted, and *Escherichia coli* was found in the pus culture. The patient's condition stabilized gradually with systemic antibiotics treatment and diabetic control during the course of hospitalization.

The retroperitoneum extends from the diaphragm superiorly to the pelvic brim inferiorly, and is bordered anteriorly by the posterior parietal peritoneum and posteriorly by the transversalis fascia. It is divided by fascial planes into the anterior and posterior pararenal spaces and the perirenal (or perinephric) space [1].

Retroperitoneal hollow organs comprise a part of the esophagus, most of the duodenum, ascending and descending portions of the colon, the rectum, and the urinary tract system. The leading causes of pneumoretroperitoneum include duodenal and rectal perforation, spontaneous colon perforation, and extensions from pneumomediastinum, and gas-containing retroperitoneal abscesses. Duodenal perforation may result from peptic ulcer disease, iatrogenic injury such as endoscopic retrograde cholangiopancreatography, and blunt or penetrating injury to the abdomen. Rectal perforation is frequently caused by



**Figure 1:** Supine abdominal plain radiograph. Clustered mottled gas suggesting pneumoretroperitoneum is noted on the right side of the abdomen (arrowheads). Crescent-shaped radiolucency in the right upper quadrant of the abdomen indicates air accumulation in the right perirenal space (\*)

pelvic fracture. Spontaneous pneumoretroperitoneum usually results from perforations of colonic diverticula or cancer [2]. Other causes include superinfected necrotizing pancreatitis, necrotizing fasciitis, abscess formation, percutaneous biopsy, epidural anesthesia, extracorporeal shock-wave lithotripsy, hydrogen peroxide wound irrigation, or inferior extension of mediastinal air [1].

The most frequently used image modality for the initial workup of patients with abdominal discomfort is supine abdominal radiography (kidneys, ureters, and bladder [KUB]).

Retroperitoneal digestive organ perforation characteristically shows a thread-like radiolucency outlining the perforated organ [3-5]. In addition, severe retroperitoneal infection, such as emphysematous pyelonephritis, might produce clusters of

**\*Address for correspondence:**

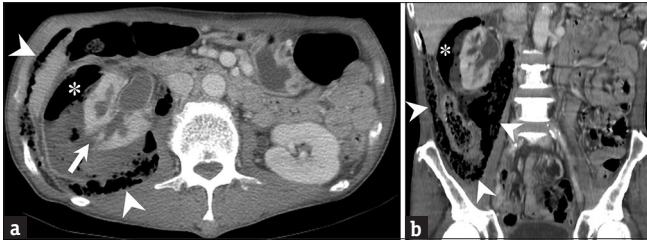Dr. Ta-Pin Lee,  
Department of Radiology, Wei-Gong Memorial Hospital, 128, Xinyi Road,  
Miaoli, Taiwan.  
E-mail: leetapin@gmail.com

This is an open access article distributed under the terms of the Creative Commons Attribution-NonCommercial-ShareAlike 3.0 License, which allows others to remix, tweak, and build upon the work non-commercially, as long as the author is credited and the new creations are licensed under the identical terms.

For reprints contact: reprints@medknow.com

**How to cite this article:** Lee TP, Huang WC. Pneumoretroperitoneum from a gas-containing retroperitoneal abscess. Tzu Chi Med J 2017;29:185-6.

Access this article online	
<b>Quick Response Code:</b> 	<b>Website:</b> www.tcmjmed.com
	<b>DOI:</b> 10.4103/tcmj.tcmj_66_17



**Figure 2:** Axial (a) and coronal (b) abdominal computed tomography. Gas collections are noted in the retroperitoneal perirenal space (\*) and posterior pararenal space (arrowheads). Right hydronephrosis with ruptured right renal parenchyma and pelvicalyx is also shown (arrow)

numerous small air bubbles, from gas-forming organisms in the retroperitoneal adipose tissue and create the specific manifestation of a “mottled air sign” on KUB [6].

Physicians should be aware that pneumoperitoneum and pneumoretroperitoneum can exist simultaneously. Even if there is an intraperitoneal air sign, the possibility of a retroperitoneal air sign should not be overlooked in cases of suspected retroperitoneal infection or bowel perforation.

#### **Declaration of patient consent**

The authors certify that the patient has obtained appropriate patient consent form. In the form, the patient has given

his consent for his images and other clinical information to be reported in the journal. The patient understands that his name will not be published and all efforts will be made to conceal his identity.

#### **Financial support and sponsorship**

Nil.

#### **Conflicts of interest**

There are no conflicts of interest.

#### **REFERENCES**

1. Goenka AH, Shah SN, Remer EM. Imaging of the retroperitoneum. *Radiol Clin North Am* 2012;50:333-55, vii.
2. Romano L, Pinto A. *Imaging of Alimentary Tract Perforation*. Switzerland: Springer; 2015. p. 85-6.
3. Yokomuro S, Uchida E, Arima Y, Mizuguchi Y, Shimizu T, Kawahigashi Y, et al. Simple closure of a perforated duodenal diverticulum: “A case report”. *J Nippon Med Sch* 2004;71:337-9.
4. Dindyal S, Bhuva NJ, Dindyal S, Ramdass M, Narayansingh V. Trichobezoar presenting with the ‘comma sign’ in Rapunzel syndrome: A case report and literature review. *Cases J* 2008;1:286.
5. Byrne P, Leung JW, Cotton PB. Retroperitoneal perforation during duodenoscopic sphincterotomy. *Radiology* 1984;150:383-4.
6. Wang YC, Lin CM, Chen SK. Intraperitoneal versus retroperitoneal air signs in abdominal radiographs. *Am J Emerg Med* 2010;28:109-10.