



Contents lists available at ScienceDirect

International Journal of Surgery Case Reports

journal homepage: www.casereports.com

Saved from a fatal flight: A ruptured splenic artery aneurysm in a pregnant woman



Anke C. Heitkamp^{a,*}, Chris Dickhoff^b, Johanna H. Nederhoed^b,
Gaby Franschman^c, Johanna I. de Vries^a

^a Department of Obstetrics and Gynecology, VU University Medical Center, P.O. Box 7057, 1007MB Amsterdam, The Netherlands

^b Department of Surgery, VU University Medical Center, P.O. Box 7057, 1007MB Amsterdam, The Netherlands

^c Department of Anesthesiology, VU University Medical Center, P.O. Box 7057, 1007MB Amsterdam, The Netherlands

ARTICLE INFO

Article history:

Received 9 September 2014

Received in revised form 5 January 2015

Accepted 6 January 2015

Available online 9 January 2015

Keywords:

Splenic artery

Aneurysm

Ruptured

Acute

Pregnancy

ABSTRACT

INTRODUCTION: The reported prevalence of a SAA varies between 0.01 and 10.4% [1], and since SAAs often remain asymptomatic, the true prevalence is uncertain. The reported SAAs occur more frequently in younger patients, with 58% diagnosed in women of childbearing age; 95% of these are diagnosed during pregnancy.

PRESENTATION OF CASE: A 26-year-old woman, thirty-one weeks pregnant, was about to board an airplane for a three hour flight from the Netherlands to Turkey. Just before entering the plane, she suddenly felt a severe abdominal pain. Ultrasound guided aspiration of the abdominal fluid showed blood and supported the decision to perform urgent laparotomy. A caesarean section was performed. After further inspection a ruptured SAA was encountered. The splenic artery was ligated proximally and distally to the rupture in order to stop the bleeding. As the hilar localization of the aneurysm interfered with a primary vascular reconstruction, a splenectomy was performed. The mother and baby survived.

DISCUSSION: Although rupture of a SAA is rare, its consequences can be devastating for both mother and child. The literature shows a higher incidence of ruptured SAA in pregnant women, although there is a difficulty in recognizing hemodynamic instability in pregnancy due to the increase in circulating volume. **CONCLUSION:** In case of pregnant women with acute abdomen and hypovolemia, emergency physicians, surgeons, anesthesiologists, and gynecologists should be aware of the possibility of a ruptured SAA, apart from more common causes like placental abruption, placenta percreta, or uterine rupture. Early recognition and prompt multidisciplinary treatment might save the life of mother and child.

© 2015 The Authors. Published by Elsevier Ltd. on behalf of Surgical Associates Ltd. This is an open access article under the CC BY-NC-ND license (<http://creativecommons.org/licenses/by-nc-nd/4.0/>).

1. Introduction

Acute abdominal complications during pregnancy are potentially fatal for both mother and fetus. Prompt recognition and management of this hazardous medical condition can save lives. A rare cause of acute abdomen in pregnancy, is life-threatening abdominal hemorrhage due to rupture of a splenic artery aneurysm (SAA).

The reported prevalence of a SAA varies between 0.01 and 10.4% [1], and since SAAs often remain asymptomatic, the true prevalence is uncertain. The reported SAAs occur more frequently in younger patients, with 58% diagnosed in women of childbearing age; 95% of these are diagnosed during pregnancy. Rupture is associated with a high maternal and fetal mortality rate, 64–75% and 72.5–95%, respectively [1].

We present a patient with a ruptured SAA during pregnancy, who was successfully saved from what could have become a fatal flying-trip. She was treated with an emergency caesarean section, followed by aneurysm exclusion and splenectomy.

2. Presentation of case

A 26-year-old woman, gravid 2 para 1, thirty-one weeks pregnant, was about to board an airplane for a three hour flight from Amsterdam, the Netherlands to Istanbul, Turkey. Her first pregnancy went uneventful and she delivered vaginally at term a boy of 4220 g. The placenta was removed manually and total blood loss of 1400 mL. Just before entering the plane, she suddenly felt a severe abdominal pain. Not willing to give up her vacation, she continued boarding. However, one of the stewardesses noticed the passenger's discomfort and convinced her to depart from the plane. By ambulance, she was transported to the emergency department of our hospital. The crew informed the hospital about the acute abdominal pain, pallor, low blood pressure, and suspicion of placental abruption.

* Corresponding author. Tel.: +31 20 4443258/6 41896351; fax: +31 20 4441485.
E-mail address: a.heitkamp@slaz.nl (A.C. Heitkamp).

On admission, a team of emergency staff, gynecologist and anesthesiologist was present in the emergency department and immediate assessment was done. The patient presented with pallor, a respiratory rate of 18/min, oxygenation of 100%, blood pressure of 90/60 mm Hg, a pulse rate of 93 beats per minute (BPM), and diffuse abdominal pain. Palpation of the uterus did not elicit extra pain.

Fetal and placental examination by means of ultrasonography done by the gynecologist, revealed a fetal heart rate within the normal range (110–150BPM) and no signs of evident placental abruption. The latter conclusion, however, was made with full awareness of the high positive, but low negative predictive value of ultrasound in detecting placental abruption [2]. On subsequently performed cardiotocography of the fetus, there was no tachycardia and a normal beat-to-beat variation, with accelerations and no decelerations. The patient informed us that a similar short lasting abdominal pain was felt during the morning, starting in the left upper abdomen. In search of another cause of the deteriorating condition of the patient, a bed-side ultrasound of the maternal abdomen demonstrated signs of intra-abdominal free fluid. Laboratory findings showed a plasma hemoglobin level of 6.4 mmol/L.

At that moment, the differential diagnosis was rupture of a SAA, rupture of a uterine artery, uterine rupture, or partial placental abruption. Ultrasound guided aspiration of the abdominal fluid showed blood and supported the decision to perform urgent laparotomy with a team consisting of a general surgeon, a vascular surgeon, and two obstetricians. By this time, fetal condition deteriorated, with tachycardia and declining variability.

The anesthesiologist prepared for lower and upper medial laparotomy and cell salvage equipment was set up. The neonatologist was present in the operating theater. At the time the abdomen was opened, blood emerged and was collected for cell salvage. The uterus was hypotonic. A prompt caesarean section followed. A healthy girl was born with an Apgar score of 9 out of 10 at one minute. After removal of the placenta oxytocin, and thereafter sulproston 100 µg/h were given intravenously. After evacuating the intra-abdominal blood, a bulging omental bursa was observed which was incised and explored. As expected, a ruptured SAA was encountered (Fig. 1A). The splenic artery was ligated proximally and distally to the rupture in order to stop the bleeding (Fig. 1B). As the hilar localization of the aneurysm interfered with a primary vascular reconstruction, a splenectomy was performed.

During operation, maternal blood pressure remained stable by returning 2 L of blood collected with the cell saver, and administering ten units of packed cells (300 mL each) and 8 units of fresh frozen plasma. The five consecutive days antibiotic prophylaxis was prescribed, daily 200 mg ceftriaxone and three times a day 500 mg metronidazole.

Postoperative recovery was uneventful for both the mother and her baby; the mother was discharged in good physical condition eleven days after surgery and her daughter after 4 weeks with normal and uneventful development despite preterm birth.

The woman was informed about the consequences of her present asplenic situation, the need for vaccination and immediate start of antibiotic treatment as soon as she develops fever.

3. Discussion

We report a case of a pregnant woman with a ruptured SAA in which mother and baby survived. Although rupture of a SAA is rare, its consequences can be devastating for both mother and child. Maternal and fetal mortality rates are as high as 70–90%, respectively [1,3,4].

Weakness of the arterial wall and increased blood pressure predispose for development of a SAA. It is hypothesized that in pregnancy estrogens and progesterons lead to degeneration of the

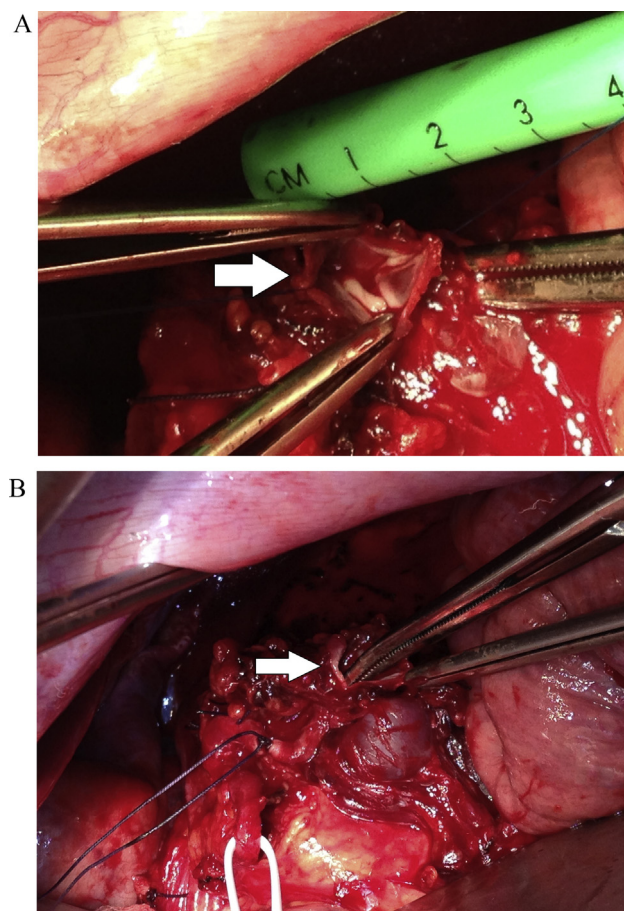


Fig. 1. Peroperative photographs: (A) the ruptured splenic artery aneurysm (see arrow) with diameter of 1.5 cm. (B) The ligated splenic artery, with the ruptured splenic artery aneurysm (indicated by the arrow) located peripheral, close to the splenic hilum.

arterial wall [1,3,4]. This might be the explanation for the higher incidence of ruptured SAA in pregnant women.

In general, a ruptured SAA is diagnosed during laparotomy or, too late, at post mortem examination. Recognition of clinical symptoms is therefore, of vital importance. This patient presented with acute diffuse abdominal pain, starting in the left upper quadrant. This is a typical presentation for ruptured SAA. In some patients it is accompanied by pain in the left tip of the shoulder (Kehr sign). These symptoms can be present in combination with sudden collapse, nausea, vomiting, or hemodynamic instability [1,3,4]. There is a difficulty in recognizing hemodynamic instability in pregnancy due to the increase in circulating volume. Signs of hypovolemia only appear when 35% or more of the total circulating volume is lost. To compensate hypovolemia, blood flow to the placenta will decrease. Therefore, blood loss in the mother is often reflected by fetal distress. Thus, monitoring the fetus is relevant to both mother and child [5].

Imaging should not delay the diagnostic process. Ultrasound, MRI, MRA, CT, and endoscopic ultrasound are all methods to make the diagnosis of a SAA more likely. In hemodynamically unstable patients, ultrasound has the advantage of being fast, bed-side available, and relatively cheap. It can be used as a tool to support the diagnosis ruptured SAA, especially when ultrasound guided aspiration confirms abdominal blood [1,3,4].

Emergency laparotomy for SAA ligation to stop bleeding with or without re-anastomosis of the artery or splenectomy is the treatment of choice.

Postoperatively asplenic patients need to be informed that any illness with fever or severe symptoms without fever could indicate the onset of a life-threatening infection, vaccinations against pneumococci, haemophilus influenza type b, meningococci, and influenza virus are recommended for asplenic patients [6].

A midline incision is to be preferred over a Pfannenstiel incision to create better exposure [7]. A laparoscopic approach for a SAA has been described in elective surgery [8], but this will not be appropriate in the emergency setting. In a pregnant woman with acute severe hypovolemia, performing a caesarean section is part of the haemodynamic stabilization. This is supported by literature on cardiac arrest and perimortem caesarean section enhancing chances for mother and fetus [5,9].

4. Conclusion

In case of pregnant women with acute abdomen and hypovolemia, emergency physicians, surgeons, anesthesiologists, and gynecologists should be aware of the possibility of a ruptured SAA, apart from more common causes like placental abruption, placenta percreta, or uterine rupture. In hemodynamically stable pregnant women with symptoms fitting a ruptured SAA, immediate bed-side ultrasound imaging should be performed in order to visualize possible intra-abdominal fluid. The presence of abdominal fluid, with or without aspiration, will help in the decision for direct surgical intervention. When maternal hemodynamic instability requires emergency laparotomy, correction of the hypovolemia is supported by a caesarean section prior to ligation of the splenic artery, enhancing survival of both the unborn child and the mother.

Early recognition of a serious health condition by the flight attendant, immediate ambulance transfer with information of the patient to the emergency department of the hospital and prompt multidisciplinary treatment by a team consisting of a surgeon, gynecologist, and anesthesiologist (neonatologist, hematologist) can be life-saving as we showed in our case. Therefore, awareness of this cause of acute abdomen, rupture of a SAA, in a pregnant patient and direct response is mandatory.

Conflict of interest

The authors declare not to have any financial or personal relationships that influence this case report.

Funding

The authors declare not to have any financial support for this case report.

Ethical approval

Not applicable.

Author contribution

All the authors were involved in the medical treatment of the patient in this case report, this article is written with the same multidisciplinary approach.

Anke C. Heitkamp (resident gynecology and obstetrics) was involved in the patient care from admission to discharge, she performed the literature review, wrote the article and did the submission process. Chris Dickhoff (consultant surgery) was present in the emergency room and performed the surgery of the laparotomy and the aneurysm together with Johanna H. Nederhoed (consultant surgery, vascular, and endovascular subspecialist) who supervised this surgery as an endovascular specialist, they added the surgical information and the pictures to this article. They reviewed and offered critiques to the article. Gaby Franschman (consultant in anesthesia) was the anesthesiologist during surgery and reviewed the article. Johanna I. de Vries, (professor in obstetrics and gynecology) was present in the emergency room for diagnoses and supervised the caesarean section, she was the case manager for this patient. She reviewed, wrote part of the discussion and offered critiques to the article.

Guarantor

Anke C. Heitkamp and Johanna I. de Vries.

Consent

The authors confirm that a written informed consent was obtained from the patient for publication of this case report and accompanying images. A copy of the written consent is available for review by the Editor-in-Chief of this journal on request.

Acknowledgement

The flight crew, for early recognition and adequate referral of a woman in pain.

References

- [1] J.F. Ha, M. Phillips, K. Faulkmer, Splenic artery aneurysm rupture in pregnancy, *Eur. J. Obst. Gynecol. Reprod. Biol.* 146 (2009) 133–137.
- [2] C. Glantz, L. Purnell, Clinical utility of sonography in the diagnosis and treatment of placental abruption, *J. Ultrasound Med.* 21 (August (8)) (2002) 837–840.
- [3] U. Sadat, O. Dar, S. Walsh, K. Varty, Splenic artery aneurysms in pregnancy—a systematic review, *Int. J. Surg.* 6 (June (3)) (2008) 261–265 (Epub 2007 August 17).
- [4] D.O. Selo-Ojeme, C.C. Welch, Review spontaneous rupture of splenic artery aneurysm in pregnancy, *Eur. J. Obst. Gynecol. Reprod. Biol.* 109 (August 15 (2)) (2003) 124–127.
- [5] K. Grady, C. Howell, C. Cox, *Managing Obstetric Emergencies and Trauma*, Advanced Life Support Group & Royal College of Obstetricians and Gynaecologists, 2002.
- [6] G. Lorry, M.D. Rubin, M.D. William Schaffner, Care of the Asplenic Patient, *N. Engl. J. Med.* 371 (July 24) (2014) 349–356.
- [7] F. Asfar, M. Saber, P.M. Dhar, N. Al Awadhi, Rupture of splenic artery aneurysm during labor: a case report of maternal and fetal survival, *Med. Princ. Pract.* 14 (January–February (1)) (2005) 53–54.
- [8] Y. Al-Habbal, C. Christophi, V. Muralidharan, Aneurysms of the splenic artery—a review, *Surgeon* 8 (August (4)) (2010) 223–231.
- [9] A. Dijkman, C.M. Huisman, M. Smit, et al., Cardiac arrest in pregnancy: increasing use of perimortem caesarean section due to emergency skills training? *BJOG* 117 (February (3)) (2010) 282–287.

Open Access

This article is published Open Access at sciedirect.com. It is distributed under the [IJSCR Supplemental terms and conditions](#), which permits unrestricted non commercial use, distribution, and reproduction in any medium, provided the original authors and source are credited.