

The combination of thermal dysregulation and agenesis of corpus callosum: Shapiro's or/and reverse Shapiro's syndrome

Yasemin Topcu, Erhan Bayram, Pakize Karaoglu, Uluc Yis, Semra Hiz Kurul

Department of Pediatrics, Dokuz Eylul University Medical Faculty, Division of Pediatric Neurology, İzmir, Turkey

Abstract

Shapiro syndrome is an extremely rare condition consisting the clinical triad of recurrent hypothermia, hyperhidrosis and agenesis of the corpus callosum. On the other hand, reverse Shapiro's syndrome is characterized periodic hyperthermia and agenesis of the corpus callosum. Here, we describe a 3.5-year-old girl with complete agenesis of corpus callosum presenting with recurrent fever and vomiting. She also had hypothermia attacks with accompanying diaphoresis. To the best of our knowledge, there is no described case with episodes of hyperthermia, hypothermia, and vomiting associated with agenesis of the corpus callosum. Recurrent vomiting may be a newly defined symptom associated with these syndromes.

Key Words

Agenesis of corpus callosum, Shapiro's syndrome, vomiting

For correspondence:

Dr. Yasemin Topcu, Department of Pediatrics, Dokuz Eylul University Medical Faculty, Division of Pediatric Neurology, İzmir, Turkey. E-mail: drytopcu@yahoo.co.uk

Ann Indian Acad Neurol 2013;16:716-9

Introduction

Shapiro syndrome, first described in 1969 by Shapiro *et al.*, is an extremely rare condition consisting of the clinical triad of recurrent hypothermia, hyperhidrosis, and agenesis of the corpus callosum. The syndrome has agenesis of the corpus callosum as a hallmark.^[1] To date, about 50 cases have been reported.^[1-9] On the other hand, reverse Shapiro's syndrome is characterized with periodic hyperthermia and agenesis of the corpus callosum. Hirayama *et al.* reported a 14-year-old girl presenting with periodic hyperthermia associated with agenesis of the corpus callosum in 1994.^[9] This case was the first reported case of "reverse" Shapiro's syndrome. Lin and Wang reported a 9-month-old girl presenting with fever of unknown origin since the age of 7 months in 2005 who had agenesis of corpus callosum.^[10] Characteristic properties of these two syndromes are dysregulation of body temperature and agenesis of corpus callosum.

According to our knowledge, there are only two described cases of periodic hyperthermia episodes associated with agenesis of the corpus callosum. However, there is no described case with episodes of hyperthermia and hypothermia, recurrent vomiting together with agenesis of the corpus callosum.

Case Report

A 3.5-year-old girl was admitted to the Dokuz Eylul University Hospital with complaints of recurrent fever and vomiting. The patient had a history of hyperthermia episodes and vomiting, which started 4 months before admission. She had an axillary daily spiking fever up to 40°C. Fever and vomiting attacks lasted for 3-8 days. Vomiting did not accompany fever in all of the episodes. Besides these fever attacks, her mother mentioned that her child was also "becoming cold" during the day and this condition lasted approximately 1 h with accompanying diaphoresis. She had been investigated at other hospitals and had been treated with antibiotics for a presumed infection many times. She had agenesis of the corpus callosum, which was determined during the intrauterine period. She had psychomotor retardation. The parents were not consanguineous. There was no history of exposure to tuberculosis, cats, tick, insect bites, rash, arthralgia, arthritis, diarrhea, constipation, abdominal pain, or weight loss.

On physical examination, her weight, height, and head circumference were 10 kg (<3p), 88 cm (<3p), 46 cm (50-75p),

Access this article online

Quick Response Code:



Website:

www.annalsofian.org

DOI:

10.4103/0972-2327.120451

respectively. Blood pressure was 90/55 mmHg. Body temperature was 40°C. Neurologic examination revealed strabismus, brisk deep tendon reflexes, and axial hypotonicity. Examination of the ears, nose, and throat was normal. She had normal lymphoid tissue with no adenopathy. Lungs were normal and cardiac examination revealed no murmur. There was no hepatosplenomegaly. The remainder of the physical examination was normal. The cause of fever with vomiting was unable determined in examination.

Initial laboratory results were as follows: White blood cell count 9600/mm³ (4000-10300); hemoglobin 9.6 g/dL (12-14.5); platelet count 496000/mm³ (156000-373000); C-reactive protein 2.3 mg/L (0.1-8.2). Peripheral blood smear was normal. Renal and liver function tests, serum creatine kinase, electrolyte levels, and urine analysis were normal. The child was started with ceftriaxone. Cultures of blood and urine were negative. Serological work-up for toxoplasmosis, rubella, cytomegalovirus, herpes simplex virus, ebstein barr virus, brucella, salmonella, mycoplasma pneumoniae, chlamydia, and hepatitis were negative. Evaluation for tuberculosis was also negative. After the elimination of infections, antibiotherapy was stopped. Serum immunoglobulin A, M, G and complement (C3, C4) levels were normal. Anti-nuclear antibodies, anti-double stranded DNA antibodies, anti-neutrophil cytoplasmic antibodies, extractable nuclear antigens were negative. Mediterranean fever mutation analysis for familial mediterranean fever was negative. Level of serum Ig D for hyperimmunoglobulin-D syndrome was normal (18 IU/mL, N: 2-99.3). Abdominopelvic ultrasonography revealed normal findings. Brain magnetic resonance images (MRI) confirmed complete agenesis of corpus callosum [Figure 1]. Chest radiography and electroencephalography were normal.

She had normal serum levels of thyrotropin releasing hormone (2.82 µIU/mL) and free thyrotropin (1.22 ng/dL), cortisol (20.5 µg/dL), adrenocorticotropic hormone (15.9 pg/mL). Thus, infections, collagen vascular diseases, malignancy, hematologic diseases, some of periodic fever syndromes, hormonal disorder were excluded as the cause of her periodic hyperthermia with vomiting. Besides these fever attacks, during hospitalization, axillary body temperature of our case was observed to decrease to 34.3°C [Figure 2] with accompanying diaphoresis, lasting for approximately an hour.

Patient was evaluated in terms of possible metabolic causes of recurrent vomiting. A metabolic survey including analysis of serum tandem mass spectrometry and blood, urine amino acid assay found nothing specific. Serum lactic acid and ammonia level were normal. Venous blood gas analysis was normal during vomiting attacks. Thereby, metabolic diseases were excluded. In terms of recurrent vomiting, all investigations including analysis of serum and urine, abdominopelvic ultrasonography, MRI were normal. No specific cause of the recurrent vomiting was identified. Bowel obstruction was not considered because physical examination was normal and there was no symptom except for attack.

In our case, thermal dysregulation and vomiting was considered to may be associated with agenesis of corpus callosum. On the

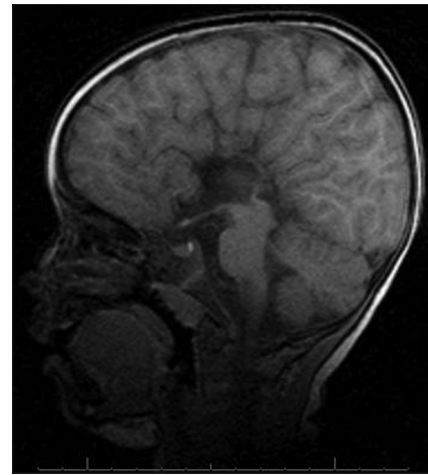


Figure 1: Brain magnetic resonance imaging-sagittal image show agenesis of complete corpus callosum

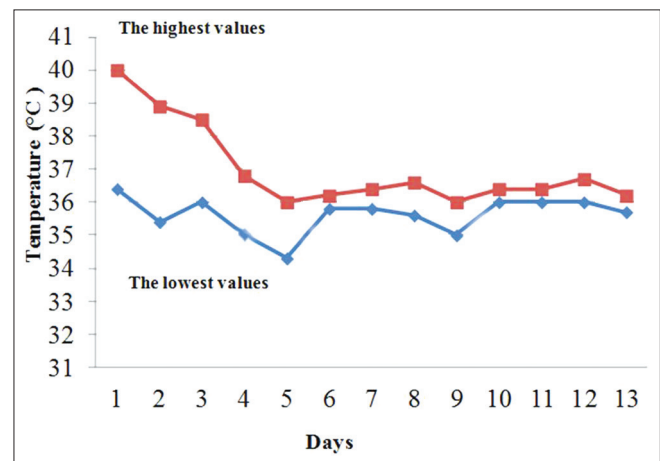


Figure 2: The axillary body temperature measurement results are shown during the hospitalization period

15th day of the follow-up, she was discharged after resolving patient's fever and vomiting attacks.

Discussion

Two hypothalamic centers act reciprocally to maintain body temperature. The posterior center conserves heat by inducing vasoconstriction, shivering while the anterior center (preoptic anterior hypothalamic area) controls heat dissipation by stimulating caudal hypothalamic region, which induces vasodilation and sweating.^[1,11] Destruction of the anterior center may cause hyperthermia, while posterior hypothalamic lesions may result in hypothermia. Persistent hypothermia or periodic hypothermia due to thermoregulatory dysfunction with associated hypothalamic damage has been well-recognized in the literature.^[12] LeWitt *et al.* recognized that acute central nervous system dysfunction with hypothalamic involvement cause transient hypothermia.^[13] Periodic hypothermia has been observed to be associated with agenesis of the corpus callosum (Shapiro syndrome) and first described by Shapiro *et al.*^[1] To date, several hypotheses have been suggested regarding pathophysiologic mechanisms underlying this

syndrome. Hypothalamic damages have been reported to may be one of the possible mechanisms. Noël *et al.* done postmortem pathologic examination in only one case and determined severe neuronal loss and fibrillary gliosis in the hypothalamic infundibular nuclei.^[14] Pineda *et al.* reported that postmortem examination revealed a severe spongiosis of the white matter in addition to the agenesis of the corpus callosum and septum pellucidum.^[15] Based on the pathological findings, it has been hypothesized that hypothalamic lesions may play an important role for the thermal dysregulation. In our case, we could not show identifiable cause that might have explained her episodes of periodic hyperthermia-hypothermia, except for agenesis of the corpus callosum. Endocrine evaluation of hypothalamic-pituitary axis, thyroid, adrenals, and gonads can unremarkable in patients with Shapiro syndrome. Some of the cases with Shapiro syndrome described in the literature have not been determined hormonal abnormalities.^[5,16,17] We did not perform thyrotropin releasing hormone test cause thyroid-stimulating hormone, free thyroxine were normal.

Neurochemical abnormalities have been reported to be in association with thermal dysregulation. It has been reported that the episodic nature of the attacks hypothermia supports that Shapiro syndrome may be related to a chemical abnormality rather than a structural lesion of the hypothalamus.^[18-20] Lin *et al.* reported that agenesis of the corpus callosum may be associated with dysregulation of dopamine-related thermoregulatory circuitry.^[10,21] Segeren *et al.* observed abnormalities in norepinephrine metabolism in some cases with Shapiro syndrome.^[20] Lewitt *et al.* also reported that some patients with Shapiro's syndrome have high plasma levels of catecholamines while excretion of catecholamine metabolites in the urine is normal.^[13,20] Hirayama *et al.* reported that hyperthermia in their case with reverse Shapiro's syndrome returned to normal by a dopamine agonist. They speculated that hyperthermia may have been caused by dopaminergic denervation of the hypothalamic thermoregulatory center.^[9] It is possible that dopamine-related thermoregulatory circuitry could have been malformed although MRI did not show structural abnormalities in the hypothalamus. Based on this information, neurochemical abnormalities seem to be the most probable mechanism in the pathophysiology of hypothermia-hyperthermia episodes in our patient.

Recurrent fever was the most prominent complaint in our patient. Previously, hypothermia was not recognized by family. Hypothermia was detected during hospitalization. Episode of recurrent cooling and excessive sweating described by the mother was thought to be related to hypothermia. Observation hypothermia with accompanying diaphoresis during hospitalization showed that episodes of hyperthermia and hypothermia repeat in our patient. We could not find a cause of inflammatory or infectious that may explain attacks of hyperthermia in our patient. To date, there is no described child with episodes of hyperthermia and hypothermia together with agenesis of the corpus callosum.

Shapiro's or reverse Shapiro's syndrome accompanied by periodic vomiting attacks has not been reported in literature. The role of corticotropin-releasing-factor (CRF) as a brain-gut mediator in foregut function has been extensively described in animals by Lenz *et al.*^[22] Taché *et al.*^[23] It is hypothesized

that CRF is released from the hypothalamus in response to various efficient. This CRF release can stimulate the inhibitory motor nerves in the dorsal motor nucleus of the vagus, causing delayed gastric emptying and nausea.^[24] Cyclic vomiting syndrome (CVS), which is characterized by severe discrete episodes of nausea, vomiting, is a fairly common, predominately childhood condition. Clinical CVS in humans is precipitated by parallel stimuli that augment CRF release in animals. Coexisting neurologic findings of developmental delay, generalized seizures, and hypotonia, as well as neuromuscular disease manifestations, which include cognitive disorders, skeletal myopathy, and cranial nerve dysfunction have been found in approximately 25% of CVS patients.^[25] CVS patients with these findings have been labeled as CVS plus. A comparison of CVS plus patients to CVS patients with no neurologic findings revealed that CVS plus patients have an earlier age of onset. They also have a 3-to 8-fold greater prevalence of dysautonomic-related disorders and constitutional abnormalities (eg., growth retardation, birth defects).^[25] Previously, Akioka *et al.* reported a case with congenital multiple anomaly syndrome with recurrent vomiting. The etiology of recurrent vomiting was unknown. They determined dilatation of the ventricles and hypoplasia of the cerebellum in brain MRI. They speculated that an organic brain lesion affecting the endocrine environment could precipitate the periodic vomiting.^[26] Their hypothesis may also account for the vomiting episodes seen in our patient. Welch *et al.* have suggested that patients with CVS may have a mechanism such as spontaneous cortical spreading depression, which is believed to be responsible for migraine pathophysiology. Kakisaka *et al.* have reported a patient who had 18q-syndrome complicated with CVS and has showed successfully treated with sumatriptan.^[27] Based on the this knowledge, recurrent vomiting was thought to may share some pathophysiology with migraine. It is also known that emetic pathway contain receptors for one or more neurotransmitter, including dopamine type 2, serotonin types 2-4, histamine type 1, and acetylcholine (muscarinic receptors type 1-5).^[28] Due to being a part of many transmitters in vomiting pathogenesis and no specific cause of the recurrent vomiting was identified, we speculated that corpus callosum agenesis could induce neurotransmitter dysregulation and it could trigger periodic vomiting. In our patient, all examinations were normal in terms of recurrent vomiting. There was no symptom associated with gastrointestinal system except attacks. Therefore, we thought that recurrent vomiting may be associated with agenesis of corpus callosum as part of this syndrome.

No definitive treatment for this disorder has been reported. Various therapies for recurrent hypothermia or hyperthermia have been tried. Dopamine agonists (levodopa with carbidopa or bromocriptine mesylate), dopamine antagonists (chlorpromazine hydrochloride and haloperidol), serotonin antagonist (cyproheptadine hydrochloride), an α 2-adrenergic agonist (clonidine) or sympathectomy were preferred in patients with hypothermia.^[9,12-14,18] Hirayama *et al.* reported that the hyperthermia in their patient with reverse Shapiro's syndrome was controlled effectively with the dopamine agonist.^[9] Ling and Wang reported that dopamine agonists (levodopa with carbidopa) and the serotonin antagonist (cyproheptadine hydrochloride) failed to control the hyperthermia. They reported that insufficient

drug dosage or a different mechanism of dopamine-related thermoregulatory circuit might account for this failure.^[10] After discharge, we started the serotonin antagonist (cyproheptadine hydrochloride) to our patient. Treatment of cyproheptadine hydrochloride was stopped in the 10th day due to lack of response to the treatment and increase in vomiting.

Conclusion

Thermal dysregulation could be seen with agenesis of corpus callosum. We thought that Shapiro's and reverse Shapiro's syndromes are not different entities from each other because episodes of hypothermia and hyperthermia could be present in the same patient. Recurrent vomiting may be a newly defined symptom associated with this syndrome. This case is the first reported case with episodes of hyperthermia, hypothermia, and vomiting together with agenesis of the corpus callosum.

References

- Shapiro WR, Williams GH, Plum F. Spontaneous recurrent hypothermia accompanying agenesis of the corpus callosum. *Brain* 1969;92:423-36.
- Walker BR, Anderson JA, Edwards CR. Clonidine therapy for Shapiro's syndrome. *Q J Med* 1992;82:235-45.
- Sanfield JA, Linares OA, Cahalan DD, Forrester JM, Halter JB, Rosen SG. Altered norepinephrine metabolism in Shapiro's syndrome. *Arch Neurol* 1989;46:53-7.
- Shenoy C. Shapiro syndrome. *QJM* 2008;101:61-2.
- Dundar NO, Boz A, Duman O, Aydin F, Haspolat S. Spontaneous periodic hypothermia and hyperhidrosis. *Pediatr Neurol* 2008;39:438-40.
- Klein CJ, Silber MH, Halliwill JR, Schreiner SA, Suarez GA, Low PA. Basal forebrain malformation with hyperhidrosis and hypothermia: Variant of Shapiro's syndrome. *Neurology* 2001;56:254-6.
- Tambasco N, Corea F, Bocola V. Subtotal corpus callosum agenesis with recurrent hyperhidrosis-hypothermia (Shapiro syndrome). *Neurology* 2005;65:124.
- Hemseloet DM, De Bleecker JL. Post-traumatic spontaneous recurrent hypothermia: A variant of Shapiro's syndrome. *Eur J Neurol* 2007;14:224-7.
- Hirayama K, Hoshino Y, Kumashiro H, Yamamoto T. Reverse Shapiro's syndrome. A case of agenesis of corpus callosum associated with periodic hyperthermia. *Arch Neurol* 1994;51:494-6.
- Lin KL, Wang HS. Reverse Shapiro's syndrome: An unusual cause of fever of unknown origin. *Brain Dev* 2005;27:455-7.
- Myers RD. Ionic concepts of the set-point for body temperature. In: Lederis K, Cooper KE, editors. *International symposium on recent studies of hypothalamic function*. Calgary, 1973. Basel: S Karger, 1974: p. 371.
- Kloos RT. Spontaneous periodic hypothermia. *Medicine (Baltimore)* 1995;74:268-80.
- LeWitt PA, Newman RP, Greenberg HS, Rocher LL, Calne DB, Ehrenkranz JR. Episodic hyperhidrosis, hypothermia, and agenesis of corpus callosum. *Neurology* 1983;33:1122-9.
- Noël P, Hubert JP, Ectors M, Franken L, Flament-Durand J. Agenesis of the corpus callosum associated with relapsing hypothermia. A clinico-pathological report. *Brain* 1973;96:359-68.
- Pineda M, Gonzalez A, Fàbregues I, Fernández-Alvarez E, Ferrer I. Familial agenesis of the corpus callosum with hypothermia and apneic spells. *Neuropediatrics* 1984;15:63-7.
- Belcastro V, Striano P, Pierguidi L, Arnaboldi M, Tambasco N. Recurrent hypothermia with hyperhidrosis in two siblings: Familial Shapiro syndrome variant. *J Neurol* 2012;259:756-8.
- Kenney DL, Toledano M, Moseley BD. Hypothermia and corpus callosum agenesis in Shapiro syndrome: Too cold, even for a Viking. *Neurology* 2012;79:e78.
- Carr-Locke D, Millac P. Diencephalic epilepsy in a patient with agenesis of the corpus callosum confirmed by computerised axial tomography. *J Neurol Neurosurg Psychiatry* 1977;40:808-14.
- Cagnacci A, Elliott JA, Yen SS. Melatonin: A major regulator of the circadian rhythm of core temperature in humans. *J Clin Endocrinol Metab* 1992;75:447-52.
- Segeren CM, Polderman KH, Lips P. Agenesis of the corpus callosum associated with paroxysmal hypothermia: Shapiro's syndrome. *Neth J Med* 1997;50:29-35.
- Parrish ML, Roessmann U, Levinsohn MW. Agenesis of the corpus callosum: A study of the frequency of associated malformations. *Ann Neurol* 1979;6:349-54.
- Lenz HJ, Raedler A, Greten H, Vale WW, Rivier JE. Stress-induced gastrointestinal secretory and motor responses in rats are mediated by endogenous corticotropin-releasing factor. *Gastroenterology* 1988;95:1510-7.
- Taché Y, Martinez V, Million M, Wang L. Stress and the gastrointestinal tract III. Stress-related alterations of gut motor function: Role of brain corticotropin-releasing factor receptors. *Am J Physiol Gastrointest Liver Physiol* 2001;280:G173-7.
- Taché Y. Cyclic vomiting syndrome: The corticotropin-releasing-factor hypothesis. *Dig Dis Sci* 1999;44:79S-86.
- Boles RG, Powers AL, Adams K. Cyclic vomiting syndrome plus. *J Child Neurol* 2006;21:182-8.
- Akioka Y, Awaya Y, Ikenaka H, Fukuyama Y. Congenital multiple anomaly syndrome with recurrent vomiting accompanied with latent SIADH; a case report. *No To Hattatsu* 1994;26:44-9.
- Kakisaka Y, Wakusawa K, Sato I, Haginoya K, Uematsu M, Hirose M, *et al.* Successful treatment with sumatriptan in a case with cyclic vomiting syndrome combined with 18q-syndrome. *J Child Neurol* 2009;24:1561-3.
- Glare P, Miller J, Nikolova T, Tickoo R. Treating nausea and vomiting in palliative care: A review. *Clin Interv Aging* 2011;6:243-59.

How to cite this article: Topcu Y, Bayram E, Karaoglu P, Yis U, Kurul SH. The combination of thermal dysregulation and agenesis of corpus callosum: Shapiro's or/and reverse Shapiro's syndrome. *Ann Indian Acad Neurol* 2013;16:716-9.
Received: 08-10-12, **Revised:** 13-01-13, **Accepted:** 07-03-13

Source of Support: Nil, **Conflict of Interest:** Nil