

CASE REPORT

Nasal rhinosporidiosis masquerading as pyogenic granuloma in a pediatric patient at a Zonal Referral Hospital in Central Tanzania: Case report

Zephania Saitabau Abraham¹  | Francis Zerd² | Aveline Aloyce Kahinga³

¹Department of Surgery, University of Dodoma, School of Medicine and Dentistry, Dodoma, Tanzania

²Department of Anatomical Pathology, The Benjamin Mkapa Hospital, Dodoma, Tanzania

³Department of Otorhinolaryngology, Muhimbili University of Health and Allied Sciences, Dar es Salaam, Tanzania

Correspondence

Zephania Saitabau Abraham,
Department of Surgery, University of Dodoma, School of Medicine and Dentistry, Dodoma, Tanzania.
Email: zsaitabau@yahoo.com

Funding information

None

Abstract

Being rare, rhinosporidiosis is a chronic granulomatous disease that is characterized by polypoidal lesions of the mucous membrane and is caused by *Rhinosporidium seeberi*. The disease commonly affects the mucous membrane of the nasopharynx, conjunctiva, and palate and its very rare in our geographical location.

KEYWORDS

granulomatous, nasal mass, pediatric patient, rhinosporidiosis

1 | INTRODUCTION

Nasal rhinosporidiosis is a chronic granulomatous disease of the nose caused by *Rhinosporidium seeberi*.^{1–5} The disease predominantly affects the mucous membrane of the nose, nasopharynx, and conjunctiva. Rhinosporidiosis tends to occur in human beings and in animals and is more common in hot tropical climates though highly endemic in India and Sri Lanka.^{6–9} Sporadic pattern for the disease has been reported in other parts of the world such as Argentina, Brazil and Africa.⁹

In terms of race and sex predilection, there is no racial predominance and males are more affected than females, especially those aged 15–40 years with male to female ratio being 4:1.^{2,10,11} Rhinosporidiosis may be transmitted by direct contact with spores through dust, infected clothing, and swimming in stagnant water.^{7,8,12,13} However, the disease

remains to be very rare in our country; yet, there are some countries that have reported several cases including Nigeria.⁸ The diagnosis of nasal rhinosporidiosis is established by observing the characteristics of the causative organisms in nasal tissue biopsies like sporangia that may be at variable stages of maturation. Since it presents like a polypoidal mass in the nasal cavity, it mimics other diseases presenting with nasal masses;^{5,14–16} thus, a high index of suspicion by clinicians is of importance in the management of patients with nasal masses in the era of this emerging disease entity.

The usual clinical presentation for the disease include gradual nasal growth, nasal obstruction, occasional nasal bleeding, nasal itching and sneezing, and yellowish foul smelling nasal discharge associated with blood-stained purulent discharge.^{3,11}

The treatment of choice is surgical excision of the nasal mass though a high recurrence rate has been

This is an open access article under the terms of the [Creative Commons Attribution-NonCommercial-NoDerivs](https://creativecommons.org/licenses/by-nc-nd/4.0/) License, which permits use and distribution in any medium, provided the original work is properly cited, the use is non-commercial and no modifications or adaptations are made.

© 2022 The Authors. *Clinical Case Reports* published by John Wiley & Sons Ltd.

reported.^{4,5,15,16} It may lead to death in immunocompromised patients.¹⁷ To the best of our knowledge, this is the first reported case of nasal rhinosporidiosis in Central Tanzania and the 16th case countrywide.

We are therefore reporting a case of nasal rhinosporidiosis that was managed by endoscopic surgical excision of the nasal mass and kept on oral dapsone for 6 months postoperatively.

2 | CASE PRESENTATION

We are presenting an 11-year-old male boy who presented at our outpatient otorhinolaryngology clinic at a Zonal Referral Hospital in Central Tanzania with a 2-year history of right-sided nasal obstruction and intermittent epistaxis for 2 years. He had no history of cheek pain, numbness of the cheek, loss of teeth, loosening of teeth, or alveolar ridge fullness. No ophthalmological, otological, or neurological complaints were reported.

On physical examination, the patient was found to have a right-sided friable nasal mass filling the entire nasal cavity and had no external nose deformity. He was not pale and had no palpable peripheral lymph nodes. Ophthalmological, otological, and neurological evaluation revealed normal findings. Laboratory results showed hemoglobin 12 g/dL and elevated ESR (40 mm/hour). A provisional diagnosis of pyogenic granuloma was established, and the patient was sent for endoscopic surgical nasal mass excision under general anesthesia, and the excised specimen was sent for histopathology. Histopathological analysis revealed thick-walled sporangium containing numerous endospores (daughter spores; [Figure 1](#)) and with further sections showing thick-walled sporangium with endospores in different stages of development accompanied by mixed inflammatory cells mainly plasma cells and lymphocytes ([Figure 2](#)).

The patient was kept on oral dapsone 50 mg/day for 6 months and with no residual disease recurrence after 6 months of follow-up.

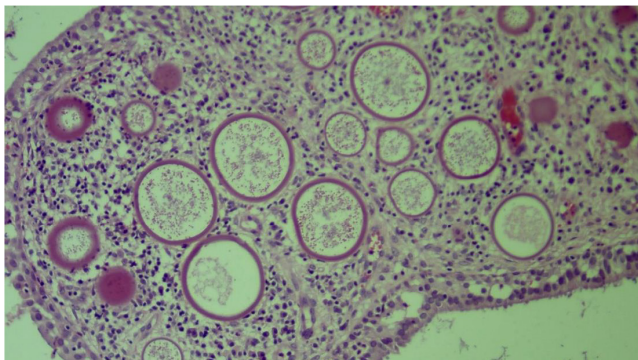


FIGURE 1 Intermediate power view of thick-walled sporangium containing numerous endospores (daughter spores)

3 | DISCUSSION

This case report documents a case of nasal rhinosporidiosis in a pediatric patient at a Zonal Referral Hospital in Central Tanzania and so far the first documented case in Central Tanzania and the 16th case countrywide. The disease has been reported from about 70 countries with diverse geographical features.⁷ The infrequently, isolated cases are reported in other parts of the world and are mainly due to migration.^{2,9}

The disease is more common in younger age groups from the available literatures and being more common in men than women with male to female ratio being 4:1.^{2,10,11} These observations appear similar to what has been observed in our case report where the affected patient was an 11-year-old male child.

Rhinosporidiosis and its causative organism *Rhinosporidium seeberi* have been known for over 100 years, and it is a rare infective chronic granulomatous disease that remains to be endemic in some part of Asia (India), although sporadic cases have been reported in America, Europe, and Africa.^{4,5,14–16}

To date, the causative organism has never been isolated in vitro, and its taxonomic position is unclear.¹⁸

In contrast to more recent fungal infections, some aspects of the taxonomy, morphology, ontogenesis, and epidemiology of those caused by *Rhinosporidium seeberi* remain controversial and have not been resolved. Though now related to a group of fish parasites referred to as the DRIP clade, most pathologists and microbiologists initially considered it to be fungus on the basis of its property to be stained by fungal stains such as Gomori methenamine silver (GMS) and periodic acid-Schiff (PAS).^{19,20}

Available literatures indicated that a combination of host specificities and resistance of *Rhinosporidium* to grow in culture may account for the failure to produce experimental rhinosporidiosis.²⁰ Some authors proposed the class of *Rhinosporidium seeberi* to be Mesomycetozoa.^{13,19,20} Fluorescent in-situ hybridization techniques provide evidence that the natural habitats for *Rhinosporidium seeberi* are water reservoirs and perhaps soil contaminated by waste. In addition, other aquatic microorganisms might be relevant to a possible synergistic action in the establishment of natural rhinosporidiosis.²⁰

The class Mesomycetozoa has two orders, which are the Dermocystida and the Ichthyophonida. In the order, Dermocystida is the family Rhinosporideaceae that includes *Rhinosporidium seeberi*, *Dermocystidium* spp., and the rosette agent.²⁰

The route of transmission for *Rhinosporidium* remains to be unclear even though the presumed mode of infection from the natural aquatic habitat of *Rhinosporidium seeberi* is through a traumatized epithelium commonly

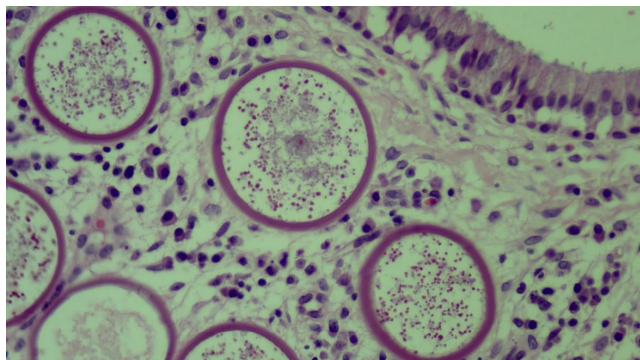


FIGURE 2 A high-power view of large, thick-walled sporangium with endospores in different stages of development accompanied by mixed inflammatory cells mainly plasma cells and lymphocytes

called trans epithelial infection and this is most common in nasal sites. For *Rhinosporidium seeberi*, various modes of spread have been documented including auto-inoculation through spillage of endospores from polyps after trauma or surgery, hematogenous spread to distant sites, lymphatic spread, and sexual transmission.^{3,20} Rhinosporidiosis is prevalent in rural settings, particularly among people working or in contact with contaminated soil, stagnant water (ponds or lakes), or sand.²⁰ In our case report, the patient gave a history of contact with contaminated pond water and was residing in a rural area. Similarly, the patient reported a history of contact with feces of infected livestock and used to work in contaminated agricultural fields. Such risk factors have been reported in the available literatures.^{19,20}

Interestingly about the incidence of rhinosporidiosis is that while several 100 people bathe in stagnant water, only few develop a progressive pattern of the disease. This might indicate the existence of predisposing factors in the host where the possibility of nonspecific immune reactivity in the host, blood group, and HLA types has been suggested as important in the pathogenesis of *Rhinosporidium seeberi* and also in the establishment of an initial focus of infection.^{19,20}

Since rhinosporidiosis has an indolent course, lesions may be present for many years before patients become symptomatic^{7,19,20} and this appears similar to what was seen in our patient who reported a history of nasal obstruction and intermittent epistaxis for 2 years.

Rhinosporidiosis manifests as tumor-like masses, usually of the nasal mucosa or conjunctivae of humans and animals, and patients with nasal involvement often have masses leading to nasal obstruction or bleeding due to polyp formation, and it can spread to the nasopharynx, oropharynx, and the maxillary antrum.^{1,3,19,20} The patient we are hereby reporting had an isolated friable mass localized in the nasal cavity with no involvement of other anatomical

sites such as maxillary sinus. The diagnosis is established by observing the characteristic appearance of the organism in tissue biopsies and computerized tomography (CT) scans. The lesion is friable, vascular pedunculated, or sessile polyp with a surface studded with tiny white dots due to spores beneath the epithelium, giving a “strawberry-like” appearance. The lesion in our case report was friable evidenced by nasal bleeding upon probing.¹⁹

Systemic disease is rare and can include multiple mucocutaneous, hepatic, renal, pulmonary, splenic, or bone lesions associated with fever, wasting, and even death.^{19,20}

Though rare, spontaneous regression of rhinosporidial growths has been noted in animals and in humans, and therefore, medical and/or surgical intervention is necessary.^{19,20} Wide local surgical excision of the rhinosporidial growth is the treatment of choice to reduce the risk of recurrence, although this may be associated with significant morbidity due to hemorrhage and septal perforation.^{5,16} Therefore, limited surgical excision and adjuvant medical therapies, including antifungals such as griseofulvin and amphotericin B, trimethoprim-sulfadiazine, and sodium stibogluconate, have been tried with varied success. All drugs were endospore-static rather than endosporicidal. The strains obtained from human and animal rhinosporidiosis have shown genetic variations that might explain the variation of responses to some drugs though data on antimicrobial drug resistance in *Rhinosporidium seeberi* is lacking.^{19,20} The only drug appearing to have clinical promise is dapsone since it arrests the maturation of sporangia and promotes fibrosis in the stroma when used as an adjunct to surgery.²¹ It could therefore be expected that presurgical dapsone would minimize both hemorrhage by promotion of fibrosis as well as preventing the colonization and infection of new sites after the release of endospores from the surgically traumatized polyps.^{22,23} Laser excision promises to be the mainstream treatment of sinonasal rhinosporidiosis in the future.²⁴ Our patient was kept on dapsone for 6 months after endoscopic nasal mass excision with no recurrence after 6 months of follow-up.

4 | CONCLUSION

In Tanzania, rhinosporidiosis is nonendemic, and in the Central zone, the disease is uncommon thus may pose diagnostic challenges. It is therefore prudent for both clinicians and pathologists to have a high index of suspicion when managing patients with nasal masses even from nonendemic areas. Moreover, it will be very crucial to make a follow up in the next few years particularly the clinical course of these patients to exclude the possibility of recurrence of the rhinosporidial growths after an extended period of time to evaluate its best treatment modality.

AUTHOR CONTRIBUTIONS

ZSA performed the surgery, collected information for the case, and drafted the initial version of the manuscript. FZ performed histopathology and also provided critical feedback of the manuscript. AAK drafted the initial version of the manuscript. All authors read and approved the final version to be published in Clinical Case Reports.

ACKNOWLEDGMENT

The patients' mother is highly acknowledged for providing a written informed consent to publish the case report. Dr. Mary Jue Xu from the Department of Surgical Oncology, University of California San Francisco, USA, is also acknowledged for technically reviewing the manuscripts' grammar.

CONFLICT OF INTEREST

None declared.

DATA AVAILABILITY STATEMENT

The data that support the findings of this report are available from the corresponding author upon reasonable request.


ETHICAL APPROVAL

This report is in accordance with the Declaration of Helsinki.

CONSENT

The patients' mother gave a written informed consent prior inclusion of the child in this report.

ORCID

Zephania Saitabau Abraham  <https://orcid.org/0000-0002-7738-9902>

REFERENCES

- Chandran A, Sakthivel P, Kumar R, Rajeshwari M. Pharyngeal rhinosporidiosis. *BMJ Case Reports*. 2020;13:6.
- Ali GM, Goravey W, Al Hyassat SA, Petkar M, Al Maslamani MA, Hadi HA. Recurrent nasopharyngeal rhinosporidiosis: case report from Qatar and review of the literature. *IDCases*. 2020;21:e00901.
- Masilela MM, Selepe MS. Nasal rhinosporidiosis in South Africa: review of literature and report of a case. *S Afr Dent J*. 2017;72(9):420-423.
- Kindo AJ, Kalyani J, Sundaram S, Kannan S, Kumar AR. Unusual presentation of rhinosporidiosis: a case report. *Sri Ramchandra J Med*. 2007;1(2):60-61.
- Echejoh GO, Manasseh AN, Tanko MN, et al. Nasal rhinosporidiosis. *J Natl Med Assoc*. 2008;100(6):713-715.
- Nath D, Khan SA, Sahaya R, Umuro P. Recurrent nasal rhinosporidiosis: a case report. *Era's J Med Res*. 2019;6(1):118-120.
- Arias AF, Romero SD, Garcés CG. Case report: rhinosporidiosis literature review. *Am J Trop Med Hyg*. 2021;104(2):708-711.
- Aliyu D, Sahabi SM. Nasal rhinosporidiosis in a Nigerian child: a rare clinical entity. *Int J Otolaryngol Head Neck Surg*. 2014;03:51-53.
- Morelli L, Polce M, Pisciole F, et al. Human nasal rhinosporidiosis: an Italian case report. *Diagn Pathol*. 2006;1(1):1-4.
- Gupta N, Singla P, Pradhan B, Gurung U. Lacrimal sac rhinosporidiosis: case report and review of literature with a new grading system to optimize treatment. *Saudi J Ophthalmol*. 2019;33(3):283-290.
- Saha S, Hoogar MB, Borkar DB, Dhar R, Naik V. Rhinosporidiosis of nose: unusual presentation masquerading as pyogenic granuloma. *Int J Res Rev*. 2017;4(1):60-63.
- Dey AK, Sharma R, Mittal K, et al. Rhinosporidiosis: a rare cause of proptosis and an imaging dilemma for sinonasal masses. *Case Reports Otolaryngol*. 2016;2016:3573512.
- Singh I, Lalrinmawii PD. Recurrent rhinosporidiosis: a case report. *J Otolaryngol ENT Res*. 2018;10(6):298-300.
- Ahluwalia KB, Maheshwari N, Deka RC. Rhinosporidiosis: a study that resolves etiologic controversies. *Am J Rhinol*. 1997;11(6):479-484.
- Rao BS, Shanthi V, Rao NM, Grandhi B, Muramreddy V, Raguraman S. Nasal polyposis associated with rhinosporidiosis in an 11 year old boy—a rare case report. *Int J Res Rev*. 2019;6(May):18-20.
- Sefu U, Fauzia A. Human nasal rhinosporidiosis: a case report from Malawi. *Pan African Med J*. 2011;9(1):27.
- Crosara PF, Becker CG, Freitas VA, Nunes FB, Becker HM, Guimarães RE. Nasal rhinosporidiosis: differential diagnosis of fungal sinusitis and inverted papilloma. *Int Arch Otolaryngol*. 2009;13(1):93-95.
- Hussein MR, Rashad UM. Rhinosporidiosis in Egypt: a case report and review of literature. *Mycopathologia*. 2005;159(2):205-207.
- Attri N, Solanki M, Kanojiya S. Nasal rhinosporidiosis. *J Med Sci Clin Res*. 2019;7(3):129-134.
- Das S, Kashyap B, Barua M, et al. Nasal rhinosporidiosis in humans: new interpretations and a review of the literature of this enigmatic disease. *Med Mycol*. 2011;49(3):311-315.
- Venkateswaran S, Date A, Job A, Mathan M. Light and electron microscopic findings in rhinosporidiosis after dapsone therapy. *Trop Med Int Health*. 1997;2(12):1128-1132.
- Arseculeratne SN. Recent advances in rhinosporidiosis and *Rhinosporidium seeberi*. *Indian J Med Microbiol*. 2002;20(3):119-131.
- Arseculeratne SN. Chemotherapy of rhinosporidiosis: a review. *J Infect Dis Antimicrobial Agents*. 2009;26(1):21-27.
- Chao SS, Loh KS. Rhinosporidiosis: an unusual cause of nasal masses gains prominence. *Singapore Med J*. 2004;45:224-226.

How to cite this article: Abraham ZS, Zerd F, Kahinga AA. Nasal rhinosporidiosis masquerading as pyogenic granuloma in a pediatric patient at a Zonal Referral Hospital in Central Tanzania: Case report. *Clin Case Rep*. 2022;10:e05977. doi: [10.1002/ccr3.5977](https://doi.org/10.1002/ccr3.5977)