



Review Article

Instrumentation following intradural tumor resection: A case analyses and literature review

Brandon Michael Wilkinson, Michael Galgano

Department of Neurosurgery, SUNY Upstate Medical University, Syracuse, New York, United States.

E-mail: *Brandon Michael Wilkinson - wilkinsb@upstate.edu; Michael Galgano - galganom@upstate.edu



***Corresponding author:**

Brandon Michael Wilkinson,
Neurosurgery, SUNY Upstate
Medical University, 750 East
Adams St, Syracuse - 13210,
New York, United States.

wilkinsb@upstate.edu

Received : 11 March 2020

Accepted : 07 May 2020

Published : 30 May 2020

DOI

10.25259/SNI_96_2020

Quick Response Code:



ABSTRACT

Background: Resection of intradural spinal tumors typically utilizes a posterior approach and often contributes to significant biomechanical instability and sagittal deformity.

Methods: We searched PubMed for studies regarding pre- and postoperative spine biomechanics/alignment in patients with intradural tumors undergoing posterior decompressions.

Results: Three patients underwent posterior decompressions with instrumented fusions to preserve good sagittal alignment postoperatively. Variables analyzed in this study included the extent of preoperative and postoperative deformity, the number of surgical levels decompressed and fused, the different frequencies of instability following the resection of cervical versus thoracic versus lumbar lesions, and whether pediatric patients were most likely to develop instability.

Conclusion: Simultaneously performing instrumented fusions following posterior spinal decompressions for tumor removal proved optimal in preventing postoperative spinal deformity. Further, "open" surgical procedures offered more optimal/definitive tumor removal versus minimally invasive approaches, and the greater operative exposure and resultant increased risk for instability were remediated by performing simultaneous fusion.

Keywords: Instrumentation, Intradural, Spine, Tumor

INTRODUCTION

Approximately 45% of spinal canal tumors are intradural; roughly 40% are extramedullary and 5% are intramedullary in location.^[9] Typically, they are resected utilizing a posterior approach, which may destabilize the spine warranting simultaneous fusion.

After the resection of intradural tumors, the cervical spine appears to be more vulnerable to instability than the thoracic or lumbar spine (e.g. risk of post laminectomy kyphosis).^[3] As the width of laminectomy increases, the risk of postoperative biomechanical stability increases.^[2,8] The pediatric population is especially susceptible to such postoperative spinal deformity.

CASE PRESENTATIONS

Case presentation #1

A 37-year-old female presented with 1 year of neck pain and bilateral upper extremity radiculopathy. An MRI revealed an intramedullary lesion extending from C2 to C6 with associated syrinx [Figure 1

This is an open-access article distributed under the terms of the Creative Commons Attribution-Non Commercial-Share Alike 4.0 License, which allows others to remix, tweak, and build upon the work non-commercially, as long as the author is credited and the new creations are licensed under the identical terms.

©2020 Published by Scientific Scholar on behalf of Surgical Neurology International

and Table 1]. She underwent C2–C7 laminectomy with lateral mass instrumented fusion. Pathology revealed ependymoma. Postoperatively, her strength was preserved, and upright X-rays showed good instrumentation placement [Figure 2].

Case presentation #2

A 75-year-old female presented with several weeks of paresis and urinary incontinence. The MRI revealed five intradural tumors between T10 and T12 [Figure 3]. She underwent a laminectomy of T10–12 with intradural resection of the tumors, followed by a pedicle screw instrumented fusion from T9 to L1. Upright X-rays [Figure 4] postoperatively showed good hardware placement, and her lower extremity weakness gradually improved, allowing her to be discharged to an inpatient rehabilitation facility on the 10th postoperative day.

Case presentation #3

A 52-year-old male presented with a 1-year history of back pain radiating to the posterior thighs and feet. The MRI revealed an intradural extramedullary lesion at the L4 level

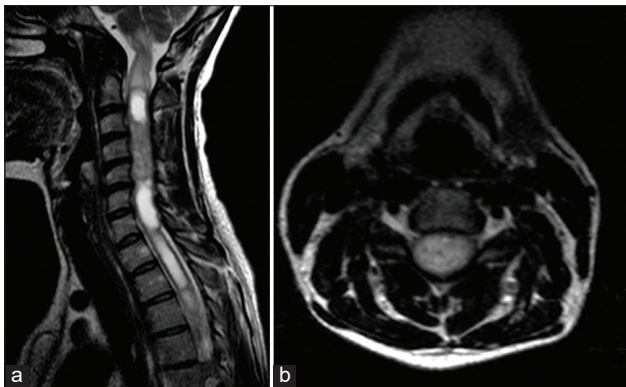


Figure 1: (a) Sagittal T2-weighted MRI showing an intradural, intramedullary lesion extending from C2 to C6 with an associated syrinx. (b) Axial T2-weighted MRI at the level of C4 showing the expansion of the spinal cord.

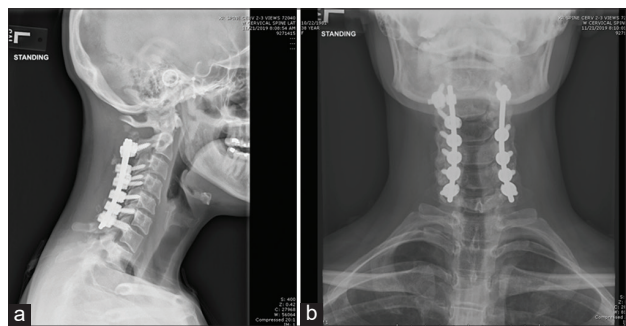


Figure 2: (a) Upright lateral cervical spine X-ray showing preserved sagittal balance. (b) AP cervical spine X-ray showing good hardware placement. The left C3 screw was removed intraoperatively due to poor purchase.

[Figure 5]. He underwent an L3–4 laminectomy, left L4–5 facetectomy, and L4–5 instrumented fusion with pedicle screws/rods. The pathology revealed a schwannoma, the WHO Grade I. Postoperatively, upright X-rays showed the good placement of hardware [Figure 6]. He did develop a wound dehiscence 2 months postoperatively that was successfully treated with oversewing and antibiotics.

DISCUSSION

When resection of intradural spinal tumors necessitates the significant disruption of posterior column elements, patients may require simultaneous fusion to avoid instability. The cervical spine appears most vulnerable followed by the thoracic and then lumbar spine.^[4]

Preoperative cervical kyphosis increases the risk that after cervical tumor resection, a cervical fusion will be warranted. Fusion should also be considered when C2 posterior elements are disrupted, as this leads to further instability.^[6] Knafo *et al.* demonstrated that patients undergoing laminectomy or laminoplasty at 4 or more levels, or those at the thoracolumbar junction, especially in patients <30 years of age, are at increased risk of postoperative sagittal

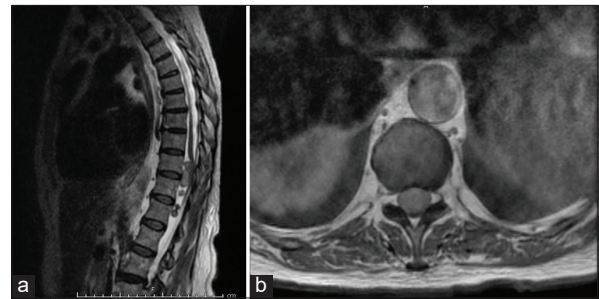


Figure 3: (a) Sagittal T2 MRI of the thoracic spine showing five intradural extramedullary masses at the levels of T10–T12. (b) Axial T1 MRI with contrast showing a uniformly enhancing circumscribed lesion at the level of T10, causing severe mass effect on the spinal cord with near-complete flattening.

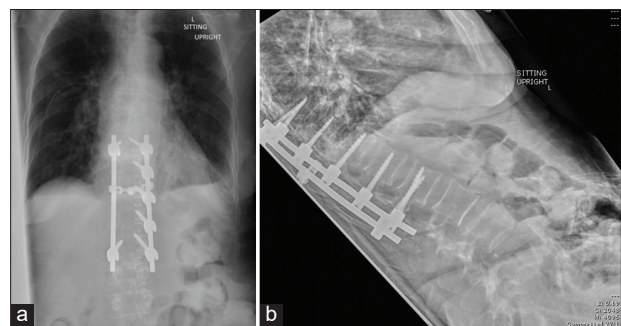


Figure 4: (a) Postoperative upright thoracic spine AP X-ray showing good hardware construct utilizing five screws on the left and two screws on the right. (b) Lateral plain film showing good sagittal alignment and disc spacing.

Table 1: Summary of instrumentation cases and outcomes.

Surgical location	Age (years)	Preoperative alignment	Levels of levels decompressed	Number of levels fused	Postoperative alignment
Cervical spine	37	Loss of lordosis	6	6	Preserved
Thoracic spine	75	Kyphotic	3	5	Preserved
Lumbar spine	52	Loss of lordosis	2	2	Preserved

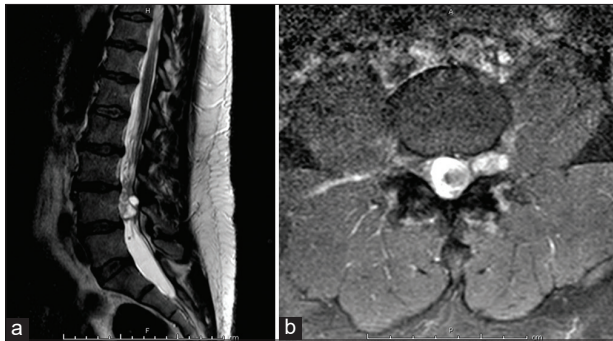


Figure 5: (a) Lumbar sagittal T2 MRI showing an intradural extramedullary lesion at the level of L4. (b) Lumbar axial T1 MRI with contrast at the level of the L4-5 intervertebral disc showing a mixed enhancing lesion extending into the left L4-5 neural foramina.

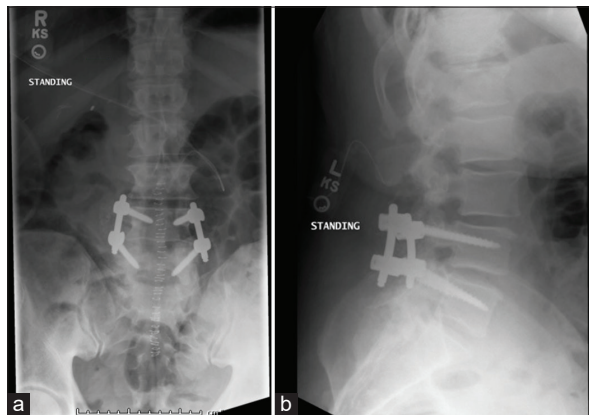


Figure 6: (a) Standing lumbar spine AP X-ray showing good hardware placement. (b) Lateral standing plain film showing preserved sagittal alignment.

deformity.^[7] The rates of postoperative deformity appear to be similar for laminectomy and laminoplasty.^[5]

Removal of one-third to half of a facet joint complex, especially in the lumbar spine, does not cause significant instability.^[1] When gaining lateral access to the dura, however, with multilevel facetectomies and pediculotomies, the need for fusion is increased.

In our series of cases, “open” surgical approaches offered more optimal tumor removal versus minimally invasive techniques. The increased instability associated with posterior column disruption was mitigated by performing

simultaneous instrumented fusions with successful prevention of postoperative spinal deformity.

CONCLUSION

Cervical spine location, pre-operative kyphosis, patient age, and number of levels decompressed appear to be the most significant risk factors for developing post-operative instability. Concomitant instrumented fusion following posterior spinal decompression for intradural tumor removal allows for maximal resection while preventing post-operative spinal deformity.

Declaration of patient consent

Patient’s consent not required as patients identity is not disclosed or compromised.

Financial support and sponsorship

Nil.

Conflicts of interest

There are no conflicts of interest.

REFERENCES

- Ahmad FU, Frenkel MB, Levi AD. Spinal stability after resection of nerve sheath tumors. *J Neurosurg Sci* 2017;61:355-64.
- Allen BL Jr., Ferguson RL. The Galveston experience with L-rod instrumentation for adolescent idiopathic scoliosis. *Clin Orthop Relat Res* 1988;229:59-69.
- Benzel EC. The essentials of spine biomechanics for the general neurosurgeon. *Clin Neurosurg* 2003;50:86-177.
- Guan Y, Yoganandan N, Pintar FA, Maiman DJ. Effects of total facetectomy on the stability of lumbosacral spine. *Biomed Sci Instrum* 2007;43:81-5.
- Hersh DS, Iyer RR, Garzon-Muvdi T, Liu A, Jallo GI, Groves ML. Instrumented fusion for spinal deformity after laminectomy or laminoplasty for resection of intramedullary spinal cord tumors in pediatric patients. *Neurosurg Focus* 2017;43:E12.
- Katsumi Y, Honma T, Nakamura T. Analysis of cervical instability resulting from laminectomies for removal of spinal cord tumor. *Spine (Phila Pa 1976)* 1989;14:1171-6.
- Knafo S, Court C, Parker F. Predicting sagittal deformity after surgery for intramedullary tumors. *J Neurosurg Spine* 2014;21:342-7.
- Raynor RB, Pugh J, Shapiro I. Cervical facetectomy and its

- effect on spine strength. *J Neurosurg* 1985;63:278-82.
9. Van Goethem JW, van den Hauwe L, Ozsarlak O, De Schepper AM, Parizel PM. Spinal tumors. *Eur J Radiol* 2004;50:159-76.

How to cite this article: Wilkinson BM, Galgano M. Instrumentation following intradural tumor resection: A case analyses and literature review. *Surg Neurol Int* 2020;11:131.