

## Comparison of Accuracy of Uncorrected and Corrected Sagittal Tomography in Detection of Mandibular Condyle Erosions: an Exvivo Study

Asieh Zamani Naser<sup>1</sup>, Amir Mansour Shirani<sup>2</sup>, Ehsan Hekmatian<sup>3</sup>, Ali Valiani<sup>4</sup>, Pegah Ardestani<sup>5</sup>, Ava Vali<sup>5</sup>

### ABSTRACT

**Background:** Radiographic examination of TMJ is indicated when there are clinical signs of pathological conditions, mainly bone changes that may influence the diagnosis and treatment planning. The purpose of this study was to evaluate and to compare the validity and diagnostic accuracy of uncorrected and corrected sagittal tomographic images in the detection of simulated mandibular condyle erosions.

**Methods:** Simulated lesions were created in 10 dry mandibles using a dental round bur. Using uncorrected and corrected sagittal tomography techniques, mandibular condyles were imaged by a Cranex Tome X-ray unit before and after creating the lesions. The uncorrected and corrected tomography images were examined by two independent observers for absence or presence of a lesion. The accuracy for detecting mandibular condyle lesions was expressed as sensitivity, specificity, and validity values. Differences between the two radiographic modalities were tested by Wilcoxon for paired data tests. Inter-observer agreement was determined by Cohen's Kappa.

**Results:** The sensitivity, specificity and validity were 45%, 85% and 30% in uncorrected sagittal tomographic images, respectively, and 70%, 92.5% and 60% in corrected sagittal tomographic images, respectively. There was a significant statistical difference between the accuracy of uncorrected and corrected sagittal tomography in detection of mandibular condyle erosions ( $P = 0.016$ ). The inter-observer agreement was slight for uncorrected sagittal tomography and moderate for corrected sagittal tomography.

**Conclusion:** The accuracy of corrected sagittal tomography is significantly higher than that of uncorrected sagittal tomography. Therefore, corrected sagittal tomography seems to be a better modality in detection of mandibular condyle erosions.

**Keywords:** Tomography, Tooth erosion, Mandibular condyle.

**Received:** November 2010

**Accepted:** March 2010

Dent Res J 2010; 7(2): 76-81

### Introduction

Erosions represent the early stages of degenerative changes indicating that the temporomandibular joint (TMJ) is unstable and alteration of bony joint surface is occurring leading to changes in occlu-

sion.<sup>1</sup> Population studies have estimated that 28 to 86% of adults experience occasional TMJ symptoms and 5% of these adults have symptoms severe enough to warrant seeking treatment.<sup>2</sup> The treat-

\* This paper derived from a doctoral thesis in Isfahan University of Medical Sciences.

<sup>1</sup> Associate Professor, Department of Oral and Maxillofacial Radiology and Torabinejad Dental Research Center, School of Dentistry, Isfahan University of Medical Sciences, Isfahan, Iran.

<sup>2</sup> Assistant Professor, Department of Oral Medicine and Torabinejad Dental Research Center, School of Dentistry, Isfahan University of Medical Sciences, Isfahan, Iran.

<sup>3</sup> Assistant Professor, Department of Oral and Maxillofacial Radiology and Torabinejad Dental Research Center, School of Dentistry, Isfahan University of Medical Sciences, Isfahan, Iran.

<sup>4</sup> Assistant Professor, Department of Anatomy, Isfahan University of Medical Sciences, Isfahan, Iran.

<sup>5</sup> Dental Student, School of Dentistry, Isfahan University of Medical Sciences, Isfahan, Iran.

Correspondence to: Asieh Zamani Naser, Email: zamaniNaser@dnt.nui.ac.ir

ment need for temporomandibular disorder in the general adult population is substantial and varies according to definition, criteria, and age.<sup>3</sup> Staging osseous changes associated with osteoarthritis (degenerative joint disease) of the TMJ is potentially useful in diagnosis of disease progression.<sup>4</sup> The goal of radiographic examination is obtaining the necessary diagnostic information without unnecessary patient expense or radiation exposure. The most appropriate imaging procedures are those that provide new information that will influence patient care. Selection of an examination is influenced by many, sometimes competing factors. The decision should be made after considering the history and clinical findings, clinical diagnosis, cost of examination, amount of radiation exposures and results of prior examination, as well as treatment planning and expected outcome. A variety of diseases affect the TMJ.<sup>5</sup> Diagnosis of these conditions frequently cannot be made with clinical examination alone.<sup>6,7</sup> Two radiographic hallmarks of different stages of degenerative joint disease (DJD) are articular surface erosions and osteophytes.<sup>4</sup> Many diagnostic imaging techniques have been proposed to image osteophytes and erosions. However, there does not seem to be a general consensus as to which diagnostic imaging technique should be the "gold standard" in detecting these lesions in the TMJ.<sup>1</sup> Some reports favor the use of axially corrected sagittal tomography while others favor the use of CT.<sup>1</sup> It is taken into account that magnetic resonance imaging (MRI) is an imperfect standard for diagnosing osteoarthritis.<sup>8</sup> There has been no single technique that provides accurate imaging of all anatomical aspects of TMJ complex.<sup>9</sup> Tomography is a radiographic technique that produces multiple thin image slices, permitting visualization of the osseous structures essentially free of superimpositions of overlapping structures. Corrected tomography technique can provide multiple image slices at right angle through joint, depicting true condylar position and revealing osseous changes.<sup>10</sup> The lateral tomographic images provide the best view of the cortical outline of the mandibular condyle and fossa, as well as the position of the condyle within the fossa and its range of translatory motion.<sup>11,12</sup> Some reports favor the use of axially corrected sagittal tomography for detection of mandibular condyle erosions.<sup>13,14</sup>

The aim of this study was to determine the accuracy of corrected sagittal tomography in com-

parison with uncorrected sagittal tomography in the detection of mandibular condyle erosions because corrected sagittal tomography is not prescribed for detection of mandibular condyle erosions routinely.

## Materials and Methods

In this experimental Ex-vivo study, ten dried human mandibles with normal condyles that had no erosive lesions on their surfaces and with normal morphology were chosen by simple sampling from Anatomy Department of Isfahan University of Medical Sciences. The study was done during the years 2008-2009 in Department of oral Radiology, School of Dentistry, Isfahan University of Medical Sciences and Torabinejad Dental Research Center. For taking radiographs, Cranex Tome x-ray unit (Soredex, Finland), operating at 57 KVP, 8 mA, 24 seconds for dry mandible and Green Sensitized extra-oral films (PriMAX RTG-G Germany), and medium extra-oral imaging screen (Kodak Lanex USA) were used. Tomograms were developed with an automatic processor (Protec, Optimax) using fresh developer and fixer solutions (Champion, England). Dental impression material was used to fix the mandible so that its occlusal surface was down by 10 degrees (TMJ program for cranex tome). Repositioning of mandible after each manipulation was possible in sequentially produced tomography by putting a sign by a marker on the mandible at the position of focal trough and horizontal light beams when first tomography was done. Then, from each intact mandibular condyle an uncorrected and a corrected sagittal tomogram were provided. For taking tomograms, we followed the manufacturer recommendation so that an inter-joint distance (IJD) scout film was taken using the orientation program of cranex tome X-ray unit. It is used to determine the distance between the condyles by taking posterior-anterior view of both condyles. Then, IJD was measured and recorded. The layer thickness was also determined according to the shape and size of condylar head on IJD Image. Then, uncorrected sagittal tomogram of each condyle was provided using the recorded IJD and layer thickness. A number was given to each tomogram. Type of the technique and whether it was taken from the right or the left condyle were recorded on a list in front of the tomogram number. For corrected sagittal tomography, an angle scout film of each condyle was taken with orientation program of

unit. This program provides four lateral exposure of the condyle at the same centrally located position, each at a different angle in one tomogram (60°, 65°, 70°, and 75°). We selected the desired angle that best demonstrated the structural position and this angle was used for additional corrected tomogram program. Using the IJD and suitable angle for corrected sagittal program, the corrected image was provided for each condyle and a number was given to each tomogram and the data was recorded. Then, by a high speed round bur (Jota AG Rotary instruments, Rutni, Switzerland) of 2 mm diameter, we removed the cortical surface of condyle and made a lesion with the same diameter at the center of superior aspect of each condylar head. With repositioning of each mandible at their previous position, uncorrected and corrected sagittal tomograms of each condyle with simulated erosive lesions were provided and the information was recorded in a list. Eventually, 20 uncorrected and 20 corrected sagittal tomograms were provided before a simulated lesion was made and 20 uncorrected and 20 corrected sagittal tomograms were provided after creation of simulated erosive lesion. Two oral specialists (one oral radiologist and one oral medicine specialist) with more than ten years of experience including TMJ imaging evaluation evaluated all Images. Each observer was asked to record the presence or absence of erosion on the randomized order of these four series of tomograms on an answer sheet. The data based on the gold standards were inserted in SPSS. Sensitivity (the percent of true positive) and specificity (the percent of true negative) of each technique were determined for each examiner. Validity (sensitivity+specificity-100)<sup>15</sup> was also determined. Wilcoxon paired test was applied to determine accuracy of the two techniques. Cohen's kappa was used to determine the inter-observer agreement.

Kappa statistics are commonly interpreted as 0 for poor agreement, 0 to 0.20 for slight agreement, 0.21 to 0.40 for fair agreement, 0.41 to 0.60 for moderate agreement, 0.61 to 0.80 for substantial agreement and 0.81 to 1 for almost perfect agreement.<sup>16</sup> A difference of  $\alpha = 0.05$  was considered to be significant.

## Results

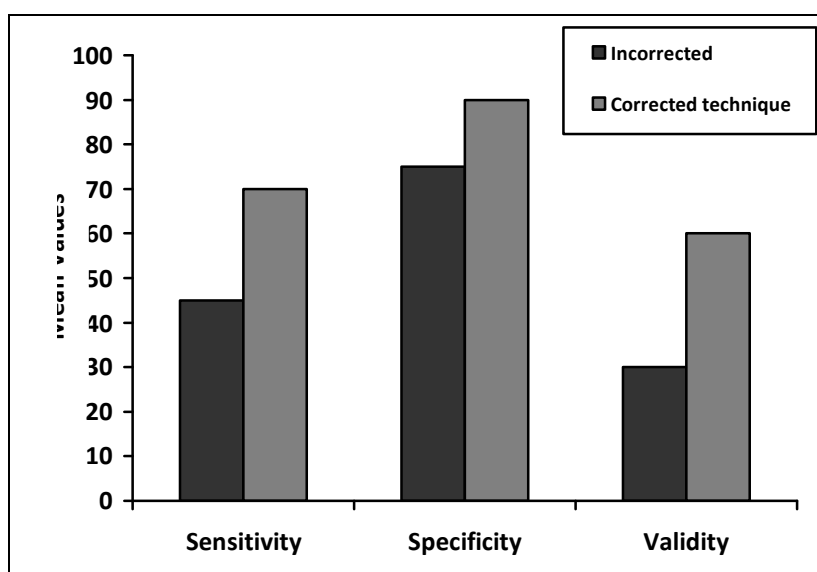
The data from the analyses of images are shown in Table 1. Sensitivity and specificity of the two techniques are shown in Table 2. The results of validity test represented by Youden's J index were 65% and 60% for the first and the second examiners, respectively for corrected sagittal tomography technique. Validity was 15% and 45% for the first and the second examiners, respectively, in uncorrected sagittal tomography technique. The mean values of sensitivity, specificity, and validity are shown in Figure 1. For both examiners, the mean sensitivity was 45% and the mean specificity was 85% and the mean validity was 30% in uncorrected sagittal tomographic images. The mean sensitivity was 70% and the mean specificity was 92.5% and the mean validity was 62.5% in corrected sagittal tomographic images. The Wilcoxon test showed a statistically significant difference between the uncorrected and the corrected sagittal tomography ( $P=0.016$ ). Mean validity was compared using proportion test; it showed significant difference ( $P<0.01$ ) between the two techniques. Kappa values for inter-observer agreement for the detection of mandibular condyle erosions are 0.05 for uncorrected sagittal tomography technique and 0.529 for corrected sagittal tomography technique. These values show slight agreement for uncorrected sagittal tomography technique and moderate agreement for corrected sagittal tomography technique between the two examiners.

**Table 1.** Distribution of results (absolute values) of uncorrected and corrected sagittal tomography

Accuracy	Uncorrected Tomography Examiner 1	Uncorrected Tomography Examiner 2	Corrected Tomography Examiner 1	Corrected Tomography Examiner 2	Gold Standard
True positive	8	10	15	13	20
False negative	12	10	5	7	—
True negative	15	19	18	19	20
False positive	5	1	2	1	—

**Table 2.** Sensitivity, specificity and validity of uncorrected and corrected sagittal tomography in the identification of mandibular condyle erosions

Accuracy	uncorrected Tomography Examiner 1	uncorrected Tomography Examiner 2	Corrected Tomography Examiner 1	Corrected Tomography Examiner 2
Sensitivity	40%	50%	75%	65%
Specificity	75%	95%	90%	95%
Validity	15%	45%	65%	60%

**Figure 1.** Mean sensitivity, specificity, validity of uncorrected and corrected sagittal tomography for the detection of mandibular condyle erosions.

## Discussion

During our research, there were not enough skulls available at Anatomy Department so we used mandibles as sample. Tomography is a radiographic technique that produces multiple thin image slices, permitting visualization of the osseous structures essentially free of super-impositions of overlapping structures and we wanted to evaluate erosive lesion on condyle not other components of joint. Because we did not use any soft tissue equivalent in this study, radiographic detail and contrast was increased compared to those images when soft tissue filters were used.<sup>17</sup> Also, using a bur for making lesions produces more well-defined border compared to those in clinical situation in which the lesions are more diffuse.<sup>17</sup> To eliminate the effect of lesions' size on proper assessment of erosive lesion of condyle,<sup>18</sup> we made all lesions using the same bur and the lesions were made at the center

of superior aspect of condyles, where most erosive lesions are located.<sup>19</sup> As shown in the tables, the accuracy of uncorrected and corrected sagittal tomograms in the detection of mandibular condyle erosions showed significant statistical difference in this study. Wilcoxon test for the paired data showed significant difference between the accuracy of the two techniques. At last, the agreement between the two examiners was determined using Cohen's kappa which showed moderate difference between the two examiners for interpretation of corrected sagittal tomograms and slight agreement for interpretation of uncorrected sagittal tomograms. Rohlin et al.<sup>19</sup> evaluated the ability of axially corrected sagittal tomography to detect macroscopic changes. They specifically observed the axially corrected sagittal tomograms and axially corrected frontal tomograms. Their study showed that the majority of findings were obtained by axially corrected sagittal tomography.

Tanimoto et al.<sup>20</sup> also reported that axially corrected frontal tomography added no further information to the axially corrected sagittal tomography. Cholitgul et al.<sup>13</sup> evaluated axially corrected sagittal tomography (ACST) in detecting lesions of the TMJ using 30 autopsy specimens. Sensitivity and specificity was 67% and 93%, respectively, which was in agreement with our data that showed a sensitivity of 70% and a specificity of 92%. Flygare et al.<sup>14</sup> determined the diagnostic values of ACST to detect erosive changes in 39 TMJ autopsy specimens. The sensitivity of detecting erosions of the condyles was 58% and the specificity was 98%, which is in agreement with our results. Only sensitivity (70%) was higher in our study. Flygare et al. also reported that the presence of erosions is underestimated by the radiological findings, which was also accepted in our study. Ludlow et al.<sup>21</sup> described the diagnostic accuracy of axially corrected sagittal tomography and panoramic images for detection of osteophytic lesions in the TMJ. They found high accuracy for axially corrected sagittal tomography in diagnosing osteophytes and erosions. In this study, we found high accuracy for axially corrected sagittal tomography in diagnosis of erosions too.

Hintze et al.<sup>22</sup> compared diagnostic accuracy of cone beam CT images with corrected tomographic images for detection of morphological temporomandibular joint changes. In general, they found no significant difference in diagnostic accuracy between Cone Beam CT images and corrected tomograms for the detection of bone changes in the condyle and the articular tubercle. Honey et al.<sup>23</sup> compared the accuracy of Cone Beam Computed Tomography (CBCT) with panoramic radiography and linear corrected tomography in detection of cortical erosions affecting the mandibular condylar head. They reported that the diagnostic accuracy of CBCT was significantly higher than that of other modalities. They also reported an inter-observer agreement of  $0.44 \pm 0.151$  for corrected linear sagittal tomography. In this study, we found an inter-observer agreement of 0.529 for the corrected sagittal spiral tomography. Hussain et al.<sup>1</sup> provided a systemic review on the role of different imaging modalities in assessment of temporomandibular joint erosion and he found axially corrected sagittal tomography as the imaging modality of choice.<sup>1</sup>

## Conclusion

It seems that corrected sagittal tomography tech-

nique is more accurate for detection of mandibular condyle erosions and is a useful modality for imaging TMJ erosions.

Further studies can be done on human skull with soft tissue equivalent as gold standard.

## References

1. Hussain AM, Packota G, Major PW, Flores-Mir C. Role of different imaging modalities in assessment of temporomandibular joint erosions and osteophytes: a systematic review. *Dentomaxillofac Radiol* 2008; 37(2): 63-71.
2. Rugh JD, Solberg WK. Oral health status in the United States: temporomandibular disorders. *J Dent Educ* 1985; 49(6): 398-406.
3. Al Jundi MA, John MT, Setz JM, Szentpetery A, Kuss O. Meta-analysis of treatment need for temporomandibular disorders in adult nonpatients. *J Orofac Pain* 2008; 22(2): 97-107.
4. Lindvall AM, Helkimo E, Hollender L, Carlsson GE. Radiographic examination of the temporomandibular joint. A comparison between radiographic findings and gross and microscopic morphologic observations. *Dentomaxillofac Radiol* 1976; 5(1-2): 24-32.
5. Brooks SL, Brand JW, Gibbs SJ, Hollender L, Lurie AG, Omnell KA, et al. Imaging of the temporomandibular joint: a position paper of the American Academy of Oral and Maxillofacial Radiology. *Oral Surg Oral Med Oral Pathol Oral Radiol Endod* 1997; 83(5): 609-18.
6. Roberts C, Katzberg RW, Tallents RH, Espeland MA, Handelman SL. The clinical predictability of internal derangements of the temporomandibular joint. *Oral Surg Oral Med Oral Pathol* 1991; 71(4): 412-4.
7. Larheim TA. Current trends in temporomandibular joint imaging. *Oral Surg Oral Med Oral Pathol Oral Radiol Endod* 1995; 80(5): 555-76.
8. Koh KJ, List T, Petersson A, Rohlin M. Relationship between clinical and magnetic resonance imaging diagnoses and findings in degenerative and inflammatory temporomandibular joint diseases: a systematic literature review. *J Orofac Pain* 2009; 23(2): 123-39.
9. Tsiklakis K, Syriopoulos K, Stamatakis HC. Radiographic examination of the temporomandibular joint using cone beam computed tomography. *Dentomaxillofac Radiol* 2004; 33(3): 196-201.
10. Pharoah MJ, white SC, Oral radiology: principles and interpretation, 6<sup>th</sup> ed. St. Louis: Mosby; 2009. p. 14, 478.
11. Eckerdal O, Lundberg M. The structural situation in temporomandibular joints. A comparison between conventional oblique transcranial radiographs, tomograms and histologic sections. *Dentomaxillofac Radiol* 1979; 8(1): 42-9.

12. Bean LR, Omnell KA, Oberg T. Comparison between radiologic observations and macroscopic tissue changes in temporomandibular joints. *Dentomaxillofac Radiol* 1977; 6(2): 90-106.
13. Cholitgul W, Petersson A, Rohlin M, Tanimoto K, Akerman S. Diagnostic outcome and observer performance in sagittal tomography of the temporomandibular joint. *Dentomaxillofac Radiol* 1990; 19(1): 1-6.
14. Flygare L, Rohlin M, Akerman S. Macroscopic and microscopic findings of areas with radiologic erosions in human temporomandibular joints. *Acta Odontol Scand* 1992; 50(2): 91-100.
15. Cara AC, Gaia BF, Perrella A, Oliveira JX, Lopes PM, Cavalcanti MG. Validity of single- and multislice CT for assessment of mandibular condyle lesions. *Dentomaxillofac Radiol* 2007; 36(1): 24-7.
16. Landis JR, Koch GG. The measurement of observer agreement for categorical data. *Biometrics* 1977; 33(1): 159-74.
17. Kavadella A, Karayiannis A, Nicopoulou-Karayianni K. Detectability of experimental peri-implant cancellous bone lesions using conventional and direct digital radiography. *Aust Dent J* 2006; 51(2): 180-6.
18. Masood F, Katz JO, Hardman PK, Glaros AG, Spencer P. Comparison of panoramic radiography and panoramic digital subtraction radiography in the detection of simulated osteophytic lesions of the mandibular condyle. *Oral Surg Oral Med Oral Pathol Oral Radiol Endod* 2002; 93(5): 626-31.
19. Rohlin M, Akerman S, Kopp S. Tomography as an aid to detect macroscopic changes of the temporomandibular joint. An autopsy study of the aged. *Acta Odontol Scand* 1986; 44(3): 131-40.
20. Tanimoto K, Petersson A, Rohlin M, Hansson LG, Johansen CC. Comparison of computed with conventional tomography in the evaluation of temporomandibular joint disease: a study of autopsy specimens. *Dentomaxillofac Radiol* 1990; 19(1): 21-7.
21. Ludlow JB, Davies KL, Tyndall DA. Temporomandibular joint imaging: a comparative study of diagnostic accuracy for the detection of bone change with biplanar multidirectional tomography and panoramic images. *Oral Surg Oral Med Oral Pathol Oral Radiol Endod* 1995; 80(6): 735-43.
22. Hintze H, Wiese M, Wenzel A. Cone beam CT and conventional tomography for the detection of morphological temporomandibular joint changes. *Dentomaxillofac Radiol* 2007; 36(4): 192-7.
23. Honey OB, Scarfe WC, Hilgers MJ, Klueber K, Silveira AM, Haskell BS, et al. Accuracy of cone-beam computed tomography imaging of the temporomandibular joint: comparisons with panoramic radiology and linear tomography. *Am J Orthod Dentofacial Orthop* 2007; 132(4): 429-38.