

The role of cone-beam computed tomography in the radiographic evaluation of obstructive sleep apnea: A review article

Marco Isaac^{1,2}, Dina Mohamed ElBeshlawy^{2,3}, Ahmed ElSobki⁴, Dina Fahim Ahmed², Sarah Mohammed Kenawy^{2,*}

¹Department of Oral and Maxillofacial Radiology, Faculty of Oral and Dental Medicine, Delta University for Science and Technology, Gamasa, Egypt

²Department of Oral and Maxillofacial Radiology, Faculty of Dentistry, Cairo University, Cairo, Egypt

³Department of Oral and Maxillofacial Radiology, Galala University, Al Galala, Egypt

⁴Department of Otorhinolaryngology, Faculty of Medicine, Mansoura University, Mansoura, Egypt

ABSTRACT

The apnea-hypopnea index is widely regarded as a measure of the severity of obstructive sleep apnea (OSA), a condition characterized by recurrent episodes of apnea or hypopnea during sleep that induce airway collapse. OSA is a catastrophic problem due to the wide range of health issues it can cause, including cardiovascular disease and memory loss. This review was conducted to clarify the roles of various imaging modalities, particularly cone-beam computed tomography (CBCT), in the diagnosis of and preoperative planning for OSA. Unfortunately, 2-dimensional imaging techniques yield insufficient data for a comprehensive diagnosis, given the complex anatomy of the airway. Three-dimensional (3D) imaging is favored as it more accurately represents the patient's airway structure. Although computed tomography and magnetic resonance imaging can depict the actual 3D airway architecture, their use is limited by factors such as high radiation dose and noise associated with the scans. This review indicates that CBCT is a low-radiation imaging technique that can be used to incidentally identify patients with OSA, thereby facilitating early referral and ultimately enhancing the accuracy of surgical outcome predictions. (*Imaging Sci Dent* 2023; 53: 283-9)

KEY WORDS: Sleep Apnea, Obstructive; Cone-Beam Computed Tomography; Polysomnography; Airway Obstruction

Introduction

Obstructive sleep apnea (OSA) is a common sleep disorder that leads to serious physiological abnormalities with numerous therapeutic implications. The concept of the apnea-hypopnea index has redefined the understanding of OSA, serving as a standard measure of sleep physiology abnormalities and an indicator of disease severity.¹ As such, OSA is now characterized as 5 or more instances of apnea or hypopnea per hour of sleep with accompanying symptoms, or 15 or more episodes per hour of sleep regardless

of associated symptoms.^{2,3}

The human pharyngeal airway lacks bone support. Consequently, the muscles must work to maintain an unobstructed air passage through the upper respiratory tract. These muscles facilitate the bending of the upper airway for speech, swallowing, and respiration. Evidence regarding neural modulation, muscular response, and efficacy suggests that the pharyngeal muscles may contribute to OSA.⁴

Sleeplessness is a result of intermittent upper airway collapse and low blood oxygen saturation.⁵ In the initial stages of OSA, patients often cannot differentiate between symptoms of the condition and regular fatigue, primarily because chronic fatigue, a common OSA symptom, is frequently underestimated. As the disease progresses, sleepiness becomes detrimental, interfering with daily life.² Recent international research indicates that the prevalence of OSA

Received June 3, 2023; Revised August 18, 2023; Accepted September 9, 2023

Published online November 6, 2023

*Correspondence to : Dr. Sarah Mohammed Kenawy

Department of Oral and Maxillofacial Radiology, Faculty of Dentistry, 11, El Saraya Street, Manial, Cairo, Egypt

Tel) 20-2-23634965, E-mail) sarah.kenawy@dentistry.cu.edu.eg

Copyright © 2023 by Korean Academy of Oral and Maxillofacial Radiology

This is an Open Access article distributed under the terms of the Creative Commons Attribution Non-Commercial License (<http://creativecommons.org/licenses/by-nc/3.0>) which permits unrestricted non-commercial use, distribution, and reproduction in any medium, provided the original work is properly cited.

Imaging Science in Dentistry · pISSN 2233-7822 eISSN 2233-7830

has risen to 2%-4% in men and 1%-2% in women within the average-aged population.¹ Since OSA is quiet, 20%-30% of middle-aged patients display no clinical indicators.² The rates of OSA have surged in tandem with global obesity trends and show no signs of decelerating. OSA has been recognized as a serious problem with extensive implications for public health, given its association with conditions such as lung diseases, diabetes, and cardiovascular diseases.^{2,6}

Polysomnography serves as the fundamental basis for diagnosing OSA. This procedure, also referred to as a sleep study, entails the continuous monitoring of various neuro-physiological and cardiorespiratory changes.⁷ Polysomnography plays a pivotal role in both the diagnosis of OSA and the evaluation of treatment success. However, to arrive at a definitive diagnosis, particularly in children, it is essential to integrate polysomnography with the patient's clinical history and radiographic evaluation.⁸

This review article received approval from the Ethics Committee of the Faculty of Dentistry at Cairo University prior to publication. The aim of this review was to examine the radiographic evaluation of OSA, with an emphasis on CBCT as an imaging modality. Furthermore, most tools related to OSA assessment are detailed in the ensuing discussion.

Radiographic assessment of OSA

The clinical evaluation process is complex due to the location of the disease, which does not permit direct visualization.⁹ To identify the anatomical structures that undergo changes during sleep, a complete radiographic evaluation is necessary.¹⁰ Two-dimensional (2D) and 3-dimensional (3D) imaging methods can be employed to assess the oropharyngeal airway. These techniques include cephalometric radiography, magnetic resonance imaging (MRI), computed tomography (CT), and cone-beam computed tomography (CBCT).¹¹

In the differentiation of OSA from other conditions, 2D cephalometric scans were long considered reliable. However, without 3D scanning, the complex outline of the airway cannot be properly evaluated.¹² Multiple studies have demonstrated that the static cross-sectional area of the pharyngeal airway is smaller in patients with OSA compared to those without the condition.^{1,13} Current research indicates that changes to the mandible and maxilla can influence the cross-sectional dimensions of the pharyngeal airway space.^{14,15}

CT imaging establishes numerous sections in different orthogonal planes, characterized by minimal thickness and

imperceptible partial volume artifacts.¹⁶ However, the primary disadvantage of CT imaging is the requisite exposure to radiation. Additionally, multiple logistical challenges are associated with sleep monitoring during CT imaging.¹⁷ Although MRI can accurately depict the true soft tissue shape of the airway, its application has been limited due to the associated noise and excessively prolonged scan time.

Maxillofacial imaging has undergone a major transition from a 2D approach to a volumetric perspective, largely due to the power of CBCT 3D imaging.¹⁸ CBCT is considered the optimal choice for 3D dental-sleep imaging due to its high spatial resolution, which enables differentiation between structures such as bone, empty space, and soft tissues.¹⁹

Despite the superiority of CT over CBCT in non-soft tissue contrast, CBCT demonstrates a comparable reduction in radiation dose. While still acknowledging the substantial adverse impacts of OSA, the principle of "as low as reasonably achievable" necessitates the reduction of radiation dose to enable precise diagnosis.

When considering the triad of non-soft tissue contrast, radiation exposure, and the potential impacts of OSA, CBCT therefore emerges as the most reasonable imaging modality. Furthermore, the application of specialized analysis software equipped with advanced thresholding techniques, along with the evolution of artificial intelligence-based computer-aided diagnostic methods, can effectively address the validation of non-soft tissue contrast abnormalities.²⁰

Role of CBCT in OSA diagnosis

The role of CBCT in OSA can be divided into several tasks. These include evaluating the dimensions of the airway; distinguishing between patients with OSA and their counterparts; correlating clinical parameters with radiographic findings; and, ultimately, validating diagnosis and treatment planning by determining the level of collapse and identifying abnormalities not visible via drug-induced sleep endoscopy.

Scanning and interpretation protocol

The process of displaying CBCT images is methodical and should be completed prior to their interpretation. The initial step involves adjusting the patient's anatomy by realigning certain patient data. For instance, the Frankfort horizontal plane should be adjusted to be parallel to the floor of the mouth, while the midsagittal plane should be made perpendicular to the Frankfort horizontal plane. These modifications are necessary if the volumetric data are to be utilized in craniofacial assessment. Subsequently,

the dataset must be optimized for greyscale brightness. This can be achieved by setting a contrast range, applying suitable filters, and completing the sharpening process. These adjustments contribute to a successful assessment of the upper airway.

CBCT raw volumetric data are exported in the Digital Imaging and Communications in Medicine format. Subsequently, these CBCT datasets can be imported into various image-processing software applications, such as OnDemand 3D (Cybermed Inc., Seoul, Korea), InVivoDental (Anatomage, San Jose, CA, USA), and Dolphin 3D (Dolphin Imaging and Management Solutions, Los Angeles, CA, USA). Within these applications, the data can be further processed to preview essential upper airway projections, which include 2D radiographic images suitable for cephalometric analysis.²¹ All slices must be dynamically analyzed by scrolling through the views, given the multitude of orthogonal images present in each plane. The images should initially be reviewed in a cranio-caudal direction (from head to toe), with the scrolling speed reduced in complex sections by scrolling in reverse. This scrolling procedure must be repeated for each of the 3 orthogonal axes.

Assessment of airway dimensions

Analysis of radiographic images from CBCT can aid in assessing both nasopharyngeal and oropharyngeal airways. Numerous authors have listed the nasopharyngeal airway dimensions, which include linear variables from the posterior nasal spine to the McNamara lower pharynx measurement. This latter measurement represents the shortest distance between the point at which the back of the tongue meets the jaw and the point closest to the back of the pharyngeal wall.²² Conversely, the dimensions of the oropharyngeal airway at 3 levels (upper, medium, and lower) can be accurately measured in both the anteroposterior and transversal directions of the airway space using CBCT software.²³

Differentiation between patients with OSA and their counterparts

CBCT has numerous applications in upper airway analysis, such as rendering airway volume, identifying anatomical features, and measuring the lengths of the soft palate and airway. As such, CBCT plays a crucial role in the early referral of patients suspected to have OSA.²¹

Airway volume rendering

The development of volume rendering was driven by the difficulty of correlating structures in each orthogonal plane.

Volume rendering is defined as a collection of methods designed to enhance visualization through the selective presentation of volumetric data. Two distinct methods are typically employed. The first, termed indirect volume rendering, involves the selection of grayscale intensity levels for the voxels, a process referred to as segmentation. This technique allows for the reconstruction of a 3D volumetric surface. The second method, direct volume rendering, involves the random selection of threshold intensities for individual voxels, while excluding all but the darkest and lightest shades of grey. Both of these techniques can be uti-

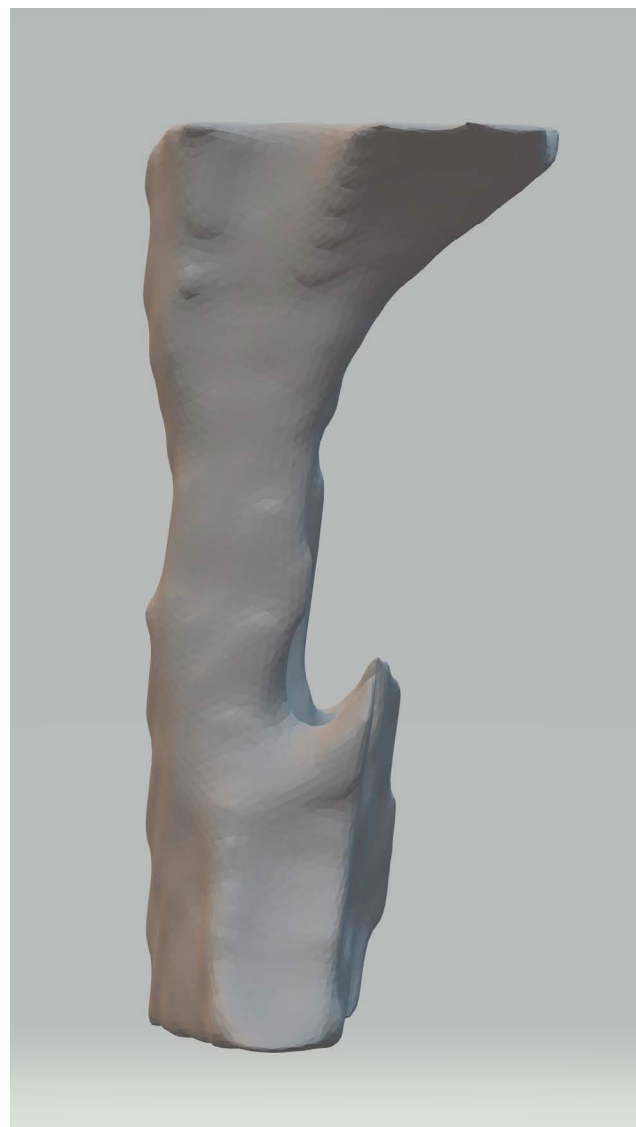


Fig. 1. A cone-beam computed tomographic scan displays an automated 3-dimensional segmentation of the oropharyngeal airway volume. The segmentation, generated by InVivo5 software (Anatomage, San Jose, CA, USA), extends from the level of the posterior nasal spine to the level of the most anterior inferior point of the second cervical vertebrae.

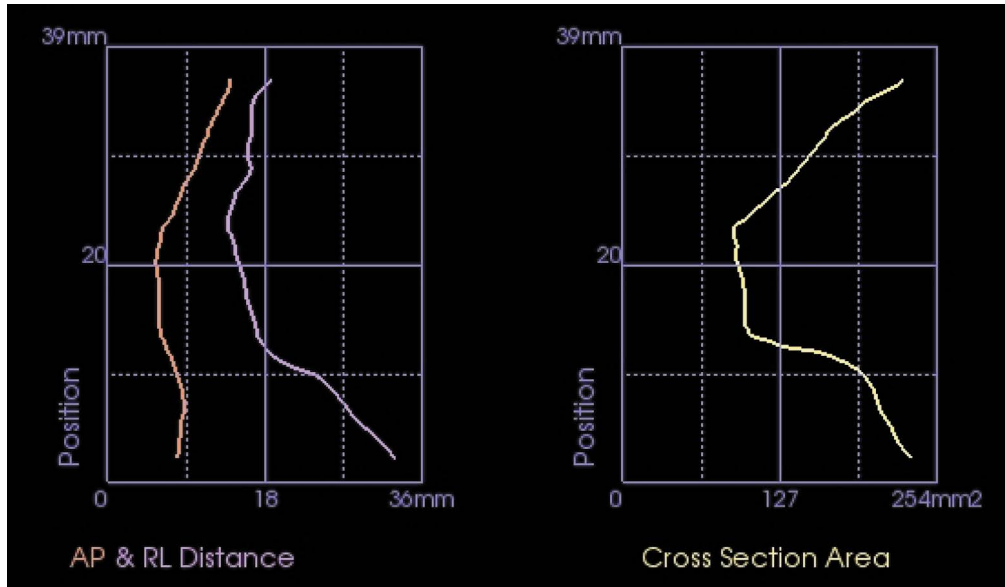


Fig. 2. Automated graphs represent a patient with obstructive sleep apnea. These graphs display the cross section area, measured in mm², along with the anteroposterior (AP) and lateral (L) dimensions, measured in mm. These measurements were taken along the predetermined oropharyngeal airway space using Invivo 5 software (Anatomage, San Jose, CA, USA).

lized to segment the airway structure, effectively isolating it from the surrounding structures. Given that CBCT data are initially reconstructed in 3D and offer superior spatial resolution, this technology yields the most accurate 3D segmented airway volume, as depicted in Figure 1.¹⁸

The primary metrics used to assess the static structure of the upper respiratory tract are typically recorded at the retro-palatal or retroglossal site. The volume of the airway can be evaluated using 3 separate measurements: the retropalatal airway volume, the retroglossal airway volume, and the total airway volume. Numerous studies have established CBCT as the gold standard for both linear and angular measurements, comparable to multislice CT. Furthermore, the use of an airway phantom for airway evaluation has indicated that CBCT is accurate and reliable for imaging the upper airway and for measuring airway volume, as depicted in Figure 2.^{21,24}

Bony anatomical features

The skeletal relationships that can modify the size of the upper airway, predisposing it to collapse during sleep and cause apnea, may be assessed through CBCT imaging. These relationships are defined through metrics derived from the information provided by CBCT midline reconstruction. In addition to a short maxilla and mandible, a high-arched palate is associated with oropharyngeal crowding and an increased likelihood of OSA. Numerous CBCT studies have demonstrated a strong correlation between an

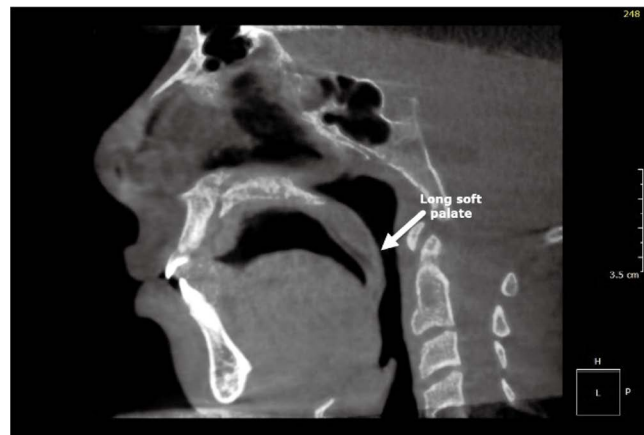


Fig. 3. Image of a patient with obstructive sleep apnea who had a long soft palate, as seen in the midsagittal plane of a cone-beam computed tomographic scan.

inferiorly positioned hyoid bone and an increased oropharyngeal length, with both parameters linked to the severity of OSA.^{25,26}

Soft palate and airway lengths

An elongated soft palate is a local airway component that may contribute to OSA. CBCT studies have demonstrated that individuals with sleep apnea possess larger and longer soft palates than those without the disorder, as depicted in Figure 3. The soft palate has been found to change over time and with disease progression; specifically, research has

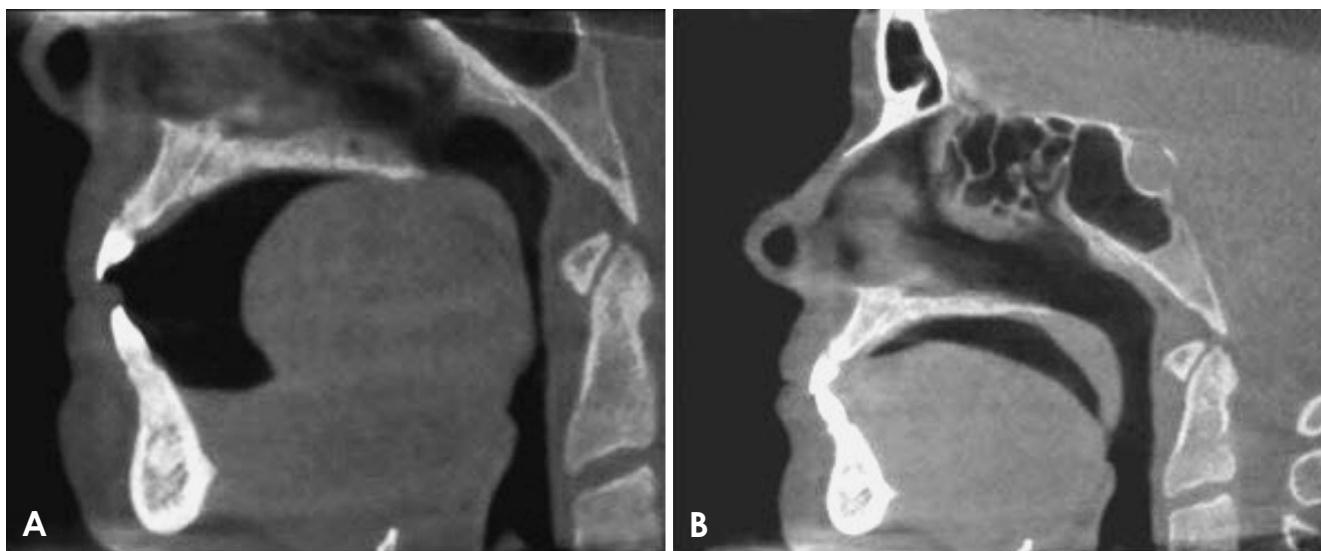

Fig. 4. Images cited from Aboelmaaty et al.³² depict the views of the end of expiration (A) and inspiration (B) in a single patient with obstructive sleep apnea. The tongue-palate interaction is observed to reduce the airway volume at the end of expiration.

demonstrated excessive flaccidity and muscle atrophy in the soft palates and uvulas of patients with OSA who snore. Shigeta et al. analyzed the midsagittal cross-sectional area of the soft palate using CBCT and observed that the soft palate was substantially longer in patients with OSA compared to control participants.²⁷

The distance between the palatal plane and a parallel plane created at the level of the lowest border of C4 is commonly used to estimate the maximum length of the upper airway. In a CBCT study conducted by Abramson et al.,²⁸ the presence of OSA was associated with a greater airway length (76.7 ± 11.1 mm) relative to controls (66.3 ± 10.1 mm). Furthermore, the morphology of the airway differs between patients with OSA and their counterparts. Those with OSA typically have an airway with a concave or elliptical shape, whereas non-OSA controls tend to have an airway that displays a concave, round, or square shape.²⁹

Validation of diagnosis and treatment planning

The oropharynx, which extends from the posterior nasal spine to the tip of the epiglottis, is the primary focus of investigation in the upper airway due to its high susceptibility to obstruction.³⁰ A pioneering CBCT study revealed that CBCT, a cutting-edge 3D imaging technique, offers reliable information about the level of collapse with minimal radiation dosage, a finding that has been validated by drug-induced sleep endoscopy. Notably, drug-induced sleep endoscopy is considered a dynamic method for determining the level of collapse, whereas virtual endoscopy is a static modality that lacks this capability.³¹

CBCT serves as an effective adjunct imaging tool that aids in the evaluation of upper airway dysfunction. Particularly in patients with OSA who exhibit tongue-palate contact or an extended palate, CBCT images provide definitive results, most notably in the end-expiration views in orthogonal plane interpretation (Fig. 4).³² CBCT should not be solely relied upon for assessing the severity of collapse. Instead, it should be utilized as a potent additional imaging resource that can assist in quantifying upper airway failure.³¹

Potential limitations of CBCT in OSA imaging

The validity of CBCT in assessing OSA is debatable, given that most CBCT devices capture images of the airway while the patient is either standing or sitting. A recent study performed by Aboelmaaty et al.³¹ found that the patient's alignment during image acquisition could impair the expansion capacity of the upper airway in the anterior-posterior plane. Furthermore, they asserted that the airway space is at its minimum size when the patient is awake.

In 2005, Tsuiki et al.³³ examined changes in airway size among patients with OSA in both upright and supine positions. The researchers found that the anatomic characteristics of the upper airway are influenced by the tonicity of the musculature, which differs significantly when the patient is in the supine position as opposed to when they are awake. Furthermore, they noted that airway obstruction at the level of the larynx and laryngopharynx cannot be established through static imaging techniques such as CBCT. Instead,

such obstructions are better examined through dynamic methods, like drug-induced sleep endoscopy. Consequently, they concluded that the results obtained from CBCT should be interpreted as a relative index of airway obstruction, rather than an absolute value.

Another study, conducted by Camacho et al.³⁴ at Stanford Hospitals and Clinics, indicated that gravity and tissue elasticity likely play major roles in the variations observed in upper airway volume. The retropalatal region, which is particularly susceptible to the effects of gravity when the palate is in the supine position, is the area where changes in the size of the upper airway are most likely to occur. The study demonstrated that when patients were in the supine position, both the total volume and the cross-sectional area of the airway were reduced.

Souza et al.³⁵ asserted that the grayscale value of a voxel is influenced by its position within the image volume. Consequently, it is improbable for 2 voxels with identical tissue density but differing scan positions to exhibit the same grayscale level in the reconstructed image. This phenomenon illustrates the absence of correlation between Hounsfield units and grayscale values. The lack of soft tissue contrast in the CBCT data stems from the constraints on grayscale values and tissue density. As such, the effects of thresholding on spatial positions are impeded.

In a study performed to establish a reliable method for measuring the dimensions of the upper airway, manual segmentation of each CBCT section was suggested as an alternative to single threshold-based segmentation algorithms. However, this approach is generally considered impractical due to the extensive time required to complete it for a single dataset; additionally, the potential for error remains. Thus, the automatic segmentation offered by various software packages is viewed as a more reliable technique. Nevertheless, the accuracy of airway volume measurements is contingent upon the thresholding technique employed by each software package.³⁵

In conclusion, CBCT is an innovative imaging technique within the field of dental sleep medicine, offering a broad spectrum of applications for the diagnosis, evaluation, and staging of OSA. However, regarding OSA assessment, CBCT should not be used in isolation. Instead, it should be integrated with other diagnostic tools, such as clinical assessment and polysomnography, as part of a comprehensive approach by a multidisciplinary team.

CBCT is a low-radiation 3D imaging technology that can be employed to diagnose patients with OSA as an incidental finding, facilitating early referral. In patients with OSA, the average size and capacity of the airway are lower, the

airway distance is greater, and the airway passage is more constricted compared to healthy individuals. Moreover, the CBCT technology may contribute to enhancing the prediction of surgical outcomes.

Conflicts of Interest: None

References

1. Maspero C, Giannini L, Galbiati G, Rosso G, Farronato G. Obstructive sleep apnea syndrome: a literature review. *Minerva Stomatol* 2015; 64: 97-109.
2. Mannarino MR, Di Filippo F, Pirro M. Obstructive sleep apnea syndrome. *Eur J Intern Med* 2012; 23: 586-93.
3. Park JG, Ramar K, Olson EJ. Updates on definition, consequences, and management of obstructive sleep apnea. *Mayo Clin Proc* 2011; 86: 549-55.
4. Eckert DJ. Phenotypic approaches to obstructive sleep apnoea - new pathways for targeted therapy. *Sleep Med Rev* 2018; 37: 45-59.
5. Lévy P, Kohler M, McNicholas WT, Barbé F, McEvoy RD, Somers VK, et al. Obstructive sleep apnoea syndrome. *Nat Rev Dis Primers* 2015; 1: 15015.
6. Massillamani F, Kailasam S, Prabhakaran A, Guntuku N. Upper aerodigestive space analysis in obstructive sleep apnea: an overview. *J Dr NTR Univ Health Sci* 2018; 7: 1-7.
7. Platon AL, Stelea CG, Boișteanu O, Patrascanu E, Zetu IN, Roșu SN, et al. An update on obstructive sleep apnea syndrome - a literature review. *Medicina (Kaunas)* 2023; 59: 1459.
8. Shi Y, Gu M, Zhang X, Wen M, Li R, Wang Y, et al. Diagnostic value of upper airway morphological data based on CT volume scanning combined with clinical indexes in children with obstructive sleep apnea syndrome. *Front Med (Lausanne)* 2023; 10: 1150321.
9. Indriksone I, Jakobsone G. The upper airway dimensions in different sagittal craniofacial patterns: a systematic review. *Stomatologija* 2014; 16: 109-17.
10. Whyte A, Gibson D. Imaging of adult obstructive sleep apnoea. *Eur J Radiol* 2018; 102: 176-87.
11. Zinsly SdR, Moraes LCd, Moura Pd, Ursi W. Assessment of pharyngeal airway space using cone-beam computed tomography. *Dental Press J Orthod* 2010; 15: 150-8.
12. Momany SM, AlJamal G, Shugaa-Addin B, Khader YS. Cone beam computed tomography analysis of upper airway measurements in patients with obstructive sleep apnea. *Am J Med Sci* 2016; 352: 376-84.
13. Neelapu BC, Kharbanda OP, Sardana HK, Balachandran R, Sardana V, Kapoor P, et al. Craniofacial and upper airway morphology in adult obstructive sleep apnea patients: a systematic review and meta-analysis of cephalometric studies. *Sleep Med Rev* 2017; 31: 79-90.
14. Kim AM, Keenan BT, Jackson N, Chan EL, Staley B, Poptani H, et al. Tongue fat and its relationship to obstructive sleep apnea. *Sleep* 2014; 37: 1639-48.
15. Degache F, Sforza E, Dauphinot V, Celle S, Garcin A, Collet P, et al. Relation of central fat mass to obstructive sleep apnea in

- the elderly. *Sleep* 2013; 36: 501-7.
16. Marshall EL, Ginat DT, Sammet S. Computed tomography imaging artifacts in the head and neck region: pitfalls and solutions. *Neuroimaging Clin N Am* 2022; 32: 271-7.
 17. Fred HL. Drawbacks and limitations of computed tomography: views from a medical educator. *Tex Heart Inst J* 2004; 31: 345-8.
 18. Scarfe WC, Li Z, Aboelmaaty W, Scott SA, Farman AG. Maxillofacial cone beam computed tomography: essence, elements and steps to interpretation. *Aust Dent J* 2012; 57 Suppl 1: 46-60.
 19. Lenza MG, Lenza MM, Dalstra M, Melsen B, Cattaneo PM. An analysis of different approaches to the assessment of upper airway morphology: a CBCT study. *Orthod Craniofac Res* 2010; 13: 96-105.
 20. Kim K, Lim CY, Shin J, Chung MJ, Jung YG. Enhanced artificial intelligence-based diagnosis using CBCT with internal denoising: clinical validation for discrimination of fungal ball, sinusitis, and normal cases in the maxillary sinus. *Comput Methods Programs Biomed* 2023; 240; 107708.
 21. Conley RS, Cattaneo PM, Haskell BS. Characterization of the upper airway morphology and its changes in the apneic patient using cone beam computed tomography. In: Kaplila S. *Cone beam computed tomography in orthodontics: indications, insights, and innovations*. Hoboken: John Wiley & Sons; 2014. p. 273-91.
 22. Chaturvedi S, Agarwal A, Chaturvedi Y, Goyal A, Agarwal V. Comparative study of the nasopharyngeal airway dimensions in Class II individuals using cone-beam computed tomography. *J Indian Orthod Soc* 2014; 48: 256-61.
 23. Dalmau E, Zamora N, Tarazona B, Gandia JL, Paredes V. A comparative study of the pharyngeal airway space, measured with cone beam computed tomography, between patients with different craniofacial morphologies. *J Craniomaxillofac Surg* 2015; 43: 1438-46.
 24. Enciso R, Nguyen M, Shigeta Y, Ogawa T, Clark GT. Comparison of cone-beam CT parameters and sleep questionnaires in sleep apnea patients and control subjects. *Oral Surg Oral Med Oral Pathol Oral Radiol Endod* 2010; 109: 285-93.
 25. Chen H, Aarab G, de Ruyter MH, de Lange J, Lobbezoo F, van der Stelt PF. Three-dimensional imaging of the upper airway anatomy in obstructive sleep apnea: a systematic review. *Sleep Med* 2016; 21: 19-27.
 26. Barrera JE, Pau CY, Forest VI, Holbrook AB, Popelka GR. Anatomic measures of upper airway structures in obstructive sleep apnea. *World J Otorhinolaryngol Head Neck Surg* 2017; 3: 85-91.
 27. Enciso R, Clark GT. Comparing the Berlin and the ARES questionnaire to identify patients with obstructive sleep apnea in a dental setting. *Sleep Breath* 2011; 15: 83-9.
 28. Abramson Z, Susarla S, August M, Troulis M, Kaban L. Three-dimensional computed tomographic analysis of airway anatomy in patients with obstructive sleep apnea. *J Oral Maxillofac Surg* 2010; 68: 354-62.
 29. Ogawa T, Enciso R, Shintaku WH, Clark GT. Evaluation of cross-section airway configuration of obstructive sleep apnea. *Oral Surg Oral Med Oral Pathol Oral Radiol Endod* 2007; 103: 102-8.
 30. Chiang CC, Jeffres MN, Miller A, Hatcher DC. Three-dimensional airway evaluation in 387 subjects from one university orthodontic clinic using cone beam computed tomography. *Angle Orthod* 2012; 82: 985-92.
 31. Aboelmaaty W, Isaac M. An evaluation of cone beam computed tomography in verifying the level of collapse in obstructive sleep apnea patients. *Cranio* (in press).
 32. Aboelmaaty WM, Isaac M, Elsobky A, Elewa M. Cone beam computed tomography role in surgical treatment planning of obstructive sleep apnea patients. *Egypt Dent J* 2018; 64: 2355-60.
 33. Tsuiki S, Almeida FR, Lowe AA, Su J, Fleetham JA. The interaction between changes in upright mandibular position and supine airway size in patients with obstructive sleep apnea. *Am J Orthod Dentofacial Orthop* 2005; 128: 504-12.
 34. Camacho M, Capasso R, Schendel S. Airway changes in obstructive sleep apnoea patients associated with a supine versus an upright position examined using cone beam computed tomography. *J Laryngol Otol* 2014; 128: 824-30.
 35. Souza KR, Oltramari-Navarro PV, Navarro Rde L, Conti AC, Almeida MR. Reliability of a method to conduct upper airway analysis in cone-beam computed tomography. *Braz Oral Res* 2013; 27: 48-54.