

Characteristics of a rat model of an open craniocerebral injury at simulated high altitude

An-Yong Yu^a, Quan-Hong Xu^b, Sheng-Li Hu^a, Fei Li^a, Yu-Jie Chen^a, Yi Yin^a, Gang Zhu^a, Jiang-Kai Lin^a and Hua Feng^a

To establish a rat model of an open craniocerebral injury at simulated high altitude and to examine the characteristics of this model. Rats were divided randomly into a normobaric group and a high-altitude group and their corresponding control groups. A rat model of an open craniocerebral injury was established with a nail gun shot. Simulated high-altitude conditions were established with a hypobaric chamber at 0.6 ATA to mimic pressure at an altitude of 4000 m. Mortality, brain water content (BWC), Evans blue content, pathology, regional cerebral blood flow (rCBF), partial pressure of brain tissue oxygen (PbtO₂), and brainstem auditory-evoked potential were observed after injury. The mortality of the high-altitude group was significantly greater than that of the normobaric group within 72 h after injury ($P < 0.05$). BWC and Evans blue content increased by 48 h after injury ($P < 0.05$); pathological changes in damaged brains were more serious. In contrast, rCBF and PbtO₂ had decreased markedly by 72 h ($P < 0.01$); brainstem auditory-evoked potential values were significantly prolonged ($P < 0.05$). Moreover, an inverse correlation between rCBF and BWC

and a positive correlation between rCBF and PbtO₂ were found. The rat model of an open craniocerebral injury at simulated high altitude can be established successfully using a nail gun shot and a hypobaric chamber. The injury characteristics at high altitude were more serious, rapid, and prolonged than those in the normobaric group. *NeuroReport* 25:1272–1280 © 2014 Wolters Kluwer Health | Lippincott Williams & Wilkins.

NeuroReport 2014, 25:1272–1280

Keywords: animal model, brain water content, high altitude, open craniocerebral injury, PbtO₂, rCBF

^aDepartment of Neurosurgery, Southwest Hospital, Third Military Medical University, Chongqing and ^bThe 41 Hospital of PLA, Tibet, People's Republic of China

Correspondence to Hua Feng, MD, PhD, Department of Neurosurgery, Southwest Hospital, Third Military Medical University, Chongqing 400038, People's Republic of China

Tel: +86 137 083 21681; fax: +86 236 546 3954; e-mail: fenghua8888@aliyun.com

Received 21 July 2014 accepted 4 August 2014

Introduction

Penetrating brain injury (PBI) is a leading cause of mortality and morbidity in modern warfare, and accounts for a significant number of traumatic brain injuries (TBI) worldwide. PBI has historically been associated with a poor prognosis [1]. The mortality rate of PBI remains high, with military rates ranging from 6.8 to 61.1% and civilian mortality ranging from 34 to 88.1% [2]. TBI is also considered a 'signature injury' in modern warfare: ~20% of veterans from the Iraq or Afghanistan wars have experienced a TBI [3]. From April 2003 to January 2011, a total of 15 192 US military personnel were injured in Operation Iraqi Freedom/Operation Enduring Freedom, with 636 patients sustaining a PBI [4]. In the civilian sector, firearm-related injuries are on the rise nationwide, with bullet wound injuries to the head being the most common cause of TBI-related fatality in the USA [5]. TBI treatment should be timely and proper, not only for the survival of the wounded, functional status, and

combat forces, but should also have a greater impact on economic development during postwar peace.

Over the past three decades, to better understand the underlying pathophysiology and explore potential treatments, animal models have been developed to mimic the various aspects of human TBI. Although researchers have established a variety of craniocerebral injury models to study TBI according to clinical needs and research purposes [6,7], no economic, practical, and reproducible animal models are available to study PBI at altitudes over 2500 m. The increasing number of individuals traveling to high altitude for work or adventure tourism is a public health issue. The WHO estimates that 3.5 million individuals a year travel to over 3000 m [8]. The higher the maximum altitude, the more likely individuals suffer from high-altitude illness, which mainly include acute mountain sickness (AMS), high-altitude cerebral edema, and pulmonary edema [9]. AMS invariably appears within several hours of reaching 4000 m [8], and reduced supply of oxygen at high altitude may lead to brain damage. To date, little is known about the pathophysiology and effective treatment for patients exposed to hypobaric hypoxia after PBI at high elevation.

This is an open-access article distributed under the terms of the Creative Commons Attribution-NonCommercial-NoDerivatives 3.0 License, where it is permissible to download and share the work provided it is properly cited. The work cannot be changed in any way or used commercially.

Several in-vivo models of brain injury are currently available [10], but the most widely used models focus on ischemia (i.e. arterial occlusion models) and blunt trauma (i.e. fluid percussion or cortical impact models). Stab-type brain injury models also exist; however, they do not mimic the ballistic damage induced by a bullet wound. Williams and colleagues [6,7] developed a penetrating ballistic-like brain injury rat model to study the effects of penetrating wounds on gross pathology wounds, locomotive deficits, and histopathological changes associated with ballistic injury. However, to our knowledge, the characteristics of PBI at high elevation have not been studied systemically in rats. Current PBI research mainly focuses on clinical reports. In this study, we created a rat model using a nail gun shot at simulated high altitude, and examined animal ethology, histopathology, brain water content (BWC), Evans blue (EB) content, regional cerebral blood flow (rCBF), partial pressure of brain tissue oxygen (PbtO₂), and monitored brainstem auditory-evoked potential (BAEP).

Methods

Experimental animals and grouping

Healthy male Wistar rats ($n=210$) weighing 200 ± 20 g were purchased from the Experimental Animal Center of the Third Military Medical University. The animals were assigned randomly to four groups: high-altitude injury group (HI, $n=96$), high-altitude control group (HC, $n=9$), normobaric injury group (NI, $n=96$), and normobaric control group (NC, $n=9$). Rats were examined at 1, 6, 12, 24, 48, 72, and 168 h after injury ($n=9$ at each time point). They were housed in a temperature-controlled facility ($20\pm 1^\circ\text{C}$) for at least 7 days before the experiments with a 12 h light/dark cycle during the experiments. Rats were allowed free access to food and water before and after surgery. Rats were anesthetized with an intraperitoneal injection of 2% sodium amobarbital whenever appropriate (100 mg/kg; Shanghai Chemical Reagent Co., Ltd, Shanghai, People's Republic of China). HI and NI animals were subjected to an open craniocerebral injury with a nail gun shot in the head, whereas HC and NC animals were not subjected to head trauma. All procedures were performed in accordance with the Animal Care Guidelines, conforming to the Health Guide for the Care and Use of Laboratory Animals, and approved by the Ethics Committee of The Third Military Medical University.

Preparation of animal models

Preparation of the nail gun

For this novel method, we selected a Civil F-30 J422 nail gun (Yongkang Chengxin Tools Co., Ltd, Zhejiang, People's Republic of China) as a preparation tool for rats with an open craniocerebral injury. Test pressure (0.7 MPa) and initial velocity (24.23 ± 3.53 m/s) were measured using a copper wire target chronometer (Field Surgery Research Institute of The Third Military

Medical University, Chongqing, People's Republic of China) under the working pressure.

Preparation of an animal model of NI

After depilation and disinfection, rats were placed to a stereotaxic frame. A point 15 mm posterior to the connection of the inner canthus, and 2 mm right of the midline, was used as an injury point. A nail gun was held close to the injury point on the scalp and then a nail was sent vertically downward into the brain with a working pressure of 0.7 MPa. It was removed along the wound tract immediately after injury and the aforementioned parameters were measured at each time point.

Preparation of an animal model of HI

To simulate acute hypobaric hypoxia, rats were placed in a temperature-controlled hypobaric chamber ($20\pm 1^\circ\text{C}$) (Binglun Corp., Yantai, People's Republic of China) and exposed to 0.6 ATA for 72 h (to simulate air pressure at an altitude of 4000 m). The chamber was opened twice (30 min each) a day for feeding and cleaning. Three days later, the rats received the same surgery as the NI group as described above. Animals were kept in the hypobaric chamber with 0.6 ATA after injury, and the aforementioned parameters were measured at each time point. HC animals were kept in the hypobaric chamber for 3 days, but without brain injury, and the aforementioned parameters were measured.

General status and death status

Rats were allowed access to food and drink ad libitum; diet, activity, and mortality were observed at each time point after injury, and dead animals were dissected and examined for brain anatomy.

Preparation of brain tissues for light and electron microscopy

For the preparation of histological slices, three rats from each group were reanesthetized and perfused intracardially with 4% paraformaldehyde in 0.1 M PBS. Brains were removed and immersed in 10% formaldehyde for several days at 4°C , dehydrated with ethanol gradients, vitrified with dimethylbenzene, and embedded in paraffin. Coronal sections of brain tissue (with the wound as center) were cut to a thickness of 5 μm . Each sampled section of brain tissue was collected on gelatin-formaldehyde mixture-coated slides, and hematoxylin and eosin (H&E) and toluidine blue were used for histopathological evaluations in Nissl staining according to a standard protocol.

To prepare ultrathin sections for electron microscopy, three rats were reanesthetized and killed. The cortex (3 mm from the epicenter) was removed and cut into $1\times 1\times 1$ mm samples. Then, they were immersed in 3% glutaraldehyde for 48 h. Samples were washed three times with PBS and incubated in 1% osmium tetroxide

for 2 h at 4°C. After further washing with water, the tissues were dehydrated through graded alcohols and embedded in epoxy resin. Ultrathin sections were analyzed under a transmission electron microscope (Hitachi, Ltd, Hitachi H7500; Chiyoda-ku, Tokyo, Japan).

Brain water content

BWC is the most direct and objective indicator of cerebral edema, whereas EB content is an objective quantitative index reflecting BBB damage [11]. To detect the effects of high altitude on changes in BWC and EB after the nail gun shot, we measured the BWC and EB content to perform an objective and accurate assessment of cerebral edema and BBB permeability. Six rats from each time point were reanesthetized and killed. The right cerebral hemispheres were removed and the wet weight (WW) of each hemisphere was determined using a precision electronic balance (analytical fidelity was 0.1 mg). The cerebral hemispheres were then placed in an electric oven at 80°C to achieve constant dry weight (DW) (average weighing error was <0.002 g). According to Elliot's formula, the percentage of BWC was calculated as follows: $BWC (\%) = (WW - DW) / WW \times 100\%$.

The relative content of EB in rat brains

To examine the effects of high altitude on the BBB, we evaluated permeability to EB [12]. Six rats were anesthetized and then placed in a stereotactic apparatus; a 2% EB solution was injected slowly into the caudal vein. Sixty minutes later, rats were perfused as described above, and then the tissue was fixed using a 4% paraformaldehyde solution. The optical density at an absorbance wavelength of 620 nm was determined using a multifunctional microplate reader (Thermo Fisher Scientific, Thermo Varioskan Flash, Massachusetts, American). A standard curve was used to calculate the relative EB content in each sample. The results were expressed as the relative EB content per gram WW of brain tissue.

rCBF monitoring

Tests were performed in a quiet room at 25°C ambient temperature. At each time point after injury, six rats were anesthetized and then placed in a stereotactic apparatus. As visualized through the skull window, the dura remained intact. A noninvasive laser Doppler probe (Moor DRT4, type CH1PR2; Moor Instruments, Devon, UK) was positioned over the right parietal cortex, over an area away from large pial vessels, to obtain low, stable readings [13]. rCBF on four points (3 mm to the epicenter) were monitored in each rat (10 min each point). Values were averaged for the four points.

PbtO₂ monitoring

Brain hypoxia occurs early after TBI, and PbtO₂ is closely related to the prognosis of TBI and development of cerebral edema [14]. Direct monitoring of PbtO₂ provides

independent cerebral oxygen information [15] and accurately reflects cerebral extraction of oxygen; however, little is known about the application of PbtO₂ in PBI at high elevation. To examine the effects of high altitude on cerebral oxygen after brain injury, we performed PbtO₂ monitoring in a quiet room at 25°C ambient temperature. At each scheduled time point after injury, six rats were anesthetized and placed in a stereotactic apparatus. Through the skull window, an oxygen electrode was inserted into the brain parenchyma to a depth of 12 mm (3 mm to the epicenter) and the skull hole was sealed with bone wax. PbtO₂ was monitored continuously on a LICOX CMP monitor (CC1.P1, oxygen-sensitive part diameter, 0.65 mm, oxygen-sensitive area, 18 mm²; Integra Neuroscience, Ratingen, Germany) for 60 min. To obtain reliable PbtO₂ readings, the values were averaged across the last 30 min in each rat. This is an established method for the evaluation of tissue oxygen pressure [16].

Brainstem auditory-evoked potential

After six rats were anesthetized, they were then placed in a stereotactic apparatus. BAEP was measured using a Signal Processor, Keypoint 4 type (Medtronic Inc., Minneapolis, Minnesota, USA). The audiosignals were monaural clicks with an alternative polarity, delivered at a repetition rate of 13.3/s by an earphone 2 cm from the right ear of the rat. The stimulus intensity was set at 100 dB SPL. Recording needle electrodes were placed in the subscalp at the intersection of the sagittal suture and bilateral external auditory canal. The reference electrodes were placed at the subcutaneous tissue of the mastoid. A metal clip was attached to the base of the tail as ground. The recording activities were then amplified and filtered with a bandpass between 100 and 2000 Hz. The response to 2100 stimuli was averaged in the time space of 10 ms following the stimulus. The averaged response was displayed on an oscilloscope and plotted on a graph paper using an X-Y recorder for reference. The peak latencies (PL) and interpeak latencies (IPL) were measured from a storage oscilloscope using the cursor. The recording was repeated two times and measured immediately after injury to ensure constancy of waves.

Statistical analysis

All experimental data are presented as the mean ± SEM. One-way analysis of variance was used to analyze BWC, rCBF, PbtO₂, and BAEP among the HI, NI, HC, and NC groups. Comparisons between mortality of the HI and NI groups were made using the Pearson χ^2 -test. Bivariate correlation statistical analyses were carried out to evaluate the correlation between rCBF and BWC or PbtO₂. All analyses were carried out using SPSS software, version 13.0 (SPSS Inc., Chicago, Illinois, USA). Statistical significance was defined as *P* less than 0.05.

Table 1 General status of HI and NI groups

Groups	Apnea (%)	Convulsion (%)	Limb movement disorder (%)	Primary coma (%)
NI	14.29	50.55	12.09	8.78
HI	16.48	57.14	13.19	9.89

HI, high-altitude injury group; NI, normobaric injury group.
 $P > 0.05$, versus the NI group.

Results

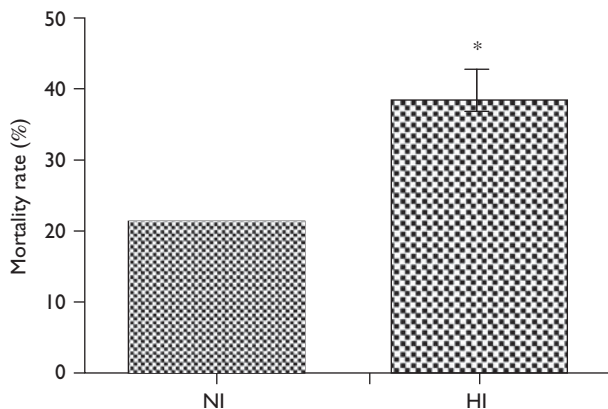
General information

The diameter of the wound tract was 1.5 mm wider than the nail gun. The nail gun could be removed easily along the wound tract because the width of the inlet and outlet of the wound tracks were the same, with no obvious foreign bodies or bone fragments. Both the HI and the NI group presented instant apnea, convulsions, limb movement disorder, and primary coma after an open craniocerebral injury (Table 1). Changes in the HI group were more serious than those in the NI group, especially 48 h after injury; however, no statistically significant difference was observed ($P > 0.05$). After 1–3 min of assisted breathing, these rats resumed spontaneous breathing.

Rats in the HI and NI groups typically died immediately or within 24 h after injury. The total mortality rate of the HI group within 72 h after injury was higher than that of the NI group (38.79 vs. 21.37%; $P < 0.05$; Fig. 1). Rats in the HC and NC groups survived well. Overall, 144 rats were used for the rest of the experiments.

Histopathological observations

Morphology and structures of the cerebral cortex were observed using light microscopy and transmission electron microscopy. The entire coronal face of the projectile of the nail is shown in Fig. 2a. Ischemic changes in brain tissues were observed 3 mm away from the lesion center

Fig. 1

Comparison of the mortality rate of the HI and NI groups. The total mortality rate of the HI group within 72 h after injury was higher than that of the NI group (* $P < 0.05$). HI, high-altitude injury group; NI, normobaric injury group.

(Fig. 2a an arrow) during the period 1–6 h after injury. A decrease in the Nissl body, mitochondrion swelling, a slight increase in the perivascular space, and edema of perivascular tissues were observed at 6 h. These changes progressed by 24–48 h (Fig. 2c, d, f, g, i and j) and began to restore 72 h after injury. The pathological changes in the HI group were more obvious compared with the NI group; however, no significant change was observed in the control group (Fig. 2).

High altitude induced an increase in brain water content after injury

BWC increased immediately at 1 h after injury, maximized between 24 and 48 h, and then began to restore at 72 h; however, it did not revert to the control level by 168 h after injury. BWC after injury in the HI group was significantly higher than that in the NI group, except at 12 and 168 h (Fig. 3a).

High altitude induced an increase in Evans blue content after injury

No blue-stained brain tissues were observed in the HC or NC group. EB particles were red under a fluorescence microscope. Exudation of EB particles was mostly observed in the HI and NI groups during the 12–24 h period after injury; there were significantly more particles in the HI group than in the NI group (Fig. 3b). The EB content increased immediately at 1 h after injury, maximized between 24 and 48 h, and then began to restore at 72 h; however, it did not revert to the control level by 168 h after injury. The EB content in the HI group after injury was markedly higher than that in the NI group at each time point (Fig. 3c).


High altitude induced a significant decrease in rCBF and an inverse correlation between rCBF and BWC was found in both HI and NI groups

In the HC group, rCBF was significantly greater than that in the NC group ($P < 0.01$, Fig. 4a). rCBF decreased at 1 h after injury, minimized between 48 and 72 h after injury, and then tended to restore, but did not revert to the control level by 168 h after injury. rCBF in the HI group after injury decreased more markedly than that in the NI group ($P < 0.05$ or $P < 0.01$ at different time points, Fig. 4a). The correlation between rCBF and BWC was inverse in both the HI and NI groups, with R -values of -0.892 and -0.941 , respectively ($P < 0.01$, Fig. 4b and c).

High altitude induced a significant decrease in PbtO₂ and a positive correlation between PbtO₂ and rCBF was found in both HI and NI groups

No significant difference was observed in PbtO₂ between the NC and HC groups. PbtO₂ decreased significantly at 1 h after injury, minimized between 24 and 48 h after injury, and then began to restore. The PbtO₂ in the HI group between 6 and 72 h after injury was significantly lower than that in the NI group ($P < 0.01$; Fig. 5a). The correlation between PbtO₂ and rCBF was positive, with

Fig. 2



Pathological changes in rat brain tissue. (a) The entire coronal face of the projectile of the nail. An arrow indicates 3 mm away from the lesion center. (b–d): H&E staining; (e–g): Nissl staining. (b, e) Normal neurons in the cerebral cortex were found in the control group. (c, f) Fewer pathological injuries occurred in the NI group 48 h after injury, arrows indicate the same meaning as in (d, g). (d, g) Neuronal swelling, nuclear condensation, a reduction in Nissl body (arrow), and conspicuous edema of interstitium are shown 3 mm away from the lesion center in the HI group 48 h after injury. Scale bars for (b–g): $\times 200$ magnification. (h) Normal blood–brain barrier. (i) Milder edema of perivascular occurred in the NI group (arrow). (j) Edema of perivascular was obviously observed 3 mm away from the lesion center 48 h after injury in the HI group (arrow). Asterisk indicates the lumen. Scale bar for transmission electron micrographs, $\times 6000$. HI, high-altitude injury group; NI, normobaric injury group.

R-values of 0.868 and 0.929, respectively ($P < 0.01$, Fig. 5b and c).

BAEP monitoring results

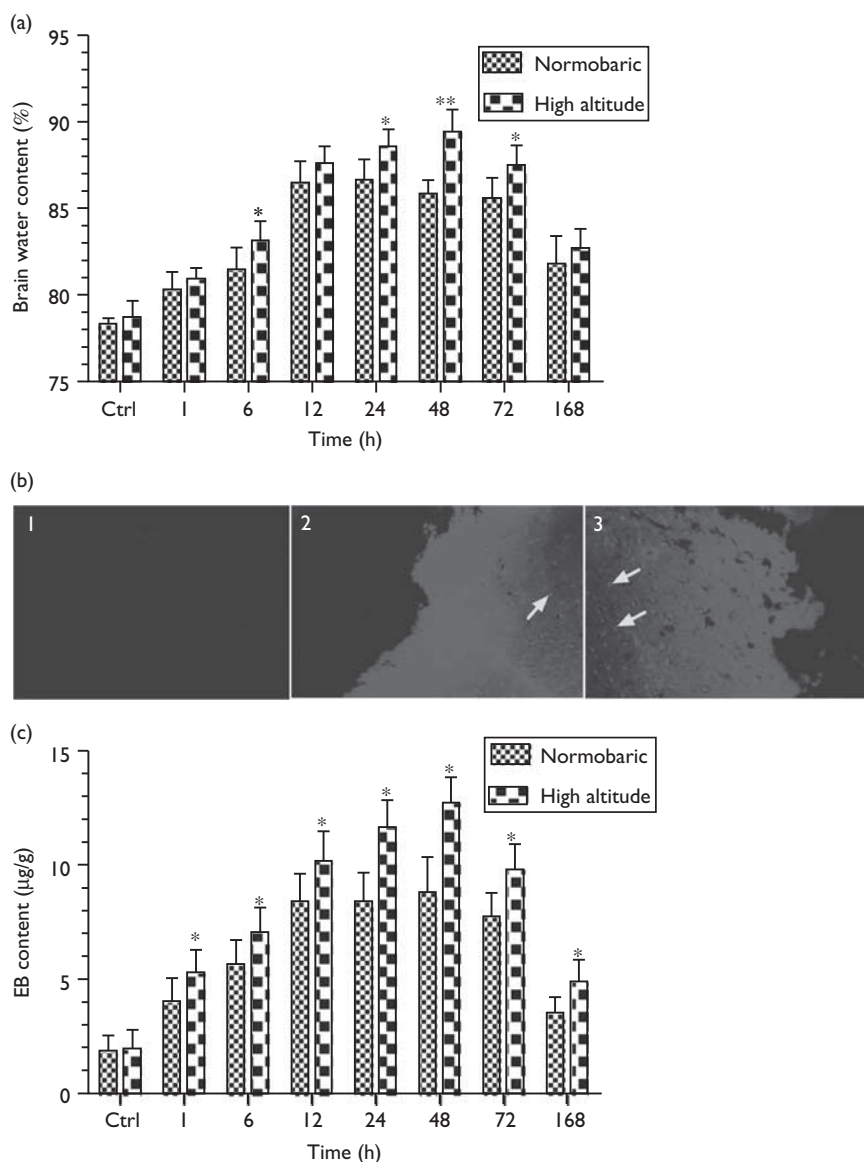
PL and IPL of each wave after injury in the HI and NI group were significantly prolonged, especially on the injured side in the HI group. PL of the I, III, and V waves and IPL extension of I–V wave were most obvious ($P < 0.05$). PL of each wave on the contralateral side had a different extension. Although the changes in the HI group

were consistent with the NI group, PL and IPL of each wave in the HI group were prolonged more significantly than those in the NI group ($P < 0.05$; Fig. 6a and b).

Discussion

To our knowledge, for the first time, we established a rat model of an open craniocerebral injury with a nail gun shot at simulated high altitude. We found an increased mortality rate in the HI group, as evidenced by increased BWC, EB content, more obvious pathological changes, decreased

Fig. 3



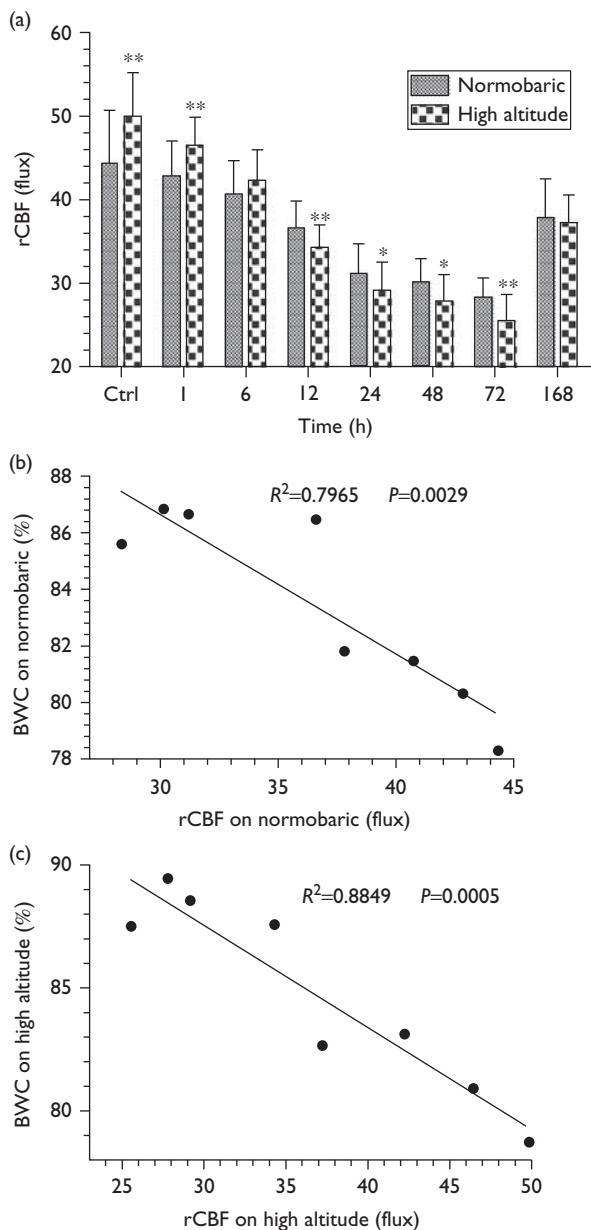
(a) A graph showing changes in brain water content $*P < 0.05$ and $**P < 0.01$ versus the NI group at the same time point. (b) EB particles shown by fluorescence microscopy. (1) No blue-stained brain tissues were observed in the control group. (2) Fewer EB particles' exudation (arrow) was observed in the NI group 12 h after injury. (3) More EB particles' exudation (arrow) was observed in the HI group 12 h after injury. (c) Quantitative analysis of changes in the EB content. $*P < 0.05$ versus the NI group at the same time point. EB, Evans blue; HI, high-altitude injury group; NI, normobaric injury group.

rCBF and $PbtO_2$, an inverse correlation between BWC and rCBF, and a positive correlation between $PbtO_2$ and rCBF.

Hypoxia is the most important factor resulting in the body's pathophysiological changes in a high-altitude environment. The incidence rate of AMS in the general tourist population is reported to be 40–50% among trekkers and climbers near 4000 m [17] and increases to more than 90% when an ascent to ~4000 m occurs over a number of hours rather than days [18]. Because rodents are somewhat less susceptible to hypoxia than humans at

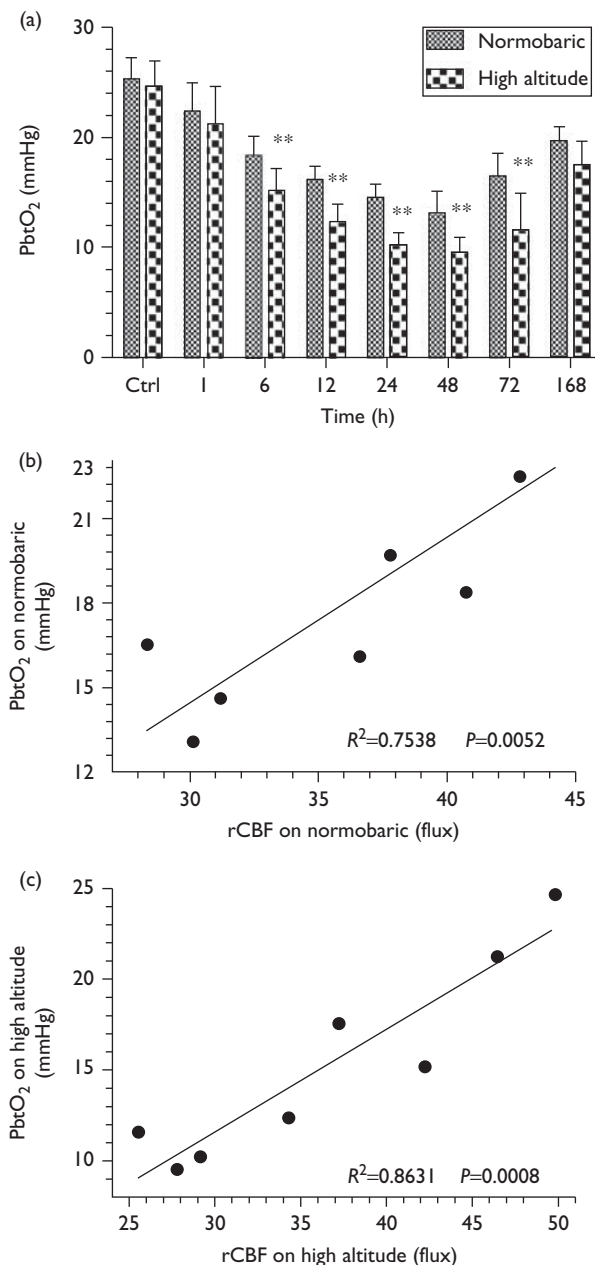
the same altitude, the altitude of 4000 m was chosen as a simulated high altitude for the model rats in this study. Although the physiology of animals with a large size is closer to humans, rodents are mostly used in TBI research owing to their modest cost, small size, and standardized outcome, and thus we chose wistar rats as experimental animals. Hypobaric chambers simulate high altitude with good controllability, low cost, and hypoxic conditions consistent with altitude. For the present study, rats were kept in a hypobaric chamber with a 0.6 ATA pressure for three days to simulate acute

Fig. 4



(a) Changes in rCBF (flux) * $P < 0.05$ and ** $P < 0.01$ versus reciprocal NI group at the same test point. (b) Inverse correlation between rCBF and BWC in the NI group, $R = -0.892$, $P < 0.01$. (c) Inverse correlation between rCBF and BWC in the HI group. $R = -0.941$, $P < 0.01$. BWC, brain water content; HI, high-altitude injury group; NI, normobaric injury group; rCBF, regional cerebral blood flow.

Fig. 5



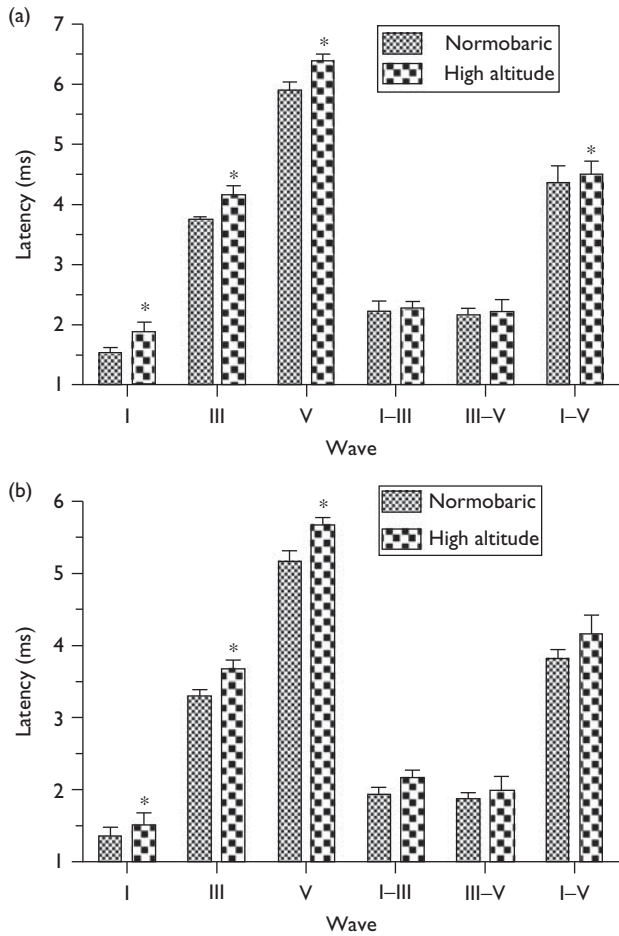
(a) Comparison of changes in PbtO₂ in the normobaric and high-altitude groups (mmHg, $x \pm s$). ** $P < 0.01$ versus the NI group at the same time point. (b) Positive correlation between PbtO₂ and rCBF in the NI group, $R = 0.868$, $P < 0.01$. (c) Positive correlation between PbtO₂ and rCBF in the HI group. $R = 0.929$, $P < 0.01$. HI, high-altitude injury group; NI, normobaric injury group; PbtO₂, partial pressure of brain tissue oxygen; rCBF, regional cerebral blood flow.

hypobaric hypoxia. The PBI model at high altitude was established successfully using this method.

Previous results of animal models of penetrating ballistic brain injury [6,19] showed that these models had a short survival time after trauma, injuries that were difficult to control, complex modeling, and variations between these and actual war wounds. Therefore, here, we used a nail

gun as an injury device because of its dynamic parameter stability, easy operation, and controllability by choosing a suitable size relative to the rat skull. Moreover, the velocity of the nail gun is constant because of low-velocity and low-energy projectiles. Rats suffered from brain damage by penetrating from the parietal to the base

Fig. 6



(a) Comparison of ipsilateral BAEP in the NI and HI groups. (b) Contralateral BAEP comparison in the NI and HI groups. * $P < 0.05$ versus the NI group at the same time point. BAEP, brainstem auditory-evoked potential; HI, high-altitude injury group; NI, normobaric injury group.

of the skull. The injured site could be controlled accurately, the wound tract was consistent between individuals, no foreign bodies and bone fragments remained, and the infection rate was low. Moreover, our results showed that HI induced more serious instant apnea after injury and convulsion than NI; however, the differences were not statistically significant. The mortality rate of the HI group within 72 h was significantly greater than that of the NI group, and death mainly occurred immediately and within 24 h after injury. The major cause of death was because of bleeding of the wound tract and central respiratory circulatory failure induced by primary brain injury. These findings suggest that the nail gun shot model can be applied to simulate PBI.

Soon after TBI, early BBB permeability increases, which is the leading cause of brain edema formation [20]. In the present study, we showed that the degree, amplitude,

and duration of increased BWC and EB content in the HI group were significantly higher than those in the NI group. These changes were consistent with the pathological changes, suggesting that acute hypoxic exposure combined with PBI increased BBB permeability, resulting in greater BWC and structural damage of neurons, which subsequently promoted the formation of edema. The results are similar to the changes observed in human brain tissue after rapid ascent to high altitude [21]. Therefore, early prevention of cerebral edema is critical in the treatment of PBI at high altitude.

In this study, exposure to high-altitude conditions during 72 h after injury induced significantly lower $PbtO_2$. $PbtO_2$ was correlated inversely with BWC, indicating that $PbtO_2$ monitoring after PBI may accurately reflect the severity of injury. In the progression of PBI at high altitude, hypoxia exerted obvious effects on $PbtO_2$, whereas cerebral ischemia and hypoxia were the final common pathways of secondary brain damage; therefore, early and continuous $PbtO_2$ monitoring is important for the treatment of PBI at high altitude.

Maintaining good brain tissue oxygen supply depends on the adequate CBF and normal arterial oxygen content. In the present study, we showed that high altitude decreased rCBF markedly. It has been shown previously that rCBF reduction in early TBI may accurately reflect the severity of injury [22], and the changes of rCBF under plateau hypoxia are sensitive and closely related to the development of brain edema after TBI [23]. It is also worthwhile to note that rCBF in the HC group increased significantly more than that in the NC group. Although $PbtO_2$ did not show such a significant difference, it is possible that increased CBF after high-altitude stimulation resulted from compensatory expansion of the cerebral blood vessels caused by hypoxia at elevation. In addition, rCBF was correlated positively with $PbtO_2$, but correlated inversely with BWC, suggesting that decreased rCBF may be the cause of the decrease in $PbtO_2$. A reduction in $PbtO_2$ could further worsen cerebral edema of the injury zone and leads to a further decrease in rCBF. Our results are consistent with a previous study showing a synergistic role between $PbtO_2$ and rCBF in the development of TBI [24]. Thus, to ensure optimal rCBF and normal cerebrovascular autoregulation, early and continuous monitoring of rCBF and $PbtO_2$ has significant value in the diagnosis and treatment of PBI, especially for the treatment of PBI at high elevation.

Here, we also showed that high altitude induced significantly prolonged PL and IPL of each wave after injury, especially the III/V wave PL and I-V wave IPL extension on the injured side. Injury was consistent with a penetrating injury from the parietal to the skull base, whereas PL of the I wave extended to the injured side, indicating that the auditory nerve of the injured side was

also affected. The PL of each wave with different extension on the contralateral side might have been caused by cerebral edema spreading to the contralateral side. The changes in the HI group were consistent with the NI group after injury, but PL and IPL of each wave in high altitude were prolonged more significantly than those in the NI group. It is known that BAEP is a reliable indicator of nerve function, brain-stem damage, and prognosis after TBI [25]. Our results suggest that brain stem and cerebral nerve function had been severely damaged immediately after the nail gun shot, and high-elevation hypoxia aggravated this damage.

In the current study, the PBI model was stable, reproducible, suitable for large quantities and longer experimental observations, and better reflected the injury characteristics of PBI at high elevation; however, the model has certain limitations with respect to war wounds. If we can use large animals and a comprehensive analysis of field experiments at high elevation, the treatment of PBI could be more meaningful.

In summary, we successfully established a rat model of PBI for the first time at simulated high altitude. We observed dynamic changes in BWC, EB content, PbtO₂, rCBF, and pathology and their close correlation at high elevation. Thus, accurate and early detection of local cerebral ischemia and hypoxia by PbtO₂ and rCBF monitoring would provide strong evidence for early diagnosis and treatment of PBI.

Acknowledgements

This study was supported by the Sci & Tech Research Project of the 'Eleventh Five-year Plan' for Medical Science Development of PLA (08G087), the Sci & Tech Research Project of the 'Twelfth Five-year Plan' for Medical Science Development of PLA (AWS11J008), the National Natural Science Foundation of China (No. 81471261) and Health Sector Public Welfare fund of China grant 200802093.

Conflicts of interest

There are no conflicts of interest.

References

- Kazim SF, Shamim MS, Tahir MZ, Enam SA, Waheed S. Management of penetrating brain injury. *J Emerg Trauma Shock* 2011; **4**:395–402.
- Weisbrod AB, Rodriguez C, Bell R, Neal C, Armonda R, Dorlac W, et al. Long-term outcomes of combat casualties sustaining penetrating traumatic brain injury. *J Trauma Acute Care Surg* 2012; **73**:1525–1530.
- Hoge CW, McGurk D, Thomas JL, Cox AL, Engel CC, Castro CA. Mild traumatic brain injury in U.S. soldiers returning from Iraq. *N Engl J Med* 2008; **358**:453–463.
- Defense and Veterans Brain Injury Center. <http://www.dvbic.org/TBI-numbers>. [Accessed 25 June 2012].
- Wani AA, Ramzan AU, Dar TI, Malik NK, Khan AQ, Wani MA, et al. Management dilemma in penetrating head injuries in comatose patients: scenario in underdeveloped countries. *Surg Neurol Int* 2012; **3**:89.
- Williams AJ, Hartings JA, Lu XC, Rolli ML, Dave JR, Tortella FC. Characterization of a new rat model of penetrating ballistic brain injury. *J Neurotrauma* 2005; **22**:313–331.
- Plantman S, Ng KC, Lu J, Davidsson J, Risling M. Characterization of a novel rat model of penetrating traumatic brain injury. *J Neurotrauma* 2012; **29**:1219–1232.
- Clarke C. Acute mountain sickness: medical problems associated with acute and subacute exposure to hypobaric hypoxia. *Postgrad Med J* 2006; **82**:748–753.
- Basnyat B, Murdoch DR. High-altitude illness. *Lancet* 2003; **361**:1967–1974.
- Xiong Y, Mahmood A, Chopp M. Animal models of traumatic brain injury. *Nat Rev Neurosci* 2013; **14**:128–142.
- Cevik NG, Orhan N, Yilmaz CU, Arican N, Ahishali B, Kucuk M, et al. The effects of hyperbaric air and hyperbaric oxygen on blood-brain barrier integrity in rats. *Brain Res* 2013; **1531**:113–121.
- Durukan Tolvanen A, Westberg JA, Serlachius M, Chang AC, Reddel RR, Andersson LC, Tatlisumak T. Stanniocalcin 1 is important for poststroke functionality, but dispensable for ischemic tolerance. *Neuroscience* 2013; **229**:49–54.
- Pettigrew LC, Kindy MS, Scheff S, Springer JE, Kryscio RJ, Li Y, Grass DS. Focal cerebral ischemia in the TNFalpha-transgenic rat. *J Neuroinflammation* 2008; **5**:47.
- Ostergaard L, Aamand R, Karabegovic S, Tietze A, Blicher JU, Mikkelsen IK, et al. The role of the microcirculation in delayed cerebral ischemia and chronic degenerative changes after subarachnoid hemorrhage. *J Cereb Blood Flow Metab* 2013; **33**:1825–1837.
- Kirkness CJ, Thompson HJ. Brain tissue oxygen monitoring in traumatic brain injury: cornerstone of care or another brick in the wall? *Crit Care Med* 2009; **37**:371–372.
- Akça O, Melischek M, Scheck T, Hellwagner K, Arkilic CF, Kurz A, et al. Postoperative pain and subcutaneous oxygen tension. *Lancet* 1999; **354**:41–42.
- Hackett PH, Rennie D, Levine HD. The incidence, importance, and prophylaxis of acute mountain sickness. *Lancet* 1976; **2**:1149–1155.
- Leadbetter G, Keyes LE, Maakestad KM, Olson S, Tissot van Patot MC, Hackett PH. *Ginkgo biloba* does – and does not – prevent acute mountain sickness. *Wilderness Environ Med* 2009; **20**:66–71.
- Shear DA, Lu XC, Pedersen R, Wei G, Chen Z, Davis A, et al. Severity profile of penetrating ballistic-like brain injury on neurofunctional outcome, blood-brain barrier permeability, and brain edema formation. *J Neurotrauma* 2011; **28**:2185–2195.
- Pillai DR, Dittmar MS, Baldaranov D, Heidemann RM, Henning EC, Schuierer G, et al. Cerebral ischemia-reperfusion injury in rats—a 3 T MRI study on biphasic blood-brain barrier opening and the dynamics of edema formation. *J Cereb Blood Flow Metab* 2009; **29**:1846–1855.
- Bailey DM, Bärtsch P, Knauth M, Baumgartner RW. Emerging concepts in acute mountain sickness and high-altitude cerebral edema: from the molecular to the morphological. *Cell Mol Life Sci* 2009; **66**:3583–3594.
- Liu H, Goodman JC, Robertson CS. The effects of L-arginine on cerebral hemodynamics after controlled cortical impact injury in the mouse. *J Neurotrauma* 2002; **19**:327–334.
- Hu S, Li F, Luo H, Xia Y, Zhang J, Hu R, et al. Amelioration of rCBF and PbtO₂ following TBI at high altitude by hyperbaric oxygen pre-conditioning. *Neurol Res* 2010; **32**:173–178.
- Figaji AA, Zwane E, Fieggen AG, Argent AC, Le Roux PD, Siesjo P, Peter JC. Pressure autoregulation, intracranial pressure, and brain tissue oxygenation in children with severe traumatic brain injury. *J Neurosurg Pediatr* 2009; **4**:420–428.
- Lew HL, Lee EH, Miyoshi Y, Chang DG, Date ES, Jerger JF. Brainstem auditory-evoked potentials as an objective tool for evaluating hearing dysfunction in traumatic brain injury. *Am J Phys Med Rehabil* 2004; **83**:210–215.