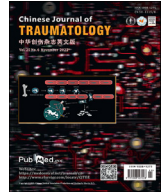



Contents lists available at ScienceDirect

## Chinese Journal of Traumatology

journal homepage: <http://www.elsevier.com/locate/CJTEE>

## Case Report

## Emergency repair of blunt traumatic bronchus injury presenting with massive air leak

Jun Sen Chuah<sup>\*</sup>, Zhun Ming Raymond Lim, Ee Peng Lee, Jih Huei Tan, Yuzaidi Mohamad, Rizal Imran Alwi

Trauma Surgery Unit, Department of General Surgery, Hospital Sultanah Aminah, Ministry of Health Malaysia, Johor Bahru, Malaysia

## ARTICLE INFO

## Article history:

Received 25 April 2021

Received in revised form

30 October 2021

Accepted 26 November 2021

Available online 22 December 2021

## Keywords:

Blunt chest trauma

Bronchus injury

Bronchoscopy

Thoracotomy

## ABSTRACT

Blunt traumatic tracheobronchial injury is rare, but can be potentially life-threatening. It accounts for only 0.5%–2% of all trauma cases. Patients may present with non-specific signs and symptoms, requiring a high index of suspicion with accurate diagnosis and prompt treatment. A 26-year-old female was brought into the emergency department after sustained a blunt trauma to the chest from a high impact motor vehicle accident. She presented with signs of respiratory distress and extensive subcutaneous emphysema from the chest up to the neck. Her airway was secured and chest drain was inserted for right sided pneumothorax. CT of the neck and thorax revealed a collapsed right middle lung lobe with a massive pneumothorax, raising the suspicion of a right middle lobe bronchus injury. Diagnosis was confirmed by bronchoscopy. In view of the difficulty in maintaining her ventilation and persistent pneumothorax with a massive air leak, immediate right thoracotomy via posterolateral approach was performed. The right middle lobar bronchus tear was repaired. There were no intra- or post-operative complications. She made an uneventful recovery. She was asymptomatic at her first month follow-up. A repeated chest X-ray showed expanded lungs. Details of the case including clinical presentation, imaging and management were discussed with an emphasis on the early uses of bronchoscopy in case of suspected blunt traumatic tracheobronchial injury. A review of the current literature of tracheobronchial injury management was presented.

© 2021 Chinese Medical Association. Production and hosting by Elsevier B.V. This is an open access article under the CC BY-NC-ND license (<http://creativecommons.org/licenses/by-nc-nd/4.0/>).

## Introduction

Blunt traumatic tracheobronchial injury is rare, accounting for only 0.5%–2% of all trauma cases.<sup>1</sup> It can be potentially life-threatening and associated with significant morbidity and mortality. Generally, 30%–80% of these patients succumb to death at the moment of injury, due to tension pneumothorax, asphyxiation or concomitant great vessels or cardiac injuries.<sup>2</sup> With the advancement of prehospital care, the survival rate of patients with traumatic tracheobronchial injury improved in recent years. However, the fatality rate for patients who receive hospital care remains high as a result of failed prompt recognition or delay in treatment. A high index of suspicion is required to prevent mortality or late complication of traumatic tracheobronchial injury. Here, we present a case of right middle lobar injury after a blunt chest trauma, which was successfully repaired via posterolateral right

thoracotomy at a trauma center. Liberal use of bronchoscopy in the case of high suspicion of traumatic tracheobronchial injury was emphasized.

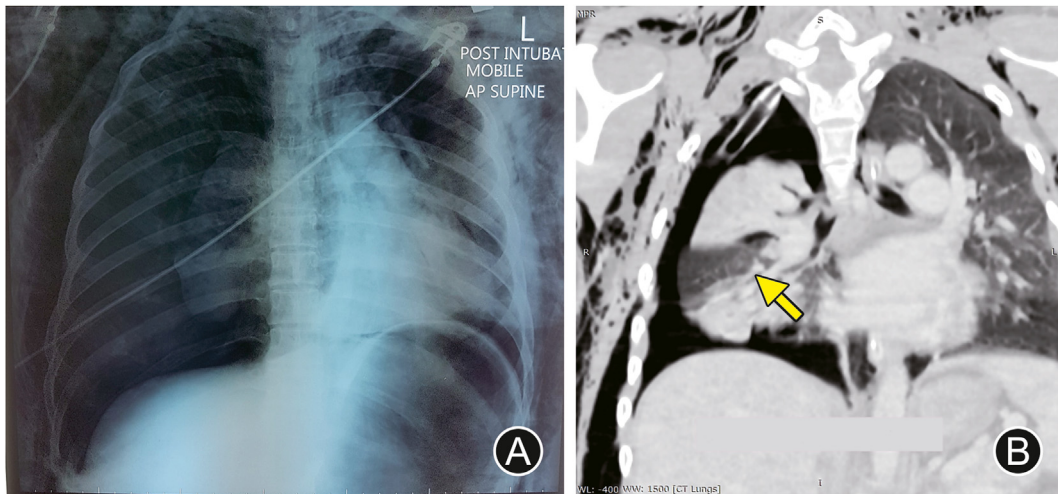
## Case report

A 26-year-old female was brought into the emergency department after sustained a blunt trauma to the chest from a high impact motor vehicle accident. Upon admission to the emergency department, her Glasgow coma score was 15, normotensive with a heart rate of 110 beats/min. She was in respiratory distress with a respiratory rate of 40 breaths/min. Physical examination revealed bruises over her upper chest and extensive subcutaneous emphysema over the face, neck and upper chest. There was reduced air entry upon lung auscultation. No other associated injury was found. She was intubated and stabilized according to advanced trauma life support protocol. A chest X-ray demonstrated right 1st to 6th ribs fractures, right pneumothorax with lung collapsed, and extensive bilateral subcutaneous emphysema (Fig. 1). Chest drain was inserted immediately. Persistent pneumothorax with poor lung

<sup>\*</sup> Corresponding author.

E-mail address: [Vincentchuahjs@gmail.com](mailto:Vincentchuahjs@gmail.com) (J.S. Chuah).

Peer review under responsibility of Chinese Medical Association.



**Fig. 1.** (A) Chest X-ray showed right pneumothorax with lung collapsed, extensive subcutaneous emphysema and multiple right ribs fracture; (B) CT scan revealed a collapsed right middle lung lobe with a massive pneumothorax (arrowed).

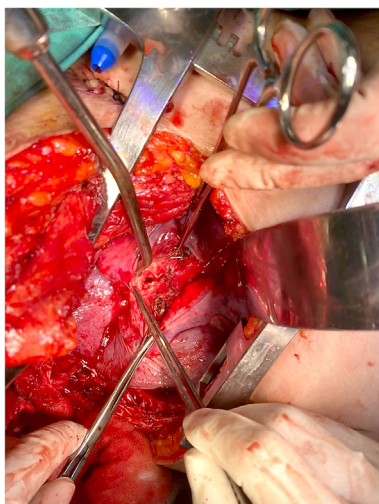
expansion was noted despite of chest tubes insertion. An urgent CT scan of the neck and thorax was performed, which revealed a collapsed right middle lung lobe with a massive pneumothorax, raising the suspicion of a right middle lobe bronchus injury (Fig. 1). She was admitted to intensive care unit (ICU) for close monitoring.

Immediate bronchoscopy confirmed the presence of a right middle lobar bronchus tear and a bronchus lumen collapse (Supplementary Fig). There was difficulty in maintaining her ventilation and persistent pneumothorax with a massive air leak. An emergency right thoracotomy via the posterolateral approach was performed by a trauma surgeon. The right middle lobar bronchus was partially transected with a major air leak (Fig. 2). Both the proximal and distal end of the injured bronchus were mobilized and primary anastomosis was performed. The lung re-expanded post-surgical was repaired (Fig. 3). There were no intra- or post-operative complications. She made an uneventful recovery and was discharged at day 10 post-surgery. She was well and asymptomatic at her first month follow-up. A repeated chest X-ray showed expanded lungs.

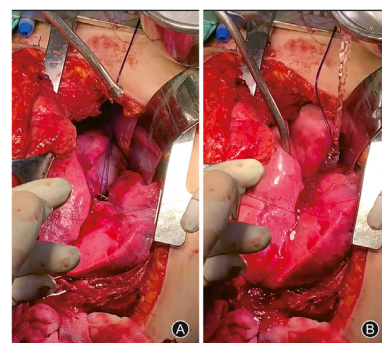
### Discussion

Incidence of traumatic tracheobronchial injury is rare and it carries a high mortality rate. A few mechanisms proposed for traumatic tracheobronchial injury in blunt chest trauma were described, including forceful anteroposterior compression of the chest, and shear forces at points of relative fixed airway during rapid deceleration or elevation of intratrachea/airway pressure.<sup>3</sup> Distal trachea, carina, and proximal main bronchus are common sites of injury in blunt traumatic tracheobronchial injury, while only 16% of blunt traumatic tracheobronchial injury occurs in lobar bronchi, as presented here.<sup>4</sup> The larger the tear, together with the more proximal involvement of the airways, more overt symptoms and signs of dyspnea, respiratory failure, hoarseness or hemoptysis, pneumothorax, pneumomediastinum and subcutaneous emphysema will present. The current case had the typical presentations of bilateral pneumothorax, subcutaneous emphysema and respiratory compromise, despite only the involvement of the lobar bronchi.

Chest X-ray is helpful in the initial step of diagnosis. Subcutaneous emphysema (35%–85%), pneumomediastinum (60%) and pneumothorax (20%–50%) can be found by chest X-ray.<sup>5</sup> Notably, a normal chest radiograph does not exclude traumatic tracheobronchial injury, especially if the injury has not extended beyond the peri-tracheal or peri-bronchial connective tissue. Spontaneous sealing of minor tear secondary to fibrin formation may also conceal such injury on a chest radiograph.<sup>6</sup> Persistent



**Fig. 2.** Transected right median lobar bronchus.



**Fig. 3.** Surgical repair of right median lobar bronchus was done. (A) Lung collapsed prior inflation of air; (B) Lung re-expanded after inflation of air.

pneumothorax post-thoracostomy with excessive air leak should raise the suspicion of traumatic tracheobronchial injury, as in the presented case.

While the sensitivity of CT thorax and neck in diagnosing traumatic tracheobronchial injury is unknown, contextual evidence with the presence of major vessels injury, subtle pneumothorax, mediastinal hematoma or pneumomediastinum on CT are valuable clues of possible traumatic tracheobronchial injury.<sup>7</sup> Bronchoscopy remains to be the gold standard for diagnosing traumatic tracheobronchial injury with direct visual assessment of the tracheobronchial tree and the extent of the injury. Besides, bronchoscopy also helps to secure the airway via endobronchial intubation, whereby the cuff of the endotracheal tube can be positioned beyond the level of injury prior to inflation. Early use of bronchoscopy with prompt intervention has been demonstrated to improve traumatic tracheobronchial injury patients' outcome.<sup>8</sup> In the current case, we performed a bronchoscopy at the ICU when the ventilation was compromised. It was not performed in the trauma bay due to resource constraints, and the patient ventilation was initially stable. Hence, the CT scan was initially arranged, followed by ICU admission. Nevertheless, the time from admission to bronchoscopy was less than 4 h.

Management of traumatic tracheobronchial injury varies from conservative watchful waiting, primary repair, reconstruction or lung resection. The choices of treatment should be individualized. In the event that the airway can be secured, the treatment of traumatic tracheobronchial injury can be delayed until the patient is stabilized. Non-operative management is feasible in selective patients with strict and active surveillance bronchoscopy to assess the development of granulation tissue. Non-operative management may result in stenosis in a later stage, which requires further airway dilatation or surgery correction.<sup>6</sup> Surgical repair is indicated in the case of difficulty in securing the airway, difficulty in maintaining ventilation, massive air leak, and mediastinal infections.<sup>6</sup> Patients with early definitive airway repair have shown a better long-term outcome in over 90% of patients.<sup>1</sup> The majority of reported series often do not warrant an acute procedure. The current case developed acute deterioration of ventilation, despite of a distal injury at the lobar bronchi rather than the main bronchus. This highlights the importance of intensive monitoring with immediate availability of operation room for emergency thoracotomy in any severe blunt traumatic tracheobronchial injury.<sup>9</sup> As the repair procedure was performed early, the patient had an uncomplicated recovery and no delayed complications. The risk of surgical complications such as anastomotic dehiscence or stricture have been reported to be reduced from 28.6% to 4.8% if repair is performed early.<sup>10</sup>

In current case, the patient had severe hypoxia due to massive air leak. This led to the early surgical intervention. Other circumstance of severe hypoxia is reported in severe tracheal injury where oral intubation is difficult, tracheostomy tube can be inserted directly to the cervical wound to provide definitive airway. Conversely, severe lung parenchymal injury would result in severe hypoxia despite minor traumatic tracheobronchial injury. In this case with high ventilatory setting, extracorporeal membrane oxygenation maybe be considered. Extracorporeal membrane oxygenation also act as a bridge following definitive airway repair especially when the required airway pressure is extreme high.<sup>6,9</sup> Despite severe traumatic tracheobronchial injury, majority have only minor hemoptysis similar to current case. However, it can also present with massive hemoptysis if there is bronchial artery injury or tracheal fistula with high mortality.<sup>11</sup>

Traumatic tracheobronchial injury should be suspected in all patients who suffer from blunt chest trauma. Bronchoscopy is the

gold standard, which aids in confirming the diagnosis, and assessing the extent and location of injury. Availability of bronchoscopy, intensivist and surgeon are essential for this case. When there is massive air leak due to bronchial injury, prompt recognition and early surgical intervention serve the best outcome with uncomplicated recovery.

## Funding

Nil.

## Ethical statement

Written informed consent was obtained from the patient for publication of this case report and accompanying images.

## Declaration of competing interest

The authors declare that they have no conflict of interest.

## Acknowledgements

The authors thank all the efforts provided by the trauma surgery unit and ICU team from Hospital Sultanah Aminah, Johor Bahru.

## Author contributions

All authors were actively involved in direct patient care and have read and approved the final manuscript. Chuah Jun Sen is the principal author. Rizal Imran Alwi and Yuzaidi Mohamad are the surgeons who did the surgery for the patient. Raymond Lim Zhun Ming, Lee Ee Peng and Tan Jih Huei were involved in data collection, proofread and revised the manuscript.

## Appendix A. Supplementary data

Supplementary data to this article can be found online at <https://doi.org/10.1016/j.cjtee.2021.12.007>.

## References

1. Karmy-Jones R, Wood DE. Traumatic injury to the trachea and bronchus. *Thorac Surg Clin*. 2007;17:35–46. <https://doi.org/10.1016/j.thorsurg.2007.03.005>.
2. Welter S, Essaleh W. Management of tracheobronchial injuries. *J Thorac Dis*. 2020;12:6143–6151. <https://doi.org/10.21037/jtd-2019-as-05>.
3. Kirsh MM, Orringer MB, Behrendt DM, et al. Management of tracheobronchial disruption secondary to nonpenetrating trauma. *Ann Thorac Surg*. 1976;22:93–101. [https://doi.org/10.1016/s0003-4975\(10\)63961-6](https://doi.org/10.1016/s0003-4975(10)63961-6).
4. Symbas PN, Justicz AG, Ricketts RR. Rupture of the airways from blunt trauma: treatment of complex injuries. *Ann Thorac Surg*. 1992;54:177–183. [https://doi.org/10.1016/0003-4975\(92\)91177-b](https://doi.org/10.1016/0003-4975(92)91177-b).
5. Altinok T, Can A. Management of tracheobronchial injuries. *Eurasian J Med*. 2014;46:209–215. <https://doi.org/10.5152/eajm.2014.42>.
6. Ak AK, Anjum F. *Tracheobronchial Tear*. StatPearls Internet; 2021. <http://www.ncbi.nlm.nih.gov/books/NBK560900/>.
7. Moser JB, Stefanidis K, Vlahos I. Imaging evaluation of tracheobronchial injuries. *Radiographics*. 2020;40:515–528. <https://doi.org/10.1148/rg.2020190171>.
8. Huei TJ, Lip HTC, Rahmat O. Major tracheobronchial injuries: management of two rare cases. *Med J Malaysia*. 2018;73:177–179.
9. Van Roozendaal LM, van Gool MH, Sprooten RTM, et al. Surgical treatment of bronchial rupture in blunt chest trauma: a review of literature. *J Thorac Dis*. 2018;10:5576–5583. <https://doi.org/10.21037/jtd.2018.08.22>.
10. Abdelmohty H, Elanwar MA, Abdelgawad BM. Urgent surgical repair is pivotal in the management of major airway injury due to blunt trauma. *Cardiothorac Surg*. 2020;28:21. <https://doi.org/10.1186/s43057-020-00031-2>.
11. Zhao Z, Zhang T, Yin X, et al. Update on the diagnosis and treatment of tracheal and bronchial injury. *J Thorac Dis*. 2017;9:E50–E56. <https://doi.org/10.21037/jtd.2017.01.19>.