

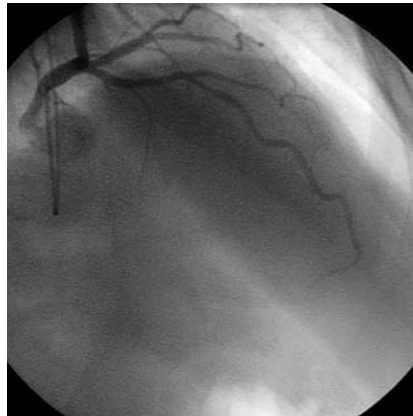
Angina, “Normal” Coronary Angiography, and Vascular Dysfunction: Risk Assessment Strategies

Raffaele Bugiardini*, Lina Badimon, Peter Collins, Raimund Erbel, Kim Fox, Christian Hamm, Fausto Pinto, Annika Rosengren, Christodoulos Stefanadis, Lars Wallentin, Frans Van de Werf

Chest pain may be associated with coronary arteries that appear “normal.” Normal is defined here as no visible disease or luminal irregularities (less than 50%) as judged visually at coronary angiography. Normal angiography in patients with chest pain is five times more common in women than in men [1]. Among patients with chest pain and normal angiography, an unknown number are suffering from cardiac pain of ischemic origin. Uncertainty is often difficult to allay, for medical attendants as well as for patients, resulting in perpetuation of symptoms, difficulties in management, and establishment of risk of subsequent coronary events [2]. In this article, we discuss how to stratify risk in patients with chest pain and a normal coronary angiogram. We based our article on a literature review, using the key words “angina with normal angiography,” “angina with normal coronary arteries,” “non-obstructive coronary disease,” or “chest pain of non-cardiac origin,” plus “[a]etiology,” “pathophysiology,” “diagnosis,” “classification,” “prognosis,” or “therapy.” A longer, more detailed version of this paper is found in the supplementary file S1.

Definition

Over the past ten years, many terms have been proposed to label patients suffering chest pain due to myocardial ischemia despite normal coronary angiography, including syndrome X [3], microvascular angina [4], and non-atherosclerotic myocardial ischemia [5]. The term syndrome X refers only to patients showing ST-segment depression on an exercise



doi:10.1371/journal.pmed.0040012.g001

Figure 1. Normal Coronary Angiogram in a Patient with Chest Pain

electrocardiogram (ECG) with completely smooth coronary arteries at angiography. More recently it has come to be used also for the metabolic syndrome, comprising hypertension, insulin resistance, elevated triglycerides, low levels of high-density-lipoproteins, and obesity. The term microvascular angina may have outlived

its usefulness, because patients with chest pain and normal angiography often exhibit a disorder not only of the coronary microcirculation, but also of the entire coronary artery and peripheral circulation [6,7].

Mechanisms

The idea that some forms of ischemic heart disease may be caused by abnormalities of the microcirculatory vessels is not new. This idea was proposed 16 years ago as a cause of angina pectoris [4]. Although the importance of microcirculation for the regulation of coronary blood flow has become clearer, pathophysiological explanations of the disease process are still poorly understood.

Vascular dysfunction. Abnormality of both endothelium-dependent and independent vasodilatation due to early atheroma may be a cause of vascular dysfunction [7–11].

A normally functioning vascular endothelium is required for appropriate dilatation of arteries during exercise [12]. Endothelial

Funding: The authors received no specific funding for this article.

Competing Interests: PC has received honoraria for speaking for and advising the following pharmaceutical companies: Eli Lilly, Schering, Organon, Merck, Pfizer, AstraZeneca, Wyeth, and Novo Nordisk. All other authors declare that they have no competing interests.

Citation: Bugiardini R, Badimon L, Collins P, Erbel R, Fox K, et al. (2007) Angina, “normal” coronary angiography, and vascular dysfunction: Risk assessment strategies. *PLoS Med* 4(2): e12. doi:10.1371/journal.pmed.0040012

Copyright: © 2007 Bugiardini et al. This is an open-access article distributed under the terms of the Creative Commons Attribution License, which permits unrestricted use, distribution, and reproduction in any medium, provided the original author and source are credited.

Abbreviations: CAD, coronary artery disease; ECG, electrocardiogram; IVUS, intravascular ultrasound; SPECT, single photon emission computed tomography; TIMI, Thrombolysis in Myocardial Infarction

Raffaele Bugiardini is in the Department of Internal Medicine, Cardio-Angiology and Hepatology, University of Bologna, Bologna, Italy. Lina Badimon is at the Cardiovascular Research Center, CSIC-ICC, Hospital de la Santa Creu i Sant Pau, Barcelona, Spain. Peter Collins and Kim Fox are in the Department of Cardiac Medicine, National Heart and Lung Institute and Royal Brompton Hospital, Imperial College London, London, United Kingdom. Raimund Erbel is in the Department of Cardiology, Essen University Clinic, Essen, Germany. Christian Hamm is in the Department of Cardiology, Kerckhoff Heart Center, Bad Nauheim, Germany. Fausto Pinto is in the Department of Cardiology, University Hospital Sta Maria, Lisbon, Portugal. Annika Rosengren is in the Department of Medicine, Sahlgrenska University Hospital/Ostra, Goteborg, Sweden. Christodoulos Stefanadis is in the Department of Cardiology, Athens University Medical School, Hippokraton Hospital, Athens, Greece. Lars Wallentin is at Uppsala Clinical Research Center, University Hospital, Uppsala, Sweden. Frans Van de Werf is at the University of Leuven, Leuven, Belgium.

* To whom correspondence should be addressed. E-mail: raffaele.bugiardini@unibo.it

The Policy Forum allows health policy makers around the world to discuss challenges and opportunities for improving health care in their societies.

dysfunction could underlie a nonspecific enhancement of the response to all vasoconstrictor stimuli [9]. Impairment of endothelium-dependent dilatation shifts a net dilator response to sympathetic stimulation to a net constrictor response [10].

“Occult” atherosclerosis. Recent pathophysiological studies show that the current concept of myocardial ischemia induced by epicardial coronary functional or fixed luminal narrowing should be renewed. Acute coronary syndromes often result from disruption of modestly stenotic plaques, not detectable by angiography, but only by intravascular ultrasound [13–15]. Plaque rupture and erosion often leads to thrombotic complications [14], or occasionally plaques may rupture and debris may be washed downstream, leading to peripheral coronary microembolization often associated with rhythm abnormalities [16]. Disturbed microvascular integrity could therefore be due to “hidden” epicardial atherosclerosis and its complications.

Prognosis

The prognosis of patients with chest pain and normal or near normal coronary arteries at angiography is not as benign as reported by preliminary cohort studies. Many such patients are at an increased risk of myocardial infarction and cardiac death. In fact, 2% of patients—men and women—with unstable angina and non-ST-segment elevation (and normal or near normal coronary arteries at angiography) die within one year of their admission [17].

The risk is not invariably high and the Thrombolysis in Myocardial Infarction (TIMI) Risk Score helps to estimate risk. The rate of death or non-fatal myocardial infarction climbs from 0.6% in patients with a TIMI score of 1, to 4.1% in those with a score of 4 or more. Adverse outcomes may also occur in less acute clinical conditions. The combined risk of death, myocardial infarction, stroke, and heart failure is over 2% per year in women with a history of chronic chest pain symptoms persisting more than one year [18]. The population is heterogeneous and the presence of coronary vascular dysfunction may predict the likelihood of patients developing coronary events.

Coronary Vascular Dysfunction

Coronary vascular dysfunction due to abnormal endothelium-dependent coronary vasodilatation is predictive of adverse outcomes [7,8,19–21]. Conversely, impaired endothelium-independent vasodilatation predicts favorable outcomes [19]. The reason for this discrepancy is not known. One might hypothesize that a blunted response to exogenous nitric oxide donors (coronary endothelium-independent vasodilatation) might simply reflect the presence of atherosclerosis, leading to increased stiffness of the vessel wall [20]. Conversely, endothelial dysfunction and atherosclerosis, although causally related, are distinct problems and may exist separately. Coronary endothelial vasoreactivity may indeed represent an index that combines information about the underlying atherosclerotic process and the overall stress imposed by risk factors on the arterial wall.

Endothelial function. Coronary endothelial dysfunction in patients with significant coronary artery disease (CAD) provides prognostic value independent of the traditional cardiovascular risk factor assessment [22]. Recent investigations addressed this issue in patients with chest pain and normal coronary angiography, and showed that 30% of patients with chest pain and severe endothelial dysfunction, as assessed by intracoronary acetylcholine testing, developed angiographically visible atherosclerosis during a ten-year follow-up [8].

Other studies evaluated patients with normal or near normal coronary angiography for a mean follow-up of four to six years [7,19–21]. Endpoints of analysis were cardiovascular death, acute myocardial infarction, unstable angina pectoris, and acute ischemic stroke. Acute vascular events occurred in 4.5% of patients. When patients were divided into two groups with either normal or abnormal endothelial function, the event rate of patients with endothelial dysfunction increased up to 14%.

Clinical Decision Making

Nearly 4 million cardiac catheterizations are performed annually in United States hospitals alone, with one in ten discharges having undergone coronary

arteriography [23]. More than 20% of patients aged 45–79 years admitted to hospital receive diagnostic cardiac catheterization [23]. More than 50% of women who are referred for cardiac catheterization because of chest pain show non-obstructive coronary lesions or smooth coronary arteries. [24]. Most of these patients have no diagnosis of angina at the time of discharge.

Epidemiological studies show that undiagnosed angina is costly in terms of mortality, morbidity, and health-care utilization [25]. In one study, over 65% of patients were re-hospitalized for chest pain during an 11-year follow-up and still remained without a diagnosis of angina [25]. Among those with an abnormal ECG result, the absolute risk of non-fatal myocardial infarction was similar in those with and without a diagnosis of angina (16% versus 15%). Also, compared with apparently healthy people, those with undiagnosed and diagnosed angina had a 2.4 and 3.2 times greater risk, respectively, of impaired physical functioning [25]. These findings underscore the importance of greater vigilance in identifying the causes of angina in patients with normal angiography

Symptoms and quality of life. Chest pain is the most common symptom of coronary atherosclerosis prompting patients to seek medical attention. Patients with normal or near normal coronary arteries may present with stable or unstable symptoms [8,17,18,26]. At one extreme are patients in whom angina develops every time the workload of the heart is increased beyond a fairly fixed threshold; at the other extreme are patients who are not necessarily restricted in their physical activity by angina, but suffer rest pain without an obvious cause. Both women and men most commonly report typical angina [8,17]. Along with severe and often unpredictable symptoms, chest pain is often associated with increased psychological morbidity, debilitating symptoms, and a poor quality of life [27–29]

In clinical practice, symptoms in most of these patients are often indistinguishable from those with obstructive CAD. More information and additional testing is needed. It is always important to establish whether or not myocardial ischemia is present.

Noninvasive testing. Use of imaging rather than non-imaging stress testing

may be helpful in the identification of microvascular flow obstruction. Magnetic resonance imaging and gated-single photon emission computed tomography (SPECT) show a substantial overlap in detection of adequate or inadequate flow reserve patterns [30]. In patients with a normal resting ECG, exercise stress myocardial perfusion SPECT yields additional prognostic value over clinical, historical, and exercise treadmill test data for the prediction of coronary events [31]. SPECT abnormality is predictive of both cardiac death and myocardial infarction in patients with obstructive and non-obstructive CAD [32]. Perfusion imaging, unlike angiography, closely correlates with flow reserve and reflects function of the epicardial conduit arteries as well as normal capacity of the resistance vessels [31].

A growing number of centers offer sophisticated cardiac diagnostic tests to aid diagnosis and management of patients with ischemic heart disease. These tests include magnetic resonance imaging, high frequency transthoracic Doppler harmonic echocardiography, and transesophageal echocardiography with Doppler imaging. [30,33,34]

In clinical practice, ischemia with standard SPECT testing identifies symptomatic patients at relatively high risk of a subsequent cardiac event.

Routine coronary angiography.

Data analysis of patients undergoing their first coronary angiography over a three-year period showed that 32% had entirely normal coronary angiograms and an additional 15% had less than a 50% stenosis in any of the major vessels [35]. The frequency of non-obstructive CAD is higher in black patients and in women. Chronic stable angina is the most common clinical presentation in patients without obstructive CAD. Many of these patients do not have angiographically visible plaques, but they have coronary disease.

In clinical practice, new effective technologies may provide better understanding of the mechanisms that account for chest pain in patients with normal or near normal angiography.

New invasive technologies. Sensor-tipped guidewires have enabled cardiologists to identify physiological measures such as absolute coronary flow reserve, relative coronary flow reserve, and pressure-derived fractional flow reserve. The most frequently

used measure is absolute coronary flow reserve. Intravascular ultrasound (IVUS) is a relatively new modality for assessment of atherosclerotic disease burden. IVUS showed that atherosclerotic disease is diffuse and involves the entire arterial tree, including multiple plaques that are not associated with vessel narrowing.

Early signs of atherosclerosis can be detected by IVUS. This may have important therapeutic and prognostic implications [36].

Endothelial function testing. Over the past several years, sophisticated techniques have evolved to measure endothelium-dependent vasodilatation in the brachial and coronary arteries [37]. Peripheral endothelial function testing through measurements of flow-mediated vasodilatation is attractive because it is non-invasive and allows repeated measurements. Coronary artery endothelial function is most commonly assessed by intracoronary infusion of acetylcholine, which, acting via muscarinic receptors on endothelial cells, causes release of nitric oxide and coronary artery dilation [6,7,11,12]. Reduced vasodilatory response of the coronary microcirculation or paradoxical vasoconstriction of the epicardial vessels is a sign of coronary endothelial dysfunction. The relationship between peripheral and coronary endothelial function is still under scrutiny.

Intracoronary acetylcholine testing may be used for patients who, during angiography, turn out not to have obstructed coronary vessels. Endothelial function measurement by peripheral testing may be a useful surrogate to reduce costs, inconvenience, and risks associated with invasive techniques during medical follow-up.

Approach to Management of Individual Patients

There are currently no critical pathways specifically developed for patients with chest pain and normal angiograms. So far, physicians apply (in varying proportions) pathophysiologic reasoning, personal clinical experience, and published research in the development of their own clinical approaches. Treatment objectives include symptom relief and risk factor identification and management with the objective of reducing progression in the underlying disease process with

enhancement of event-free survival.

Symptom relief. At present, all patients with chronic, stable ischemic heart disease should receive long-term treatment with beta-blockers to control angina even if they have normal or near normal coronary arteries at angiography [38]. Assuming that the patient has no evidence of myocardial ischemia and/or vascular dysfunction on image stress testing, they can be discharged on imipramine in an attempt to manage chest pain. Patients without evidence of a cardiac etiology may require referral for evaluation of noncardiac causes of chest pain.

Risk factor control and enhancement of event-free survival. Clinical guidelines recommend managing all patients with acute coronary syndromes with a standard set of therapies, independent of what coronary anatomy looks like [39]. Chronic stable symptoms may require a more selective intervention. Therapy with statins, and perhaps angiotensin-converting enzyme inhibitors, should be used for patients with evidence of coronary endothelial dysfunction and/or atherosclerotic plaques within the arterial wall detected by IVUS [38,40].

A negative angiographic test cannot alleviate the call for intensive lifestyle changes in these patients. The medical community should become increasingly aware that atherosclerosis poses a serious health risk even in its mild form. It is important to understand that the presence of coronary endothelial dysfunction and/or atherosclerotic plaques within the arterial wall is not normal and deserves medical intervention.

A Call for Clinical Trials

We recommend the development of large-scale prospective collaborative clinical trials as well as retrospective analyses of already completed trials, in which the results of angiography may be available in at least a portion of patients. Large numbers of patients will need to be studied, since relatively low-risk patients will be included. These studies require considerable communication among all parties: researchers, physicians, hospital administrators, patient groups, and policy planners. This communication can only be realized by close collaboration between important scientific institutions playing

a prominent role in research funding and program development. A call to action for risk assessment strategies in this area is warranted. ■

Supplementary Information

Text S1. Longer, more detailed version of article

Found at doi:10.1371/journal.pmed.0040012.sd001 (119 KB DOC).

Acknowledgments

Author contributions. RB designed the study. RB, LB, PC, RE, KF, CH, FP, AR, CS, LW, and FVDW analyzed data and contributed to writing the paper.

References

- Sullivan AK, Holdright DR, Wright CA, Sparrow JL, Cunningham D, et al. (1994) Chest pain in women: Clinical, investigative, and prognostic features. *BMJ* 308: 883–886.
- Bugiardini R, Bairey Merz CN (2005) Angina with “normal” coronary arteries: A changing philosophy. *JAMA* 293: 477–484.
- Arbogast R, Bourassa MG (1973) Myocardial function during atrial pacing in patients with angina pectoris and normal coronary arteriograms: Comparison with patients having significant coronary artery disease. *Am J Cardiol* 32: 257–263.
- Cannon RO, Epstein SE (1988) “Microvascular angina” as a cause of chest pain with angiographically normal coronary arteries. *Am J Cardiol* 61: 1338–1343.
- Temkin LP, Marcus PI (1983) Nonatherosclerotic myocardial ischemia. *J Am Coll Cardiol* 1: 1534–1535.
- Bugiardini R, Pozzati A, Ottani F, Morgagni GL, Puddu P (1993) Vasotonic angina: A spectrum of ischemic syndromes involving functional abnormalities of the epicardial and microvascular coronary circulation. *J Am Coll Cardiol* 22: 417–425.
- Halcox JP, Schenke WH, Zalos G, Mincemoyer R, Prasad A, et al. (2002) Prognostic value of coronary vascular endothelial dysfunction. *Circulation* 106: 653–658.
- Bugiardini R, Manfrini O, Pizzi C, Fontana F, Morgagni G (2004) Endothelial function predicts future development of coronary artery disease. A study on women with chest pain and normal angiograms. *Circulation* 109: 2518–2523.
- Drexler H, Zeiher AM, Wollschlaeger H, Meinertz T, Just H, et al. (1989) Flow-dependent coronary artery dilatation in humans. *Circulation* 80: 466–474.
- Nabel EG, Ganz P, Gordon JB, Alexander RW, Selwyn AP (1988) Dilatation of normal and constriction of atherosclerotic coronary arteries caused by the cold pressor test. *Circulation* 77: 43–52.
- Egashira K, Inou T, Hirooka Y, Yamada A, Urabe Y, et al. (1993) Evidence of impaired endothelium-dependent coronary vasodilatation in patients with angina pectoris and normal coronary angiograms. *N Engl J Med* 328: 1659–1664.
- Zeiber AM, Krause T, Schachinger V, Minners J, Moser E (1995) Impaired endothelium-dependent vasodilation of coronary resistance vessels is associated with exercise-induced myocardial ischemia. *Circulation* 91: 2345–2352.
- Tuzcu EM, Kapadia SR, Tutar E, Ziada KM, Hobbs RE, et al. (2001) High prevalence of coronary atherosclerosis in asymptomatic teenagers and young adults: Evidence from intravascular ultrasound. *Circulation* 103: 2705–2710.
- Jeremias A, Ge J, Erbel R (1997) New insight into plaque healing after plaque rupture with subsequent thrombus formation detected by intravascular ultrasound. *Heart* 77: 293.
- Ge J, Haude M, Gorge G, Liu F, Erbel R (1995) Silent healing of spontaneous plaque disruption demonstrated by intravascular ultrasound. *Eur Heart J* 16: 1149–1151.
- Erbel R, Heusch G (2000) Coronary microembolization. *J Am Coll Cardiol* 36: 22–24.
- Bugiardini R, Manfrini O, De Ferrari GM (2006) Unanswered questions for management of acute coronary syndrome. Risk stratification of patients with minimal disease or normal coronary angiography. *Arch Int Med* 166: 1391–1395.
- Johnson BD, Shaw LJ, Pepine CJ, Reis SE, Kelsey SF, et al. (2006) Persistent chest pain predicts cardiovascular events in women without obstructive coronary artery disease: Results from the NIH-NHLBI-sponsored Women’s Ischaemia Syndrome Evaluation (WISE) study. *Eur Heart J* 27: 1408–1415.
- Suwaidi JA, Hamasaki S, Higano ST, Nishimura RA, Holmes DR Jr, et al. (2000) Long-term follow-up of patients with mild coronary artery disease and endothelial dysfunction. *Circulation* 101: 948–954.
- Schachinger V, Britten M, Zeiher A (2000) Prognostic impact of coronary vasodilator dysfunction on adverse long-term outcome of coronary heart disease. *Circulation* 101: 1899–1906.
- von Mering GO, Arant CB, Wessel TR, McGorray SP, Bairey Merz CN, et al. Abnormal coronary vasomotion as a prognostic indicator of cardiovascular events in women: Results from the National Heart, Lung, and Blood Institute-Sponsored Women’s Ischemia Syndrome Evaluation (WISE). *Circulation* 2004 109: 722–725.
- Reddy KG, Nair RN, Sheehan HM, Hodgson JM (1994) Evidence that selective endothelial dysfunction may occur in the absence of angiographic or ultrasound atherosclerosis in patients with risk factors for atherosclerosis. *J Am Coll Cardiol* 23: 833–843.
- Agency for Healthcare Research and Quality (1997) Procedures in U.S. hospitals. Rockville (MD): Agency for Healthcare Research and Quality.
- Sharaf BL, Pepine CJ, Kerensky RA, Reis SE, Reichel N, et al. (2001) Detailed angiographic analysis of women with suspected ischemic chest pain (pilot phase data from the NHLBI-sponsored Women’s Ischemia Syndrome Evaluation [WISE] Study Angiographic Core Laboratory). *Am J Cardiol* 87: 937–941.
- Hemingway H, Shipley M, Britton A, Page M, Macfarlane P, et al. (2003) Prognosis of angina with and without a diagnosis: 11 year follow up in the Whitehall II prospective cohort study. *BMJ* 327: 895.
- Bugiardini R (2006) Women, “non-specific” chest pain, and normal or near-normal coronary angiograms are not synonymous with favourable outcome. *Eur Heart J* 27: 1387–1389.
- Asbury EA, Collins P (2005) Psychosocial factors associated with noncardiac chest pain and cardiac syndrome X. *Herz* 30: 55–60.
- Asbury EA, Creed F, Collins P (2004) Distinct psychosocial differences between women with coronary heart disease and cardiac syndrome X. *Eur Heart J* 25: 1695–1701.
- Bass C, Wade C, Hand D, Jackson G (1983) Patients with angina with normal and near normal coronary arteries: Clinical and psychosocial state 12 months after angiography. *Br Med J (Clin Res Ed)* 287: 1505–1508.
- Panting JR, Gatehouse PD, Yang GZ, Grothues F, Firmin DN, et al. (2002) Abnormal subendocardial perfusion in cardiac syndrome X detected by cardiovascular magnetic resonance imaging. *N Engl J Med* 346: 1948–1953.
- Hachamovitch R, Berman DS, Kiat H, Cohen I, Friedman JD, et al. (2002) Value of stress myocardial perfusion single photon emission computed tomography in patients with normal resting electrocardiograms: An evaluation of incremental prognostic value and cost-effectiveness. *Circulation* 105: 823–829.
- Abdel Fattah A, Kamal AM, Panchoy S, Ghods M, Russell J, et al. (1994) Prognostic implications of normal exercise tomographic thallium images in patients with angiographic evidence of significant coronary artery disease. *Am J Cardiol* 74: 769–771.
- Bartel T, Yang Y, Muller S, Wenzel RR, Baumgart D, et al. (2002) Noninvasive assessment of microvascular function in arterial hypertension by transthoracic Doppler harmonic echocardiography. *J Am Coll Cardiol* 39: 2012–2018.
- Poelaert JI, Schupfer G (2005) Hemodynamic monitoring utilizing transesophageal echocardiography: The relationships among pressure, flow, and function. *Chest* 127: 379–390.
- Wennberg DE, Kellett MA, Dickens JD, Malenka DJ, Keilson LM, et al. (1996) The association between local diagnostic testing intensity and invasive cardiac procedures. *JAMA* 275: 1161–1164.
- Smith SC Jr, Feldman TE, Hirshfeld JW Jr, Jacobs AK, Kern MJ, et al. (2006) ACC/AHA/SCAI 2005 guideline update for percutaneous coronary intervention: A report of the American College of Cardiology/American Heart Association Task Force on Practice Guidelines (ACC/AHA/SCAI Writing Committee to Update 2001 Guidelines for Percutaneous Coronary Intervention) *Circulation* 113: e166–e286.
- Corretti MC, Anderson TJ, Benjamin EJ, Celermajer D, Charbonneau F, et al. (2002) Guidelines for the ultrasound assessment of endothelial-dependent flow-mediated vasodilation of the brachial artery: A report of the International Brachial Artery Reactivity Task Force. *J Am Coll Cardiol* 39: 257–265.
- Fox K, Garcia MA, Ardisino D, Buszman P, Camici PG, et al. (2006) Guidelines on the management of stable angina pectoris: Executive summary: The Task Force on the Management of Stable Angina Pectoris of the European Society of Cardiology. *Eur Heart J* 27: 1341–1381.
- Braunwald E, Antman EM, Beasley JW, Califf RM, Cheitlin MD, et al. (2002) American College of Cardiology/American Heart Association. Committee on the Management of Patients With Unstable Angina. ACC/AHA 2002 guideline update for the management of patients with unstable angina and non-ST-segment elevation myocardial infarction—summary article: a report of the American College of Cardiology/American Heart Association task force on practice guidelines (Committee on the Management of Patients With Unstable Angina) *J Am Coll Cardiol* 40: 1366–1374.
- Pizzi C, Manfrini O, Fontana F, Bugiardini R (2004) Angiotensin-converting enzyme inhibitors and 3-hydroxy-3-methylglutaryl coenzyme a reductase in cardiac Syndrome X: Role of superoxide dismutase activity. *Circulation* 109: 53–58.