

# Shoulder Reconstruction for Brachial Plexus Birth Injuries: An In-Depth Review and Case-Based Update

Ryan Serbin, MD<sup>1</sup>; Peter M. Waters, MD<sup>1,2,3</sup>; Daniel Lewis, MD<sup>1,2</sup>; Glenn Gaston, MD<sup>1,2</sup>; Bryan Loeffler, MD<sup>1,2</sup>

<sup>1</sup>Atrium Health Carolinas Medical Center, Department of Orthopaedic Surgery, Charlotte, NC; <sup>2</sup>OrthoCarolina Hand Center, Charlotte, NC; <sup>3</sup>Boston Children's Hospital, Boston, MA

Correspondence: Peter Waters, MD, Atrium Health Musculoskeletal Institute, OrthoCarolina Hand Center, 1915 Randolph Road Second Floor, Charlotte, NC 28207. Email: [peter.waters@atriumhealth.org](mailto:peter.waters@atriumhealth.org)

Received: September 5, 2023; Accepted: September 13, 2023; Published: November 15, 2023

DOI: 10.55275/JPOSNA-2023-784

## Abstract

Brachial plexus birth injuries can result in significant shoulder dysfunction with limitations in range of motion, decreased strength, and risk of glenohumeral joint deformity. This comprehensive review examines current approaches for management of the shoulder including surgical reconstruction following these injuries. Serial clinical exams and selective imaging are critical to determine optimal timing of surgery based on recovery potential and joint pathology. Biceps recovery is monitored monthly from birth and, if absent by 5-6 months, serves as an indication for nerve reconstruction with nerve grafting, transfers, or both. Glenohumeral contracture, deformity, and dislocation commonly occur in infancy and are assessed by exam, ultrasound, and MRI scan. Procedural intervention is indicated when there is loss of passive external rotation, active motor weakness, and/or glenohumeral deformity/dislocation is present. Contracture release and joint reduction to center the humeral head on the glenoid is performed early when there are limitations in passive external rotation not resolved with therapy. Glenoid remodeling can occur when reduction is performed early (6 months to 2-3 years). Surgical options include (1) extraarticular contracture releases (e.g., botox, subscapularis slide) and closed reduction, (2) intraarticular arthroscopic/open release and reduction, and (3) contracture release/joint reduction combined with tendon transfers (latissimus-teres major most common). The lower trapezius transfer is increasingly used for active external rotation as it spares internal rotation strength and has an excellent line of pull reproducing that of the infraspinatus. For advanced joint deformity, humeral/glenoid osteotomies are utilized. A nuanced, individualized approach is required considering the child's deficits, pathoanatomy, and age in a case-based manner. Open communication between providers and families is imperative to optimize care. This review provides a comprehensive analysis of current shoulder reconstruction approaches following brachial plexus birth injuries.

**Key Concepts**

- Failure of biceps recovery by 5-6 months for extraforaminal injuries (C5-C6; C5-C6-C7) indicates nerve surgery intervention between 5-9 months using nerve grafting, transfers, or a combination to restore function in the shoulder (and as for indicated elbow, forearm, and wrist).
- Glenohumeral joint complications such as contracture, deformity, and dislocation often emerge during early infancy to the first 2-3 years due to incomplete recovery. Physical exams focus on the progressive limitations of external rotation (ER), and advanced imaging (ultrasound or MRI) is needed when passive ER falls below 30 degrees and/or there's posterior humeral head prominence.
- In cases of glenohumeral deformity and dislocation, it's crucial to center and stabilize the humeral head on the glenoid during reduction. Early intervention (6 months to 2-3 years) can result in glenoid remodeling.
- Surgical options range from extraarticular contracture releases, such as botox and subscapularis slide, to intraarticular arthroscopic or open release and reduction. Depending on patient age and deformity severity, reduction surgeries can be standalone or combined with tendon transfers. It's vital to adopt a patient-tailored, stepwise approach during surgery.
- The latissimus dorsi-teres major transfer restores active external rotation, while the lower trapezius offers an alternative for active ER that preserves internal rotation strength. In situations with pronounced deformities in older patients, glenoid and humeral osteotomies can be performed.

**Introduction**

Brachial plexus birth injuries (BPBI) present a complex set of challenges in managing shoulder function and anatomic development. Occurring during childbirth, these injuries often result in significant impairments, including internal rotation contracture, external rotation, abduction weakness, glenohumeral deformity, dislocation, and functional loss. While many patients recover from transient birth injuries, 10-30% of infants experience long-term deficits of BPBI.<sup>1</sup> Addressing these conditions in individuals with chronic deficits often requires effective shoulder reconstruction techniques in a time-sensitive manner to improve function and quality of life. This is a comprehensive review of current shoulder reconstruction approaches to guide clinicians in treatment strategies.

***Clinical and Radiographic Evaluation***

Clinical examination, ultrasound imaging, and MRI play crucial roles in the evaluation of brachial plexus birth injuries and resulting glenohumeral dysplasia. Physical exam for limitations in passive shoulder external rotation and abduction suggest glenohumeral contracture

or deformity. Ultrasound provides an accessible, noninvasive method for screening infants to detect early posterior subluxation or dislocation of the humeral head.

Ultrasound enables dynamic, real-time visualization without sedation which makes it ideal for serial exams in the office setting, starting around 3 months up until around 2 years of age (Figure 1). Comparative glenoscapular (alpha) angle, glenoid version, and posterior humeral head displacement relative to the posterior scapular margin can be measured (Figure 2).<sup>2-4</sup> Accuracy does diminish with humeral head ossification.

MRI serves as the gold standard imaging modality to diagnose and characterize glenohumeral dysplasia severity for surgical planning (Figure 3). MRI can accurately visualize the unossified glenoid structures. However, it often requires sedation or anesthesia.

***Brief Considerations of Nerve Reconstruction***

Nerve reconstruction is indicated if there is no biceps function at 5-6 months.<sup>6</sup>



**Figure 1.** Clinician demonstrating proper positioning of transducer in transverse orientation at posterior shoulder to visualize glenohumeral joint.

Preganglionic, intraforaminal injuries (e.g., nerve root avulsions) are more complex reconstructions but can still improve function beyond natural history.

Postganglionic, extraforaminal injuries (e.g., nerve root ruptures) have better-expected results with high majority recovering both elbow flexion (musculocutaneous nerve: biceps, brachialis) and shoulder abduction (axillary nerve: deltoid) and majority recovering shoulder external rotation (suprascapular nerve: supraspinatus, infraspinatus) by nerve grafting and/or nerve transfers.

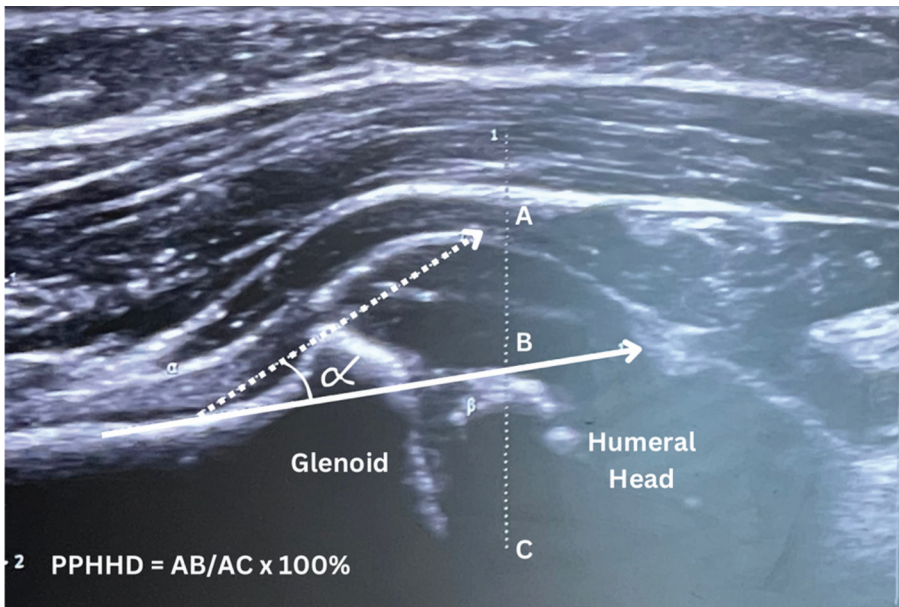
For patients with intact biceps and triceps function but not shoulder function at 9-15 months, nerve transfer from partial triceps motor to axillary and partial spinal accessory to suprascapular nerve may be indicated to restore shoulder abduction and external rotation (Figures 4 and 5).

In infants with early glenohumeral dysplasia, nerve reconstruction alone will not sufficiently improve function.<sup>7,8</sup> Always examine the shoulder for contracture or dislocation before nerve surgery and intervene to resolve contracture and reduce glenohumeral joint as necessary.

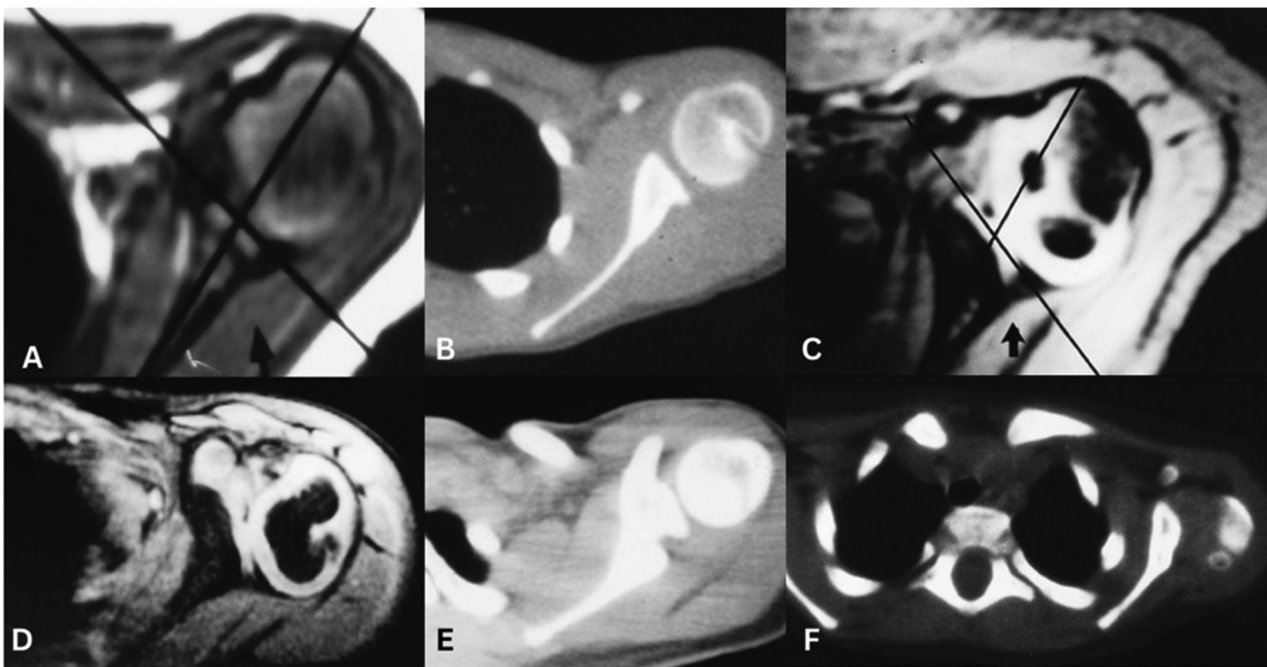
### ***Surgical Considerations for Shoulder Reconstruction***

Surgical intervention is indicated when a patient (1) fails conservative management to prevent internal rotation shoulder contracture, (2) fails to regain shoulder active external rotation and abduction function, (3) persists with limited active external rotation function above the shoulder level either by natural history or after nerve reconstruction, (4) has a rare infantile dislocation, and (5) has progressive or severe glenohumeral dysplasia with increased glenoid retroversion, pseudoglenoid, and subluxated or dislocated humeral head.<sup>9</sup>



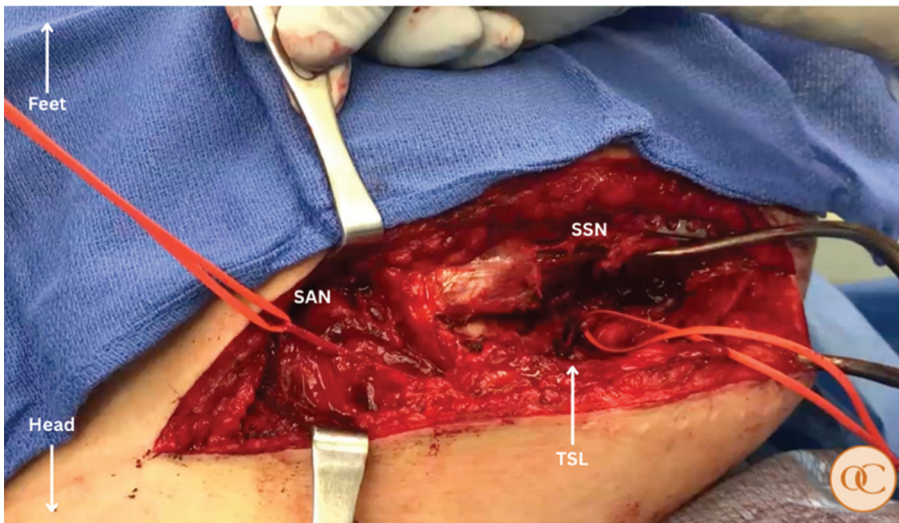


**Figure 2.** Transverse ultrasound shows the patient's glenohumeral joint. The alpha angle (A) is between the posterior scapular margin (solid line) and a line tangent to the posterior humeral head (dotted line). An alpha angle >30 degrees suggests posterior humeral head subluxation. Percentage posterior humeral head displacement (PPHHD) is the percentage of the humeral head behind the posterior scapular margin.

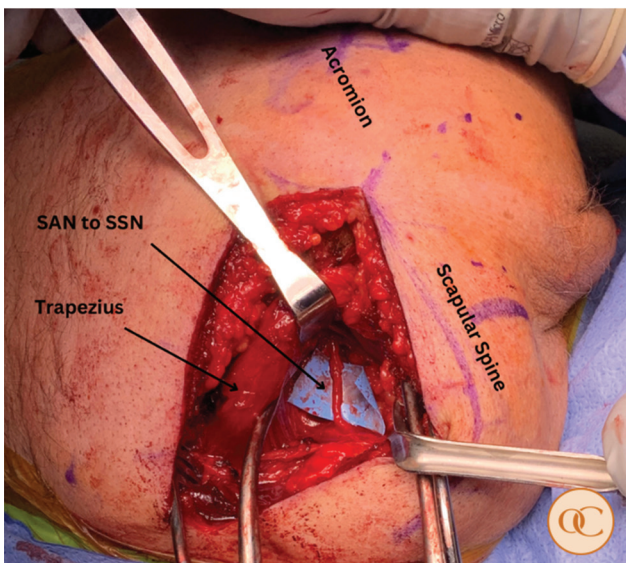


**Figure 3A-F.** Sequential radiographic classifications of glenohumeral joint deformities using CT and MRI scans<sup>5</sup> (Table 1).





**Figure 4.** This depicts the preparation for a SAN to SSN transfer and each nerve tagged with vessel loops. The transverse scapular ligament (TSL) must be excised to expose the SSN. This arrow indicates where the TSL should be found prior to excision.



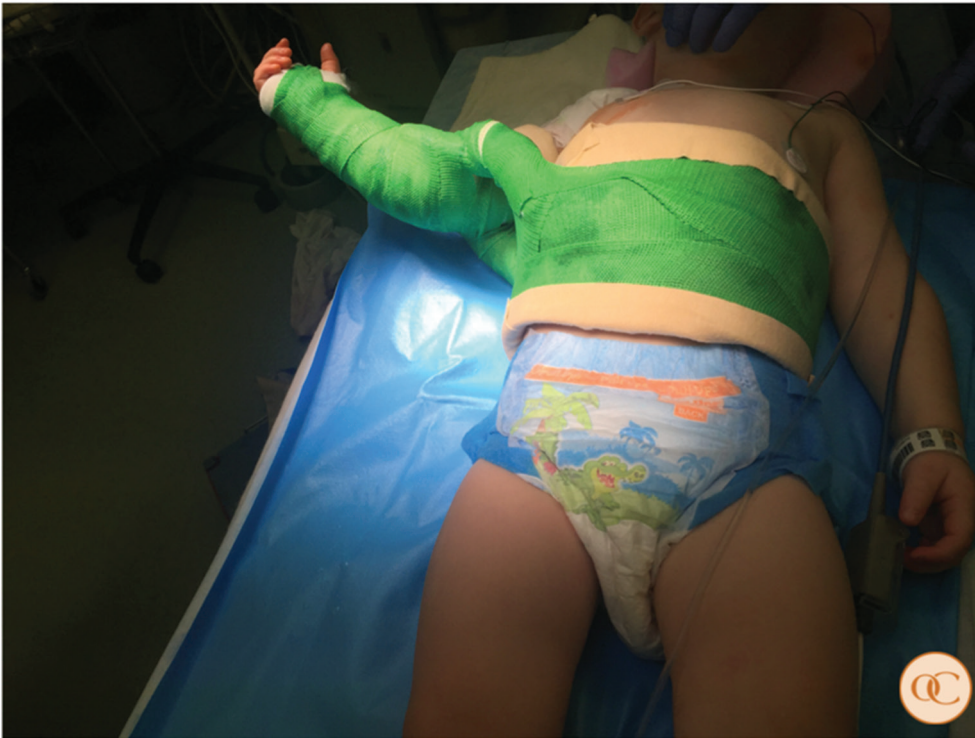**Figure 5.** The left image provides a broader orientation, while the right offers a detailed close-up view of a partial spinal accessory nerve to suprascapular nerve transfer.

There are several established techniques that restore range of motion and function depending on the patient's age and deficits on presentation. These soft-tissue and tendon rebalancing procedures can prevent the progress of glenohumeral dysplasia and promote joint remodeling if done before 2-3 years old.<sup>10-12</sup>

**Table 1. Progression of Glenohumeral Dysplasia as Described by Waters et al.<sup>5</sup>**

Classification	Radiographic Features
Type I (Figure 3A)	Less than 5-degree difference in retroversion between the humeral head and glenoid
Type II (Figure 3B)	More than 5-degree difference in retroversion between the humeral head and glenoid
Type III (Figure 3C)	Posterior humeral head subluxation, with less than 35% of the humeral head anterior to the scapular spine axis
Type IV (Figure 3D)	Presence of a false glenoid, indicating the formation of a secondary glenoid fossa
Type V (Figure 3E)	Flattening of the humeral head, leading to progressive or complete humeral head dislocation
Type VI (Figure 3F)	Infantile posterior dislocation of the humeral head

The following treatment algorithm offers a framework for relevant procedures and aids clinicians in surgical decision-making. While these are general guidelines, it's essential to tailor the treatment plan considering the patient's physical exam, age, MRI findings, and social support.



**Figure 6.** Shoulder spica cast applied to patient with shoulder abducted to 40 degrees and externally rotated >60 degrees post-botox injection and closed reduction glenohumeral joint.

**A. For children aged 6-15 months with persistent contracture resistant to therapy but still with potential for recovery of external rotation and abduction, isolated contracture release can be considered.**

Options include (1) temporizing botox injections and closed reduction glenohumeral joint, (2) subscapularis slide and closed reduction, (3) arthroscopic or open joint release and reduction, (4) coracoacromial ligament release and reduction. Arthroscopic joint releases, alone or with tendon transfer, will be discussed in the section on contracture with glenohumeral dysplasia. Open reduction will be reviewed in conjunction with tendon transfers. Our authors do not perform coracoacromial ligament releases alone and thus will not cover them here.

### Botulinum Toxin A

Injection of botulinum toxin into antagonist muscles (i.e., subscapularis, teres major-latissimus dorsi, and/or pectoralis major) is done in conjunction with closed reduction of the glenohumeral joint and spica casting or splinting to maintain reduction. The cast should be

applied with the shoulder abducted to approximately 30 to 40 degrees and externally rotated to >60 degrees (Figure 6). It can reset and help normalize the situation while awaiting recovery.<sup>13-15</sup>

### Subscapularis Slide

A contracted subscapularis can lead to limited passive ER and be an integral factor in the development of glenohumeral deformity. Tenotomy and z-lengthening risk the loss of internal rotation power and development of ER contracture. Subscapularis slide was originally described by Carlloz to improve passive ER while limiting risk of internal rotation dysfunction or ER contracture.<sup>16</sup> More recently, Shah has described a minimally invasive subscapularis slide.<sup>17</sup> In a patient without advanced glenohumeral pathology (Type I, II) and opportunity for neurologic recovery (i.e., prior to 2 years old), this procedure can be done in isolation.

- **Patient Positioning:** Position the patient in lateral decubitus with the affected arm up. Carefully pad all neurovascular structures and bony prominences,

including the opposite brachial plexus and peroneal and ulnar nerves.

- **Prepping and Draping:** Prep and drape the entire shoulder girdle and arm meticulously to adequately expose the medial scapula and accurately measure passive external rotation.
- **Incision:** A longitudinal medial scapular incision is made, allowing access to the targeted area.
- **Dissection:** Dissection is carried out along the anterior medial border of the scapula. Electrocautery is initially used, followed by a broad elevator to release the subscapularis origin from the anterior scapula.
- **Mobilization:** Mobilize the muscle belly of the subscapularis from medial to lateral to facilitate passive external rotation correction. Use passive external rotation of the arm in adduction following mobilization to achieve the desired correction. Aim to achieve 60 to 80 degrees without excessive tension.
- **Immobilization and Rehabilitation:** A shoulder spica cast is applied to maintain the corrected adduction and external rotation position for a period of 4-6 weeks, followed by intensive postoperative therapy.

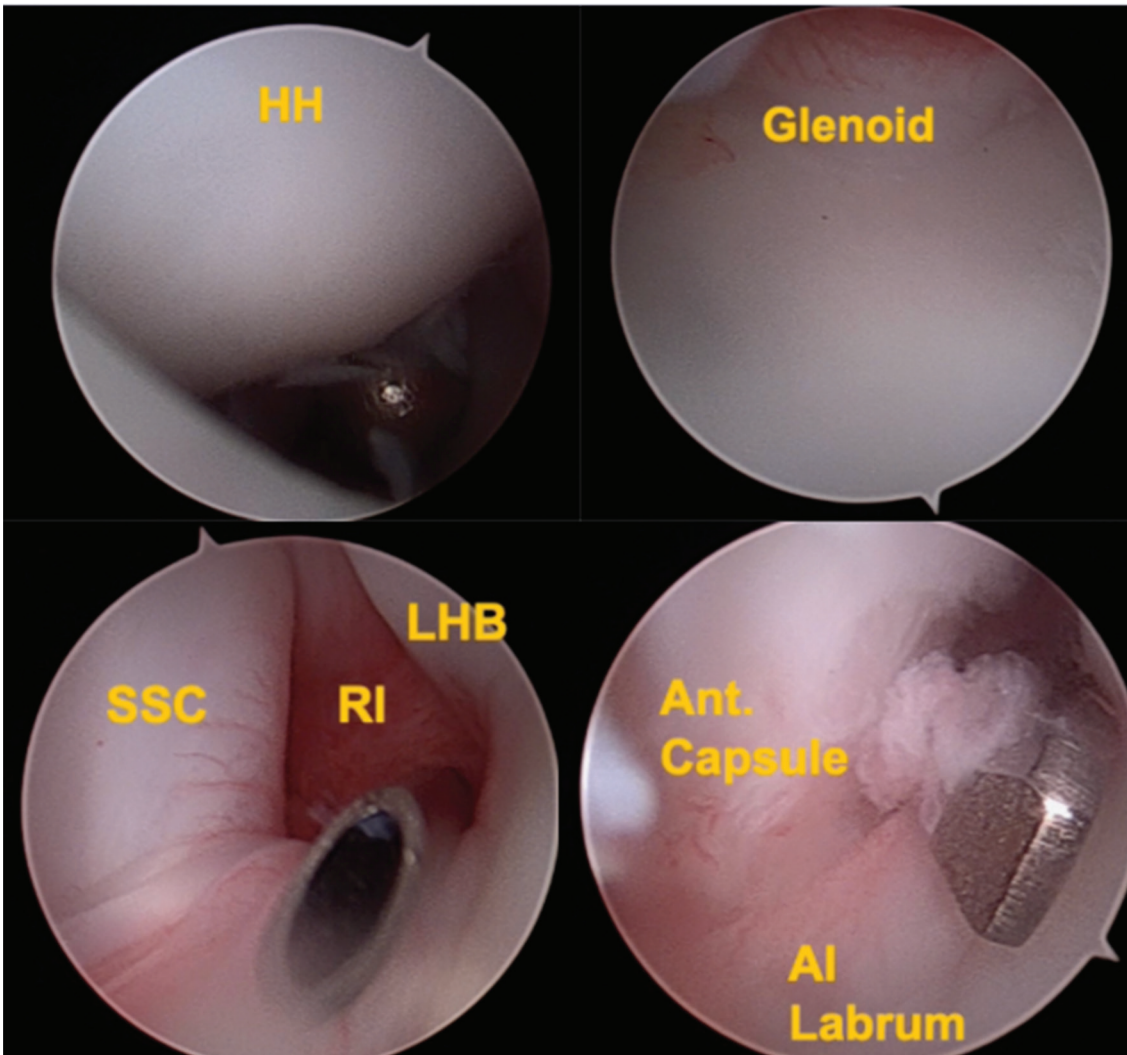
**B. For younger children (6 months to 18 months) with mild to moderate joint deformity (Type II to Type III) and potential for remodeling, consider soft tissue releases and joint reduction.**

### Arthroscopic Release and Joint Reduction

For young patients with Type II or III deformities, intraarticular techniques are recommended. The key consideration is whether arthroscopic release and reduction is effective in isolation or requires a simultaneous tendon transfer. Arthroscopic and open methods address passive ER limitations and ensure joint reduction with direct visualization.<sup>18,19</sup> Arthroscopic release and reduction is performed most often. Passive external rotation >60 degrees and a reduced, stable glenohumeral joint is the goal. It is imperative to avoid over-release that might weaken internal rotation power or cause an external rotation contracture.

- **Patient Positioning:** Position the patient in lateral decubitus with the affected arm up. To ensure consistent body positioning throughout the surgery, a beanbag is utilized.
- **Prepping and Draping:** Prep and drape the arm and entire shoulder girdle, including the scapula.
- **Joint Insufflation:** Use the standard posterior portal inferior and medial to the posterolateral acromion. Use an 18-gauge needle to insufflate the joint with saline and diluted epinephrine. Ensure free flow return to confirm joint entry.
- **Visualization and Portal Placement:** Obtain manual joint distraction by applying longitudinal arm traction. Insert a 2.7 mm arthroscope through the posterior portal, aiming for the coracoid. Be aware of the trajectory for a dysplastic shoulder. A medial-to-lateral trajectory allows the scope to pass around the posteriorly dislocated humeral head. Establish the anterior portal using an 18-gauge spinal needle, positioning it between the labrum, subscapularis, and biceps tendon. Depending on the patient's size, use a cannula through the anterior portal.
- **Operative Release:** Throughout this procedure, the axillary nerve is in proximity and must be protected. Using a hooked Bovie electrocautery device through the anterior portal, the anterior-inferior edge is visualized and the capsule, inferior, and middle glenohumeral ligaments are sequentially released (Figure 7).
- **Evaluation:** After each release, assess passive external rotation and joint reduction to prevent over-release and long-term functional issues. Target >60 degrees of tension-free external rotation with a reduced humeral head (Figure 8).
- **Optional Partial Subscapularis Release:** If capsular release isn't sufficient, consider a partial subscapularis release. Avoid extensive release to maintain internal rotation strength and prevent potential external rotation contracture or anterior-inferior glenohumeral instability.





**Figure 7.** Arthroscopic views of subscapularis sparing procedures. Top Images: Visualizing the humeral head and glenoid. Bottom left: An 18-gauge spinal needle enters through the anterior portal, viewed from the posterior portal. Bottom right: An arthroscopic biter releases the anterior inferior capsule. HH: Humeral Head, SSC: Subscapularis, RI: Rotator Interval, LHB: Long Head of Biceps.

- **Immobilization:** Apply a shoulder spica cast in adduction and external rotation to maintain joint reduction. Keep the cast on for 4-6 weeks, then start therapy.

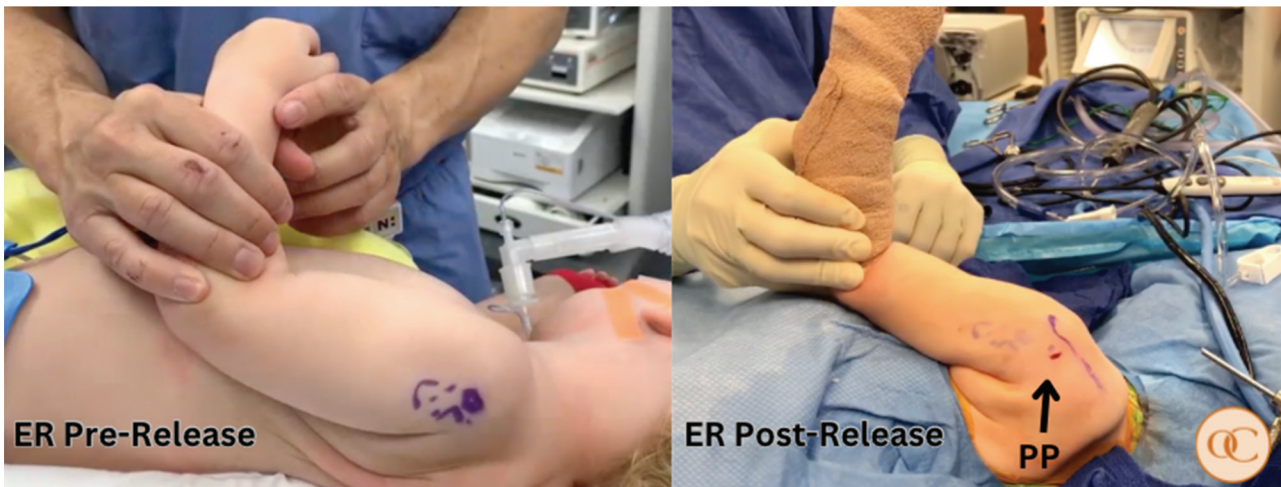Typically, we combine arthroscopic reduction with external rotation tendon transfer rather than reduction in isolation.

**C. For older children, aged between 2 and 5 years, where active ER recovery is unlikely and joint deformity has the potential to remodel, a combination**

**of joint release and reduction procedures and tendon transfers is recommended.**

### Options for Tendon Transfer and Lengthening/Release

Tendon transfers are commonly used to restore external rotation function and improve abduction in patients with incomplete shoulder recovery. If there is external rotation/abduction weakness alone without an internal rotation contracture, then tendon transfers can be performed in isolation. This type of patient will most



**Figure 8.** Exam under anesthesia pre- (left) and post- (right) arthroscopic anterior capsular release demonstrating significantly improved passive adduction-external rotation. The posterior portal (PP) is also visualized.

commonly present after nerve reconstruction has failed to reinnervate the suprascapular nerve. The latissimus dorsi and teres major, introduced by L'Episcopo<sup>20</sup> in 1930 and modified by many,<sup>21</sup> is most used. However, recent literature has described and supported the use of the lower trapezius to restore external rotation, assuming that the spinal accessory nerve was not utilized as a nerve transfer previously.<sup>22-25</sup>

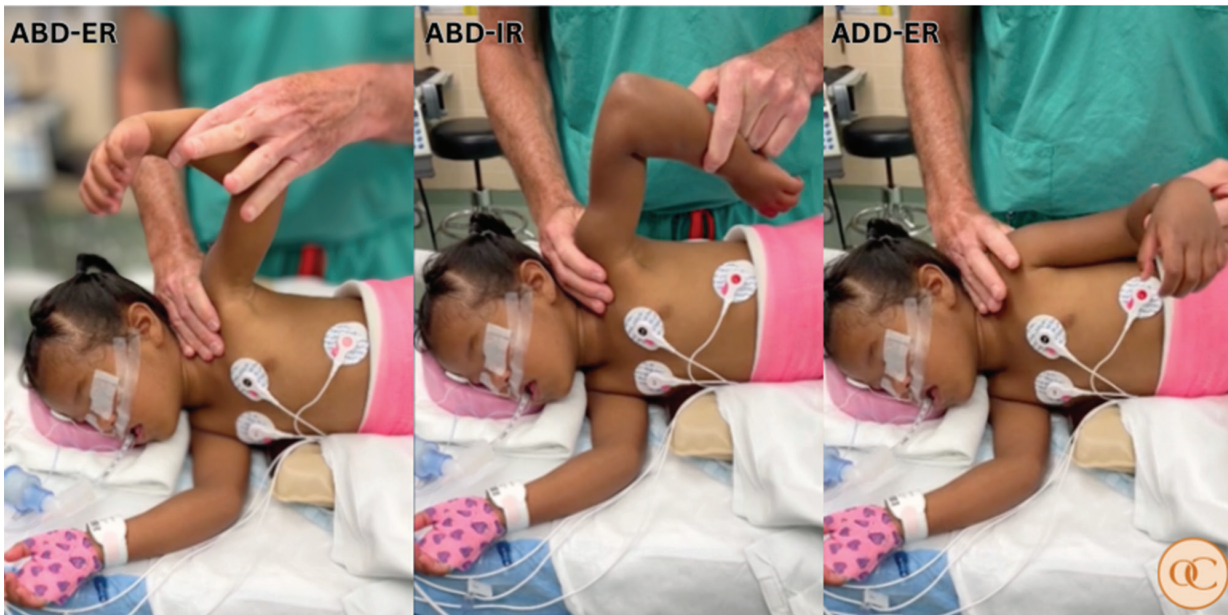
If there is a contracture and weakness alone, then the surgeon should incorporate soft-tissue release techniques with tendon transfer. This can involve extraarticular musculotendinous lengthening of the pectoralis major (improves ABD-ER) and less often, limited subscapularis lengthening (improves ADD-ER) during exposure for a latissimus dorsi-teres major transfer.

If there is glenohumeral subluxation or dislocation, it is necessary to include joint release-reduction techniques. This can be performed open as part of the exposure and mobilization of the latissimus-teres major tendons or arthroscopic before either latissimus-teres or lower trapezius tendon transfer. The surgical approach is customized for each patient, considering individualized releases, lengthenings, transfers, and joint reduction techniques. The extent of reconstruction is determined intraoperatively in a stepwise fashion.

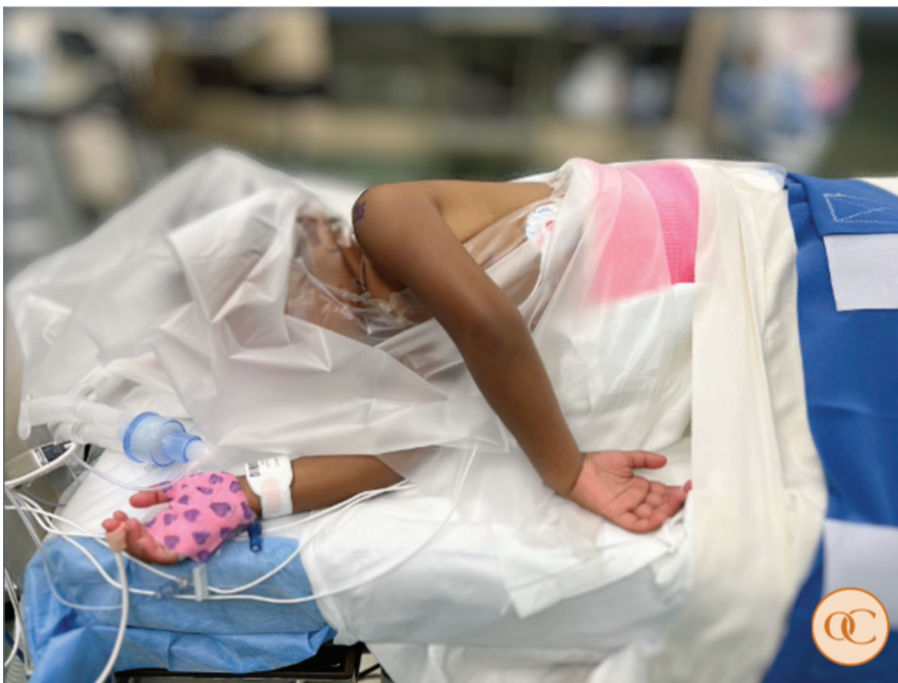## I. Preoperative Examination

- Examine the patient under anesthesia prior to positioning and sterile prep. Assess range of motion, glenohumeral instability, and ability to reduce a dislocated joint once under anesthesia and throughout the case with each step. Joint reduction is assessed by physical exam for (1) reduction of the humeral head into glenoid through dynamic IR/ER motion testing while palpating the posterior soft spot, (2) near symmetric ER in ADD and ABD when reduced. Glenohumeral joint reduction can be confirmed with an OR ultrasound or arthrographic static and dynamic exams. Radiographs are less precise due to skeletal immaturity of the humeral head and glenoid in this age group. It is beneficial to place the waist portion of the spica cast on prior to surgery for ease of finishing application after surgical release, reduction, and tendon transfer (Figure 9).
- Specifically, assess passive motion in ADD-ER rotation (often  $<0$  degrees in OR; normal  $>60$ ), ABD-ER rotation (often  $<90$  degrees; normal  $>120$ ), and the scapulohumeral angle (often  $<120$ ; normal  $>150$ ). Also, check for a Putti sign, signaling glenohumeral abduction contracture.





**Figure 9.** Preoperative exam under anesthesia demonstrating slightly limited abduction-external rotation (left), normal abduction-internal rotation (middle), and significantly limited adduction-external rotation (right).



**Figure 10.** Patient in lateral decubitus position.

- Repeat this exam after each release, lengthening and/or transfer to ensure desired range of motion, joint reduction, and stability at each step.

## II. Patient Positioning and Preparation

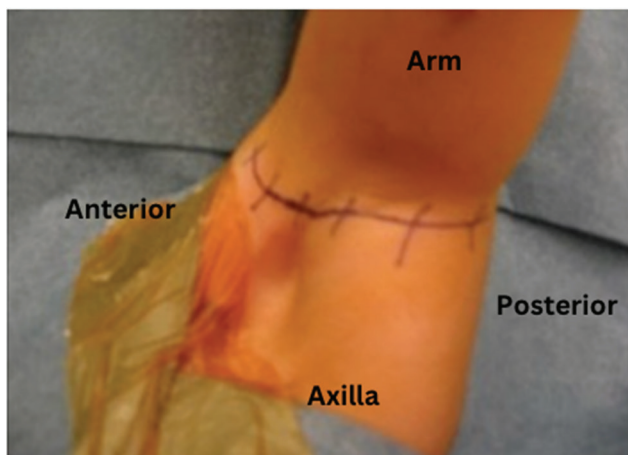
- Place the patient in the lateral decubitus position with the affected side up (Figure 10).



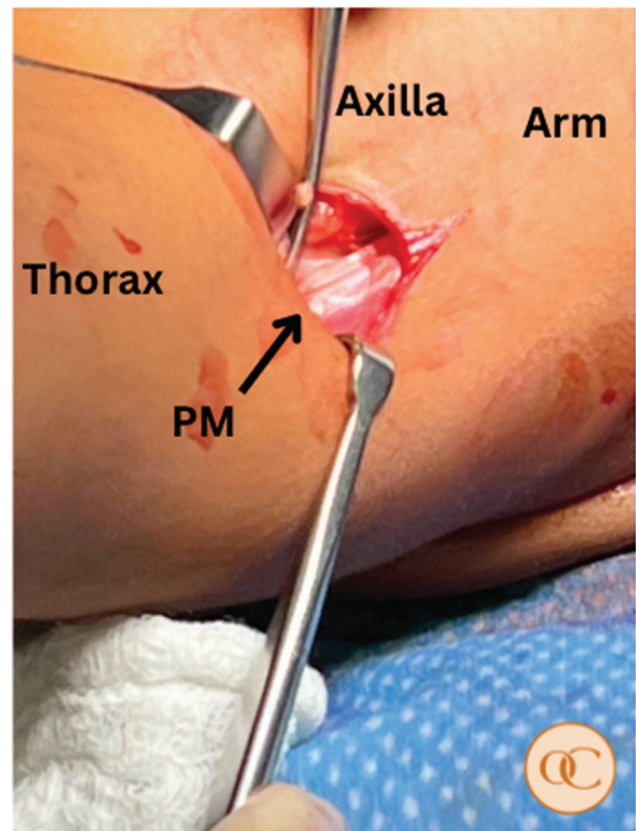
- Prep the affected arm, axillae, shoulder girdle, and scapula. When prepping, it is essential to have the whole scapula within the surgical field to accurately discern between scapulothoracic and glenohumeral movements.

### III. Latissimus Dorsi-Teres Major Axillary Exposure and Pectoralis Major Lengthening

- If the patient has limited abduction-external rotation (ABD-ER), perform trans-axillary exposure and pectoralis major lengthening.
- The incision extends from the anterior edge of the pectoralis major to the posterior edge of the axillary fold near the acromion. Take care to place the incision in the axillary crease to minimize scar profile (Figure 11).
- Locate the anterior margin of the pectoralis major and perform a dissection beneath its tendon, leading to its attachment point on the humerus (Figure 12).
- Mobilize the pectoralis major from the coracobrachialis, pectoralis minor, and the short head of the biceps that anchor to the coracoid. Protect the musculocutaneous nerve.
- Use a scalpel or protected cautery to release the contracted, thickened portion of tendon near the



**Figure 11.** This demonstrates the trans-axillary approach for exposure of the pectoralis major, latissimus dorsi and teres major.



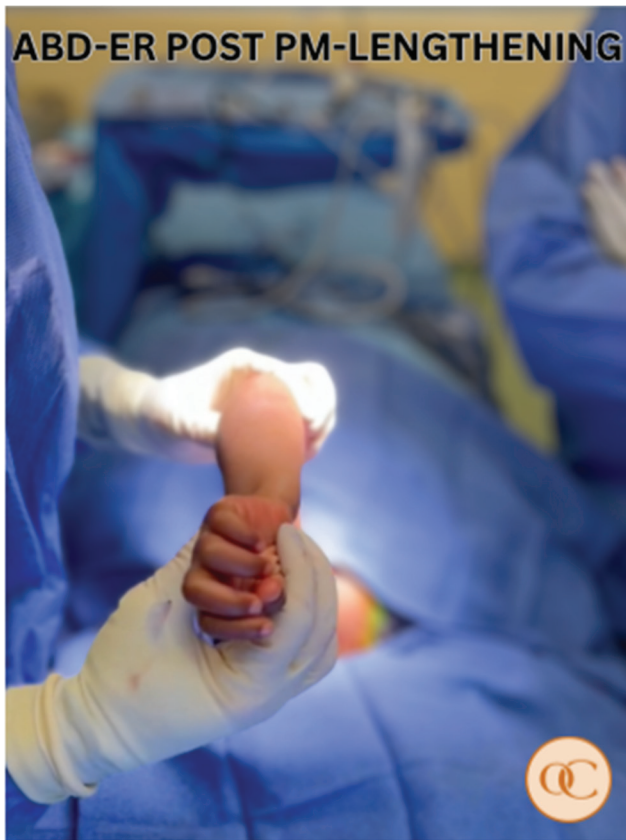**Figure 12.** This demonstrates trans-axillary exposure of the pectoralis major tendon (PM) at its insertion to the humerus.

insertion while preserving the underlying muscle. Observe the slide at the musculotendinous junction following release.

- At this point, pause to reassess the range of motion, especially in abduction-external rotation. It should improve beyond vertical, but adduction-external rotation may not improve substantially (Figure 13).
- Also assess humeral head reduction. Typically, this maneuver alone does not lead to joint reduction, and more is needed.

### IV. Latissimus Dorsi-Teres Major Tendon Transfer

After the pectoralis major lengthening, a tendon transfer is performed to improve active abduction and external rotation. Choose between the latissimus dorsi-teres major (LD-TM) transfer and lower trapezius transfer



**Figure 13.** Improved abduction-external rotation ~90 degrees following pectoralis major fractional lengthening.

(LTT). The LD-TM transfer is described here to allow a stepwise presentation of the overall procedure. However, the LTT, described separately, can take the place of the LD-TM transfer in this algorithm.

- For latissimus dorsi-teres major (LD-TM) transfer, use the transaxillary exposure described above. Dissect and expose the LD and TM muscle insertion on the humerus in the posterior aspect of this incision (Figure 14).
- Identify and protect the brachial plexus anterior to the latissimus tendon and the axillary nerve as it runs inferior to the teres minor as it traverses the quadrilateral space.
- Release LD and TM tendons from their humeral periosteal insertion. In this patient population, the tendons are often conjoined at the insertion and

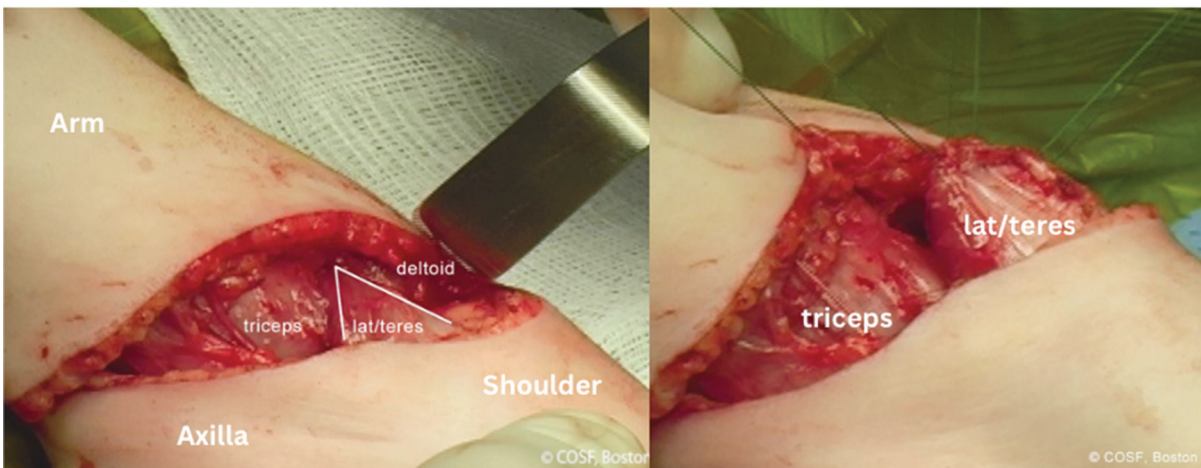
are typically released and transferred together (Figure 14).

- To maximize tendon excursion, release adherent fascia and mobilize LD and TM tendons and muscles back to their neurovascular pedicle.
- Place inverted nonabsorbable horizontal mattress sutures in the tendons to prepare for eventual tendon insertion.
- Following release, retest passive range of motion for ABD-ER and ADD-ER as well as joint reduction and stability. If ABD-ER >110 degrees (20 degrees beyond vertical), ADD-ER >60 degrees with light 2-finger testing, and the glenohumeral joint is stably reduced, then no further releases are required. Proceed with inserting the tendon transfer (Step VII).
- If Add-ER <30 degrees and the joint is not reduced or stable, perform a joint capsulotomy, reduction, and, if needed, subscapularis partial lengthening.

## V. Subscapularis Partial Lengthening, Joint Capsulotomy, and Reduction

This can be done arthroscopically as presented previously, before tendon transfer, or open as we will discuss here:

- Utilizing the same exposure, dissect down to the subscapularis as it traverses across the anterior and inferior glenohumeral joint and inserts into the lesser tuberosity of the humerus.
- Mobilize the subscapularis from the glenohumeral joint capsule using a soft tissue elevator. Given the adherence between the subscapularis and capsule, dissect carefully to avoid entering the joint.
- Once the capsule is isolated, assess ADD-ER again. If ADD-ER >40 degrees with a reduced and stable joint, progress to LD-TM tendon transfer insertion.
- If subscapularis mobilization fails to improve passive ADD-ER ROM, which is common, move



**Figure 14.** Trans-axillary exposure of the lat/teres is demonstrated on the left and subsequent release and tagging of the lat/teres is demonstrated on the right (images courtesy of COSF, Boston).

on to capsulotomy and joint reduction. Begin sequential capsular release, taking care not to injure the labrum or articular cartilage. Once ADD-ER >60 degrees with 2-finger testing and the joint is stable, proceed to LD-TM tendon transfer insertion.

- If ADD-ER remained limited with an unstable humeral head, then a partial subscapularis musculotendinous lengthening is added to center the humeral head on the dysplastic glenoid. Do not overlengthen or release the subscapularis.

## VI. LD-TM Tendon Transfer Insertion

- Dissect between the deltoid and triceps to locate the supraspinatus and infraspinatus insertions on the greater tuberosity. Safeguard the axillary nerve and its deltoid insertion.
- Clean the greater tuberosity and supraspinatus-infraspinatus footprint from any adherent soft tissues in the posterior subacromial space.
- Suture the tendons to the greater tuberosity using strong nonabsorbable sutures in a trans-periosteal fashion (Figure 15). Tendon transfer insertion needs to be into the epiphysis to avoid injury to the physis and for the transfer to remain in proper position with anticipated future growth.

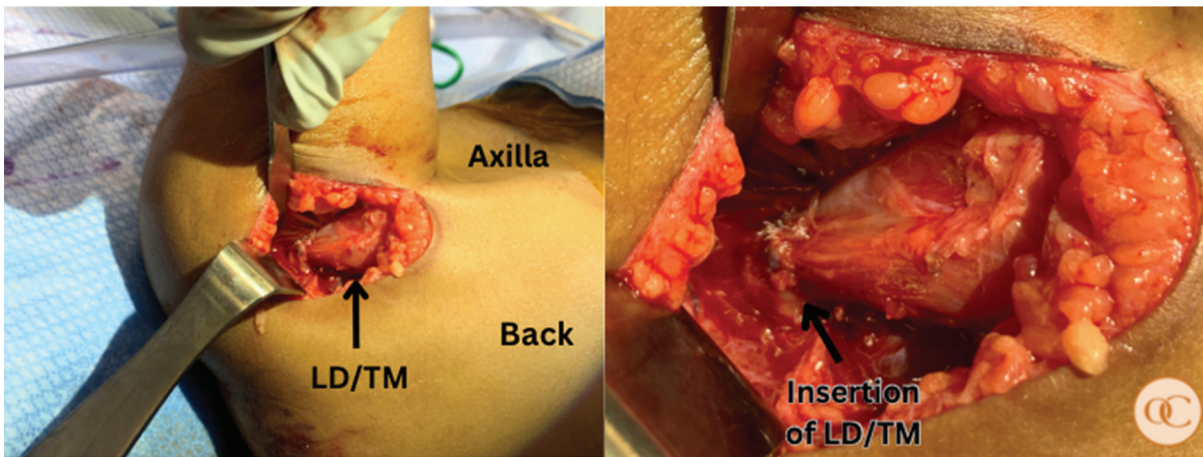
- A temporary traction suture placed into the tendon transfer and exiting the anterior portal (when concomitant arthroscopic release is performed) can aid in proper tensioning during the transfer (Figure 16).

- Make sure that the shoulder is in a position of slight abduction and external rotation to prevent over-tightening of the transfer.
- Test range of motion and joint stability, making sure that there is no external rotation or abduction contracture because of the transfer insertion. Test for scapular winging that could be caused by too tight of an insertion (i.e., Putti sign).

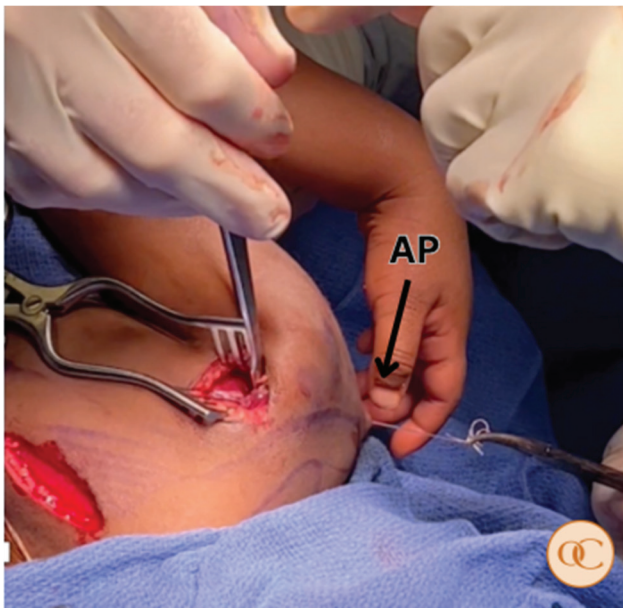
## VII. Final Checks

- Ensure ABD-ER >110 degrees (20 degrees beyond vertical), ADD-ER >60 degrees with 2-finger testing, and a reduced and stable joint.
- Check for a scapulohumeral angle >140 degrees with the scapula stabilized. If not, consider musculotendinous lengthening of the triceps.
- Ensure that the humeral head is reduced and stable throughout motion. If not, evaluate for potential causes like untreated contractures or unrecognized obstacles to reduction.





**Figure 15.** Illustration of the LD-TM tendon insertion into the supraspinatus-infraspinatus footprint on a right shoulder. The left image provides a broader orientation, while the right offers a detailed close-up view.



**Figure 16.** The tendon is tensioned by pulling a traction suture out through the anterior portal (AP) site with the arm in maximum external rotation.

- Be sure to protect all neurovascular structures during closure, especially when closing over tendon transfers.
- Immobilize with shoulder spica in slight abduction and external rotation >60 degrees.

### Lower Trapezius Transfer

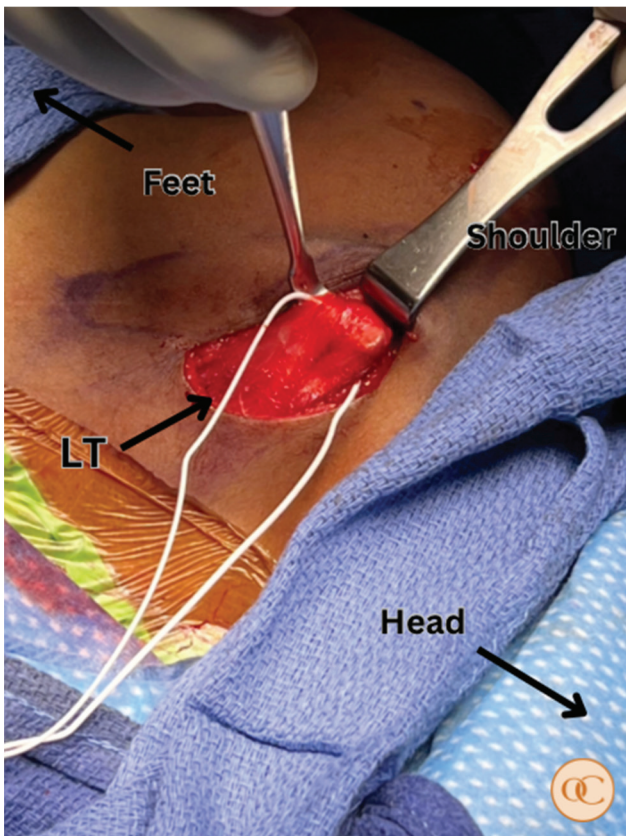
Originally described and used for adult rotator cuff and brachial plexus injuries, lower trapezius transfer suits

patients aged 18 months to adults. Ideal candidates have preserved active forward flexion and abduction but lack active external rotation.

It's often paired with an arthroscopic subscapularis sparing rotator interval, anterior and inferior capsular release, and, if necessary, a mini-open anterior fractional lengthening of the pectoralis major as described in previous sections.

Our favored LTT technique aligns with Elhassan's method but with modifications.<sup>23</sup> Notably, we forgo allografts, opting for a large periosteal sleeve, reflecting Valenti and Bertelli's techniques.<sup>24,25</sup> We now prefer lower trapezius transfer for external rotation power because it (1) closely matches the native infraspinatus anatomy and (2) conserves internal rotation muscles.

- **Exposure of Lower Trapezius Origin:** Make a 6 cm longitudinal incision parallel to the scapula's medial and medial/inferior border. Identify and mobilize the trapezius's lower border until reaching its tendinous part (Figure 17). Release it from the scapular spine's inferior border.
- **Exposure of Lower Trapezius Insertion:** Make a second longitudinal incision from the posterolateral corner of the acromion just medial to the posterior aspect of the axillary fold (Figure 18).



**Figure 17.** Longitudinal incision made just medial to the medial border of the scapula, lower trapezius tendon is identified and mobilized by defining its borders.

- **Lower Trapezius Mobilization:** Develop the interval between the lower and middle trapezius. Elevate the lower trapezius with a substantial periosteal strip combined with its tendon. This strip provides adequate length for transfer, eliminating the need for an allograft. Use a passing suture to help transfer the tendon through the lateral incision (Figures 18 and 19).
- **Shuttling the Lower Trapezius:** Develop the raphe between the middle and posterior deltoid tunnel with a hemostat from lateral to medial under the posterior deltoid (Figure 20).
- **Preparing the Transfer:** Place a series of (4) 2-0 nonabsorbable sutures in the infraspinatus footprint for horizontal mattress repair of the lower trapezius. The LT can be tensioned with the arm in maximal external rotation by passing the suture through the

previously used anterior portal site of the arthroscopic release (Figure 16).

- **Tendon Insertion:** The tendon is then directly sutured into the infraspinatus (IS) tendon, near its insertion point.
- **Postoperative Care:** Immobilize in an external rotation spica cast in a position of mild abduction and external rotation (Figure 21). This cast is utilized full-time for the initial 6 weeks, transitioning to nighttime use only for an additional 4 weeks.

**4. In the case of older children with severe deformity, bony surgeries, such as humeral osteotomy and glenoid osteotomy, may be necessary.**

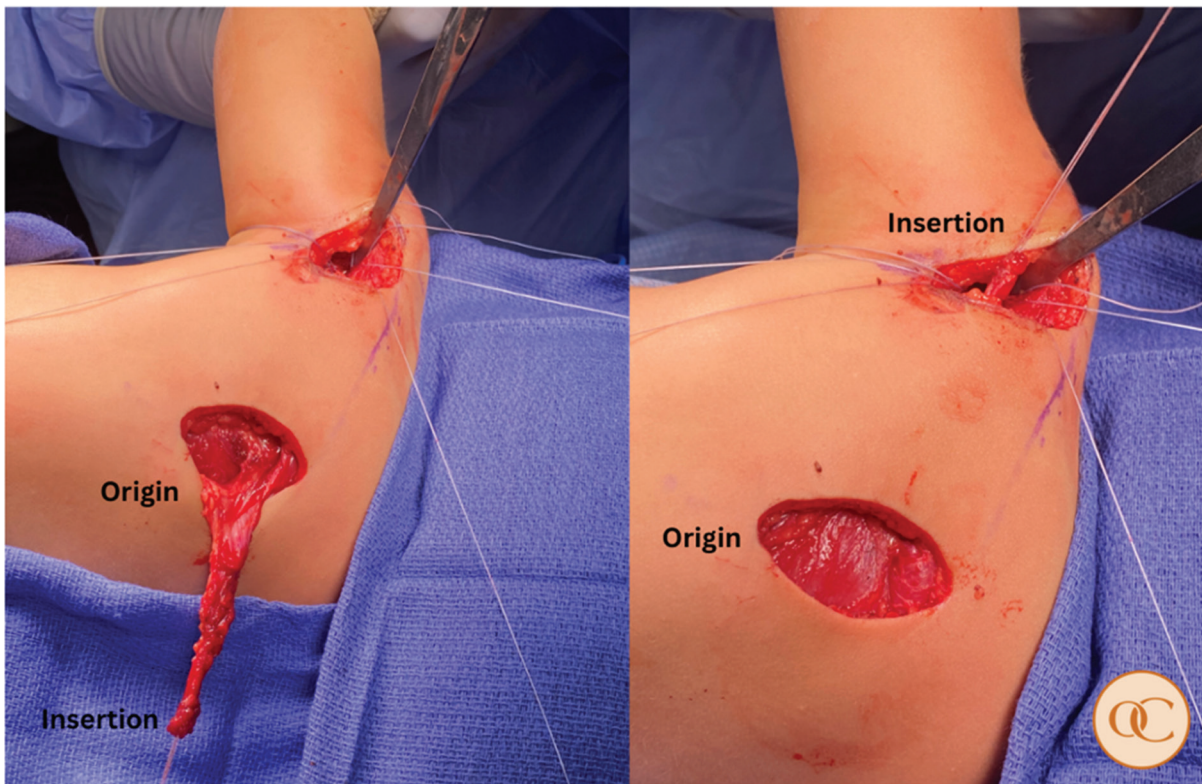
### Humeral Osteotomy

In adolescents with internal rotation contracture, joint deformation (Type V), and limited external rotation (ER), a humeral derotation osteotomy can enhance functionality (Figure 22).

This procedure repositions the hand for better daily activity performance, optimizing the limited motion arc. The correction degree is determined by preoperative and intraoperative glenohumeral motion assessments with a stabilized scapula. Ideally, there are 110-120 degrees of glenohumeral motion pre-surgery. Less than 90 degrees may contraindicate the osteotomy. Typical corrections range from 40-80 degrees but most often 60-70 degrees.

- **Patient Positioning:** Use a modified beach chair position. Ensure midline stability for accurate rotation assessment in all planes, checking rotation arc and alignment continuously.
- **Prepping and Draping:** Prep the affected upper extremity, shoulder girdle, and scapula. Post-draping, ensure midline structures remain palpable.
- **Incision:** Incise the length of a six-hole plate either above the deltoid insertion or along the medial upper arm. Curve the anterior incision's distal portion internally to match the osteotomy's external rotation



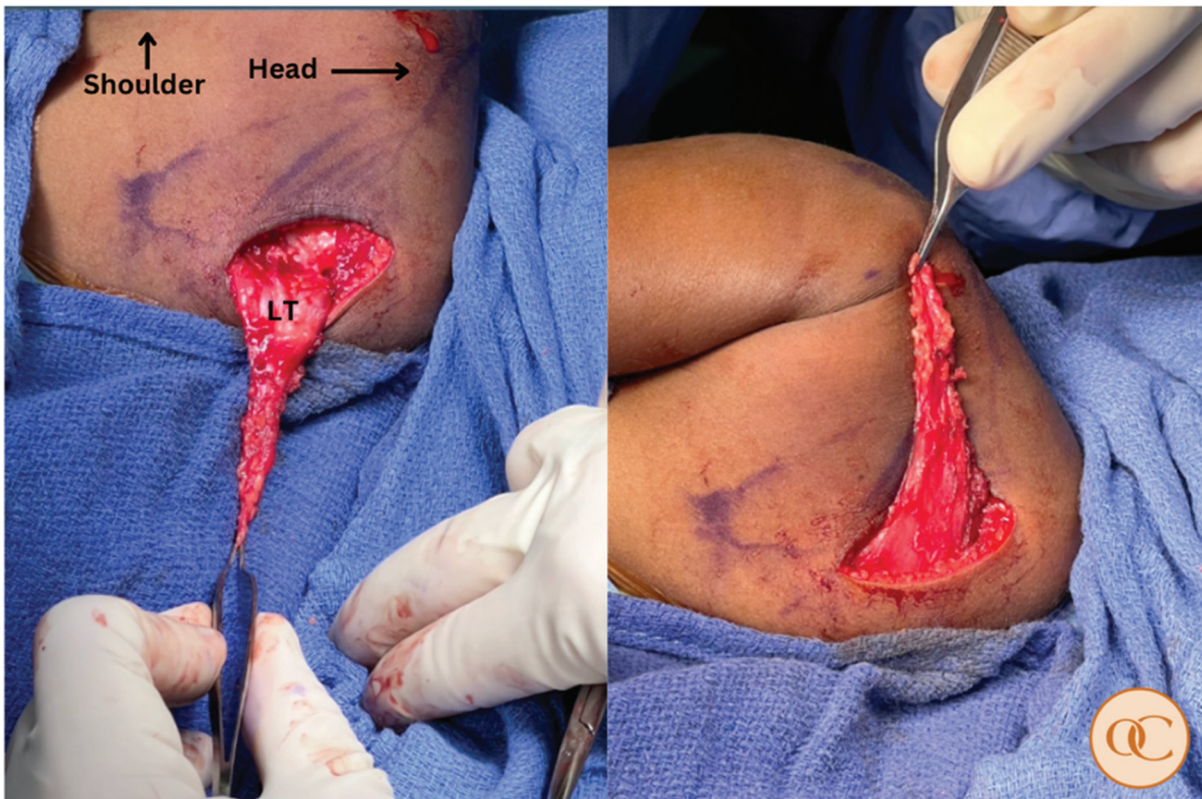


**Figure 18.** The image shows the medial longitudinal incision exposing the lower trapezius origin and the lateral incision revealing its insertion. The released lower trapezius with a periosteal strip, pulled through the medial incision, is also depicted (left).

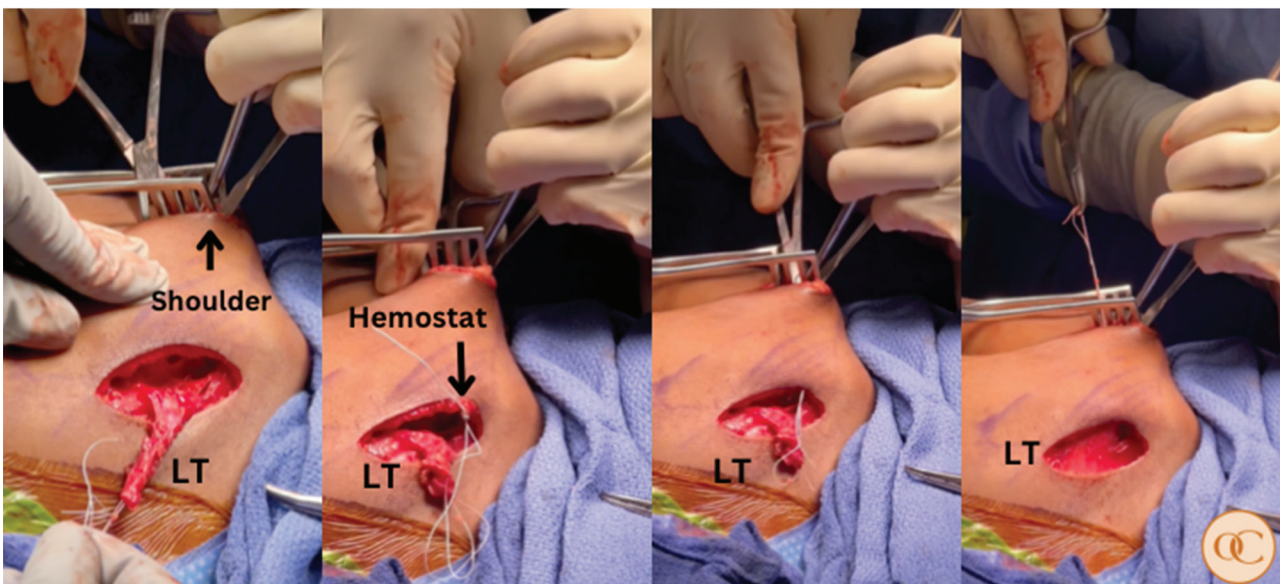
correction, minimizing scar risk. A medial incision is less visible but risks ulnar nerve injury.

- **Dissection:** (1) Anteriorly, conduct a deltopectoral dissection, safeguarding the cephalic vein. Elevate subperiosteally between the pectoralis major-deltoid insertions and through the brachialis, protecting the radial nerve. (2) Medially, access the humerus beneath the pectoralis major and deltoid. Isolate and shield neurovascular structures, especially the ulnar nerve, during medial humerus exposure. In either approach, continue with subperiosteal dissection protecting radial nerve.
- **Plate Application:** Apply a six-hole nonlocking compression plate (or double-stacked semi-tubular plates for smaller patients) centered at the planned osteotomy. Insert and then remove the top three screws.
  - Anterior approach: plate and osteotomy are proximal to the deltoid insertion (Figure 23).
  - Medial approach: plate and osteotomy are positioned more distally (Figure 24).
- **Marking the Osteotomy Site:** Mark the osteotomy site with an osteotome and electrocautery, using temporary K-wires for guidance (Figure 24). While the typical correction is about 70 degrees external rotation (approximately the small fragment plate's width), it must be exact, determined by preoperative and intraoperative glenohumeral motion with a stabilized scapula.
- **Making the Osteotomy:** Perform the transverse osteotomy with an oscillating saw and osteotome, ensuring the safety of the radial nerve by not violating the periosteum posteriorly. Confirm a thorough transverse cut, avoiding 'bone spikes' that might disrupt rotation or apposition.
- **Plate Reapplication and Rotation:** Reattach the plate(s) loosely to the proximal fragment using prior screw holes. Rotate the distal humerus to match

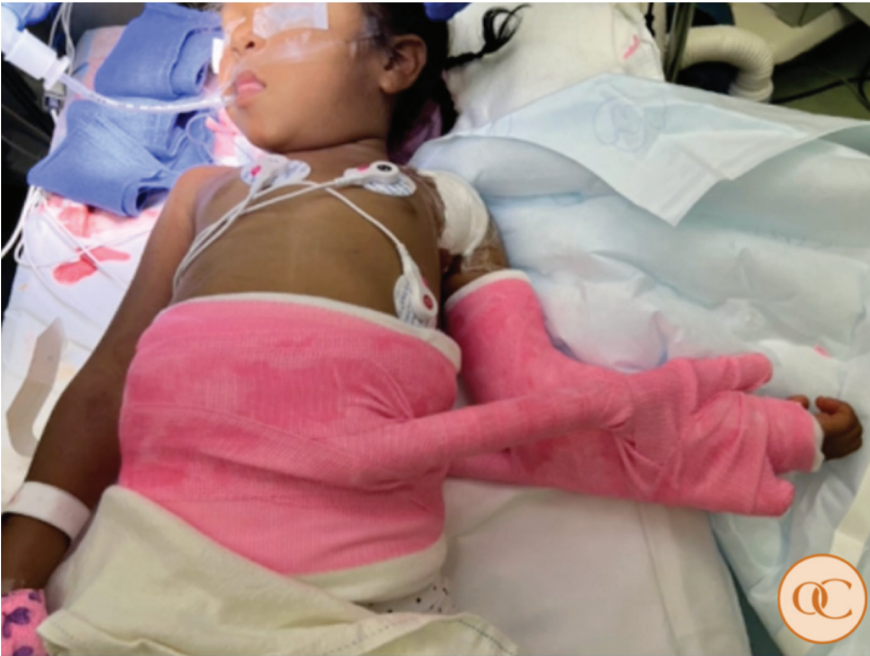



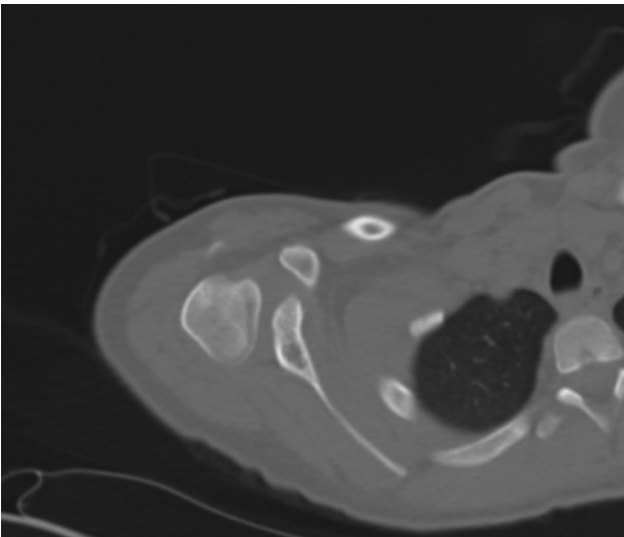
**Figure 19.** The lower trapezius (LT) is released from its insertion at the inferior edge of the scapular spine with a large periosteal strip. The image on the right demonstrates its fiber orientation in line with that of the infraspinatus.



**Figure 20.** From left to right this demonstrates the subsequent shuttling of the lower trapezius (LT) from medial to lateral under the posterior deltoid.



**Figure 21.** Shoulder spica cast applied in external rotation to protect tendon transfer.



**Figure 22.** Axial CT of a patient with Type V GHD who subsequently underwent humeral osteotomy.

the bone's vertical marks or pre-set K-wires for the intended correction. Secure the proximal screws, stabilize the osteotomy site, and insert one or two distal screws under compression.

- **Motion Testing & Final Fixation:** Conduct manual motion tests with temporary fixation. The hand should access the groin, chest, and mouth in internal

rotation; have >30-40 degrees of adduction and ER; and easily touch the occiput. Monitor for possible scapulothoracic compensation. After confirming desired ER with a stable scapula, insert the remaining distal screws.

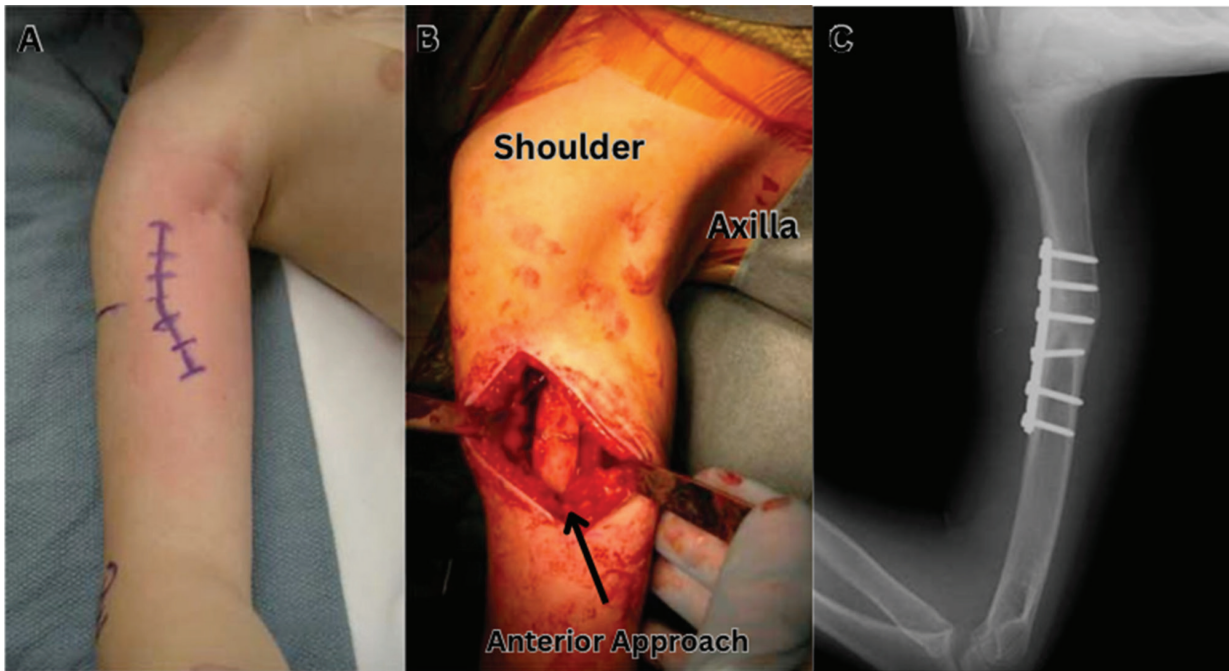
- **Intraoperative Radiographs and Closure:** Acquire intraoperative radiographs or fluoroscopy to verify alignment of bone, screws, and plate. Make necessary adjustments.
- **Postoperative Care:** Use a sling and swathe and start early motion.

### Glenoid Osteotomy: Posterior Opening Wedge

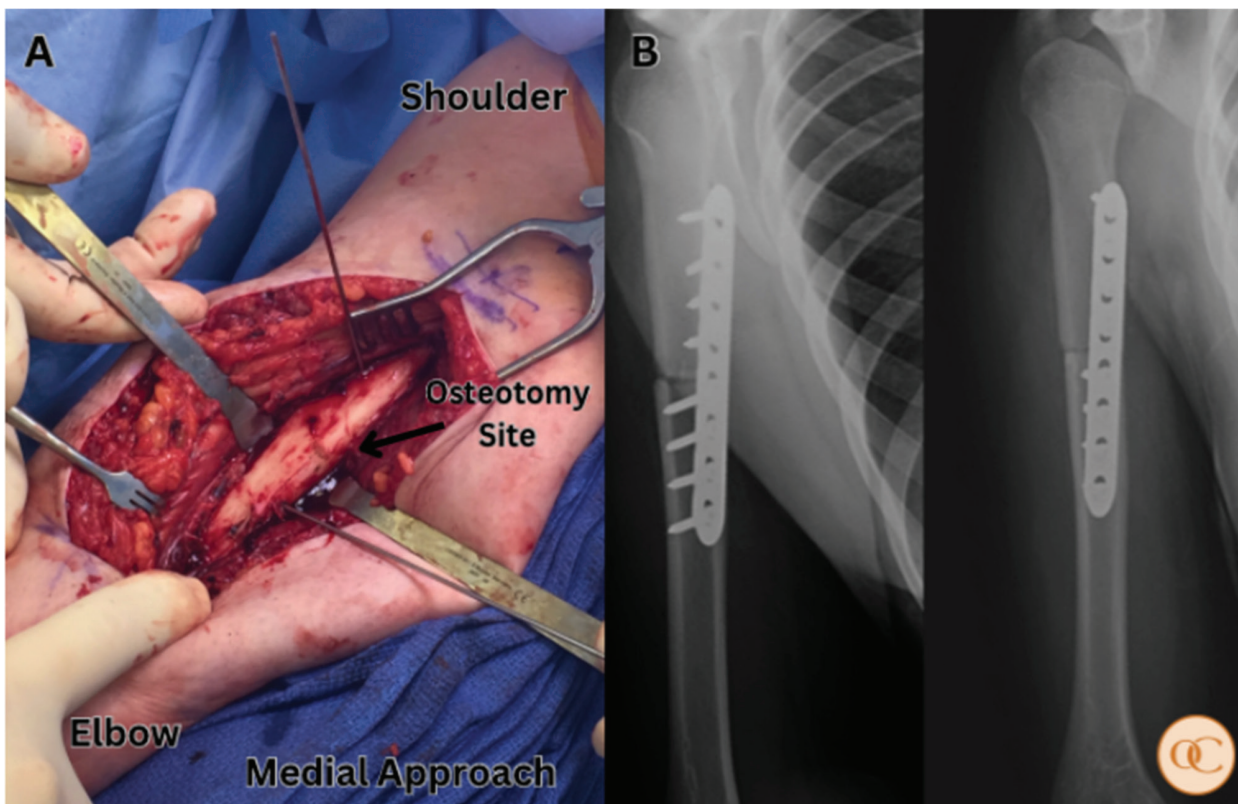
This procedure is for patients with Type III-IV glenoid dysplasia experiencing glenohumeral joint instability and limited external rotation (Figure 25). It's suitable for children over 5 years who have a reconstructable joint but won't remodel with joint reduction. The osteotomy often pairs with a tendon transfer in younger patients.

- **Patient Positioning:** Position the patient in lateral decubitus with the affected side up.



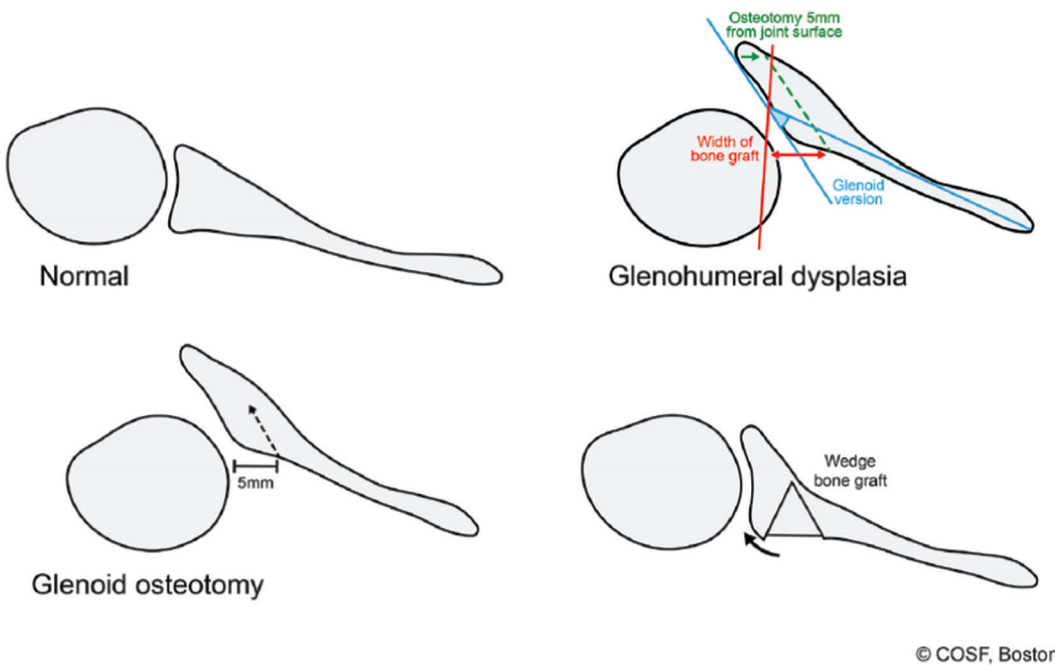


**Figure 23.** (A) The incision for the anterior approach. (B) The anterior exposure of the humerus is shown. (C) A lateral radiograph following anterior plate application is shown.



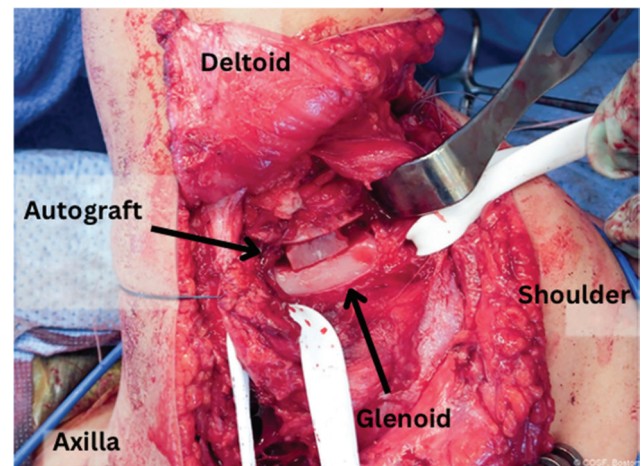
**Figure 24.** The medial approach to the humerus is shown. The osteotomy site is marked with electrocautery, and temporary K-wires indicate the intended correction. AP and lateral radiographs following humeral osteotomy and subsequent plate application are shown.





**Figure 25.** Illustration demonstrating the steps of a glenoid osteotomy for glenohumeral dysplasia (courtesy of COSF, Boston, MA).

- **Surgical Exposure:** Start with a posterior oblique incision from the scapular spine to the humerus's greater tuberosity. Detach the deltoid from the posterior acromion, safeguarding the axillary nerve. Secure the deltoid with nonabsorbable sutures for retraction and later repair. Using a vessel loop, isolate the infraspinatus muscle and tendon, then detach its insertion and tag it for later repair.
- **Release LD and TM tendons for tendon transfer if planned:** Expose the LD and TM muscle insertion. Release them from the humeral insertion periosteum, ensuring maximum tendon mobility and safeguarding the neurovascular pedicle. Place sutures in the tendons.
- **Glenoid Osteotomy:** Identify the dysplastic glenoid and make a small posterior capsulotomy. Use a freer elevator for a full glenoid view. Start the osteotomy with a curved osteotome, targeting the coracoid. Elevate the posterior cortex for graft placement. If the deformity is mild, keep the anterior cortex intact.
- **Graft Placement:** Extract a scapular bicortical graft. Reopen the osteotomy, insert the graft, and ensure



**Figure 26.** Intraoperative photograph of a glenoid osteotomy with scapular spine autograft in place.

the humeral head aligns with the glenoid. Close the surrounding soft tissues, typically stabilizing the graft without needing pin or screw fixation (Figure 26).

- **LD-TM transfer insertion if performed:** Insert the tendons into the supraspinatus-infraspinatus footprint of the greater tuberosity with the shoulder in ABD 20-30 degrees, ER ~40 degrees. Positioning

in excessive external rotation may reduce internal rotation. Reattach the deltoid to the acromion.

- **Immobilization:** Apply a spica cast in adduction, ER as noted previously.
- **Postoperative Care:** Consider a CT scan post-surgery to check the correction and graft placement. Maintain cast immobilization for 6 weeks, followed by 6 weeks of therapy to strengthen the transfer and avoid contractures, especially in ABD and ER.

### Latissimus Dorsi-Teres Major versus Lower Trapezius Transfer

Latissimus dorsi-teres major to greater tuberosity transfer has been studied extensively. Waters and Bae showed significant postoperative improvements in glenoid version, humeral head position, and functional movement scores with open joint reduction and LD-TM tendon transfers.<sup>11</sup> Kozin et al. observed similar findings with arthroscopic reduction and LD-TM transfers.<sup>26</sup>

Regarding the lower trapezius tendon transfer, Bertelli,<sup>24</sup> Garcon et al.,<sup>27</sup> and Crepaldei et al.<sup>28</sup> all published small case series of BPBI patients with improved active ER function after LT transfer. Our internal case series of six BPBI children who underwent lower trapezius transfer revealed markedly improved ER function by active movement scores.

A common critique of LD/TM transfer is concern for postoperative internal rotation deficits.<sup>29-32</sup> LT transfer spares internal rotation muscles.

In summary, the lower trapezius tendon transfer to the infraspinatus tendon for BPBI is a promising alternative to latissimus dorsi and/or teres major transfers. It offers similar outcomes in restoring external rotation without risking the loss of functional internal rotation. The choice of technique depends on the patient's shoulder abduction. Both techniques are used with joint reduction as needed and are valuable tools for brachial plexus surgeons performing tendon transfers for shoulder deficits.

### Case Examples as Present "State of Art" Guidelines for Restoring Shoulder Function Following BPBI

The following case examples cover a broad spectrum of patients with limited shoulder function following BPBI. Presentations and treatment recommendations differ by age of presentation, clinical exam, amount of recovery, and previous treatment history. In our experience, they represent common case presentations and describe the authors' preferred management.

#### Patient 1: Spinal Accessory Partial Nerve Transfer to Restore Active External Rotation

**Presentation:** This patient presents in the age range of 9-15 months after previously recovering biceps function (i.e., positive elbow flexion) at 5 months. They have been treated by natural history alone up to this point. They have not recovered external rotation or deltoid function but have intact triceps function (i.e., positive elbow extension). Their passive external rotation in adduction is >60 degrees (i.e., no joint contracture) and MRI findings demonstrate Type I/II glenohumeral dysplasia.

**Treatment:** In this patient, we would elect for a spinal accessory nerve (CNXI) to suprascapular nerve transfer for active external rotation as well as triceps motor branch of radial nerve to the anterior division of the axillary nerve for abduction recovery (Figure 5).

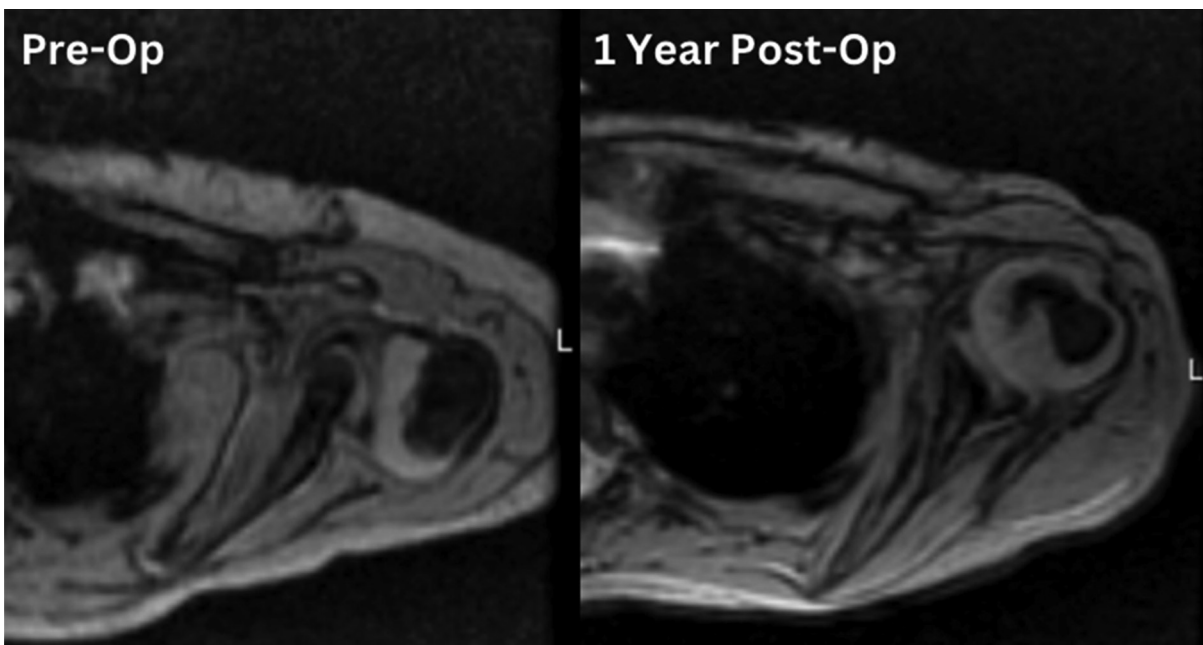
**Rationale:** Given that this patient is less than 15 months old they are young enough to still benefit from nerve transfer. Additionally, they do not have significant glenohumeral contracture or dysplasia and therefore do not meet requirements for joint release, reduction, and/or tendon transfer.

#### Patient 2: Combined Arthroscopic Contracture Release-Glenohumeral Joint Reduction-Tendon Transfer for Active External Rotation

**Presentation:** The patient presents in the age range of 18-36 months. The patient has had recovery of biceps and deltoid function by 5 months. They have a passive



**Figure 27.** Preoperative clinical exam of patient demonstrating, from left to right, limited active external rotation, a decreased scapulohumeral angle, and normal finger-to-nose and active internal rotation.



**Figure 28.** Preoperative MRI demonstrating Type III glenohumeral dysplasia (left). One-year postoperative MRI following open reduction, capsular release, and LD-TM transfer showing remodeled glenohumeral joint.

external rotation  $<30$  degrees and have absence of active external rotation (Figure 27). Prior treatments include rigorous, supervised physical therapy and botox injections with spica casting. On MRI, this patient has Type III glenohumeral dysplasia.

**Treatment:** In this patient, we would elect for an arthroscopic release and joint reduction and tendon transfer. We prefer the lower trapezius transfer to restore external rotation although an open reduction with latissimus dorsi-teres major transfer is also appropriate here.



**Rationale:** In this age range, there is minimal benefit to primary nerve reconstruction, as there is no literature to support further nerve recovery at this stage. The LTT is our tendon transfer of choice due to its improved biomechanical properties compared to the LT-TM transfer and it preserves internal rotation power. Arthroscopic release and reduction are warranted here given evidence of internal rotation contracture with passive ER ROM <30 degrees. The combination of contracture release, joint reduction, and tendon transfer for muscle rebalancing has a high likelihood in Types I-early III, and reasonable likelihood in Types III-IV, of not only improved function short term, but joint remodeling that can preserve functional gains long-term (Figure 28).

### Patient 3: Lower Trapezius Tendon Transfer for Active External Rotation

**Presentation:** This patient presents in the age range of 2 to 5 years old. They have either recovered biceps and deltoid function by the age of 5 months old or after nerve reconstruction surgery in infancy. Passive external rotation ROM >60 degrees has been maintained. However, the patient is unable to actively externally rotate at the shoulder. On MRI, the patient has Type I-II glenohumeral dysplasia.

**Treatment:** Isolated lower trapezius transfer (Latissimus dorsi-teres major transfer is also appropriate).

**Rationale:** This patient is too old for a nerve transfer to be beneficial. There is no evidence of an internal rotation contracture or glenohumeral dysplasia, so treatment can be exclusively an extraarticular tendon transfer.

### Conclusion

Brachial plexus birth injuries present complex challenges in preserving glenohumeral development and shoulder function in infants and children. As highlighted in this review, management requires a nuanced, individualized approach considering the child's age, clinical deficits, and pathoanatomic changes. Nonsurgical techniques play a vital role early on, but surgical interventions

are often necessary to restore motion, strength, and joint integrity. The optimal timing and combination of releases, reductions, transfers, and osteotomies must balance potentially competing goals of motion, stability, and function. Advances like arthroscopic techniques and the lower trapezius transfer demonstrate promising improvements, but further research that demonstrates longitudinal outcomes is still needed.

### Additional Links

- POSNAcademy: [Nerve Transfers in Brachial Plexus Birth Palsies](#)
- POSNAcademy: [Lower Trapezius Transfer to Restore External Rotation](#)
- POSNAcademy: [Shoulder Reconstruction for Brachial Plexus Palsy](#)
- POSNAcademy: [Humeral Osteotomy via Medial Approach](#)

### Disclaimer

No funding was received. The authors report no conflicts of interest related to this manuscript.

### References

1. Lagerkvist AL, Johansson U, Johansson A, et al. Obstetric brachial plexus palsy: a prospective, population-based study of incidence, recovery, and residual impairment at 18 months of age. *Dev Med Child Neurol*. 2010;52:529-534.
2. Pöyhkä TH, Lamminen AE, Peltonen JJ, et al. Brachial plexus birth injury: US screening for glenohumeral joint instability. *Radiology*. 2010;254(1):253-260. Erratum in: *Radiology*. 2010;255(1):308.
3. Bauer AS, Lucas JF, Heyrani N, et al. Ultrasound screening for posterior shoulder dislocation in infants with persistent brachial plexus birth palsy. *J Bone Joint Surg Am*. 2017;99(9):778-783.
4. Gunes A, Gumeler E, Akgoz A, et al. Value of shoulder US compared to MRI in infants with obstetric brachial plexus paralysis. *Diagn Interv Radiol*. 2021;27(3):450-457.
5. Waters PM, Smith GR, Jaramillo D. Glenohumeral deformity secondary to brachial plexus birth palsy. *J Bone Joint Surg Am*. 1998;80:668-677.
6. Buterbaugh KL, Shah AS. The natural history and management of brachial plexus birth palsy. *Curr Rev Musculoskelet Med*. 2016;9(4):418-426.
7. Manske MC, Kalish LA, Cornwall R, et al. Reconstruction of the suprascapular nerve in brachial plexus birth injury: a comparison of nerve grafting and nerve transfers. *J Bone Joint Surg Am*. 2020;102(4):298-308.
8. O'Grady KM, Power HA, Olson JL, et al. Comparing the efficacy of triple nerve transfers with nerve graft reconstruction in upper trunk obstetric brachial plexus injury. *Plast Reconstr Surg*. 2017;140(4):747-756.

9. Waters PM, Shore BJ, Hedequist DJ, et al. Chapter 10: Brachial plexus shoulder: joint reduction, tendon transfers, humeral and glenoid osteotomies. In: *Boston Children's Hospital Illustrated Tips and Tricks in Pediatric Orthopaedic Reconstructive Surgery*. Wolters Kluwer; 2022.
10. Van Heest A, Glisson C, Ma H. Glenohumeral dysplasia changes after tendon transfer surgery in children with birth brachial plexus injuries. *J Pediatr Orthop*. 2010;30(4):371-378. Erratum in: *J Pediatr Orthop*. 2010;30(8):945.
11. Waters PM, Bae DS. Effect of tendon transfers and extra-articular soft-tissue balancing on glenohumeral development in brachial plexus birth palsy. *J Bone Joint Surg Am*. 2005;87(2):320-325.
12. Waters PM, Bae DS. The early effects of tendon transfers and open capsulorrhaphy on glenohumeral deformity in brachial plexus birth palsy. *J Bone Joint Surg Am*. 2008;90(10):2171-2179.
13. Greenhill DA, Wissinger K, Trionfo A, et al. External rotation predicts outcomes after closed glenohumeral joint reduction with botulinum toxin type A in brachial plexus birth palsy. *J Pediatr Orthop*. 2018;38(1):32-37.
14. Arad E, Stephens D, Curtis CG, et al. Botulinum toxin for the treatment of motor imbalance in obstetrical brachial plexus palsy. *Plast Reconstr Surg*. 2013;131(6):1307-1315.
15. Singh AK, Manske MC, James MA. Outcomes of botulinum toxin injection for shoulder internal rotation contractures in infants with brachial plexus birth injury. *J Hand Surg Am*. 2020;45(12):1186.e1-1186.e6.
16. Pichon F, Carlioz H. La désinsertion du muscle sous-scapulaire dans le traitement de la paralysie obstétricale du membre supérieur. *Chir Pediatr*. 1979;20(2):135-141. [French].
17. Shah MM, Naik N, Patel T, et al. Minimally invasive subscapularis release: a novel technique and results. *J Pediatr Orthop*. 2020;40(6):e466-e472.1.
18. Andrés-Cano P, Toledo MÁ, Farrington DM, et al. Arthroscopic treatment for internal contracture of the shoulder secondary to brachial plexus birth palsy: report of a case series and review of the literature. *Eur J Orthop Surg Traumatol*. 2015;25(7):1121-1129.
19. Pearl ML. Arthroscopic release of shoulder contracture secondary to birth palsy: an early report on findings and surgical technique. *Arthroscopy*. 2003;19(6):577-582.
20. L'Episcopo JB. Tendon transplantation in obstetrical paralysis. *Am J Surg*. 1934;25(1):122-125.
21. Hoffer MM, Wickenden R, Roper B. Brachial plexus birth palsies. Results of tendon transfers to the rotator cuff. *J Bone Joint Surg Am*. 1978;60(5):691-695.
22. Elhassan B. Lower trapezius transfer for shoulder external rotation in patients with paralytic shoulder. *J Hand Surg Am*. 2014;39(3):556-562.
23. Elhassan B, Bishop AT, Shin A. Trapezius transfer to restore external rotation in a patient with brachial plexus injury. A case report. *J Bone Joint Surg Am*. 2009;91(4):939-944.
24. Bertelli JA. Lengthening of subscapularis and transfer of the lower trapezius in the correction of recurrent internal rotation contracture following obstetric brachial plexus palsy. *J Bone Joint Surg Br*. 2009;91(7):943.
25. Valenti P, Puig Dubois J, Werthel JD, et al. Surgical technique: lower trapezius transfer in paediatric paralytic shoulder. *Tech Hand Up Extrem Surg*. 2022;26(1):18-22.
26. Kozin SH, Boardman MJ, Chafetz RS, et al. Arthroscopic treatment of internal rotation contracture and glenohumeral dysplasia in children with brachial plexus birth palsy. *J Shoulder Elbow Surg*. 2010;19(1):102-110.
27. Garcon C, Abdelnour H, Jeandel C, et al. Change in shoulder external rotation strength and motion after lower trapezius transfer to the infraspinatus in children with obstetric brachial plexus palsy. *Int Orthop*. 2021;3:3163-3170.
28. Crepaldi BE, Neto JQL, Rezende MR, et al. Lower trapezius transfer for patients with brachial plexus injury. *Hand (N Y)*. 2019;14(2):179-186.
29. Greenhill DA, Smith WR, Ramsey FV, et al. Double versus single tendon transfers to improve shoulder function in brachial plexus birth palsy. *J Pediatr Orthop*. 2019;39(6):328-334.
30. Ozkan T, Aydin A, Onel D, et al. [Reconstruction of shoulder abduction and external rotation in obstetric brachial plexus palsy]. *Acta Orthop Traumatol Turc*. 2004;38:161-169.
31. Oztürk K, Bülbül M, Demir BB, et al. Reconstruction of shoulder abduction and external rotation with latissimus dorsi and teres major transfer in obstetric brachial plexus palsy. *Acta Orthop Traumatol Turc*. 2010;44(3):186-193.
32. Terzis JK, Kostas I. Reconstruction of shoulder abduction and external rotation in obstetrical brachial plexus palsy patients. *Semin Plast Surg*. 2005;19(1):56-65.