



Contents lists available at ScienceDirect

International Journal of Surgery Case Reports

journal homepage: www.casereports.com

Primary breast leiomyosarcoma with metastases to the lung in a young adult: Case report and literature review

Melissa Amberger^{a,d,*}, Timothy Park^{a,c}, Bert Petersen^{b,d}, Gerard A. Baltazar^{a,c,d}

^a Division of General Surgery, Department of Surgery, SBH Health System, 4422 Third Avenue, Bronx, NY 10457 USA

^b Division of Breast Surgery, Department of Surgery, SBH Health System, 4422 Third Avenue, Bronx, NY 10457 USA

^c College of Osteopathic Medicine, New York Institute of Technology, PO Box 8000, Old Westbury, NY 11568 USA

^d School of Medicine, City University of New York, 160 Convent Avenue, New York, NY 10031 USA

ARTICLE INFO

Article history:

Received 17 March 2018

Accepted 6 April 2018

Available online 16 April 2018

Keywords:

Breast

Cancer

Neoplasm

Leiomyosarcoma

Metastatic

ABSTRACT

INTRODUCTION: Primary leiomyosarcomas of the breast are extremely rare. Because of this rarity, only a small number of studies have been published about the disease; diagnosis, treatment, and prognosis are not well-described. Our work has been reported in line with the SCARE criteria.

PRESENTATION OF CASE: We present a 20-year-old female with primary breast leiomyosarcoma who despite mastectomy, developed lung metastases three years later.

DISCUSSION: We discuss the rarity of breast leiomyosarcoma and risk of metastatic disease even with treatment. We review the literature and provide an outline of available data to shed light on the best strategies to manage this aggressive disease.

CONCLUSION: Physicians and surgeons treating breast leiomyosarcoma must be vigilant of potential lung metastases in order to optimize short- and long-term oncologic outcomes.

© 2018 The Authors. Published by Elsevier Ltd on behalf of IJS Publishing Group Ltd. This is an open access article under the CC BY-NC-ND license (<http://creativecommons.org/licenses/by-nc-nd/4.0/>).

1. Introduction

Primary breast sarcoma is an uncommon neoplasm with incidence of 0.5–1%. Breast leiomyosarcoma (LMS) is a rare subtype of breast sarcoma, constituting 5–10% of breast sarcomas [2], making it an extraordinarily rare malignancy. There are less than 70 documented cases in the literature, the majority of which are case reports, with the earliest appearing in 1968.

Because of this rarity, diagnosis and treatment have been historically non-uniform; however, more recent literature has described a more consistent approach.

In this case report, we describe a primary breast LMS in a premenopausal adult female who despite mastectomy, developed metastatic disease in the lung.

2. Presentation of case

A 20-year-old female patient with a past medical history of neurofibromatosis type 1, presented with a three centimeter palpable left breast mass at the inferior aspect of the nipple-areolar complex at the 6 o'clock position. The mass reportedly developed after sustaining blunt trauma to the left breast. Initial ultrasound revealed a likely hematoma. However, at a three-month follow up for repeat ultrasound, the mass had increased in size.

Excisional biopsy revealed a 27 millimeter leiomyosarcoma with marked nuclear pleomorphism and 30 abnormal mitotic figures for every 10 high powered field. Immunohistochemical stain was positive for smooth muscle actin, vimentin, desmin, and CD68 but negative for cytokeratin 7 and S-100. Her staging was Stage IIA.

Metastatic work-up included negative chest x-ray and positron emission tomography – computed tomography (PET-CT). PET-CT identified retroareolar soft tissue density in the left breast indicative of metabolic activity with a standardized uptake value of 8.8.

In addition, metabolic activity was seen in the left axillary lymph node. Because of the fear of recurrence of the LMS, a left breast total mastectomy was performed with two sentinel lymph node specimens. Both nodes had no evidence of LMS; however, the left breast was positive for residual LMS without lymphovascular invasion.

Two years and eight months after mastectomy, workup in the emergency department for complaints of dyspnea, coughs, and chest pain revealed a lung nodule. Chest computed tomography revealed a large right sided mass (14.3 × 13.9 × 11.1 cm) involving all lobes of the right lung and extending into the mediastinum as well as a moderate-sized pericardial effusion. Pericardial window drained bloody fluid of which cytology demonstrated no malignant cells. Pericardial biopsy revealed fibrinous pericarditis with neutrophils, lymphocytes, fibrin and fibroblasts without the presence of any malignant cells. Core needle biopsy confirmed metastatic LMS to the lung (Fig. 1).

After treatment of the pericardial effusion, she was transferred to a tertiary care center with sarcoma specialists to be enrolled in a clinical trial for further treatment of her metastatic disease.

* Corresponding author at: 4422 Third Avenue, Bronx, NY, 10457, USA.
E-mail address: mamberger@sbhny.org (M. Amberger).

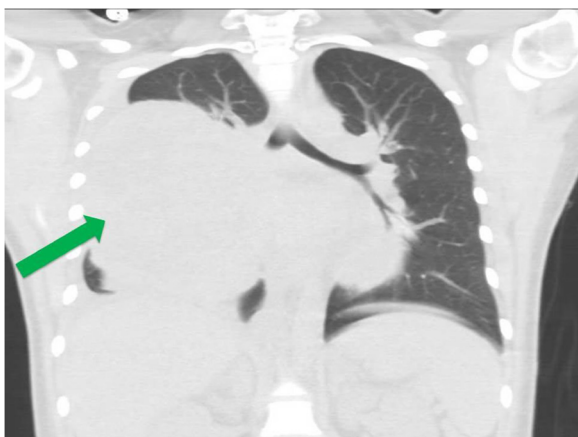


Fig. 1. Coronal section from computed tomography of the chest, demonstrating large breast leiomyosarcoma metastasis to the lung in right hemithorax with mediastinal extension (GREEN ARROW).

3. Discussion

Although sarcomas can occur anywhere in the body, less than 1% of all breast neoplasms consist of sarcomas [2–5]. LMS is a rare subtype of breast sarcoma. The diagnosis of breast LMS is generally post-menopausal [4,5]. Due to its rarity, in all age groups, there have been 68 documented cases in the literature, mostly isolated case reports—to our knowledge, ours is the first manuscript to detail all case reports of breast LMS (Table 1).

Clinically, breast LMS may be difficult to distinguish from other breast neoplasms especially since physical exam and imaging findings are often identical to other types of malignancy. Typically, at diagnosis, breast LMS may be several centimeters in diameter and well-circumscribed [4,6]. Mammogram, ultrasound, and other imaging modalities are also typically non-specific [6]. The masses are often mistaken for benign etiologies, but more commonly mistaken for more common breast malignancies, as there are no characteristic imaging features of these tumors.

Definitive diagnosis relies on the results or core needle [6], or excisional biopsy. Histologically, potential origin of the malignant cells include; blood vessel smooth musculature, smooth muscle of the nipple areolar complex, or malignant transformation from benign neoplasms, such as leiomyoma or other spindle cell tumors [2,7].

Diagnostic histologic characteristics consist of interlacing spindle cell bundles [2,4] with further grading via degree of atypia, mitotic activity, cellularity, and nuclear pleomorphism [4].

Diagnosis is confirmed with immunohistochemical stains. LMS stains positive for smooth muscle actin, desmin, vimentin, and muscle specific actin [2,4,6,7] and negative for S-100, cytokeratins, and epithelial markers [2,6,7]. Clinical staging follows standard TMN classification for breast malignancy.

Treatment of early-stage disease is initially operative – local resection or mastectomy. LMS tends to recur locally; thus, the local resection would be inadequate unless wide negative margins are achieved [5,6,8]. Fujita et al. have recommended a negative margin of at least three centimeter for maximum effectiveness; however two centimeter margins can be utilized for breast conservation therapy [8].

Furthermore, because hematogenous dissemination is the main route of metastasis, there have been no documented case of axillary lymph node invasion; thus, it is possible that lymph node dissection is unnecessary [3,5,7,8]. However, because of the rarity of this disease and limited number of studies to guide treatment decisions,

sentinel lymph node biopsy is often done to confirm no lymph node involvement [8].

Chemotherapy and radiotherapy have unclear benefit. Radiotherapy has been recommended after local excision [8]. Chemotherapy, is indicated for metastatic disease however the effect on morbidity and mortality, and benefit is unclear [2,7]. Chemotherapy parallels treatment for other types of sarcoma. Anthracyclines are currently considered the first line chemotherapy with the addition of ifosfamide [6]. However, Fujita et al. describe two cases that resulted in effective chemotherapy treatment with cycles of vincristine, adriamycin, cyclophosphamide, and dacarbazine [8].

Metastasis of breast LMS most often occurs in the lungs and bones; however, it may also disseminate to other less common organs. Because LMS is generally very slow growing, development of metastatic disease may occur years after the initial resection [7] similar to our case. In addition, Liang et al. describe situations where metastasis to the liver and brain occurred 16 and 20 years after the initial treatment of breast LMS, respectively [4].

The risk of metastasis seems to be unrelated to tumor size [7]. Isolation of circulating tumor cells (CTC) during the early stages of invasive sarcomas may detect the risk of metastatic LMS [3]. Detecting CTC would not have been possible for our patient, as she did not present with invasive disease at the initial time of diagnosis. Because sarcomas exhibit micro-dissemination within the blood for years before clinical metastatic disease develops, it is possible that detecting these CTCs to identify patients at the stage between local and distant metastatic disease will help guide clinical and therapeutic decisions [3].

Chinen et al. describe the method to isolate sarcomatous CTC simply by their physical size and not by any cellular marker; isolation by size of tumor cells has a relatively reliable sensitivity since sarcoma cells are documented to be larger than lymphocytes [3]. However, more studies are necessary for a true prognostic value of CTC detection.

Prognosis is generally optimistic compared to the other breast sarcomas [2]. Five year survival rates are 63%, 36%, and 14% for localized, regional, and distant disease respectively. However, because of the prolonged risk of recurrence, long-term follow-up may be indicated [7].

4. Conclusion

Physicians and surgeons treating breast leiomyosarcoma must be vigilant of potential lung metastases in order to optimize short- and long-term oncologic outcomes.

Conflicts of interest

Each author declares no conflicts of interest.

Sources of funding

Each author declares no sources of funding for our research.

Ethical approval

Institutional Review Board approval was obtained for this research project (SBH IRB #2017.130).

Consent

Written informed consent was obtained from the patient for publication of this case report and accompanying images. A copy

Table 1
Patients with primary breast leiomyosarcoma documented in the literature.

Author(s)	Journal	Year	Number of cases
Norris HJ and Taylor HB	<i>Cancer</i>	1968	1
Haagensen CD	<i>Diseases of the Breast</i>	1971	1
Mindan P et al	<i>American Journal of Clinical Pathology</i>	1974	1
Hernandez FJ	<i>American Journal of Clinical Pathology</i>	1978	1 ^a
Barnes L and Pietruska M	<i>Cancer</i>	1977	1
Degrell I	<i>Acta Medica Academiae Scientiarum Hungaricae</i>	1980	1
Chen et al	<i>Cancer</i>	1981	1
Gobardhan	<i>The Netherlands Journal of Surgery</i>	1984	1
Nielsen BB	<i>Virchows Archiv A</i>	1984	1
Yatsuka K et al	<i>Japanese Journal of Surgery</i>	1984	1
Callery CD et al	<i>Annals of Surgery</i>	1985	2
Yamashina M	<i>Japanese Journal of Clinical Oncology</i>	1987	1
Christensen L et al	<i>European Journal of Surgical Oncology</i>	1988	1
Arista-Nasr J et al	<i>American Journal of Clinical Pathology</i>	1989	1
Pollard SG et al	<i>Cancer</i>	1990	1
Alessi E et al	<i>The American Journal of Dermatopathology</i>	1992	1
Lonsdale RN and Widdison A	<i>Histopathology</i>	1992	1
Parham DM et al	<i>Cytopathology</i>	1992	1
Waterworth PD et al	<i>British Journal of Surgery</i>	1992	1
Bosciano A et al	<i>Tumori</i>	1994	2
Gutman H et al	<i>Surgery</i>	1994	2
Levy RD et al	<i>South African Journal of Surgery</i>	1995	1
Ugras S et al	<i>Surgery Today</i>	1997	1
North JH et al	<i>American Surgeon</i>	1998	2
Gupta RK et al	<i>Acta Cytologica</i>	2000	1
Szekely E et al	<i>Pathology & Oncology Research</i>	2001	1
Kusama R et al	<i>Pathology International</i>	2002	1
Shinto O et al	<i>Surgery Today</i>	2002	1
Lesar M et al	<i>Acta Med Croatica</i>	2003	1
Liang W et al	<i>The Breast Journal</i>	2003	1
Markaki S et al	<i>European Journal of Obstetrics & Gynecology and Reproductive Biology</i>	2003	2
Wei J et al	<i>Diagnostic Cytopathology</i>	2003	1
Zelek L et al	<i>Journal of Clinical Oncology</i>	2003	2
Saeger W	<i>Der Pathologe</i>	2004	1
Adem C et al	<i>British Journal of Cancer</i>	2004	2
Munitiz V et al	<i>The Breast</i>	2004	1
Stafyla VK et al	<i>Current Surgery</i>	2004	1
Jayaram G et al	<i>Acta Cytologica</i>	2005	1
Chirife AM et al	<i>Medicina Buenos Aires</i>	2006	1
De la Pena J and Wappier I	<i>Cases Journal</i>	2008	1
Wong LC et al	<i>Journal of Zhejiang University-SCIENCE B</i>	2008	1
Cobanoglu B et al	<i>The Breast</i>	2009	1
Boehm D et al	<i>World Journal of Oncology</i>	2010	1 ^a
Kamio T et al	<i>Surgery Today</i>	2010	1
Masannat Y et al	<i>Case Reports in Medicine</i>	2010	1 ^a
Sandhya B et al	<i>Indian Journal of Surgery</i>	2010	1
Fujita N et al	<i>The Breast</i>	2011	1
Oktay Y and Fikret A	<i>Journal of Surgical Case Reports</i>	2011	1
Karabulut Z et al	<i>Journal of Breast Cancer</i>	2012	1
Rane S et al	<i>Case Reports in Pathology</i>	2012	1
Pai M and Yoon SN	<i>Clinical Nuclear Medicine</i>	2013	1
Yener O and Aksoy F	<i>Indian Journal of Surgery</i>	2013	1
Amaadour L et al	<i>Case Reports in Oncologic Medicine</i>	2013	1
Basset P et al	<i>Journal of Surgical Case Reports</i>	2014	1
Sokolovskaya E et al	<i>F1000 Research</i>	2014	1
Kim BR et al	<i>Clinical Imaging</i>	2015	1
Tajima S et al	<i>Pathology International</i>	2015	1
Falconeri G et al	<i>American Journal of Clinical Pathology</i>	2016	2
Lee SY and Lee NR	<i>Korean Journal of Internal Medicine</i>	2016	1
M'rabet F et al	<i>Gale</i>	2017	1
TOTAL REPORTED CASES OF PRIMARY BREAST LEIOMYOSARCOMA		68	

^a Male patients.

of the written consent is available for review by the Editor-in-Chief of this journal on request.

Author contribution

MA is the primary author and contributed to writing, study concept and data collection.

TP is the secondary author and contributed to writing and data collection.

BP is the tertiary author and contributed to writing, data collection and data interpretation.

GB is the primary investigator and contributed to study concept, data collection, data interpretation and writing the manuscript.

Registration of research studies

These registrations do not seem to be appropriate for our case report.

Guarantor

Gerard A. Baltazar DO FACOS.

References

- [2] F. M'rabet, H. Kacemi, O. Mesbahi, K. Hassouni, B. Gueddari, Primary breast leiomyosarcoma: case report and literature review, *Gale* 3 (10) (2017) 620–622, <http://dx.doi.org/10.4236/health.2017.310104>.
- [3] L. Chinen, C. Mello, E. Abdallah, L.M. Ocea, M.E. Buim, N.M. Breve, J.L. Gasparini Junior, M.F. Fanelli, P. Paterlini-Bréchet, Isolation, detection, and immunomorphological characterization of circulating tumor cells (CTCs) from patients with different types of sarcoma using isolation by size of tumor cells: a window on sarcoma-cell invasion, *Gale* 16 (7) (2017) 1609–1617, <http://dx.doi.org/10.2147/OTT.S62349>.
- [4] W. Liang, B. Sickle-Santanello, T. Nims, P. Accetta, Primary leiomyosarcoma of the Breast: a case report with review of the literature, *Breast J.* 9 (6) (2003) 494–496, <http://dx.doi.org/10.1046/j.1524-4741.2003.09613.x>.
- [5] S. Rane, C. Batra, U. Saikia, Primary leiomyosarcoma of Breast in an adolescent girl: a case report and review of the literature, *Case Rep. Pathol.* 2012 (2012) 1–5, <http://dx.doi.org/10.1155/2012/491984>.
- [6] L. Amaadour, Z. Benbrahim, K. Moumna, L. Boudahna, A. Amarti, S. Arifi, N. Mellas, O. El Mesbahi, Primary Breast leiomyosarcoma, *Case Rep. Oncol. Med.* 2013 (2013) 1–4, <http://dx.doi.org/10.1155/2013/732730>.
- [7] Z. Karabulut, H. Akkaya, G. Moray, Primary leiomyosarcoma of the Breast: a case report, *J. Breast Cancer* 15 (1) (2012) 124, <http://dx.doi.org/10.4048/jbc.2012.15.1.124>.
- [8] N. Fujita, R. Kimura, J. Yamamura, K. Akazawa, T. Kasugai, F. Tsukamoto, Leiomyosarcoma of the breast: a case report and review of the literature about therapeutic management, *Breast* 20 (5) (2011) 389–393, <http://dx.doi.org/10.1016/j.breast.2011.03.001>.

Open Access

This article is published Open Access at scimedirect.com. It is distributed under the [IJSCR Supplemental terms and conditions](#), which permits unrestricted non commercial use, distribution, and reproduction in any medium, provided the original authors and source are credited.