

**REVIEW****REVIEW SERIES: IMAGING IMMUNOLOGICAL PROCESSES IN NEUROINFLAMMATORY DISEASES****Series Editor: Sandra Amor****Clinical and neuroimaging findings in MOGAD–MRI and OCT**

**Frederik Bartels<sup>1,2</sup> | Angelo Lu<sup>3,4</sup> | Frederike Cosima Oertel<sup>3,4</sup> | Carsten Finke<sup>1,2</sup> | Friedemann Paul<sup>1,3,4</sup> | Claudia Chien<sup>3,4,5</sup>**

<sup>1</sup>Department of Neurology, Charité – Universitätsmedizin Berlin, Corporate Member of Freie Universität Berlin and Humboldt-Universität zu Berlin, Berlin, Germany

<sup>2</sup>Berlin School of Mind and Brain, Berlin Institute of Health at Charité – Universitätsmedizin Berlin and, Humboldt-Universität zu Berlin, Berlin, Germany

<sup>3</sup>Humboldt-Universität zu Berlin and Max Delbrück Center for Molecular Medicine in the Helmholtz Association, Experimental and Clinical Research Center, Charité – Universitätsmedizin Berlin, Corporate Member of Freie Universität Berlin, Berlin, Germany

<sup>4</sup>NeuroCure Clinical Research Center, Charité – Universitätsmedizin Berlin, Corporate Member of Freie Universität Berlin, Humboldt-Universität zu Berlin, Berlin, Germany

<sup>5</sup>Department for Psychiatry and Neurosciences, Charité – Universitätsmedizin Berlin, Corporate Member of Freie Universität Berlin, Humboldt-Universität zu Berlin, Berlin, Germany

**Correspondence**

Friedemann Paul, Experimental and Clinical Research Center, Lindenberger Weg 80, 13125 Berlin, Germany.  
Email: friedemann.paul@charite.de

**Abstract**

Myelin oligodendrocyte glycoprotein antibody-associated disorders (MOGAD) are rare in both children and adults, and have been recently suggested to be an auto-immune neuroinflammatory group of disorders that are different from aquaporin-4 autoantibody-associated neuromyelitis optica spectrum disorder and from classic multiple sclerosis. *In-vivo* imaging of the MOGAD patient central nervous system has shown some distinguishing features when evaluating magnetic resonance imaging of the brain, spinal cord and optic nerves, as well as retinal imaging using optical coherence tomography. In this review, we discuss key clinical and neuroimaging characteristics of paediatric and adult MOGAD. We describe how these imaging techniques may be used to study this group of disorders and discuss how image analysis methods have led to recent insights for consideration in future studies.

**KEYWORDS**

magnetic resonance imaging, myelin oligodendrocyte glycoprotein associated disorders, optical coherence tomography

**OTHER ARTICLES PUBLISHED IN THIS REVIEW SERIES**

*Imaging immune responses in neuroinflammatory diseases. Clinical and Experimental Immunology 2021, 206: 248–250.*

*Magnetic resonance imaging in neuromyelitis optica spectrum disorder. Clinical and Experimental Immunology 2021, 206: 251–265.*

*Towards PET imaging of the dynamic phenotypes of microglia. Clinical and Experimental Immunology 2021, 206: 282–300.*

*Imaging immunological processes from blood to brain in amyotrophic lateral sclerosis. Clinical and Experimental Immunology 2021, 206: 301–313.*

*Neuroinflammation and immunoregulation in glioblastoma and brain metastases: Recent developments in imaging approaches. Clinical and Experimental Immunology 2021, 206: 314–324.*

*'A picture is worth a thousand words' – The use of microscopy for imaging neuroinflammation. Clinical and Experimental Immunology 2021, 206: 325–345.*

This is an open access article under the terms of the Creative Commons Attribution-NonCommercial-NoDerivs License, which permits use and distribution in any medium, provided the original work is properly cited, the use is non-commercial and no modifications or adaptations are made.

© 2021 The Authors. *Clinical & Experimental Immunology* published by John Wiley & Sons Ltd on behalf of British Society for Immunology

## INTRODUCTION

Myelin oligodendrocyte glycoprotein (MOG) immunoglobulin (Ig)G antibody-associated disorders (MOGAD) describe a new entity of demyelinating neurological syndromes defined by the presence of serum IgG autoantibodies against MOG detected by cell-based assays [1–3]. MOGAD occur in both children and adults and comprise a heterogeneous disease spectrum [4,5]. Clinical presentation can include monophasic or recurrent episodes of optic neuritis (ON), myelitis, brain stem syndromes, acute disseminated encephalomyelitis (ADEM) and symptoms of encephalitis such as seizures [6,7]. MOGAD are rare, with an incidence of 1.1–2.4 per million people [8] and are more frequent in children compared with adults, as reported in a recent Dutch cohort with an incidence of 3.1 per million in children [9].

A direct pathophysiological effect of the MOG-IgG in the central nervous system (CNS) has yet to be elucidated [2]. It remains unclear whether MOG-IgG has a direct pathogenic role or whether it is a biomarker reflecting an immunological response from disrupted myelin in the MOG-IgG-associated demyelinating disease spectrum. Increasing clinical and pathological evidence now strongly indicates that MOGAD represent a distinct disease entity different from other neuroinflammatory and demyelinating diseases, such as multiple sclerosis (MS) or aquaporin-4 (AQP4) IgG-positive neuromyelitis optica spectrum disorder (NMOSD) [10–15]. These conditions apparently exhibit differential responses to immunotherapies, underscoring the necessity for accurate and timely diagnostic procedures during which neuroimaging plays a paramount role [16–21]. Due to the widespread nervous system affection in MOGAD, magnetic resonance imaging (MRI) and optical coherence tomography (OCT) are important imaging tools in gaining more knowledge concerning the disease and for the monitoring of patients with this rare set of disorders [22,23]. This review article will give an overview of the clinical, radiological and advanced imaging aspects which are currently of high interest for the MOGAD clinical research community.

## MOGAD CLINICAL PRESENTATIONS

The clinical phenotype of MOGAD is broad, and includes uni- and bilateral anterior ON, long and short transverse myelitis (TM), ADEM, brain stem encephalitis and cortical encephalitis with or without seizures [2]. In addition, combinations of these syndromes can occur, e.g. as NMOSD-like phenotype presenting with ON and TM [12]. Importantly, the clinical phenotype strongly depends upon age, with a more ADEM-like phenotype in children

and a more optico-spinal phenotype in adolescents and adults [2]. In paediatric patients, the following four phenotypes account for 90% of MOGAD cases: 46% presenting with ADEM, 30% with ON, 11% with TM and 4% with a NMOSD-like phenotype (ON + TM) [24]. Relapses in both children and adults have been described in 40–80% of patients, especially in the form of ON [6,25–27].

## Acute disseminated encephalomyelitis

MOG-IgG serum antibodies were first identified in a subset of children with ADEM [28,29]. Children with ADEM represent the most common phenotype among all MOGAD patients, and account for almost 50% of paediatric MOGAD patients [2,24]. Clinical presentation of ADEM includes polyfocal neurological deficits and encephalopathy (i.e. behavioural changes or altered consciousness) not explainable by fever [30]. It has recently been shown that up to 50% of all children with ADEM are seropositive for MOG-IgG [31]. In these patients, MOG-IgG seroprevalence is associated with a higher risk for longitudinally extensive transverse myelitis (LETM), but with resolution of brain lesions and a better outcome compared to MOG-IgG-negative ADEM patients [32]. Relapses can occur with further episode(s) of ADEM as multi-phasic ADEM (MDEM), with ON (ADEM-ON) or with transverse myelitis (ADEM-TM) [33]. However, up to 75% of MOG-IgG-seropositive ADEM patients become seronegative within months, which highly correlates with a monophasic disease course [34]. In contrast, persistent seroprevalence of MOG-IgG is strongly associated with an increased risk for relapsing disease [35,36].

## Optic neuritis (ON)

ON is the most common clinical presentation of MOGAD in adults, comprising more than 50% of MOGAD phenotypes at onset, as shown by three large national studies from the United Kingdom, France and Sri Lanka [6,25,37]. Clinical symptoms of ON include blurred vision and reduced visual acuity or visual loss as well as eye pain, especially retrobulbar pain with eye movement [38]. ON in MOGAD is often bilateral, either concurrently or sequentially [39,40]. Up to 25% of patients present with bilateral ON at disease onset [41]. Bilateral ON represents an important clinical presentation that can help to differentiate MOGAD-ON from ON in multiple sclerosis (MS-ON). Meanwhile, the incidence of bilateral ON is less differential when evaluating its presence in MOGAD *versus* AQP4-IgG-positive NMOSD [42]. Differences include a more anterior affection of the optic nerve in MOGAD with optic nerve head swelling and retrobulbar involvement.

## Myelitis

Myelitis is the second most common clinical presentation in adult MOGAD patients as it accounts for 20% of disease-related attacks, but is less common in children [9,25,37]. LETM, defined as a spinal cord lesion spanning three or more vertebral segments in length, is a characteristic finding in MOGAD [43]. Typical symptoms include motor and/or sensory deficits (numbness), bladder, bowel and/or erectile dysfunction [43]. Neuropathic pain has been implicated in NMOSD to be related to the level(s) at which spinal cord lesion(s) are located, which could also be the case in MOGAD patients, as 86% of MOGAD patients in one study reportedly suffered from chronic pain [44–47]. Clinical differences distinguishing myelitis in MOGAD *versus* MS or AQP4-NMOSD include: a higher skew towards males, higher frequency of bladder and erectile dysfunction, younger age, prodromal infection and concurrent ADEM. Short myelitis (lesions spanning fewer than three vertebral segments) can also occur, and is found in up to 38% of MOGAD cases [48,49]. Sphincter involvement has also been found to be more prevalent in MOGAD patients with LETM compared to those with short myelitis (80 *versus* 50% [49]).

## Neuromyelitis optica spectrum disorder (NMOSD)

A combination of ON and/or myelitis is the classical clinical phenotype of NMOSD. Neuromyelitis optica (NMO) was traditionally characterized by recurrent uni- or bilateral ON and TM and was later expanded to a broader spectrum with restricted or extended forms, including brain stem syndromes, referred to NMOSD [12,50,51]. Approximately one-third of AQP4-IgG-negative NMOSD patients harbour IgG serum autoantibodies against MOG [12,52]. As the presenting phenotype in MOGAD, NMOSD occurs in 5–20% of patients [6,25,53]. Therefore, in patients with an optico-spinal phenotype, MOGAD represents an important differential diagnosis to AQP4-NMOSD, especially as the combination of myelitis with ON seems to be more common in MOGAD compared to AQP4-NMOSD [12,53,54]: up to 10% of MOGAD patients present with simultaneous ON and TM compared to only 4% in AQP4-NMOSD [12]. It should be noted that a recent large study by Tajfirouz *et al.* found that involvement of the optic chiasm was more frequent in both AQP4-NMOSD (20%) and MOGAD (16%) than have been thought previously, although MOGAD chiasmal involvement is more probably associated with a longitudinally extensive optic nerve lesion [55]. Similar to AQP4-NMOSD, MOGAD

can also present with brain stem symptoms, including intractable nausea, vomiting and hiccups, described as area postrema syndrome [56]. However, this syndrome is rare (2–5%) in MOGAD [12,57].

## Encephalitis

Epileptic seizures were repeatedly described in a subgroup of MOGAD patients and are more common than in AQP4-IgG-seropositive NMOSD [58–60], occurring in 20% of all adult and paediatric MOGAD patients [61].

Encephalitis with and without seizures is now becoming increasingly recognized as an important clinical phenotype of MOGAD [61]. Patients present with neuropsychiatric symptoms, behavioural changes, seizures and memory or speech problems [62]. Recently, encephalitis with MOG-IgG has been described as the most common type of autoimmune encephalitis in children, accounting for 34% of all children presenting with encephalitis other than ADEM [63].

## Other rare types of clinical presentation

Another rare presentation of MOGAD is found in children who show similar symptoms of ADEM with a progressive disease course [64]. The clinical course and symmetrical confluent cerebral MRI changes resemble that of children with leukodystrophy, leading to its description as a ‘leukodystrophy-like phenotype’. Recently, overlapping central and peripheral nervous system syndromes have been described as potential additional MOGAD phenotypes, including cranial nerve involvement, myeloradiculitis, inflammatory neuropathies and combined central and peripheral demyelination syndromes [65–69].

## MRI IN MOGAD

MRI abnormalities in MOGAD can be detected in the brain, the optic nerve and/or the spinal cord, depending upon the clinically affected anatomical region of the nervous system [70]. MOGAD patients are often scanned after a first presentation of ON, LETM and/or other clinical symptoms; thus, most imaging findings are cross-sectional and follow-up imaging data is scant. On cerebral MRI, findings in children mainly reflect signs of ADEM with diffuse, widespread white matter T2 lesions, while in adults cerebral MRI is either normal or shows brain stem or cortical lesions [2]. Acute ON can lead to swelling of the optic nerve and to severe retinal neurodegeneration over time [71–74]. Typical MRI findings of ON in MOGAD are

**TABLE 1** Comparisons of MRI findings in adult versus paediatric MOGAD patients

MRI finding	Adult MOGAD	Paediatric MOGAD
Brain		
Typical ADEM-like lesions <sup>a</sup>	(−)	+ <sup>b</sup>
Brain stem lesions	+ <sup>c</sup>	(+)
Cortical lesions	+	(+)
Optic nerve		
Extensive optic neuritis <sup>d</sup>	+	+
Optic perineuritis <sup>e</sup>	(+)	(−)
Spinal cord		
LETM <sup>f</sup>	+	+
Short myelitis	+	+

<sup>a</sup>Acute disseminated encephalomyelitis (ADEM): widespread supra- and infratentorial, asymmetrical diffuse white matter T2-hyperintense lesions.

<sup>b</sup>In 40–50% of paediatric adult myelin oligodendrocyte glycoprotein associated disorders (MOGAD) cases.

<sup>c</sup>In up to 30% of MOGAD patients.

<sup>d</sup>Extensive (uni-/bilateral) anterior T2 hyperintense optic nerve lesions, nerve swelling and gadolinium enhancement.

<sup>e</sup>Perineural or periorbital gadolinium enhancement in the orbital soft tissue.

<sup>f</sup>Longitudinally extensive transverse myelitis (LETM): spinal cord lesion spanning three or more vertebral segments in length.

long lesions in the anterior part of the optic nerve with periorbital enhancement and often bilateral affection [42]. Spinal cord lesions in MOGAD can be visualized using MRI typically showing LETM affecting mainly the grey matter, as seen as an ‘H-sign’ on the axial plane [43]. Important differential disease diagnoses via MRI findings in MOGAD include its distinction from MS and AQP4-IgG seropositive NMOSD [75,76]. The following sections describe common radiological presentations found in both adult and paediatric MOGAD (Table 1), as well as advanced MRI techniques with the potential to further evaluate CNS changes in these disorders. Table 1 indicates the likelihood of observing these radiological features, where positive (greater) and negative (lesser) symbols denote comparative prevalence between the adults and paediatric patients. Brackets around the positive and negative symbols denote rare observations.

## Radiological presentation on clinically routine MRI

### Cerebral MRI

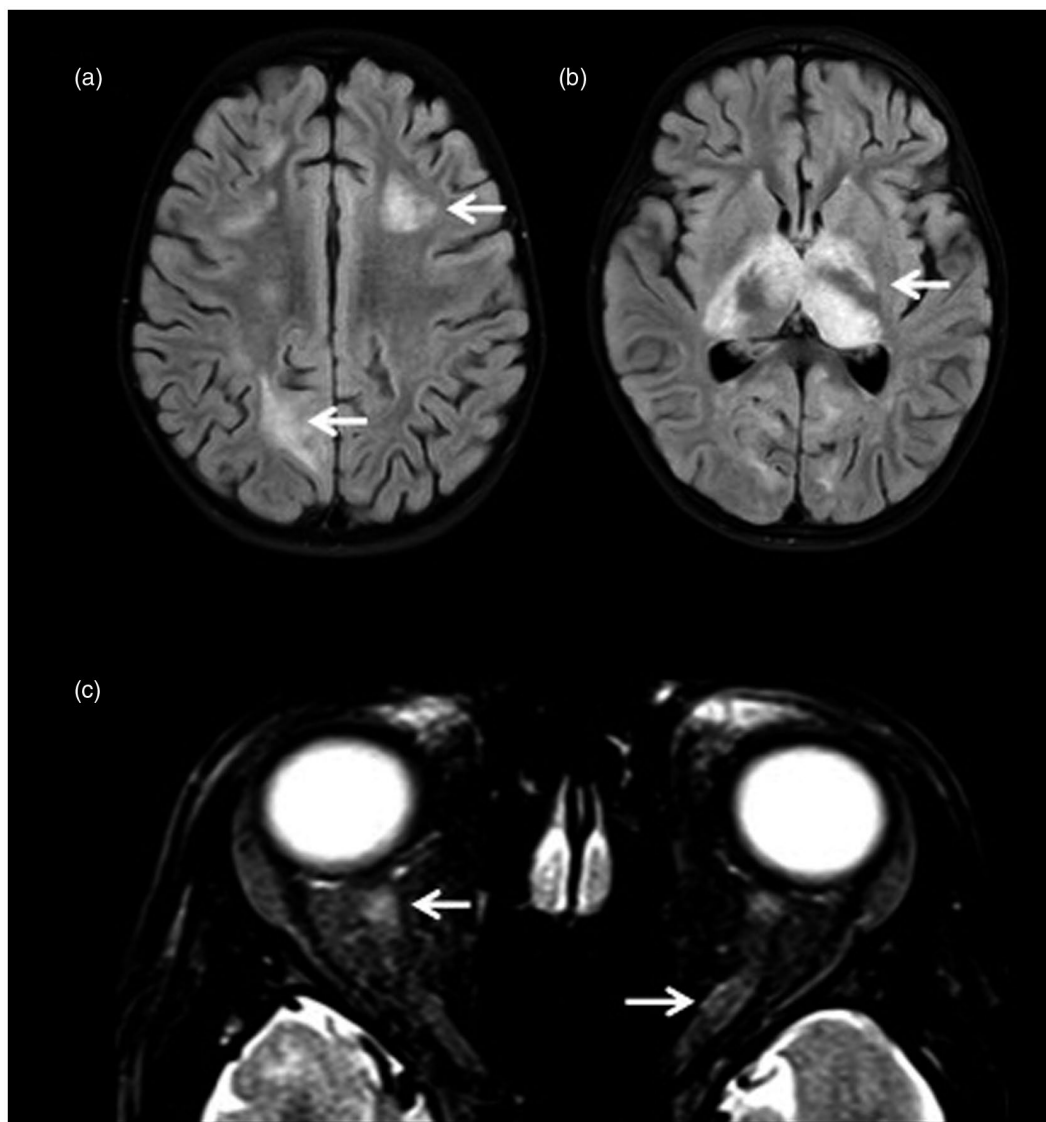
Cerebral MRI changes in MOGAD are highly dependent upon age. In children, typical MRI findings of ADEM are found in 40–50% of MOGAD cases [7]. These include

widespread supra- and infratentorial, asymmetrical diffuse white matter T2 hyperintense lesions [32,77]. In a small cohort, additional bilateral thalamic lesions were found in more than 80% of paediatric MOG-IgG-positive compared to only 10% of MOG-IgG-negative ADEM patients [78]. In adults, brain MRI lesions are typically few and either found infratentorially or presenting as cortical lesions [79,80]; however, there have been observations of large, confluent T2 hyperintense lesions in the white matter similar to ADEM [11].

Brain stem lesions can be found in up to 30% of adult MOGAD patients [6,81]. These lesions are typically poorly demarcated, located in the pons around the fourth ventricle or the cerebellar peduncles, and resolving over time [79]. Isolated brain or brain stem lesions in adults are rare (approximately 5%). However, brain lesions are found in 45% of initial cerebral MRI scans in adult MOGAD patients, mainly in combination with optico-spinal lesions [6]. One patient presented with an initial MRI pattern typical of chronic lymphocytic inflammation with pontine perivascular enhancement responsive to steroids (CLIPPERS) and then subsequently developed LETM leading to a diagnosis of MOGAD [82].

Isolated T2 hyperintense cortical lesions visible on fluid-attenuated inversion recovery (FLAIR) sequences in both adult and paediatric patients with seizures were identified and referred to as FLAMES: FLAIR-hyperintense lesions in anti-MOG-associated encephalitis with seizures [80,83]. In these patients, cerebral MRI reveal unilateral or bilateral cortical T2 hyperintense lesions, but can also include deep grey matter, white matter and brain stem lesions [58,60,84]. In paediatric MOG-associated autoimmune encephalitis, cerebral MRI findings include extensive cortical and/or subcortical grey matter involvement without the typical white matter lesions seen in ADEM [4,63]. Importantly, cerebral MRI in these children was normal in only 9% of the cohort, which is comparatively lower than other types of autoimmune encephalitis such as anti-N-methyl-D-aspartic acid or N-methyl-D-aspartate (NMDA)-receptor encephalitis, where MRI can be normal in 50% of the patients [85]. In young children presenting with the rare leukodystrophy-like MOGAD phenotype, cerebral MRI shows extensive confluent symmetrical white matter lesions with progression over time [64].

As MOGAD represents an important differential diagnosis from MS and AQP4-NMOSD, several studies have assessed potential differences using radiological features on MRI. A distinct pattern of MRI lesions defined by the so-called Matthews–Jurynczyk criterion can help to differentiate MOG-NMOSD *versus* MS. This criterion strongly favours MS over MOGAD, when: (i)  $\geq 1$  lesion(s) adjacent to a lateral ventricle and in the inferior temporal lobe, (ii) subcortical U-fibre lesions and (iii) Dawson’s finger-type

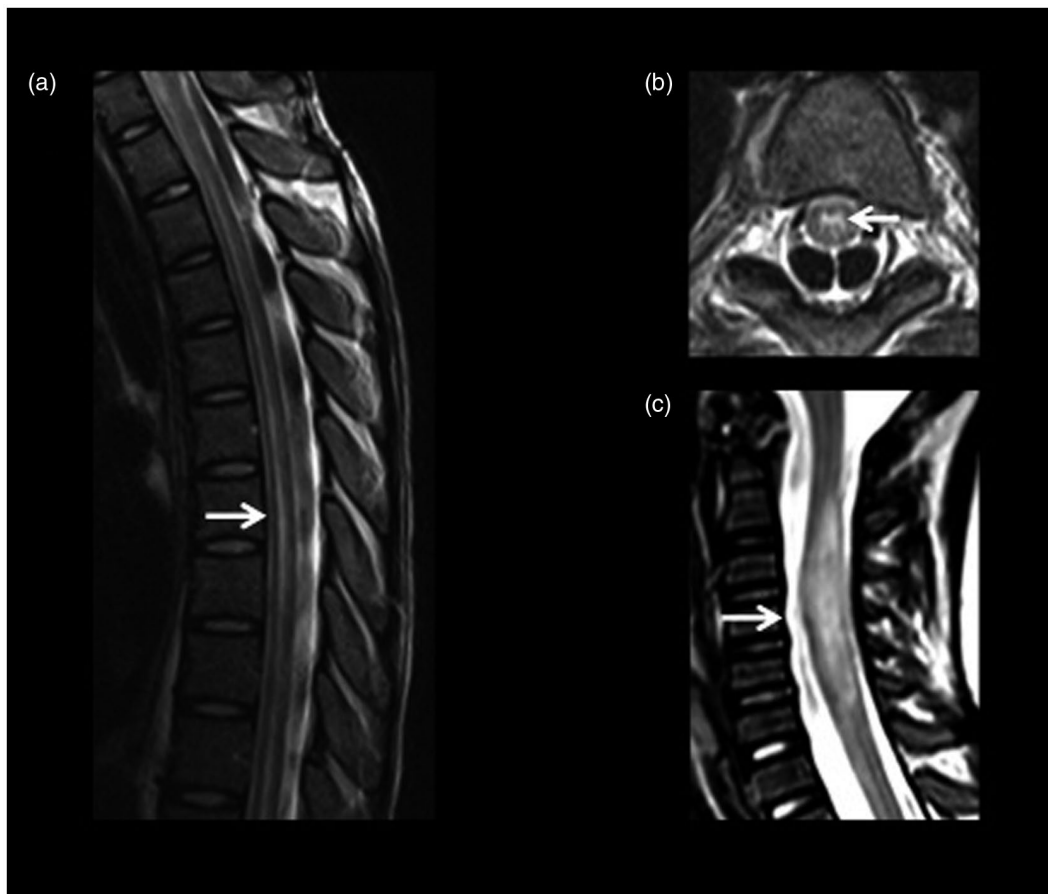


**FIGURE 1** Cerebral magnetic resonance imaging (MRI) in paediatric myelin oligodendrocyte glycoprotein-associated disorders (MOGAD). (a,b) Axial T2-weighted fluid-attenuated inversion recovery (FLAIR) MRI sequences of a 3-year-old female MOG-immunoglobulin (Ig)G-positive acute disseminated encephalomyelitis (ADEM) patient showing bilateral white matter and deep grey matter thalamic lesions. (c) Axial T2-weighted MRI sequence of a 12-year-old female patient with MOG-immunoglobulin (Ig)G-positive ADEM and bilateral optic neuritis (ON) showing optic nerve swelling and hyperintensity

lesions are present [79,86,87]. However, these studies did not report criteria to help to discriminate between MOGAD and AQP4-NMOSD patients [88]. Both MOGAD and AQP4-NMOSD patients can present with lesions in the brain stem [79,87], while cortical and juxtacortical lesions are more frequently found in MOGAD *versus* AQP4-NMOSD patients (57 *versus* 0%). Meanwhile, the area postrema syndrome that often affects AQP4-NMOSD patients with its corresponding MRI lesions (50%) does not seem to be a characteristic feature in MOGAD (7%) (Figure 1) [57].

MRI findings in ON can include T2 hyperintense lesions, nerve swelling and gadolinium enhancement of the

affected optic nerve on T1-weighted imaging. In MOG-ON, optic nerve lesions are usually extensive, also termed longitudinally extensive ON (LEON), affecting more than half of the pre-chiasmatic optic nerve length [42,89,90]. MOG-ON also predominantly affects the anterior part of the optic nerve. This can help with differentiating MOG-ON from AQP4-ON, which is also often extensive, but predominantly affecting the posterior part of the optic pathway (including the optic chiasm) [42,91–93]. Although MS-ON typically involves shorter segments of the optic nerve compared to both MOG-ON and AQP4-ON, bilateral ON, with bilateral radiological optic nerve involvement, is found in more than 80% of MOG-ON and



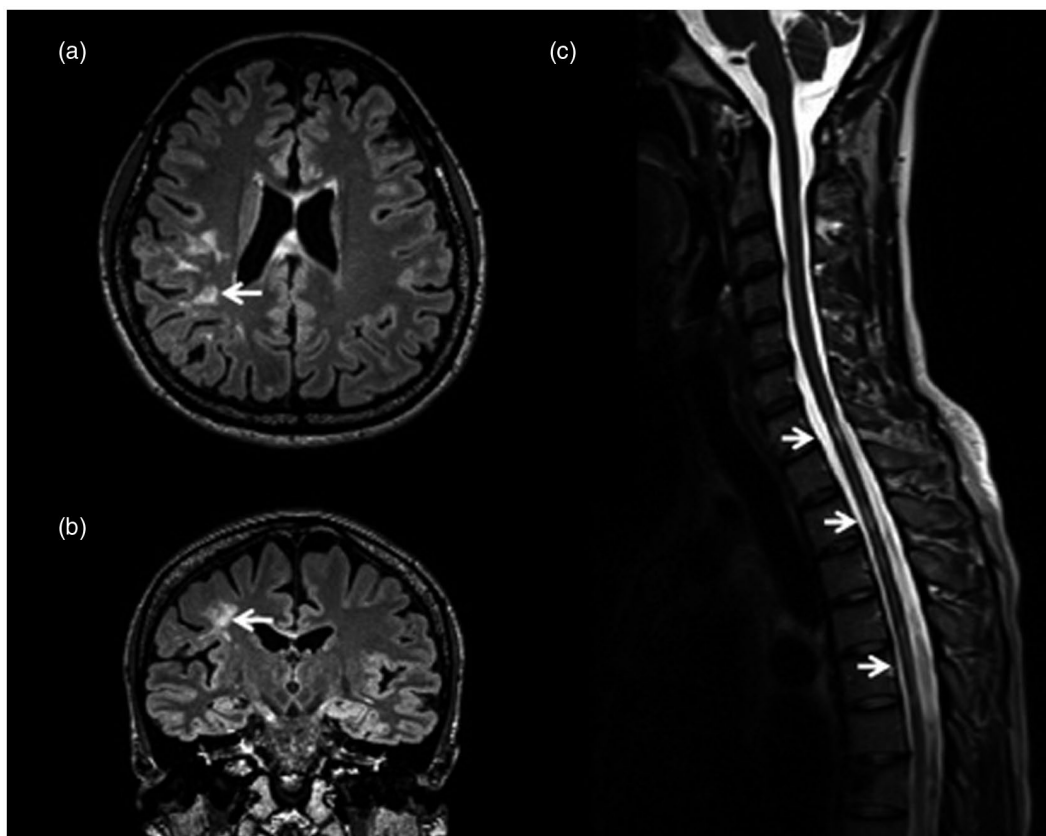
**FIGURE 2** Spinal cord magnetic resonance imaging (MRI) in paediatric myelin oligodendrocyte glycoprotein associated disorders (MOGAD). Sagittal (a) and transversal (b) T2-weighted spinal cord MRI of a 12-year-old female patient with MOG-immunoglobulin (Ig) G-positive acute disseminated encephalomyelitis (ADEM). (b) Longitudinally extensive transverse myelitis (LETM) with grey matter spinal cord affection presenting with the ‘H-sign’ and (a) as longitudinal hyperintense line. (c) Sagittal T2-weighted cervical cord MRI in a 3-year-old female patient with MOG-IgG-seropositive ADEM (the same patient shown in Figure 1a,b)

AQP4-ON patients compared to only 20% in MS-ON [41]. Additionally, in paediatric patients, bilateral ON has been associated with higher MOG-IgG titres [39,42]. Another characteristic feature described in MOG-ON is perineuritis with perineural or periorbital gadolinium enhancement in the orbital soft tissue that is not typically found in MS-ON (Figure 2) [53,89,90,94–96].

### Spinal cord MRI

Typical spinal cord MRI changes in both children and adult MOGAD patients are TM, often in the form of LETM, but also as short myelitis [12,48]. LETM is found in more than 70% of MOGAD patients with spinal cord involvement, mainly affecting the cervical and/or thoracic cord [43,49,53,77]. LETM is also a main radiological feature in AQP4-NMOSD [48]. Conus involvement and multiple spinal cord lesions

have been more frequently observed in MOG-TM (40%) than in AQP4-TM (15%) together with multiple lesions observed 60% of the time in MOGAD [43,97,98]. Short myelitis, which is typical of MS, can similarly be found in MOG-TM (up to 50% of cases); however, it is less frequently observed (~15%) in AQP4-TM patients [27,43,49,99,100]. MOG-TM may present in spinal cord MRI as a hyperintense ‘H-sign’ observed in the axial orientation, while imaged as a longitudinal thin vertical line in the T2-weighted sagittal plane image. This suggests a predominant affection of the spinal cord grey matter, as opposed to AQP4-TM, which may not be as centrally located in the cord [43,101,102]. Gadolinium contrast-enhancement of spinal cord lesions is detected in only 25% of MOG-TM cases compared to lesions in MS (75%) or AQP4-TM (80%) [43]. Of note, spinal cord MRI can initially be normal in up to 10% of MOGAD patients with myelitis attacks (Figure 3) [103].



**FIGURE 3** Adult myelin oligodendrocyte glycoprotein-associated disorders (MOGAD) patient cerebral and spinal cord affection. (a) T2-weighted fluid-attenuated inversion recovery (FLAIR) magnetic resonance imaging (MRI) sequence in the axial orientation showing large, confluent hyperintense lesions in the white matter. (b) In the coronal view of the same cerebral scan as in (a), it can be seen that the lesions extend toward the cortex. (c) The T2-weighted spinal cord MRI shows short segment lesions, appearing to be located centrally in the cord

### Structural and functional MRI analysis techniques

Structural and functional MRI analysis techniques include brain and spinal cord volumetric analyses, diffusion tensor imaging (DTI) and resting-state functional MRI. These techniques are usually not applied as part of the clinical routine work-up in MOGAD patients, and quantitative volumetric and/or microstructural grey and white matter analyses using advanced MRI techniques are few. Recent studies, however, have identified specific changes in MOGAD patients that are potential new imaging biomarkers and tools for a clearer understanding of MOGAD disease pathology [23,104–106].

Although brain lesion distributions have been found to differ between MOGAD and AQP4-NMOSD patients, brain MRI volumetry did not show any differences in MOGAD patients compared to healthy controls in whole brain, deep grey matter or white matter volumes [104,107]. However, there are conflicting results as to whether localized reductions in the volume of several grey matter structures exist [104,108]. In children with ADEM, reduced brain volume and failure of age-expected brain

growth was found for both MOG-IgG-seropositive and -seronegative patients (Bartels *et al.*, submitted), similar to findings in paediatric anti-NMDA-receptor encephalitis and paediatric-onset MS [7,85,109].

Spinal cord MRI analysis could identify spinal cord atrophy in patients with MOGAD compared to healthy subjects, which was found to associate with increased counts of historical myelitis attacks. However, cord lesion frequency and atrophy was found to be less frequent compared to AQP4-TM [43,105], which is in line with clinical observations that MOGAD patients often recover their motor functions more completely than AQP4-TM patients [25]. In MOG-myelitis patients, another study showed that the grey matter volume in the spinal cord was reduced during the acute phase of the attack [106], thus indicating that affection of grey matter might be a more common occurrence than previously thought. This also supports previous findings of long-term damage to cerebral grey matter.

Meanwhile, evaluating CNS changes using graph theory and network statistical methods for elucidating clinical attack-related damage in NMOSD patients has also shown promise. Both cortical topological network changes and

deep grey matter volume changes have been detected in AQP4-NMOSD patients following ON attacks and in patients with a simultaneous combination of clinical attacks [108,110]. These findings suggest that there may be non-localized damage or affection in NMOSD, which could also be the case in MOGAD, and be of interest in cognitive impairment studies in these patients.

Using DTI, one study found decreased white matter integrity in adult MOGAD patients compared to healthy controls: specifically, reduced parallel diffusivity within whole-brain white matter tracts [104]. Parallel or axial diffusivity characterizes diffusion along the long axis of the axonal tract; thus, a reduction in this measure may be associated with various mechanisms of axonal damage or injury, commonly thought to occur via Wallerian degeneration [111].

As demyelination represents a pathological hallmark in MOGAD, *in-vivo* imaging of myelin integrity could represent a promising technique to further identify disease mechanisms and disease courses in MOGAD [112]. Further studies investigating white matter abnormalities may utilize quantitative techniques, such as T1-weighted/T2-weighted intensity ratio, multi-parameter mapping and magnetization transfer MRI analysis. These advanced imaging analysis methods could help in the identification of more subtle MRI changes in MOGAD patients in the future [113–115]. Recently, the underlying pathophysiology of neuroinflammation has been evaluated using quantitative susceptibility mapping (QSM) MRI in MS. QSM is a technique that allows for the quantification of magnetic susceptibility differences in a spatial manner to measure different para- and diamagnetic atoms (such as iron atoms) within tissue [116]. In a relatively large MS cohort, it was found using QSM that depletions of myelin and iron concentration were associated with thalamic atrophy and disability [117], indicating that iron concentration in the brain is a possible biomarker in neurodegeneration related to myelin damage. Another method of evaluating molecular changes in the brain is by using hydrogen-1-magnetic resonance spectroscopy ( $^1\text{H}$ -MRS), which measures hydrogen proton concentrations attached to specific metabolites such as glutamate, choline and  $\gamma$ -aminobutyric acid (GABA). Some small studies have found conflicting results in MS patients, however, due to the complex analysis methods and confound corrections required for robust results [118]. Both QSM and MRS are relatively well established in many 1.5–3 Tesla MRI facilities, and could be imaging analyses of interest for clinical immunologists and MOGAD researchers in the future.

Proton emission tomography (PET)-MRI research has allowed for more *in-vivo* molecular imaging, where radio-nuclide tracers can be used to calculate myelin kinetics, concentrations of neuroinflammatory molecules and help

to investigate pathophysiology [119]. PET tracers rely upon the radiolabelling of antibodies or chemical chelates that bind to specific targets of interest [120]. However, to detect the radioactive decay signals, X-ray computed tomography (CT) imaging is traditionally applied to first create an image for quantification of the signal [121], and currently very few PET-MRI systems are available globally. Often, PET research is conducted using both a CT and MRI [122]. Thus, there are still some hurdles in applying this imaging method in a clinical setting, especially in rare diseases such as MOGAD.

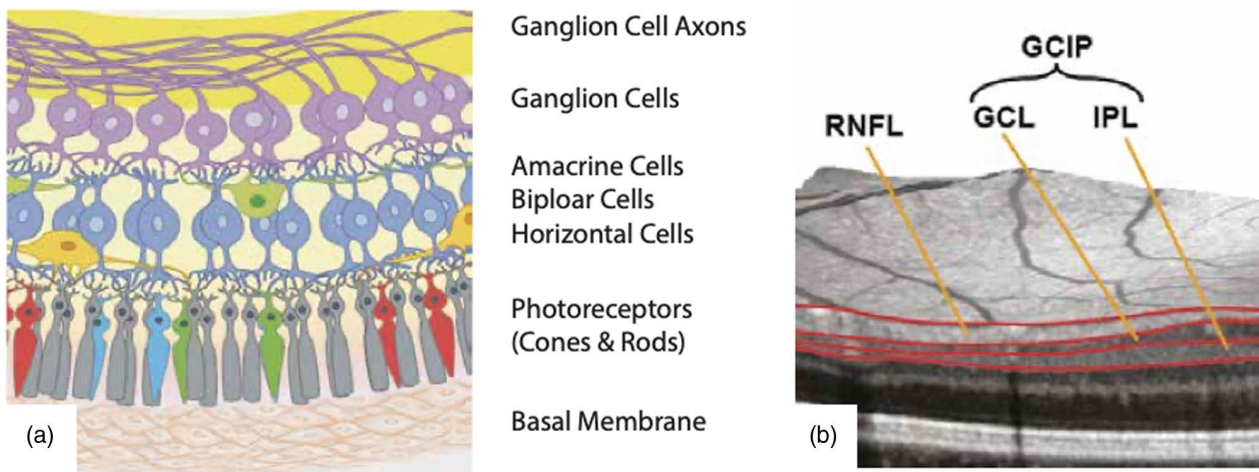
Resting-state functional MRI connectivity allows for the study of functional connectivity alterations, such as in the visual or sensorimotor networks of the brain [123–125]. Recently, it was found that altered interhemispheric function in patients with MOG-ON can be observed compared to healthy controls using resting-state functional MRI. These preliminary findings warrant further investigation into patient sensorimotor functions after an ON attack [126].

## OCT IN MOGAD

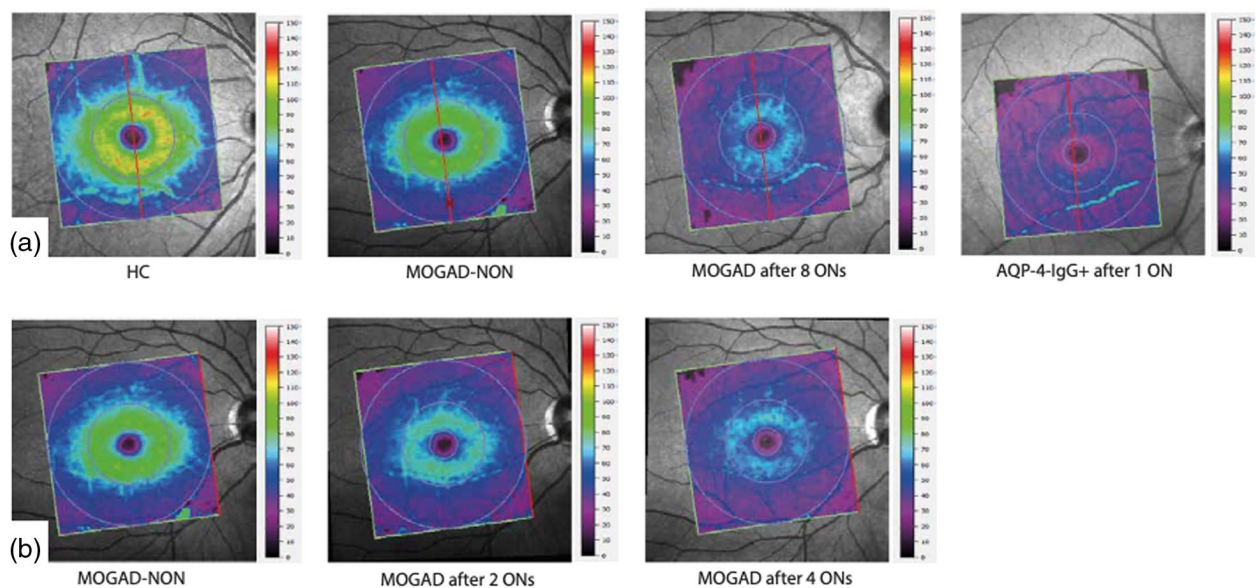
The quantitative and qualitative assessment of the retinal changes over time can be performed in close-to-cellular resolution using spectral domain optical coherence tomography (OCT) [23,72,127]. Improvement of OCT techniques in the past decade has allowed the retina to be examined in greater detail. The unprecedented resolution of down to 3.9  $\mu\text{m}$  enables measurement of retinal ganglion cell loss, evaluated by the volumes of the combined macular ganglion cell layer and inner plexiform layers (mGCIPL) and their axons, as measured by the thickness of the peripapillary retinal nerve fibre layer (pRNFL). These OCT metrics have been shown to correlate well with visual function and the damage that occurs in NMOSD and MS patients [128,129]. Thus, OCT is a valuable tool for monitoring many neuro-ophthalmological and neurological conditions, including NMOSD and MOGAD (Figure 4) [72,130,131].

Acute ON in MOGAD is often bilateral and localized in the anterior optic nerve inducing severe and characteristic retinal oedema [132]. Initially covered by the oedema, the neuroaxonal layers of the retina (pRNFL, mGCIPL) degenerate significantly during the following months (Figure 5) [23,73,127,132,133]. These losses accumulate with each additional ON episode, which occur frequently in MOGAD [73,74]. Therefore, although a single episode does not often lead to disastrous damage [91,134], the highly recurrent ON attacks accumulate with pRNFL and mGCIPL loss. This is comparable to patients with AQP4-IgG-seropositive NMOSD, which is characterized





**FIGURE 4** Retinal anatomy and optical coherence tomography. (a) Anatomical representation of the human retina and (b) the human retina as imaged using optical coherence tomography (OCT). These images have been kindly reproduced and modified under a Creative Common Licence from [www.neurodiad.de](http://www.neurodiad.de). RNFL = retinal nerve fibre layer; GCL = ganglion cell layer; IPL = inner plexiform layer; GCIP = ganglion cell and inner plexiform layer



**FIGURE 5** Macular scans from optical coherence tomography (OCT). Macular scans of various retinas with corresponding thickness scale (0–150  $\mu\text{m}$ ) with heat-maps highlighting the thickness variations across the macular ganglion cell and inner plexiform (GCIP) layer. (a) Variations in the thickness across various pathologies in different patients. (b) Right eye of the same myelin oligodendrocyte glycoprotein-associated disorders (MOGAD) patient prior to optic neuritis (ON) after two and four ONs. Thinner areas are depicted with cooler colours (purple/blue) and thicker areas depicted with warmer colours (red/yellow). HC = healthy control; MOGAD-NON: MOGAD with no history of ON; AQP-4-IgG: aquaporin-4 immunoglobulin G

by less frequent, but more damaging, ON episodes [74]. In comparison with MS, MOGAD patients are described as undergoing more severe retinal neurodegeneration after ON; however, a final consensus on this topic has not been reached [91,127,135].

Further studies are warranted to investigate retinal neurodegeneration independent of ON in MOGAD. One

study performed a first exploratory analysis in a small data set recording pRNFL loss without associated GCIP loss [136]. Apart from true retinal neurodegeneration, this could potentially be explained by a remission of attack-associated oedema, which commonly affects the RNFL more than the ganglion cell layer [137]. If the absence of ON-independent GCIP loss is confirmed, this would

not only stress the importance of ON attack-prevention in MOGAD but also allow a better separation from MS and AQP4-IgG-seropositive NMOSD, which are both affected by ON-independent retinal neuroaxonal loss.

OCT data in paediatric MOGAD are scarce. The results in paediatric cohorts generally mirror those in adults with measurable post-ON swelling and associated reduction and thinning of the pRNFL [73,138]. There are, however, conflicting reports concerning unilateral ON cases with subclinical involvement of the contralateral, clinically healthy eye, an area which would benefit from further research given the potential detrimental impact on the otherwise healthy eye [138,139].

In both paediatric and adult presentations, and notwithstanding the high relapse rates and severe neuroaxonal degeneration, high-contrast visual acuity is surprisingly preserved in MOGAD patients compared with AQP4-IgG-seropositive NMOSD patients, although both groups have comparable neuroaxonal loss [74,91,140–142]. How visual acuity is preserved in MOGAD remains unclear, but data suggest an influence of a primary retinal astrocytopathy in AQP4-IgG-seropositive NMOSD accumulating in additional retinal changes with functional consequences [143]. Nevertheless, MOGAD patients, with their high prevalence of ON attacks, are at risk of irreversible visual impairment when deprived of a timely diagnosis and preventative immunotherapy.

## CONCLUDING REMARKS

MOGAD pathophysiology, disease treatment and monitoring are currently of high interest in the autoimmune neuroinflammatory diseases research community. Currently, most known MRI and OCT characteristics in MOGAD are based on small monocentric studies that yielded some contradicting results, thus multi-centred and prospective studies are necessary to validate findings. Such multi-centred studies are beginning to shed light upon this rare disease, such as the Collaborative OCT in NMOSD (CROCTINO) and the PARallel MRI in NMOSD (PAMRINO) studies [144]. Especially in a rare and heterogeneous disease, such as MOGAD, it is pertinent to gather information on patients from varying demographic backgrounds, over larger age ranges and with standardized imaging protocols to allow for robust investigations using a variety of analysis techniques.

*In-vivo* imaging using MRI and OCT has given clinicians and researchers insights into the CNS affection of this rare disorder at an unprecedented rate. These imaging techniques will allow us to further investigate changes in the brain, spinal cord and retina of patients with a dissemination in time and space, providing the opportunity to find biomarkers of

disease-related damage and potentially predictive markers for future attacks, thus allowing for stratification of patients and real-time communication of the risk of further attacks with patients based on bioimaging markers for treatment decisions. As new technologies and analysis methods continue to be developed, together with the increase in open-sharing and collaborative, prospective studies on the horizon, we believe that both MRI and OCT will lead the way towards personalized prognostics and treatment in MOGAD.

## ACKNOWLEDGEMENTS

Funding was not provided for the writing of this review article. MRI samples from paediatric patients with MOGAD with permission from patients and care givers were kindly provided by Kevin Rostásy from the Department of Paediatric Neurology, Children's Hospital Datteln, Witten/Herdecke University, Datteln, Germany. F. Bartels is a participant in the BIH-Charité Clinician Scientist Program funded by the Charité – Universitätsmedizin Berlin and the Berlin Institute of Health. Open access funding enabled and organized by ProjektDEAL.

## CONFLICTS OF INTEREST

F. Bartels is supported by the Berlin Institute of Health (BIH) and the Berlin School of Mind and Brain, both unrelated to this review. A. Lu has no disclosures to report. F. C. Oertel receives research support from the American Academy of Neurology (AAN) unrelated to this review. C. Finke receives research funding by the Deutsche Forschungsgemeinschaft (DFG, German Research Foundation; grant numbers FI 2309/1-1 and FI 2309/2-1) and the German Ministry of Education and Research (BMBF, grant number 01GM1908D; CONNECT-GENERATE) unrelated to this review. F. Paul is named as co-inventor on the patent application for the foveal shape analysis method ('Method for estimating shape parameters of the fovea by optical coherence tomography', International Publication number: 'WO 2019/016319 A1'), is a co-founder and holds shares in technology start-up Nocturne GmbH, receives honoraria for lecturing and travel expenses for attending meetings from Guthy Jackson Foundation, Bayer, Biogen, Merck Serono, Sanofi Genzyme, Novartis, Alexion, Viela Bio, Roche, UCB, Mitsubishi Tanabe and Celgene. His research is funded by the German Ministry for Education and Research (BMBF), Deutsche Forschungsgemeinschaft (DFG), Einstein Foundation, Guthy Jackson Charitable Foundation, EU FP7 Framework Program, Biogen, Genzyme, Merck Serono, Novartis, Bayer, Alexion, Roche, Parexel and Almirall. C. Chien has received speaking fees from Bayer and research support from Novartis unrelated to this review.

## AUTHOR CONTRIBUTIONS

All authors contributed to the writing of the original draft and constructively aided in the revisions of the manuscript.

## DATA AVAILABILITY STATEMENT

As this is a review article, this is not applicable.

## ORCID

Claudia Chien  <https://orcid.org/0000-0001-8280-9513>

## REFERENCES

- Zamvil SS, Slavov AJ. Does MOG Ig-positive AQP4-seronegative opticospinal inflammatory disease justify a diagnosis of NMO spectrum disorder? *Neurol Neuroimmunol Neuroinflamm*. 2015;2:e62.
- Reindl M, Waters P. Myelin oligodendrocyte glycoprotein antibodies in neurological disease. *Nat Rev Neurol*. 2019;15:89–102.
- Reindl M, Schanda K, Woodhall M, Tea F, Ramanathan S, Sagen J, et al. International multicenter examination of MOG antibody assays. *Neurol Neuroimmunol Neuroinflamm*. 2020;7:e674.
- Wegener-Panzer A, Cleaveland R, Wendel E-M, Baumann M, Bertolini A, Häusler M, et al. Clinical and imaging features of children with autoimmune encephalitis and MOG antibodies. *Neurol - Neuroimmunol Neuroinflamm*. 2020;7:e731.
- Narayan R, Simpson A, Fritsche K, Salama S, Pardo S, Mealy M, et al. MOG antibody disease: a review of MOG antibody seropositive neuromyelitis optica spectrum disorder. *Mult Scler Relat Disord*. 2018;1:66–72.
- Cobo-Calvo A, Ruiz A, Maillart E, Audoin B, Zephir H, Bourre B, et al. Clinical spectrum and prognostic value of CNS MOG autoimmunity in adults: the MOGADOR study. *Neurology* 2018;90:e1858–69.
- Baumann M, Bartels F, Finke C, Adamsbaum C, Hacohen Y, Rostásy K, et al. E.U. paediatric MOG consortium consensus: Part 2 – Neuroimaging features of paediatric myelin oligodendrocyte glycoprotein antibody-associated disorders. *Eur J Paediatr Neurol* 2020;29:14–21.
- Hor JY, Asgari N, Nakashima I, Broadley SA, Leite MI, Kissani N, et al. Epidemiology of neuromyelitis optica spectrum disorder and its prevalence and incidence worldwide. *Front Neurol* [internet]. 2020;11. Available at: <https://www.ncbi.nlm.nih.gov/pmc/articles/PMC7332882/>. Accessed 8 Feb 2021.
- de Mol CL, Wong Y, van Pelt ED, Wokke B, Siepman T, Neuteboom RF, et al. The clinical spectrum and incidence of anti-MOG-associated acquired demyelinating syndromes in children and adults. *Mult Scler J*. 2020;26:806–14.
- Bruijstens AL, Wong YYM, van Pelt DE, van der Linden PJE, Haasnoot GW, Hintzen RQ, et al. HLA association in MOG-IgG and AQP4-IgG-related disorders of the CNS in the Dutch population. *Neurol Neuroimmunol Neuroinflamm*. 2020;7:e702.
- Höftberger R, Guo Y, Flanagan EP, Lopez-Chiriboga AS, Endmayr V, Hochmeister S, et al. The pathology of central nervous system inflammatory demyelinating disease accompanying myelin oligodendrocyte glycoprotein autoantibody. *Acta Neuropathol*. 2020;139:875–92.
- Jarius S, Paul F, Weinshenker BG, Levy M, Kim HJ, Wildemann B. Neuromyelitis optica. *Nat Rev Dis Primer*. 2020;6:1–32.
- Cobo-Calvo Á, d'Indy H, Ruiz A, Collongues N, Kremer L, Durand-Dubief F, et al. Frequency of myelin oligodendrocyte glycoprotein antibody in multiple sclerosis: a multicenter cross-sectional study. *Neurol Neuroimmunol Neuroinflamm* [internet]. 2020;7:e649. Available at: <https://nn.neurology.org/content/7/2/e649>. Accessed 2 Feb 2021.
- Kim H, Lee E-J, Kim S, Choi L-K, Kim K, Kim HW, et al. Serum biomarkers in myelin oligodendrocyte glycoprotein antibody-associated disease. *Neurol Neuroimmunol Neuroinflamm*. 2020;7:e708.
- Ferilli MAN, Valeriani M, Papi C, Papetti L, Ruscitto C, Figà Talamanca L, et al. Clinical and neuroimaging characteristics of MOG autoimmunity in children with acquired demyelinating syndromes. *Mult Scler Relat Disord*. 2021;10:102837.
- Whittam DH, Cobo-Calvo A, Lopez-Chiriboga AS, Pardo S, Gornall M, Cicconi S, et al. Treatment of MOG-IgG-associated disorder with rituximab: An international study of 121 patients. *Mult Scler Relat Disord* [internet]. 2020;44. Available at: [https://www.msard-journal.com/article/S2211-0348\(20\)30327-8/abstract](https://www.msard-journal.com/article/S2211-0348(20)30327-8/abstract). Accessed 23 Jan 2021.
- Borisow N, Mori M, Kuwabara S, Scheel M, Paul F. Diagnosis and treatment of NMO spectrum disorder and MOG-encephalomyelitis. *Front Neurol*. 2018;9:888.
- Cobo-Calvo A, Sepúlveda M, Rollot F, Armangué T, Ruiz A, Maillart E, et al. Evaluation of treatment response in adults with relapsing MOG-Ab-associated disease. *J Neuroinflamm*. 2019;16:134.
- Graf J, Mares J, Barnett M, Aktas O, Albrecht P, Zamvil SS, et al. Targeting B Cells to Modify MS, NMOSD, and MOGAD: Part 1. *Neurol Neuroimmunol Neuroinflamm* [Internet]. 2021;8:e918. Available at: <https://nn.neurology.org/content/8/1/e918>. Accessed 8 Feb 2021.
- Graf J, Mares J, Barnett M, Aktas O, Albrecht P, Zamvil SS, et al. Targeting B cells to modify MS, NMOSD, and MOGAD: Part 2. *Neurol Neuroimmunol Neuroinflamm*. 2021;8:e918.
- Li S, Ren H, Xu Y, Xu T, Zhang Y, Yin H, et al. Long-term efficacy of mycophenolate mofetil in myelin oligodendrocyte glycoprotein antibody-associated disorders: a prospective study. *Neurol Neuroimmunol Neuroinflamm*. 2020;7:e705.
- Kuchling J, Paul F. Visualizing the central nervous system: imaging tools for multiple sclerosis and neuromyelitis optica spectrum disorders. *Front Neurol*. 2020;11:450.
- Lotan I, Cosima Oertel F, Chien C, Asseger S, Paul F, Stiebel-Kalish H. Practical recognition tools of MOG-IgG positive optic neuritis and its clinical implications. *Clin Exp Neuroimmunol*. 2020;cen3.12623.
- Bruijstens AL, Lechner C, Flet-Berliac L, Deiva K, Neuteboom RF, Hemingway C, et al. E.U. paediatric MOG consortium consensus: Part 1 – Classification of clinical phenotypes of paediatric myelin oligodendrocyte glycoprotein antibody-associated disorders. *Eur J Paediatr Neurol*. 2020;29:2–13.
- Jurynczyk M, Messina S, Woodhall MR, Raza N, Everett R, Roca-Fernandez A, et al. Clinical presentation and prognosis in MOG-antibody disease: a UK study. *Brain J Neurol*. 2017;140:3128–38.
- Ramanathan S, Mohammad S, Tantsis E, Nguyen TK, Merheb V, Fung VSC, et al. Clinical course, therapeutic responses and outcomes in relapsing MOG antibody-associated demyelination. *J Neurol Neurosurg Psychiatry*. 2018;89:127–37.

27. Mariotto S, Ferrari S, Monaco S, Benedetti MD, Schanda K, Alberti D, et al. Clinical spectrum and IgG subclass analysis of anti-myelin oligodendrocyte glycoprotein antibody-associated syndromes: a multicenter study. *J Neurol*. 2017;264:2420–30.
28. O'Connor KC, McLaughlin KA, De Jager PL, Chitnis T, Bettelli E, Xu C, et al. Self-antigen tetramers discriminate between myelin autoantibodies to native or denatured protein. *Nat Med*. 2007;13:211–7.
29. McLaughlin KA, Chitnis T, Newcombe J, Franz B, Kennedy J, McArdel S, et al. Age-dependent B cell autoimmunity to a myelin surface antigen in pediatric multiple sclerosis. *J Immunol*. 2009;18:4067–76.
30. Krupp LB, Tardieu M, Amato MP, Banwell B, Chitnis T, Dale RC, et al. International Pediatric Multiple Sclerosis Study Group criteria for pediatric multiple sclerosis and immune-mediated central nervous system demyelinating disorders: revisions to the 2007 definitions. *Mult Scler*. 2013;19:1261–7.
31. Hennes E-M, Baumann M, Schanda K, Anlar B, Bajer-Kornek B, Blaschek A, et al. Prognostic relevance of MOG antibodies in children with an acquired demyelinating syndrome. *Neurology*. 2017;89:900–8.
32. Baumann M, Sahin K, Lechner C, Hennes EM, Schanda K, Mader S, et al. Clinical and neuroradiological differences of paediatric acute disseminating encephalomyelitis with and without antibodies to the myelin oligodendrocyte glycoprotein. *J Neurol Neurosurg Psychiatry*. 2015;86:265–72.
33. Baumann M, Hennes E-M, Schanda K, Karenfort M, Kornek B, Seidl R, et al. Children with multiphasic disseminated encephalomyelitis and antibodies to the myelin oligodendrocyte glycoprotein (MOG): Extending the spectrum of MOG antibody positive diseases. *Mult Scler*. 2016;22:1821–9.
34. Waters P, Fadda G, Woodhall M, O'Mahony J, Brown RA, Castro DA, et al. Serial anti-myelin oligodendrocyte glycoprotein antibody analyses and outcomes in children with demyelinating syndromes. *JAMA Neurol*. 2020;77:82–93.
35. López-Chiriboga AS, Majed M, Fryer J, Dubey D, McKeon A, Flanagan EP, et al. Association of MOG-IgG serostatus with relapse after acute disseminated encephalomyelitis and proposed diagnostic criteria for MOG-IgG-associated disorders. *JAMA Neurol*. 2018;75:1355–63.
36. Hyun J-W, Woodhall MR, Kim S-H, Jeong IH, Kong B, Kim G, et al. Longitudinal analysis of myelin oligodendrocyte glycoprotein antibodies in CNS inflammatory diseases. *J Neurol Neurosurg Psychiatry*. 2017;88:811–7.
37. Senanayake B, Jitprapaikulsan J, Aravinthan M, Wijesekera JC, Ranawaka UK, Riffy MT, et al. Seroprevalence and clinical phenotype of MOG-IgG-associated disorders in Sri Lanka. *J Neurol Neurosurg Psychiatry*. 2019;90:1381–3.
38. Toosy AT, Mason DF, Miller DH. Optic neuritis. *Lancet Neurol*. 2014;13:83–99.
39. Wendel E-M, Baumann M, Barisic N, Blaschek A, Coelho de Oliveira Koch E, Della Marina A, et al. High association of MOG-IgG antibodies in children with bilateral optic neuritis. *Eur J Paediatr Neurol*. 2020;27:86–93.
40. Chen JJ, Bhatti MT. Clinical phenotype, radiological features, and treatment of myelin oligodendrocyte glycoprotein-immunoglobulin G (MOG-IgG) optic neuritis. *Curr Opin Neurol*. 2020;33:47–54.
41. Hegen H, Reindl M. Recent developments in MOG-IgG associated neurological disorders. *Ther Adv Neurol Disord*. 2020;13:1756286420945135.
42. Ramanathan S, Prelog K, Barnes EH, Tantsis EM, Reddel SW, Henderson APD, et al. Radiological differentiation of optic neuritis with myelin oligodendrocyte glycoprotein antibodies, aquaporin-4 antibodies, and multiple sclerosis. *Mult Scler*. 2016;22:470–82.
43. Dubey D, Pittock SJ, Krecke KN, Morris PP, Sechi E, Zalewski NL, et al. Clinical, radiologic, and prognostic features of myelitis associated with myelin oligodendrocyte glycoprotein autoantibody. *JAMA Neurol*. 2019;76:301.
44. Asseyer S, Schmidt F, Chien C, Scheel M, Ruprecht K, Bellmann-Strobl J, et al. Pain in AQP4-IgG-positive and MOG-IgG-positive neuromyelitis optica spectrum disorders. *Mult Scler J Exp Transl Clin*. 2018;4:2055217318796684.
45. Asseyer S, Henke E, Trebst C, Hümmert MW, Wildemann B, Jarius S, et al. Pain, depression and quality of life in adults with MOG-antibody associated disease. *Eur J Neurol*. 2021;28:1645–58.
46. Asseyer S, Kuchling J, Gaetano L, Komnenić D, Siebert N, Chien C, et al. Ventral posterior nucleus volume is associated with neuropathic pain intensity in neuromyelitis optica spectrum disorders. *Mult Scler Relat Disord* [internet]. 2020;46. Available at: [https://www.msard-journal.com/article/S2211-0348\(20\)30653-2/abstract](https://www.msard-journal.com/article/S2211-0348(20)30653-2/abstract). Accessed 9 Nov 2020.
47. Asseyer S, Cooper G, Paul F. Pain in NMOSD and MOGAD: a systematic literature review of pathophysiology, symptoms, and current treatment strategies. *Front Neurol*. 2020;11:778.
48. Ciccarelli O, Cohen JA, Reingold SC, Weinschenker BG. International Conference on Spinal Cord Involvement and Imaging in Multiple Sclerosis and Neuromyelitis Optica Spectrum Disorders. Spinal cord involvement in multiple sclerosis and neuromyelitis optica spectrum disorders. *Lancet Neurol*. 2019;18:185–97.
49. Ciron J, Cobo-Calvo A, Audoin B, Bourre B, Brassat D, Cohen M, et al. Frequency and characteristics of short versus longitudinally extensive myelitis in adults with MOG antibodies: a retrospective multicentric study. *Mult Scler J*. 2020;26:936–44.
50. Wingerchuk DM, Banwell B, Bennett JL, Cabre P, Carroll W, Chitnis T, et al. International consensus diagnostic criteria for neuromyelitis optica spectrum disorders. *Neurology*. 2015;85:177–89.
51. Wingerchuk DM, Lennon VA, Lucchinetti CF, Pittock SJ, Weinschenker BG. The spectrum of neuromyelitis optica. *Lancet Neurol*. 2007;6:805–15.
52. Mader S, Gredler V, Schanda K, Rostasy K, Dujmovic I, Pfaller K, et al. Complement activating antibodies to myelin oligodendrocyte glycoprotein in neuromyelitis optica and related disorders. *J Neuroinflamm*. 2011;28:184.
53. Jarius S, Ruprecht K, Kleiter I, Borisow N, Asgari N, Pitarokoili K, et al. MOG-IgG in NMO and related disorders: a multicenter study of 50 patients. Part 2: Epidemiology, clinical presentation, radiological and laboratory features, treatment responses, and long-term outcome. *J Neuroinflamm*. 2016;13:280.
54. Jarius S, Ruprecht K, Kleiter I, Borisow N, Asgari N, Pitarokoili K, et al. MOG-IgG in NMO and related disorders: a multicenter study of 50 patients. Part 1: Frequency, syndrome specificity, influence of disease activity, long-term course, association with AQP4-IgG, and origin. *J Neuroinflamm*. 2016;13:279.

55. Tajfirouz D, Padungkiatsagul T, Beres S, Moss HE, Pittcock S, Flanagan E, et al. Optic chiasm involvement in AQP-4 antibody-positive NMO and MOG antibody-associated disorder. *Mult Scler*. 2021;12:13524585211011450.
56. Kunchok A, Krecke KN, Flanagan EP, Jitprapaikulsan J, Lopez-Chiriboga AS, Chen JJ, et al. Does area postrema syndrome occur in myelin oligodendrocyte glycoprotein-IgG-associated disorders (MOGAD)? *Neurology* 2020;94:85–8.
57. Salama S, Khan M, Shanchei A, Levy M, Izbudak I. MRI differences between MOG antibody disease and AQP4 NMOSD. *Mult Scler*. 2020;26:1854–65.
58. Ogawa R, Nakashima I, Takahashi T, Kaneko K, Akaishi T, Takai Y, et al. MOG antibody-positive, benign, unilateral, cerebral cortical encephalitis with epilepsy. *Neurol Neuroimmunol Neuroinflamm*. 2017;4:e322.
59. Ramanathan S, O'Grady GL, Malone S, Spooner CG, Brown DA, Gill D, et al. Isolated seizures during the first episode of relapsing myelin oligodendrocyte glycoprotein antibody-associated demyelination in children. *Dev Med Child Neurol*. 2019;61:610–4.
60. Hamid SHM, Whittam D, Saviour M, Alorainy A, Mutch K, Linaker S, et al. Seizures and encephalitis in myelin oligodendrocyte glycoprotein IgG disease vs aquaporin 4 IgG disease. *JAMA Neurol*. 2018;75:65.
61. Shen C-H, Zheng Y, Cai M-T, Yang F, Fang W, Zhang Y-X, et al. Seizure occurrence in myelin oligodendrocyte glycoprotein antibody-associated disease: a systematic review and meta-analysis. *Mult Scler Relat Disord*. 2020;42:102057.
62. Graus F, Titulaer MJ, Balu R, Benseler S, Bien CG, Cellucci T, et al. A clinical approach to diagnosis of autoimmune encephalitis. *Lancet Neurol*. 2016;15:391–404.
63. Armangué T, Olivé-Cirera G, Martínez-Hernández E, Sepulveda M, Ruiz-García R, Muñoz-Batista M, et al. Associations of paediatric demyelinating and encephalitic syndromes with myelin oligodendrocyte glycoprotein antibodies: a multicentre observational study. *Lancet Neurol*. 2020;19:234–46.
64. Hacohen Y, Rossor T, Mankad K, Chong W', Lux A, Wassmer E, et al. 'Leukodystrophy-like' phenotype in children with myelin oligodendrocyte glycoprotein antibody-associated disease. *Dev Med Child Neurol*. 2018;60:417–23.
65. Rinaldi S, Davies A, Fehmi J, Beadnall HN, Wang J, Hardy TA, et al. Overlapping central and peripheral nervous system syndromes in MOG antibody-associated disorders. *Neurol Neuroimmunol Neuroinflamm*. 2021;8:e924.
66. Cobo-Calvo A, Aygnac X, Kerschen P, Horellou P, Cotton F, Labauge P, et al. Cranial nerve involvement in patients with MOG antibody-associated disease. *Neurol Neuroimmunol Neuroinflamm* [internet]. 2019. Available at: <https://nn.neurology.org/content/6/2/e543>. Accessed 7 Feb 2021.
67. Patterson K, Iglesias E, Nasrallah M, González-Álvarez V, Suñol M, Anton J, et al. Anti-MOG encephalitis mimicking small vessel CNS vasculitis. *Neurol Neuroimmunol Neuroinflamm*. 2019;6:e538.
68. Matesanz S, Kotch C, Perrone C, Waanders AJ, Hill B, Narula S. Expanding the MOG phenotype: brainstem encephalitis with punctate and curvilinear enhancement. *Neurol Neuroimmunol Neuroinflamm*. 2019;6:e619.
69. Vazquez Do Campo R, Stephens A, Marin Collazo IV, Rubin DI. MOG antibodies in combined central and peripheral demyelination syndromes. *Neurol Neuroimmunol Neuroinflamm*. 2018;5:e503.
70. Solomon JM, Paul F, Chien C, Oh J, Rotstein DL. A window into the future? MRI for evaluation of neuromyelitis optica spectrum disorder throughout the disease course. *Ther Adv Neurol Disord*. 2021;1:17562864211014388.
71. Motamedi S, Gawlik K, Ayadi N, Zimmermann HG, Assefer S, Bereuter C, et al. Normative data and minimally detectable change for inner retinal layer thicknesses using a semi-automated OCT image segmentation pipeline. *Front Neurol*. 2019;25:1117.
72. Oertel FC, Zimmermann H, Paul F, Brandt AU. Optical coherence tomography in neuromyelitis optica spectrum disorders: potential advantages for individualized monitoring of progression and therapy. *EPMA J*. 2018;9:21–33.
73. Zhao G, Chen Q, Huang Y, Li Z, Sun X, Lu P, et al. Clinical characteristics of myelin oligodendrocyte glycoprotein seropositive optic neuritis: a cohort study in Shanghai, China. *J Neurol*. 2018;265:33–40.
74. Pache F, Zimmermann H, Mikolajczak J, Schumacher S, Lacheta A, Oertel FC, et al. MOG-IgG in NMO and related disorders: a multicenter study of 50 patients. Part 4: Afferent visual system damage after optic neuritis in MOG-IgG-seropositive versus AQP4-IgG-seropositive patients. *J Neuroinflamm*. 2016;13:282.
75. Filippi M, Preziosa P, Banwell BL, Barkhof F, Ciccarelli O, De Stefano N, et al. Assessment of lesions on magnetic resonance imaging in multiple sclerosis: practical guidelines. *Brain* 2019;142:1858–75.
76. Gheraldes R, Ciccarelli O, Barkhof F, De Stefano N, Enzinger C, Filippi M, et al. The current role of MRI in differentiating multiple sclerosis from its imaging mimics. *Nat Rev Neurol*. 2018;14:199–213.
77. Baumann M, Grams A, Djurdjevic T, Wendel E-M, Lechner C, Behring B, et al. MRI of the first event in pediatric acquired demyelinating syndromes with antibodies to myelin oligodendrocyte glycoprotein. *J Neurol*. 2018;265:845–55.
78. Cobo-Calvo Á, Ruiz A, D'Indy H, Poulat A-L, Carneiro M, Philippe N, et al. MOG antibody-related disorders: common features and uncommon presentations. *J Neurol*. 2017;264:1945–55.
79. Jurynczyk M, Gheraldes R, Probert F, Woodhall MR, Waters P, Tackley G, et al. Distinct brain imaging characteristics of autoantibody-mediated CNS conditions and multiple sclerosis. *Brain J Neurol*. 2017;140:617–27.
80. Budhram A, Mirian A, Le C, Hosseini-Moghaddam SM, Sharma M, Nicolle MW. Unilateral cortical FLAIR-hyperintense Lesions in Anti-MOG-associated Encephalitis with Seizures (FLAMES): characterization of a distinct clinico-radiographic syndrome. *J Neurol*. 2019;266:2481–7.
81. Jarius S, Kleiter I, Ruprecht K, Asgari N, Pitarokoi K, Borisow N, et al. MOG-IgG in NMO and related disorders: a multicenter study of 50 patients. Part 3: Brainstem involvement – frequency, presentation and outcome. *J Neuroinflamm*. 2016;13:281.
82. Symmonds M, Waters PJ, Küker W, Leite MI, Schulz UG. Anti-MOG antibodies with longitudinally extensive transverse myelitis preceded by CLIPPERS. *Neurology* 2015;84:1177–9.
83. Stamenova S, Redha I, Schmierer K, Garcia ME. FLAIR-hyperintense Lesions in Anti-MOG-Associated Encephalitis With Seizures (FLAMES) unmasked by withdrawal of immunosuppression for Crohn's disease? *Mult Scler Relat Disord*. 2021;48:102729.
84. Wang L, Zhang Bao J, Zhou L, Zhang Y, Li H, Li Y, et al. Encephalitis is an important clinical component of myelin

- oligodendrocyte glycoprotein antibody associated demyelination: a single-center cohort study in Shanghai, China. *Eur J Neurol*. 2019;26:168–74.
85. Bartels F, Krohn S, Nikolaus M, Johannsen J, Wickström R, Schimmel M, et al. Clinical and magnetic resonance imaging outcome predictors in pediatric anti-N-methyl-D-aspartate receptor encephalitis. *Ann Neurol*. 2020;88:148–59.
  86. Matthews L, Marasco R, Jenkinson M, Kuker W, Luppe S, Leite MI, et al. Distinction of seropositive NMO spectrum disorder and MS brain lesion distribution. *Neurology* 2013;80:1330–7.
  87. Juryńczyk M, Tackley G, Kong Y, Geraldine R, Matthews L, Woodhall M, et al. Brain lesion distribution criteria distinguish MS from AQP4-antibody NMOSD and MOG-antibody disease. *J Neurol Neurosurg Psychiatry*. 2017;88:132–6.
  88. Sá MJ, Soares dos Reis R, Altintas A, Celius EG, Chien C, Comi G, et al. State of the art and future challenges in multiple sclerosis research and medical management: an insight into the 5th International Porto Congress of Multiple Sclerosis. *Neurol Ther*. 2020;9:281–300.
  89. Chen JJ, Flanagan EP, Jitrapaikulsan J, López-Chiriboga A(S, Fryer JP, Leavitt JA, et al. Myelin oligodendrocyte glycoprotein antibody-positive optic neuritis: clinical characteristics, radiologic clues, and outcome. *Am J Ophthalmol*. 2018;195:8–15.
  90. Song H, Zhou H, Yang M, Xu Q, Sun M, Wei S. Clinical characteristics and outcomes of myelin oligodendrocyte glycoprotein antibody-seropositive optic neuritis in varying age groups: a cohort study in China. *J Neurol Sci*. 2019;15:83–9.
  91. Akaishi T, Sato DK, Nakashima I, Takeshita T, Takahashi T, Doi H, et al. MRI and retinal abnormalities in isolated optic neuritis with myelin oligodendrocyte glycoprotein and aquaporin-4 antibodies: a comparative study: Table 1. *J Neurol Neurosurg Psychiatry*. 2016;87:446–8.
  92. Biotti D, Bonneville F, Tournaire E, Ayrignac X, Dallièrre CC, Mahieu L, et al. Optic neuritis in patients with anti-MOG antibodies spectrum disorder: MRI and clinical features from a large multicentric cohort in France. *J Neurol*. 2017;264:2173–5.
  93. Zhao Y, Tan S, Chan TCY, Xu Q, Zhao J, Teng DA, et al. Clinical features of demyelinating optic neuritis with seropositive myelin oligodendrocyte glycoprotein antibody in Chinese patients. *Br J Ophthalmol*. 2018;102:1372–7.
  94. Shor N, Aboab J, Maillart E, Lecler A, Bensa C, Le Guern G, et al. Clinical, imaging and follow-up study of optic neuritis associated with myelin oligodendrocyte glycoprotein antibody: a multicentre study of 62 adult patients. *Eur J Neurol*. 2020;27:384–91.
  95. Denève M, Biotti D, Patsoura S, Ferrier M, Meluchova Z, Mahieu L, et al. MRI features of demyelinating disease associated with anti-MOG antibodies in adults. *J Neuroradiol*. 2019;46:312–8.
  96. Kim S-M, Woodhall MR, Kim J-S, Kim S-J, Park KS, Vincent A, et al. Antibodies to MOG in adults with inflammatory demyelinating disease of the CNS. *Neurol Neuroimmunol Neuroinflamm* [internet]. 2015. Available at: <https://www.ncbi.nlm.nih.gov/pmc/articles/PMC4608758/>. Accessed 4 Feb 2021.
  97. Kitley J, Waters P, Woodhall M, Leite MI, Murchison A, George J, et al. Neuromyelitis optica spectrum disorders with aquaporin-4 and myelin-oligodendrocyte glycoprotein antibodies: a comparative study. *JAMA Neurol*. 2014;71:276–83.
  98. Sato DK, Callegaro D, Lana-Peixoto MA, Waters PJ, Jorge FMdH, Takahashi T, et al. Distinction between MOG antibody-positive and AQP4 antibody-positive NMO spectrum disorders. *Neurology* 2014;82:474–81.
  99. Mariano R, Messina S, Kumar K, Kuker W, Leite MI, Palace J. Comparison of clinical outcomes of transverse myelitis among adults with myelin oligodendrocyte glycoprotein antibody vs aquaporin-4 antibody disease. *JAMA Netw Open*. 2019;2:e1912732.
  100. Flanagan EP, Weinshenker BG, Krecke KN, Lennon VA, Lucchinetti CF, McKeon A, et al. Short myelitis lesions in aquaporin-4-IgG-positive neuromyelitis optica spectrum disorders. *JAMA Neurol*. 2015;72:81–7.
  101. Tantsis EM, Prelog K, Alper G, Benson L, Gorman M, Lim M, et al. Magnetic resonance imaging in enterovirus-71, myelin oligodendrocyte glycoprotein antibody, aquaporin-4 antibody, and multiple sclerosis-associated myelitis in children. *Dev Med Child Neurol*. 2019;61:1108–16.
  102. Cai W, Tan S, Zhang L, Shan Y, Wang Y, Lin Y, et al. Linear lesions may assist early diagnosis of neuromyelitis optica and longitudinally extensive transverse myelitis, two subtypes of NMOSD. *J Neurol Sci*. 2016;15:88–93.
  103. Sechi E, Krecke KN, Pittock SJ, Dubey D, Lopez-Chiriboga AS, Kunchok A, et al. Frequency and characteristics of MRI-negative myelitis associated with MOG autoantibodies. *Mult Scler*. 2021;27:303–8.
  104. Schmidt FA, Chien C, Kuchling J, Bellmann-Strobl J, Ruprecht K, Siebert N, et al. Differences in advanced magnetic resonance imaging in MOG-IgG and AQP4-IgG seropositive neuromyelitis optica spectrum disorders: a comparative study. *Front Neurol*. 2020;11:499910.
  105. Chien C, Scheel M, Schmitz-Hübsch T, Borisow N, Ruprecht K, Bellmann-Strobl J, et al. Spinal cord lesions and atrophy in NMOSD with AQP4-IgG and MOG-IgG associated autoimmunity. *Mult Scler J*. 2019;25:1926–36.
  106. Mariano R, Messina S, Roca-Fernandez A, Leite MI, Kong Y, Palace JA, et al. Quantitative spinal cord MRI in MOG-antibody disease, neuromyelitis optica and multiple sclerosis. *Brain* [internet]. 2020. Available at: <https://doi.org/10.1093/brain/awaa347>. Accessed 22 Jan 2021.
  107. Yang L, Li H, Xia W, Quan C, Zhou L, Geng D, et al. Quantitative brain lesion distribution may distinguish MOG-ab and AQP4-ab neuromyelitis optica spectrum disorders. *Eur Radiol*. 2020;30:1470–9.
  108. Chien C, Oertel FC, Siebert N, Zimmermann H, Asseger S, Kuchling J, et al. Imaging markers of disability in aquaporin-4 immunoglobulin G seropositive neuromyelitis optica: a graph theory study. *Brain Commun*. 2019;1:fcz026.
  109. Bartels F, Nobis K, Cooper G, Wendel E, Cleaveland R, Bajer-Kornek B, et al. Childhood multiple sclerosis is associated with reduced brain volumes at first clinical presentation and brain growth failure. *Mult Scler J*. 2019;25:927–36.
  110. Backner Y, Ben-Shalom I, Kuchling J, Siebert N, Scheel M, Ruprecht K, et al. Cortical topological network changes following optic neuritis. *Neurol Neuroimmunol Neuroinflamm*. 2020;7:e687.
  111. Aung WY, Mar S, Benzinger TL. Diffusion tensor MRI as a biomarker in axonal and myelin damage. *Imaging Med*. 2013;5:427–40.
  112. Mancini M, Karakuzu A, Cohen-Adad J, Cercignani M, Nichols TE, Stikov N. An interactive meta-analysis of MRI biomarkers

- of myelin. eLife [internet]. Available at: <https://www.ncbi.nlm.nih.gov/pmc/articles/PMC7647401/>. Accessed 23 Feb 2021.
113. Cooper G, Finke C, Chien C, Brandt AU, Asseger S, Ruprecht K, et al. Standardization of T1w/T2w ratio improves detection of tissue damage in multiple sclerosis. *Front Neurol*. 2019;10:334.
  114. Cooper G, Hirsch S, Scheel M, Brandt AU, Paul F, Finke C, et al. Quantitative multi-parameter mapping optimized for the clinical routine. *Front Neurosci*. 2020;14:611194.
  115. Cooper G, Chien C, Zimmermann HG, Bellmann-Strobl J, Ruprecht K, Kuchling J, et al. Longitudinal analysis of T1w/T2w ratio in patients with multiple sclerosis from first clinical presentation. *Mult Scler Houndmills Basingstoke Engl*. 2021 Apr 15;13524585211003480.
  116. Liu C, Wei H, Gong N-J, Cronin M, Dibb R, Decker K. Quantitative susceptibility mapping: contrast mechanisms and clinical applications. *Tomography* 2015;1:3–17.
  117. Pontillo G, Petracca M, Monti S, Quarantelli M, Criscuolo C, Lanzillo R, et al. Unraveling deep gray matter atrophy and iron and myelin changes in multiple sclerosis. *Am J Neuroradiol* [internet]. 2021. Available at: <http://www.ajnr.org/content/early/2021/04/22/ajnr.A7093>. Accessed 14 Jun 2021.
  118. Swanberg KM, Landheer K, Pitt D, Juchem C. Quantifying the metabolic signature of multiple sclerosis by *in vivo* proton magnetic resonance spectroscopy: current challenges and future outlook in the translation from proton signal to diagnostic biomarker. *Front Neurol* [internet]. 2019. Available at: <https://www.frontiersin.org/articles/10.3389/fneur.2019.01173/full>. Accessed 14 Jun 2021.
  119. Bauckneht M, Capitanio S, Raffa S, Roccatagliata L, Pardini M, Lapucci C, et al. Molecular imaging of multiple sclerosis: from the clinical demand to novel radiotracers. *EJNMMI Radiopharm Chem* [internet]. 2019. Available at: <https://www.ncbi.nlm.nih.gov/pmc/articles/PMC6453990/>. Accessed 14 Jun 2021.
  120. Stevens MY, Cropper HC, Lucot KL, Chaney AM, Lechtenberg KJ, Jackson IM, et al. Development of a CD19 PET tracer for detecting B cells in a mouse model of multiple sclerosis. *J Neuroinflamm*. 2020;17:275.
  121. Airas L, Rissanen E, Rinne J. Imaging of microglial activation in MS using PET: Research use and potential future clinical application. *Mult Scler J*. 2017;23:496–504.
  122. Bodini B, Veronese M, García-Lorenzo D, Battaglini M, Poirion E, Chardain A, et al. Dynamic imaging of individual remyelination profiles in multiple sclerosis. *Ann Neurol*. 2016;79:726–38.
  123. Rocca MA, Savoldi F, Valsasina P, Radaelli M, Preziosa P, Comi G, et al. Cross-modal plasticity among sensory networks in neuromyelitis optica spectrum disorders. *Mult Scler*. 2018;1:1352458518778008.
  124. Chavarro VS, Bellmann-Strobl J, Zimmermann HG, Scheel M, Chien C, Oertel FC, et al. Visual system damage and network maladaptation are associated with cognitive performance in neuromyelitis optica spectrum disorders. *Mult Scler Relat Disord*. 2020;45:102406.
  125. Finke C, Zimmermann H, Pache F, Oertel FC, Chavarro VS, Kramarenko Y, et al. Association of visual impairment in neuromyelitis optica spectrum disorder with visual network reorganization. *JAMA Neurol*. 2018;75:296–303.
  126. Sun M, Zhou H, Xu Q, Yang M, Xu X, Zhou M, et al. Differential patterns of interhemispheric functional connectivity between AQP4-optic neuritis and MOG-optic neuritis: a resting-state functional MRI study. *Acta Radiol*. 2021;6:776–83.
  127. Havla J, Kümpfel T, Schinner R, Spadaro M, Schuh E, Meinl E, et al. Myelin-oligodendrocyte-glycoprotein (MOG) autoantibodies as potential markers of severe optic neuritis and subclinical retinal axonal degeneration. *J Neurol*. 2017;264:139–51.
  128. Schmidt F, Zimmermann H, Mikolajczak J, Oertel FC, Pache F, Weinhold M, et al. Severe structural and functional visual system damage leads to profound loss of vision-related quality of life in patients with neuromyelitis optica spectrum disorders. *Mult Scler Relat Disord*. 2017;11:45–50.
  129. Walter SD, Ishikawa H, Galetta KM, Sakai RE, Feller DJ, Henderson SB, et al. Ganglion cell loss in relation to visual disability in multiple sclerosis. *Ophthalmology*. 2012;119:1250–7.
  130. Motamedi S, Oertel FC, Yadav SK, Kadas EM, Weise M, Havla J, et al. Altered fovea in AQP4-IgG-seropositive neuromyelitis optica spectrum disorders. *Neurol Neuroimmunol Neuroinflamm*. 2020;7:e805.
  131. Oertel FC, Kuchling J, Zimmermann H, Chien C, Schmidt F, Knier B, et al. Microstructural visual system changes in AQP4-antibody-seropositive NMOSD. *Neurol Neuroimmunol Neuroinflamm*. 2017;4:e334.
  132. Vicini R, Brügger D, Abegg M, Salmen A, Grabe HM. Differences in morphology and visual function of myelin oligodendrocyte glycoprotein antibody and multiple sclerosis associated optic neuritis. *J Neurol* [internet]. 2020. Available at: <http://link.springer.com/10.1007/s00415-020-10097-x>. Accessed 19 Jan 2021.
  133. Sotirchos ES, Filippatou A, Fitzgerald KC, Salama S, Pardo S, Wang J, et al. Aquaporin-4 IgG seropositivity is associated with worse visual outcomes after optic neuritis than MOG-IgG seropositivity and multiple sclerosis, independent of macular ganglion cell layer thinning. *Mult Scler J*. 2020;26:1360–71.
  134. Stiebel-Kalish H, Lotan I, Brody J, Chodick G, Bialer O, Marignier R, et al. Retinal nerve fiber layer may be better preserved in MOG-IgG versus AQP4-IgG optic neuritis: a cohort study. *PLOS ONE*. 2017;12:e0170847.
  135. Eyre M, Hameed A, Wright S, Brownlee W, Ciccarelli O, Bowman R, et al. Retinal nerve fibre layer thinning is associated with worse visual outcome after optic neuritis in children with a relapsing demyelinating syndrome. *Dev Med Child Neurol*. 2018;60:1244–50.
  136. Oertel FC, Outteryck O, Knier B, Zimmermann H, Borisow N, Bellmann-Strobl J, et al. Optical coherence tomography in myelin-oligodendrocyte-glycoprotein antibody-seropositive patients: a longitudinal study. *J Neuroinflamm*. 2019;16:154.
  137. Ramanathan S. Antibodies to myelin oligodendrocyte glycoprotein in bilateral and recurrent optic neuritis. *Neurol Neuroimmunol Neuroinflamm*. 2014;1:e40.
  138. Giacomini T. Pediatric optic neuritis and anti MOG antibodies – a cohort of Italian patients. *Mult Scler Relat Disord*. 2019;39:101917.
  139. Narayan RN, McCreary M, Conger D, Wang C, Greenberg BM. Unique characteristics of optical coherence tomography (OCT) results and visual acuity testing in myelin oligodendrocyte glycoprotein (MOG) antibody positive pediatric patients. *Mult Scler Relat Disord*. 2019;28:86–90.
  140. Martinez-Lapiscina EH, Sepulveda M, Torres-Torres R, Alba-Arbalaz S, Llufríu S, Blanco Y, et al. Usefulness of optical coherence tomography to distinguish optic neuritis associated with AQP4 or MOG in neuromyelitis optica spectrum disorders. *Ther Adv Neurol Disord*. 2016;9:430–40.

141. Mekhasingharak N, Laowanapiban P, Siritho S, Satukijchai C, Prayoonwiwat N, Jitprapaikulsan J, et al. Optical coherence tomography in central nervous system demyelinating diseases related optic neuritis. *Int J Ophthalmol.* 2018;11:1649–56.
142. Garg A, Margolin E, Micieli JA. Myelin oligodendrocyte glycoprotein antibody-associated optic neuritis in Canada. *Can J Neurol Sci J.* 2021;48:324–26.
143. Filippatou AG, Mukharesh L, Saidha S, Calabresi PA, Sotirchos ES. AQP4-IgG and MOG-IgG related optic neuritis—prevalence, optical coherence tomography findings, and visual outcomes: a systematic review and meta-analysis. *Front Neurol.* 2020;11:540156.
144. Specovius S, Zimmermann HG, Oertel FC, Chien C, Bereuter C, Cook LJ, et al. Cohort profile: a collaborative multicentre study of retinal optical coherence tomography in 539 patients with neuromyelitis optica spectrum disorders (CROCTINO). *BMJ Open.* 2020;10:e035397.

**How to cite this article:** Bartels F, Lu A, Oertel FC, Finke C, Paul F, Chien C. Clinical and neuroimaging findings in MOGAD–MRI and OCT. *Clin Exp Immunol.* 2021;206:266–281. <https://doi.org/10.1111/cei.13641>