

A mixed odontogenic sarcoma: A challenging histopathologic case and brief review of the literature

Saede Atarbashi-Moghadam, Ali Lotfi, Sepideh Mokhtari¹

Department of Oral and Maxillofacial Pathology, Dental School of Shahid Beheshti University of Medical Sciences,
¹Education Development Office, School of Dentistry, Tehran University of Medical Sciences, Tehran, Iran

Abstract

Ameloblastic fibro-odontosarcoma (AFOS) is an extremely rare malignant mixed odontogenic tumor. The ectomesenchymal part of the neoplasm shows malignancy, whereas the epithelial component is rather benign. In addition, small areas with deposition of enamel matrix and dentine material are seen. The rarity of this neoplasm and microscopic similarities with other malignant and benign tumors can lead to diagnostic problems. Here, we describe the histopathologic features of a new case of AFOS of the mandible in a 34-year-old female patient. It is essential for oral pathologists to be familiar with the microscopic features of this rare neoplasm to have a proper diagnosis. This is also the first reported case of AFOS that closely resembles osteosarcoma in some areas.

Keywords: Ameloblastic, fibro-odontoma, odontogenic, osteosarcoma

Address for correspondence: Dr. Sepideh Mokhtari, School of Dentistry, Tehran University of Medical Sciences, Tehran, Iran.
E-mail: sepidemokhtary@yahoo.com

Received: 09.04.2017, **Accepted:** 21.12.2017

INTRODUCTION

Malignant neoplasms with odontogenic origin are extremely rare and accounts for <5% of all odontogenic tumors of diverse series of cases reported in the literature.^[1,2] According to the classification of the World Health Organization (WHO), odontogenic sarcoma is composed of a benign epithelial part and malignant connective tissue element and is divided into two groups as follows: ameloblastic fibrosarcoma (AFS) and ameloblastic fibro-dentinosarcoma and/or fibro-odontosarcoma (AFOS). Odontogenic carcinosarcoma has distinctively malignant activity in both components, leading to more aggressive clinical behavior and regional or distant metastasis.^[3] The most common presenting features of AFOS/AFS are pain and swelling,^[4-6] but paresthesia,^[1] ulceration,^[4] and

rapid growth^[5] have been also reported. There is a male predilection,^[7] the mean age of involvement is 27 years and the mandible in the posterior area is the more affected site.^[1,4] Radiographically, the lesion shows a unilocular or multilocular radiolucency with ill-defined borders.^[2] Due to the rarity of this odontogenic tumor, it is essential for oral pathologists to be familiar with the histopathologic characteristics of this tumor to avoid misdiagnosis or confusion with other benign and malignant odontogenic and nonodontogenic tumors.^[8]

The purpose of this article is to describe the microscopic features of a case of AFOS mimicking osteosarcoma. It should be mentioned that clinical and surgical aspects of this case have been discussed before in the literature.^[9]

Access this article online

Quick Response Code:



Website:

www.jomfp.in

DOI:

10.4103/jomfp.JOMFP_74_17

This is an open access article distributed under the terms of the Creative Commons Attribution-NonCommercial-ShareAlike 3.0 License, which allows others to remix, tweak, and build upon the work non-commercially, as long as the author is credited and the new creations are licensed under the identical terms.

For reprints contact: reprints@medknow.com

How to cite this article: Atarbashi-Moghadam S, Lotfi A, Mokhtari S. A mixed odontogenic sarcoma: A challenging histopathologic case and brief review of the literature. J Oral Maxillofac Pathol 2018;22:S29-34.

CASE REPORT

A 32-year-old female patient was referred to a dentist for evaluation of a painful expansion in her mandible [Figure 1]. Intraoral examination revealed a diffuse swelling in the posterior area of the left mandible. The overlying mucosa was erythematous, ulcerated and necrotic [Figure 2]. The panoramic radiograph showed a radiolucent lesion with ill-defined borders extending from the second premolar to second molar [Figure 3]. The incisional biopsy was performed, and the general pathologist's diagnosis was ameloblastoma. Other consulting reports from other General Pathology Departments were ameloblastic fibroma (AF), osteosarcoma and mesenchymal chondrosarcoma. Due to the first microscopic diagnosis (ameloblastoma), *en bloc* resection from the second premolar to the third molar was done and reconstruction was performed after 6 months using autogenous iliac bone graft stabilized using titanium mesh and plate. Two years later, she came back with a huge recurrent lesion and obvious facial asymmetry. Therefore, she was referred to an oral and maxillofacial pathology center for more investigation, and her primary biopsy specimens and previous histopathological slides were reviewed. Two slides (number 1, 2) of the primary lesion were present. Careful evaluation of slide number 1 showed scattered benign ameloblastic islands and dental papilla-like stroma with tumoral giant cells [Figures 4 and 5]. Hyalinization was seen around these benign islands [Figure 6]. Dentinoid material was also found near some odontogenic epithelial nests [Figure 7]. Slide number 2 revealed a highly cellular mesenchymal tissue with hyperchromatic and bizarre pleomorphic cells without any epithelial islands. The malignant counterpart was similar to a poorly differentiated round-cell sarcoma. Some eosinophilic materials, most likely dysplastic dentin, were also found in this malignant counterpart [Figures 8 and 9]. The eosinophilic material was osteoid-like, and in these areas, the histopathologic feature was very similar to fibroblastic osteosarcoma. These varying microscopic features justified the different and unusual pathologic reports of the lesion as ameloblastoma, AF, osteosarcoma and mesenchymal chondrosarcoma. However, due to the histopathologic features of the lesion, the diagnosis of AFOS was confirmed. No cervical lymphadenopathy was present and the laboratory data were unremarkable. Computed tomography scan of the abdomen, pelvic sonography and chest X-ray were normal, and the patient was referred for surgical treatment. As well, adjuvant chemotherapy consisting of fluorouracil and cyclophosphamide was carried out. Unfortunately,

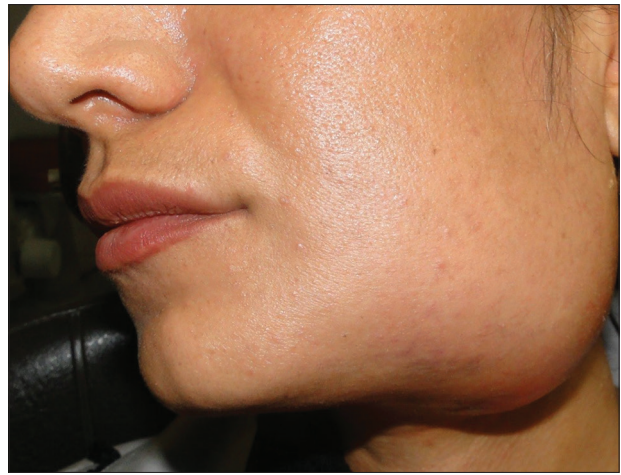

Figure 1: A painful expansion in the left mandibular region and marked facial asymmetry

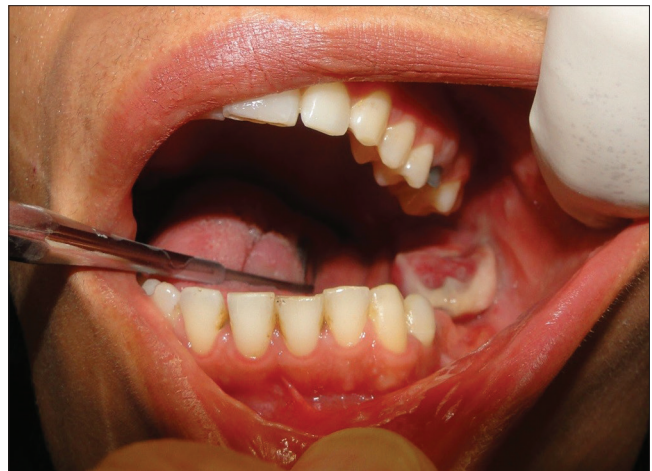

Figure 2: Intraoral examination showed a diffuse swelling in the posterior area of left mandible with erythematous and ulcerated overlying mucosa

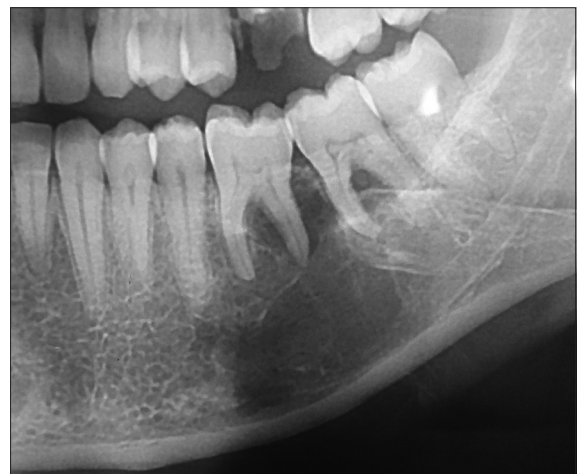


Figure 3: Panoramic radiograph of the primary lesion showed a radiolucent lesion with ill-defined borders extending from the left mandibular second premolar to the second molar

12 months after surgery and in spite of local tumor control, pulmonary, mediastinal and axillary lymph

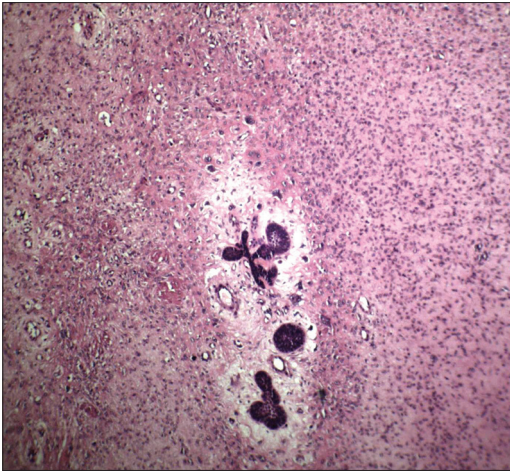


Figure 4: Histopathologic feature in a low magnification illustrates the nature of the tissue as a mixed odontogenic lesion

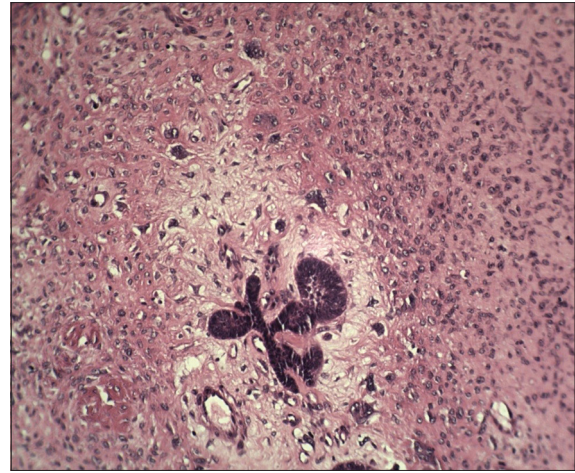


Figure 5: Histopathologic section showed scattered odontogenic islands and pleomorphic giant stromal cells in a malignant dental papilla-like connective tissue (x100)

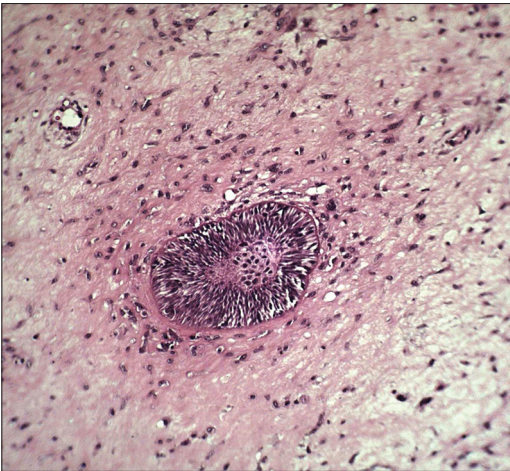


Figure 6: Hyalinization was seen around some odontogenic islands (x100)

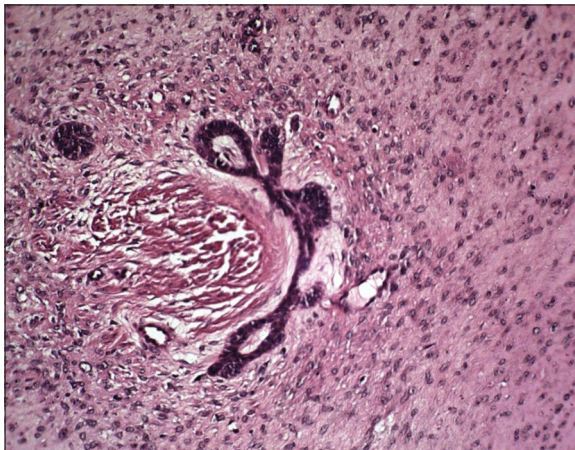


Figure 7: Some amount of dentinoid material was found near the odontogenic epithelial nests (x100)

node metastases arose, indicating a progressive systemic disease. Therefore, she was referred to the oncologist for palliative chemotherapy.

DISCUSSION

AFOS is an extremely rare subtype of odontogenic sarcoma. Seventeen cases have been reported in the literature till date.^[10] AFOS is composed of a benign epithelial part and a malignant connective tissue element. In addition, it includes small areas with deposition of enamel matrix and dysplastic dentin.^[2] The terms ameloblastic dentinosarcoma and ameloblastic odontosarcoma have been used for these types of neoplasms depending on the presence of dentin or enamel, and some authors consider these lesions as histological variants of the same neoplasm. As well, the presence or absence of dentin and enamel in an odontogenic sarcoma is of no prognostic value.^[11,12]

In the recent WHO “classification” of odontogenic tumors, ameloblastic odontosarcoma and dentinosarcoma are listed separately from AFS.^[8] Investigations show a high number of loss of heterozygosity (LOH) in the AFO compared to AF. Therefore, although AFO and AF show histological similarities, they may have differences in their tumorigenesis and may present a distinct genetic profile.^[13]

The epithelial element of AFS/AFOS ultimately becomes less prominent and may disappear altogether after local recurrences.^[14] This gradual loss of odontogenic islands is related with more malignant behavior of AFS/AFOS clinically. The most common phenotypic appearance of the malignant part is that of low-to-intermediate—grade fibrosarcoma. The neoplasm eventually demonstrates poorly differentiated fibrosarcoma or even a high-grade sarcoma of undetermined derivation. The stromal cells may show herringbone, cartwheel or storiform pattern.^[6]

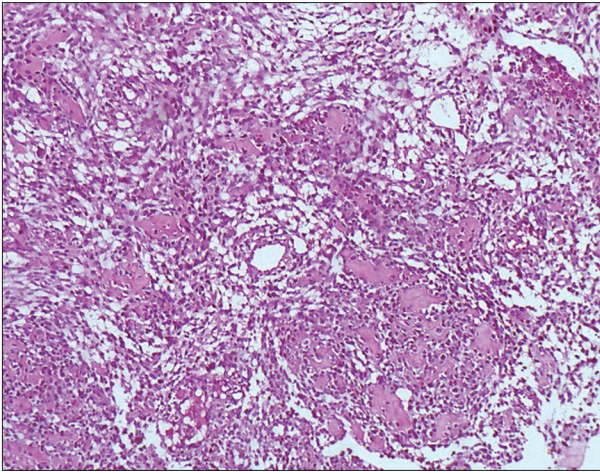


Figure 8: Some eosinophilic material was found in the malignant counterpart. The histopathologic feature in these areas was very similar to fibroblastic osteosarcoma (x100)

In the present case, the microscopic examination of the lesion showed a pattern-less proliferation of round-to-ovoid malignant mesenchymal cells and some amount of dentinoid material. Very few islands of odontogenic epithelium, compared to the extensive malignant mesenchymal component, were also present, a feature commonly seen in AFS/AFOS.^[7] However, in most cases of AFOS, dentinoid material is only found adjacent to the epithelial islands,^[2,15] and in this case, dentinoid material was found both near the odontogenic islands and in the sarcomatous areas, far from the bland odontogenic epithelium. Since this eosinophilic material was very similar to osteoid, the lesion was misdiagnosed with fibroblastic osteosarcoma by some pathologists. Osteosarcoma arises from primitive transformed cells of the mesenchyme that exhibit osteoblastic differentiation and produce malignant osteoid. Fibroblastic type of osteosarcoma is a high-grade spindle-cell malignancy and usually contains a minimal amount of osseous matrix.^[16] Differentiation should be based on the fact that odontogenic epithelium is only seen in odontogenic lesions, and it cannot be present in pure mesenchymal tumor-like osteosarcoma. Moreover, the presence of hyalinization and inductive material around and near the odontogenic nests, although in very limited areas of the lesion [Figures 6 and 7], designates the odontogenic epithelium as the origin of this matrix material. Therefore, the eosinophilic material is the product of inductive effect of odontogenic epithelial cells on adjacent odontogenic mesenchyme. In fact, this matrix material is dentinoid not osteoid, and the lesion should be diagnosed as AFOS not osteosarcoma. Osteosarcoma also has been previously mentioned as a differential diagnosis for AF in the literature.^[17] However, this is the first reported case of AFOS with very similar histopathologic features to osteosarcoma.

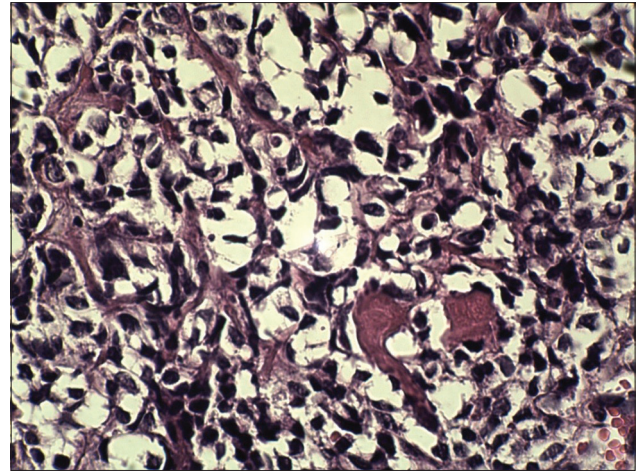


Figure 9: The eosinophilic material in sarcomatous area was osteoid like (x400)

The diagnosis of a collision tumor, consisting of osteosarcoma and AFS, is also proposed. However, there is no report of this type of collision tumor in the literature.

In the present case, tumoral giant cells were found near the odontogenic epithelium. Investigations show that the loss of benign odontogenic epithelium is correlated with the presence of bizarre tumoral giant cells.^[1,18]

AFOS/AFS can arise in a preexisting AF or can present *de novo* (two-third of the cases).^[4,19] The present case was considered *de novo* since the patient did not have any history of previous AF. Moreover, tumoral giant cells and malignant mesenchymal cells were present in the slides of the primary lesion and this confirms that the primary lesion was malignant and a *de novo* type AFOS.

Due to the rarity of this malignant odontogenic tumor, investigations of the molecular events associated with its malignant evolution are scarce.^[20] Therefore, the diagnosis of AFOS/AFS is made microscopically,^[21] and no immunohistochemical marker is used for the diagnosis. However, immunostaining may help make a definite diagnosis in some problematic cases. Cytokeratin can identify epithelial nests and exclude pure sarcomas.^[11] Mesenchymal cells of AFS show expression of CD34; however, the function of this protein in AFS is not explained.^[11] Moreover, the cells in the sarcomatous areas are positive for vimentin, p53 and Ki-67, but negative for smooth muscle actin, S-100, CD68, desmin^[22] and c-KIT (CD117).^[8] As well, nestin (one of the intermediate filaments of the cytoskeleton) is a useful protein for detection of the odontogenic mesenchyme in odontogenic neoplasms.^[21] Bcl-2 alteration may also participate in the pathogenesis of this neoplasm.^[19]

A study by Muller *et al.*^[18] found that although there is an association between DNA aneuploidy and increased histologic grade in many microscopic types of sarcomas, this relationship is not found in AFS. As well, Galvão *et al.*^[13] described that AF shows a lower fractional allelic loss than AFS. In addition, a different pattern of LOH of tumor-suppressor genes is present in AFS. They suggest that these findings may be useful in the differential diagnosis between AF and AFS. Although no definite immunohistochemical profile has been described for AFOS, the odontogenic epithelium was evident in the histopathologic features of this case, and no immunohistochemical staining was needed to rule out the pure mesenchymal tumor-like osteosarcoma.

AFS is a highly locally aggressive tumor with low potential for distant metastasis.^[6,13] The recurrence rate and distant metastasis are described as 23.9%–37% and 4.5%, respectively.^[23] AFS has been reported to become increasingly aggressive clinically with each recurrence.^[10] AFOS is considered to be less aggressive than AFS, with only one report of regional metastasis.^[24] However, recurrences and fatalities due to recurrence/progression involving the skull base have been reported.^[10] Nevertheless, in this case, distant metastasis was seen after 3 years from initial diagnosis.

Since AFS is an exceedingly rare neoplasm, no exact treatment has been established.^[4,25] Some authors suggest the wide surgical excision and long-term follow-up as the treatment of choice.^[1,2] Routine neck dissection is not performed due to the low incidence of cervical lymph node involvement.^[18] Death usually results from uncontrolled local tumor infiltration after several recurrences.^[12] Some investigations recommend the prognostic benefit of chemo and/or radiotherapy, especially for those who have unresectable disease or need salvage operations following the initial surgery.^[26,27] Gatz *et al.* suggested that chemotherapy with ifosfamide and doxorubicin may have a role in the adjuvant or neoadjuvant setting.^[10] Nevertheless, there was no response to chemo/radiotherapy in this patient similar to some other reported cases.^[4]

CONCLUSION

AFOS may resemble osteosarcoma or other malignant/benign odontogenic or nonodontogenic tumors. Precise evaluation of the histopathologic features of this tumor is essential to avoid misdiagnosis, and oral pathologists have an important role in the proper diagnosis of this rare malignant odontogenic lesion. Despite local tumor control, the progressive systemic disease may occur. Therefore, long-term follow-up is recommended in all cases.

Declaration of patient consent

The authors certify that they have obtained all appropriate patient consent forms. In the form the patient(s) has/have given his/her/their consent for his/her/their images and other clinical information to be reported in the journal. The patients understand that their names and initials will not be published and due efforts will be made to conceal their identity, but anonymity cannot be guaranteed.

Financial support and sponsorship

Nil.

Conflicts of interest

There are no conflicts of interest.

REFERENCES

- Bregni RC, Taylor AM, García AM. Ameloblastic fibrosarcoma of the mandible: Report of two cases and review of the literature. *J Oral Pathol Med* 2001;30:316-20.
- Wang S, Shi H, Wang P, Yu Q. Ameloblastic fibro-odontosarcoma of the mandible: Imaging findings. *Dentomaxillofac Radiol* 2011;40:324-7.
- Kunkel M, Ghalibafian M, Radner H, Reichert TE, Fischer B, Wagner W, *et al.* Ameloblastic fibrosarcoma or odontogenic carcinosarcoma: A matter of classification? *Oral Oncol* 2004;40:444-9.
- Kobayashi K, Murakami R, Fujii T, Hirano A. Malignant transformation of ameloblastic fibroma to ameloblastic fibrosarcoma: Case report and review of the literature. *J Craniomaxillofac Surg* 2005;33:352-5.
- Williams MD, Hanna EY, El-Naggar AK. Anaplastic ameloblastic fibrosarcoma arising from recurrent ameloblastic fibroma: Restricted molecular abnormalities of certain genes to the malignant transformation. *Oral Surg Oral Med Oral Pathol Oral Radiol Endod* 2007;104:72-5.
- Kousar A, Hosein MM, Ahmed Z, Minhas K. Rapid sarcomatous transformation of an ameloblastic fibroma of the mandible: Case report and literature review. *Oral Surg Oral Med Oral Pathol Oral Radiol Endod* 2009;108:e80-5.
- Loya-Solis A, González-Colunga KJ, Pérez-Rodríguez CM, Ramírez-Ochoa NS, Ceceñas-Falcón L, Barboza-Quintana O, *et al.* Ameloblastic fibrosarcoma of the mandible: A case report and brief review of the literature. *Case Rep Pathol* 2015;2015:245026.
- Gilani SM, Raza A, Al-Khafaji BM. Ameloblastic fibrosarcoma: A rare malignant odontogenic tumor. *Eur Ann Otorhinolaryngol Head Neck Dis* 2014;131:53-6.
- Pourandesh F, Mohamadi M, Moshref M, Soltaninia O. Ameloblastic fibrosarcoma of the mandible with distant metastases. *J Oral Maxillofac Surg* 2015;73:2067.e1-7.
- Gatz SA, Thway K, Mandeville H, Kerawala C, MacVicar D, Chisholm J, *et al.* Chemotherapy responsiveness in a patient with multiply relapsed ameloblastic fibro-odontosarcoma of the maxilla. *Pediatr Blood Cancer* 2015;62:2029-32.
- Lee OJ, Kim HJ, Lee BK, Cho KJ. CD34 expressing ameloblastic fibrosarcoma arising in the maxilla: A new finding. *J Oral Pathol Med* 2005;34:318-20.
- Mainenti P, Oliveira GS, Valério JB, Daroda LS, Daroda RF, Brandão G, *et al.* Ameloblastic fibro-odontosarcoma: A case report. *Int J Oral Maxillofac Surg* 2009;38:289-92.
- Galvão CF, Gomes CC, Diniz MG, Vargas PA, de Paula AM, Mosqueda-Taylor A, *et al.* Loss of heterozygosity (LOH) in tumour suppressor genes in benign and malignant mixed odontogenic tumours. *J Oral Pathol Med* 2012;41:389-93.
- Kulkarni RS, Sarkar A, Goyal S. Recurrent ameloblastic fibroma: Report of a rare case. *Case Rep Dent* 2013;2013:565721.

15. Zabolinejad N, Hiradfar M, Anvari K, Razavi AS. Ameloblastic fibrosarcoma of the maxillary sinus in an infant: A case report with long-term follow-up. *J Pediatr Surg* 2008;43:e5-8.
16. Chaudhary M, Chaudhary SD. Osteosarcoma of jaws. *J Oral Maxillofac Pathol* 2012;16:233-8.
17. Kim IK, Pae SP, Cho HY, Cho HW, Seo JH, Lee DH, *et al.* Odontogenic carcinosarcoma of the mandible: A case report and review. *J Korean Assoc Oral Maxillofac Surg* 2015;41:139-44.
18. Muller S, Parker DC, Kapadia SB, Budnick SD, Barnes EL. Ameloblastic fibrosarcoma of the jaws. A clinicopathologic and DNA analysis of five cases and review of the literature with discussion of its relationship to ameloblastic fibroma. *Oral Surg Oral Med Oral Pathol Oral Radiol Endod* 1995;79:469-77.
19. Pontes HA, Pontes FS, Silva BS, Cury SE, Fonseca FP, Salim RA, *et al.* Immunoeexpression of ki67, proliferative cell nuclear antigen, and bcl-2 proteins in a case of ameloblastic fibrosarcoma. *Ann Diagn Pathol* 2010;14:447-52.
20. Batista de Paula AM, da Costa Neto JQ, da Silva Gusmão E, Guimarães Santos FB, Gomez RS. Immunolocalization of the p53 protein in a case of ameloblastic fibrosarcoma. *J Oral Maxillofac Surg* 2003;61:256-8.
21. Fujita S, Hideshima K, Ikeda T. Nestin expression in odontoblasts and odontogenic ectomesenchymal tissue of odontogenic tumours. *J Clin Pathol* 2006;59:240-5.
22. Hu YY, Deng MH, Yuan LL, Niu YM. Ameloblastic fibrosarcoma of the mandible: A case report and mini review. *Exp Ther Med* 2014;8:1463-6.
23. Al Shetawi AH, Alpert EH, Buchbinder D, Urken ML. Ameloblastic fibrosarcoma of the mandible: A Case report and a review of the literature. *J Oral Maxillofac Surg* 2015;73:1661.e1-7.
24. Carlos R, Alini M, Takeda Y. Odontogenic sarcomas. In: Barnes L, Eveson J, Reichart P, Sidransky D, editors. *Pathology and Genetics of Head and Neck Tumours*. Lyon: IARC Press; 2005. p. 294-5.
25. Lai J, Blanas N, Higgins K, Klieb H. Ameloblastic fibrosarcoma: Report of a case, study of immunophenotype, and comprehensive review of the literature. *J Oral Maxillofac Surg* 2012;70:2007-12.
26. Demoor-Goldschmidt C, Minard-Colin V, Cassagneau E, Supiot S, Oberlin O, D'hautuille C, *et al.* Ameloblastic fibrosarcoma of the mandible: Report of 2 chemosensitive pediatric cases. *J Pediatr Hematol Oncol* 2012;34:e72-6.
27. Pillay RR, Bilski A, Batstone M. Ameloblastic fibrosarcoma arising in the maxilla. *Ochsner J* 2016;16:143-5.