

Rechtsmedizin 2021 · 31:145–147

<https://doi.org/10.1007/s00194-021-00462-z>

Accepted: 4 January 2021

Published online: 15 February 2021

© Springer Medizin Verlag GmbH, ein Teil von Springer Nature 2021



I. Kniep · A. Heinemann · C. Edler · J. P. Sperhake · K. Püschel · B. Ondruschka · A. S. Schröder

Institute of Legal Medicine, University Medical Center Hamburg-Eppendorf, Hamburg, Germany

## COVID-19 lungs in post-mortem computed tomography

### Case presentations

Typical findings in post-mortem computed tomography (PMCT) for coronavirus disease 2019 (COVID-19) pneumonia are presented referring to three autopsy cases from the Institute of Legal Medicine in Hamburg, Germany.

**Case 1:** Death of an 80-year-old man in hospital with autopsy-proven sepsis as a consequence of a superinfected COVID-19 pneumonia. No invasive ventilation was performed. The PMCT was performed 48 h after death and revealed dorsal ground glass opacities (GGO) and multiple areas of consolidation in the pulmonary lobes (■ Fig. 1a, b).

**Case 2:** The 90-year-old woman died in a nursing home with a positive severe acute respiratory syndrome coronavirus type 2 (SARS-CoV-2) test ante-mortem. The PMCT performed 18 h after death revealed dorsal GGO in the peripheral segments of the pulmonary lobes as well as centrilobular nodules and a single area of consolidation (■ Fig. 2a, b). Autopsy showed COVID-19 pneumonia as direct cause of death.

**Case 3:** This is the case of an 89-year-old man who died of COVID-19 pneumonia after intensive care treatment with invasive ventilation in hospital. The PMCT, which was performed 8 h after death, showed disseminated GGO and peripherally accentuated consolidations (■ Fig. 3a, b). Autopsy confirmed COVID-19 pneumonia as cause of death.

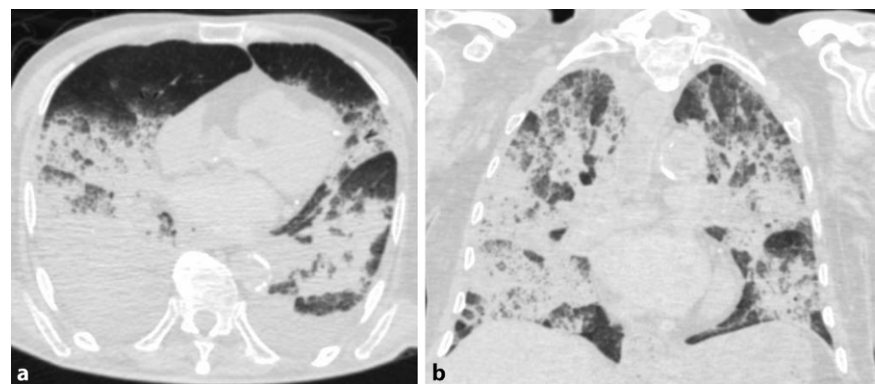
### Difficulties of lung interpretation in PMCT

In comparison to clinical CT, the assessment of lung tissue in PMCT, especially in the dorsal segments, where fluid accumulation typically occurs, may be complicated by post-mortem artifacts in the lungs caused by hypostasis. Furthermore, post-mortem increases in pleural effusions may mask dorsal findings [9]. Dorsal hypostasis, which is typically manifested as milk glass opacity [2], in-

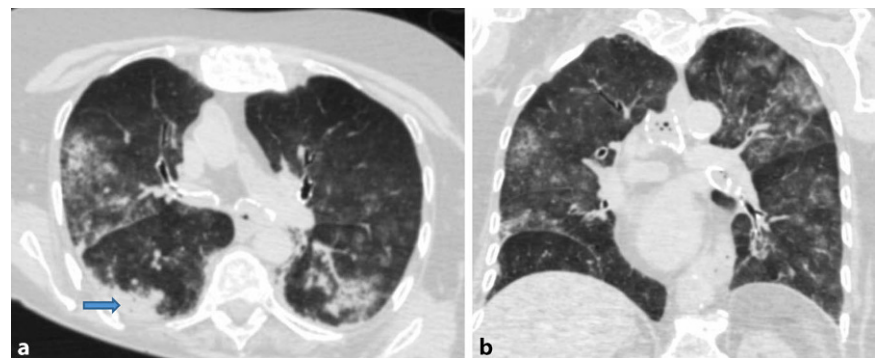
creases with time after death [6] highlighting the necessity of fast post-mortem imaging after death, whenever possible.

### Discussion

So far, there is little literature on COVID-19 deaths that have been systematically studied with PMCT. Ducloyer et al. described diffuse bilateral crazy-paving patterns, i.e. GGO in areas of reticular densification of the lungs in one fatal case of COVID-19 in PMCT [4]. In another case



**Fig. 1** ▲ Post-mortem computed tomography case 1. **a** Axial CT image (lung section). **b** Coronal CT image (lung section)



**Fig. 2** ▲ Post-mortem computed tomography case 2. **a** Axial CT image (lung section; blue arrow directing to the area of consolidation). **b** Coronal CT image (lung section)

with COVID-19 positive PMCT signs, Leth et al. described GGO and localized consolidation [10], comparable to the illustrative case series reported here. The authors own recent study of SARS-CoV-2-associated deaths from Hamburg, Germany and with post-mortem imaging also showed these typical patterns: GGO, consolidations and crazy-paving patterns [9, 14]. Even in the very first COVID-19 deceased in Hamburg, GGO and reticular changes in the PMCT were already diagnosed as being disease-associated lung changes [7].

However, pulmonary artery embolisms diagnosed at autopsy [5] in a relevant percentage of COVID-19 deaths could not be reliably delineated in the native PMCT [9]. To the best of our knowledge no systematic studies have yet investigated the possible benefit of PMCT angiography to overcome this issue.

More literature exists on clinical cases with CT imaging in COVID-19, where bilateral GGO and consolidations are described as frequent manifestations in the lungs [3], with GGO dominating in the early stages, but increasingly showing consolidation as the disease progresses [1, 13, 16]. Changes in lung morphology over time is also described in lung histoarchitecture with changing patterns of diffuse alveolar damage [12]. Thickening of interlobular septa and crazy paving patterns, the reversed halo sign, as well as changes in airways and vessels are also described as occurring patterns [1]. Consolidations are more likely to occur in the peripheral subpleural sections and along the bronchovascular bundles of the lungs [15]. According to Carotti et al., synoptic calculations from various studies on the frequency of occurrence of various lung changes in COVID-19 have shown that GGO occur in 66%, GGO and consolidations occur in up to 47% and in 41% consolidations are detected [1]. Ye et al. [15] also identified GGO and consolidations as the dominating changes in the lungs in COVID-19.

With respect to the pathogenesis of the lung changes, CT morphological differentiation between primary bacterial pneumonia and bacterial superinfected

Rechtsmedizin 2021 · 31:145–147 <https://doi.org/10.1007/s00194-021-00462-z>  
© Springer Medizin Verlag GmbH, ein Teil von Springer Nature 2021

I. Kniep · A. Heinemann · C. Edler · J. P. Sperhake · K. Püschel · B. Ondruschka · A. S. Schröder

## COVID-19 lungs in post-mortem computed tomography

### Abstract

Post-mortem computed tomography (PMCT) is a rapid and noninvasive diagnostic tool for important contributions to the identification of pulmonary findings in the deceased with pneumonia, including cases of coronavirus disease 2019 (COVID-19). Although computed tomography (CT) shows a high sensitivity for pneumonia in living persons, it is relatively unspecific for COVID-19 pneumonia clinically. Typical CT findings for viral pneumonia therefore require confirmation by PCR tests (polymerase chain reaction tests), even if lung infections with severe acute respiratory syndrome coronavirus type 2 (SARS-CoV-2) show characteristic patterns, most frequently ground glass opacities (GGO)

and a combination of GGO and air space consolidations.

In the consecutive autopsy series of SARS-CoV-2 deaths from Hamburg, Germany, the most frequent cause of death was and still is COVID-19 pneumonia. Typical findings were frequently found in the PMCT in SARS-CoV-2-associated deaths, which were taken into account when classifying the death as COVID-19.

### Keywords

SARS-CoV-2 · Ground glass opacities · Pulmonary manifestation · Hypostasis · Consolidation

## COVID-19-Lungen in der Post-mortem-Computertomographie

### Zusammenfassung

Die Post-mortem-Computertomographie (PMCT) ist ein schnelles und nicht-invasives Diagnoseinstrument, das einen wichtigen Beitrag zur Identifizierung von Lungenbefunden bei Verstorbenen mit Pneumonie leistet – auch bei Fällen der Coronaviruskrankheit (COVID-19). Obwohl die Computertomografie (CT) eine hohe Sensitivität für Lungenentzündungen bei lebenden Personen aufweist, ist sie für eine COVID-19-Pneumonie klinisch recht unspezifisch. Typische CT-Befunde für virale Pneumonien bedürfen daher der Bestätigung durch PCR-Tests (Polymerase-Ketten-Reaktion-Tests), auch wenn die Lungeninfektion mit SARS-CoV-2 charakteristische Muster

zeigt – am häufigsten Milchglstrübungen (GGO) und eine Kombination aus GGO und Konsolidierungen.

In der konsekutiven Autopsieserie von SARS-CoV-2-Todesfällen aus Hamburg war und ist die häufigste Todesursache die COVID-19-Pneumonie. In der PMCT fanden sich bei SARS-CoV-2-assoziierten Todesfällen häufig typische Befunde, die bei der Klassifizierung des Todes als COVID-19 berücksichtigt wurden.

### Schlüsselwörter

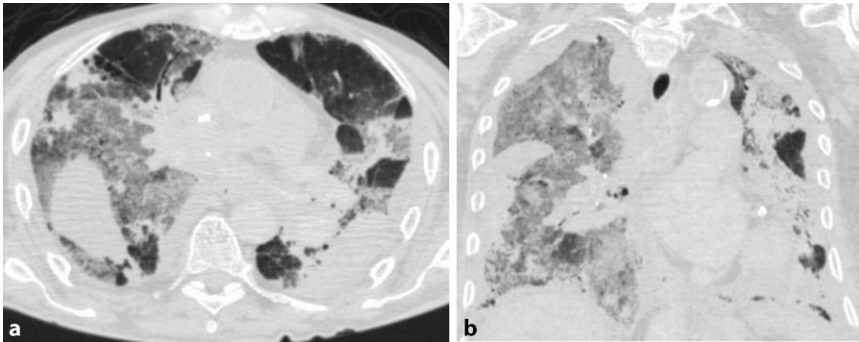
SARS-CoV-2 · Milchglstrübungen · Lungenmanifestation · Hypostase · Konsolidierung

COVID-19 pneumonia is not possible [11].

In summary, both ante-mortem and post-mortem imaging allow tracing the stages of pulmonary manifestation in COVID-19; ultimately, a “colorful” radiological picture emerges; however, depending on the severity of the disease, later stages are more frequently visible in PMCT, with earlier stages sometimes also occurring here.

An advantage of PMCT is the low-contact and thus lower-risk option of post-mortem diagnosis as an alternative to autopsy if the latter is rejected or is not pos-

sible for other reasons. Own experiences showed a higher percentage of approval to non-invasive post-mortem investigations such as PMCT in this pandemic compared to full autopsy. In SARS-CoV-2-associated deaths, PMCT can reveal a ground-breaking finding in determination of the cause of death if combined with PCR tests of nasopharyngeal swabs or it can even serve as a screening tool for further post-mortem diagnostic modalities. Ideally, PMCT together with a full post-mortem examination allow a detailed description of pulmonary changes and to define the ultimate cause of death.



**Fig. 3** ▲ Post-mortem computed tomography case 3. **a** Axial CT image (section of the lung). **b** Coronal CT image (lung section)

An important point not to be overlooked when assessing lungs with PMCT compared to clinical CT is the occurrence of post-mortem hypostasis in the dorsal segments [8]. These changes may mimic pulmonary inflammation, especially with COVID-19. Provided that hypostatic areas are not included in the assessment in PMCT, circumscribed peripheral milk glass opacity—mostly combined with consolidations—is a landmark finding that in most cases allows classification of viral pneumonia being present and may have been the cause of death. This is especially true in cases with documented advanced pulmonary involvement and symptoms during the clinical course of a confirmed COVID-19 infection.

### Corresponding address

#### I. Kniep

Institute of Legal Medicine, University Medical Center Hamburg-Eppendorf  
Butenfeld 34, 22529 Hamburg, Germany  
i.kniep@uke.de

### Compliance with ethical guidelines

**Conflict of interest.** I. Kniep, A. Heinemann, C. Edler, J.P. Spherhake, K. Püschel, B. Ondruschka and A.S. Schröder declare that they have no competing interests.

For this article no studies with human participants or animals were performed by any of the authors. All studies performed were in accordance with the ethical standards indicated in each case. Additional written informed consent was obtained from all individual participants or their legal representatives for whom identifying information is included in this article.

### References

- Carotti M, Salaffi F, Sarzi-Puttini P, Agostini A, Borgheresi A, Minorati D, Galli M, Marotto D, Giovagnoni A (2020) Chest CT features of coronavirus disease 2019 (COVID-19) pneumonia: key points for radiologists. *Radiol Med* 125(7):636–646. <https://doi.org/10.1007/s11547-020-01237-4>
- Christie A, Flach P, Ross S, Spendlove D, Bolliger S, Vock P, Thali MJ (2010) Clinical radiology and postmortem imaging (virtopsy) are not the same: specific and unspecific postmortem signs. *Leg Med* 12(5):215–222. <https://doi.org/10.1016/j.legalmed.2010.05.005>
- Chung M, Bernheim A, Mei X, Zhang N, Huang M, Zeng X, Cui J, Xu W, Yang Y, Fayad ZA, Jacobi A, Li K, Li S, Shan H (2020) CT imaging features of 2019 novel coronavirus (2019-nCoV). *Radiology* 295(1):202–207. <https://doi.org/10.1148/radiol.202000230>
- Ducloyer M, Gaborit B, Toquet C, Castain L, Bal A, Arrigoni PP, Lecomte R, Clement R, Sagan C (2020) Complete post-mortem data in a fatal case of COVID-19: clinical, radiological and pathological correlations. *Int J Legal Med*. <https://doi.org/10.1007/s00414-020-02390-1>
- Edler C, Schröder AS, Aepfelbacher M, Fitzek A, Heinemann A, Heinrich F, Klein A et al (2020) Dying with SARS-CoV-2 infection—an autopsy study of the first consecutive 80 cases in Hamburg, Germany. *Int J Legal Med* 134(4):1275–1284. <https://doi.org/10.1007/s00414-020-02317-w>
- Filigrana L, Thali M (2013) Post-mortem computed tomography (PMCT) of the lungs: pitfalls and potential misdiagnosis. In: *ECR2013*, p C-928 <https://doi.org/10.1594/ecr2013/C-0928>
- Fitzek A, Spherhake J, Edler C, Schröder AS, Heinemann A, Heinrich F, Ron A, Mushumba H, Lütgehetmann M, Püschel K (2020) Evidence for systematic autopsies in COVID-19 positive deceased: case report of the first German investigated COVID-19 death. *Rechtsmedizin* 30(3):184–189. <https://doi.org/10.1007/s00194-020-00401-4>
- Kawasumi Y, Onozuka N, Kakizaki A, Usui A, Hosokai Y, Sato M, Saito H, Ishibashi T, Hayashizaki Y, Funayama M (2013) Hypothermic death: possibility of diagnosis by post-mortem computed tomography. *Eur J Radiol* 82(2013):361–365
- Kniep I, Lutter M, Ron A, Edler C, Püschel K, Ittrich H, Heller M, Heinemann A (2020) Postmortale Bildgebung der Lunge bei COVID-19-Todesfällen. *Radiologe* 60(17):927–933. <https://doi.org/10.1007/s00117-020-00733-y>
- Leth PM, Rasmussen CH, Pagh M (2020) Findings in post-mortem CT and autopsy in a 53-year-old-man with COVID-19. *Ugeskr Laeg* 182(28):V4200289
- Lohöfer FK, Kaissis GA, Makowski MR, Braren RF (2020) CT-Diagnostik bei COVID-19: Nutzen und Limitationen im klinischen Alltag. *Dtsch Arztebl* 117(17):876–878
- Menter T, Haslbauer JD, Nienhold R, Savic S, Hopfer H, Deigendesch N, Frank S, Turek D, Willi N, Pargger H et al (2020) Postmortem examination of COVID-19 patients reveals diffuse alveolar damage with severe capillary congestion and variegated findings in lungs and other organs suggesting vascular dysfunction. *Histopathology* 77:198–209. <https://doi.org/10.1111/his.14134>
- Salehi S, Abedi A, Balakrishnan S, Gholamrezazhad A (2020) Coronavirus disease 2019 (COVID-19): a systematic review of imaging findings in 919 patients. *AJR Am J Roentgenol* 215(1):87–93. <https://doi.org/10.2214/AJR.20.23034>
- Wichmann D, Spherhake JP, Lütgehetmann M, Steurer S, Edler C, Heinemann A, Heinrich F, Mushumba H, Kniep I et al (2020) Autopsy findings and venous thromboembolism in patients with COVID-19: a prospective cohort study. *Ann Intern Med* 173(4):268–277. <https://doi.org/10.7326/M20-2003>
- Ye Z, Zhang Y, Wang Y, Huang Z, Song B (2020) Chest CT manifestations of new coronavirus disease 2019 (COVID-19): a pictorial review. *Eur Radiol* 30(8):4381–4389. <https://doi.org/10.1007/s00330-020-06801-0>
- Zheng Q, Lu Y, Lure F, Jaeger S, Lu P (2020) Clinical and radiological features of novel coronavirus pneumonia. *XST* 28(3):391–404. <https://doi.org/10.3233/XST-200687>