

CASE REPORT

Open Access



Type 1 neovascularization with polypoidal lesions complicating dome shaped macula

Jonathan Naysan^{1,2,3,4}, Kunal K Dansingani^{1,2,5}, Chandrakumar Balaratnasingam^{1,2,6} and K Bailey Freund^{1,2,3,4*}

Abstract

Dome-shaped macula is described as an inward bulge of the macula within a posterior staphyloma in highly myopic eyes. Choroidal neovascularization is a known complication that can cause visual loss in dome-shaped macula. Herein, we describe a patient who presented with features of polypoidal choroidal neovascularization that developed on a background of high myopia with dome-shaped macula.

Keywords: Dome-shaped macula, Polypoidal, Polypoidal choroidal vasculopathy, Polypoidal choroidal neovascularization, High myopia, Neovascularization, Imaging

Background

Dome-shaped macula (DSM) is an inward bulge of the macula within a posterior staphyloma in highly myopic patients [1]. Recently, Imamura et al. [2] utilized enhanced depth optical coherence tomography (EDI-OCT) to demonstrate that the anterior bulge was consequent to relative increases in scleral thickness beneath the macula. Gaucher et al. [1] reported that the prevalence of dome-shaped macula was approximately 10.7% in highly myopic eyes. However, recent reports have utilized multimodal imaging to show that the rate of DSM is higher and in the range between 15 and 20% [3, 4].

Choroidal neovascularization (CNV) is a known complication of DSM and occurs at a rate of approximately 20% [4, 5]. Deobhakta et al. [6] recently demonstrated that some eyes with DSM will manifest a shallow pigment epithelial detachment (PED) overlying an area of abrupt change in choroidal thickness typically occurring at the edge of the dome. They hypothesized that some of these flat irregular PEDs might harbor type 1 neovascularization. Herein, we describe the multimodal imaging findings in a patient with DSM who presented with

type 1 neovascularization with polypoidal lesions. To our knowledge, polypoidal type 1 neovascularization has not been documented in the setting of DSM.

Case presentation

A 50-year-old white female with a history of high myopia presented with metamorphopsia and visual deterioration in her left eye that had developed gradually over many months. She had previously been diagnosed with central serous chorioretinopathy and had received photodynamic therapy to the left eye after which two intravitreal injections of bevacizumab were administered (last treatment was over 1 year previously). She was taking metformin for glucose intolerance and was otherwise healthy.

Visual acuities were $20/250$ in the right eye, improving to $20/100$ with pinhole and $20/800$ in the left eye, improving to $20/100$ with pinhole. Her refractive error was -7.5 and -9.0 diopters right and left, respectively.

The anterior segments were unremarkable and intraocular pressures were 15 mmHg in both eyes. Ophthalmoscopic examination showed peripapillary atrophy and retinal pigment epithelial changes that were consistent with myopic degeneration (Figure 1). There was no hemorrhage.

Horizontal OCT (Heidelberg Spectralis, Heidelberg Engineering, Germany) raster scans did not overtly

*Correspondence: kbfnf@aol.com

¹ Vitreous Retina Macula Consultants of New York, 460 Park Avenue, Fifth Floor, New York, NY 10022, USA

Full list of author information is available at the end of the article

illustrate any dome configuration of the patient’s macula. However, a combination of horizontal and vertical raster scans enabled a radially asymmetric three-dimensional

dome-shaped configuration to be appreciated (Figure 2). Spectral domain OCT showed thin choroids in both eyes with subfoveal choroidal thickness of 98 and 95 μm ,

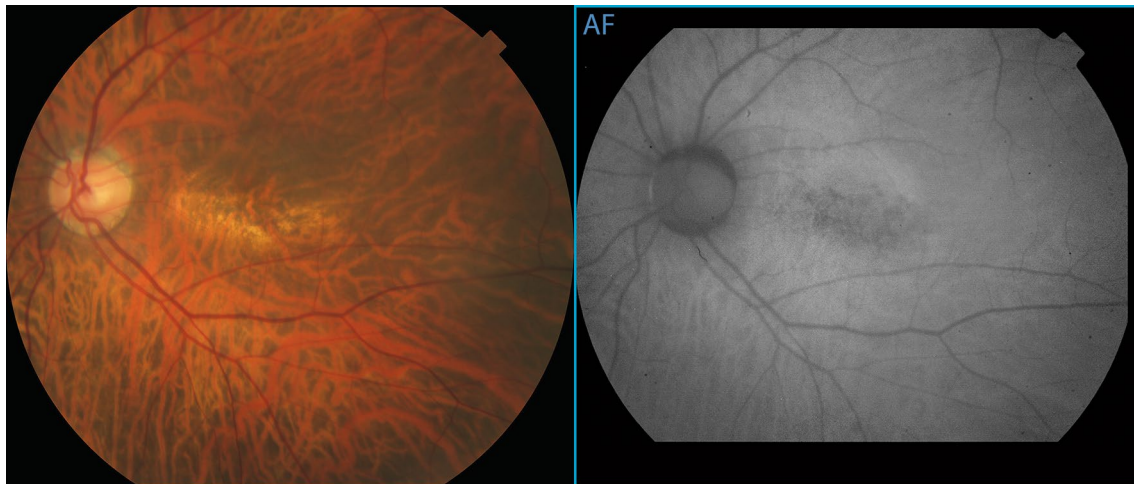


Figure 1 Color photograph and fundus autofluorescence images of the posterior pole of the *left* eye show a rectangular area of mottled retinal pigment epithelial atrophy arranged with its long axis aligned horizontally.

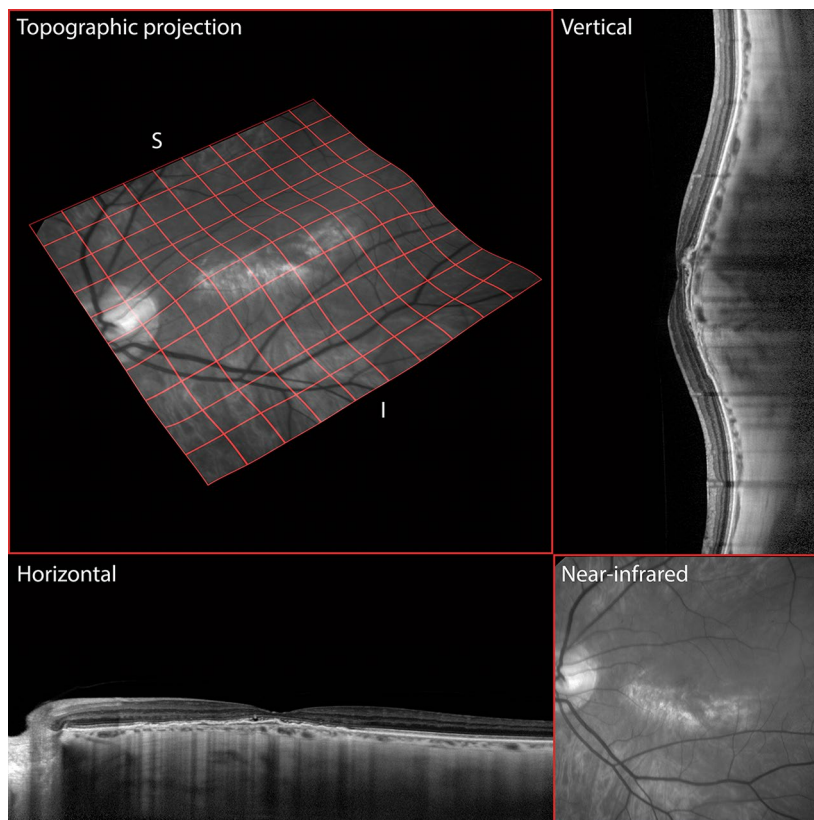


Figure 2 Topological representations of the posterior pole. Vertical and horizontal raster spectral domain optical coherence tomography line scans show that the long axis of the elliptical dome lies in the horizontal meridian, as demonstrated also by a quad-mesh projection onto an elevation-mapped near-infrared image plane. The region of atrophy lies at the inferior border of the crest of the elliptical dome, where the choroid is thinnest.

respectively. The vertically oriented OCT line scans showed an abrupt change in choroidal thickness occurring at the inferior edge of the dome (Figure 3). EDI-OCT confirmed an increase in scleral thickness beneath the site of the macular dome.

A complex irregular pigment epithelial detachment was noted at the left macula consistent with a polypoidal

lesion and its associated type 1 branching vascular network (BVN) (Figures 2, 3). Shallow subretinal fluid was also seen on these scans. Indocyanine green angiography (TRC-50FX, Topcon Corporation, Tokyo, Japan) and split spectrum amplitude decorrelation angiography (Avanti, Optovue, Fremont, CA, USA) demonstrated the polypoidal lesion and its corresponding feeding vessels (Figure 3). The

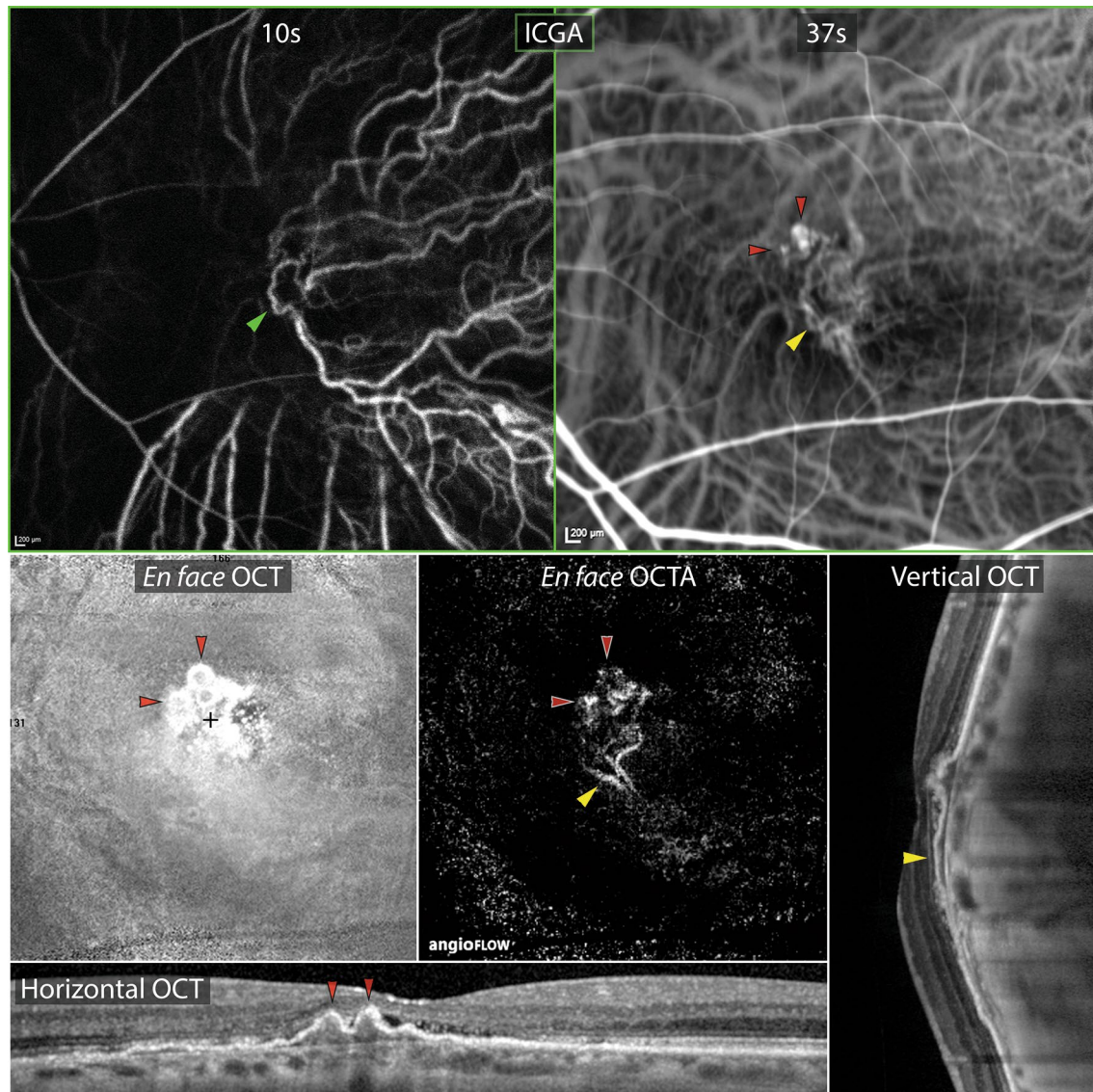


Figure 3 Multimodal imaging findings of choroidal neovascularization. Early and transit phase indocyanine green angiographic frames demonstrate perfusion of a choroidal vascular loop at the fovea (*green arrowhead*) followed by hyperfluorescence of at least three polypoidal lesions (*red arrowheads*) and their feeding network (*yellow arrowhead*). Magnified horizontal and vertical raster enhanced depth spectral domain optical coherence tomographic (OCT) line scans through these areas show the polypoidal lesions as peaked pigment epithelial detachments (PEDs) and the feeding network as an adjacent shallow irregular PED. The presence of pathologically dilated choroidal vessels is noted with overlying loss of choriocapillaris tissue, especially at the crest of the dome. *En face* OCT (3×3 mm) through the shallow PED reveals the spherical morphology of at least three polypoidal lesions. *En face* OCT angiography (3×3 mm) through the PED isolates the type 1 neovascular tissue from the rest of the choroid and shows significant flow through the feeder vessels and within the polypoidal lesions.

ICGA also showed relatively larger caliber choroidal vessels in the thicker choroid at the superior edge of the dome.

DSM is associated with high myopia [1] and previous reports have shown that this diagnosis can be missed if the macula is evaluated with a single OCT scan orientation. Liang et al. [4] reported that vertical and horizontal OCT scans are necessary to achieve diagnostic sensitivity for DSM. In their paper, they showed that of those eyes with DSM, the diagnosis could be made using only the vertical section in 77% of cases and using only the horizontal section in 2% of cases. These findings are reflected in our patient in whom the diagnosis of DSM was confirmed only after integration of vertical and horizontal OCT scans to construct a three-dimensional structure.

Vision loss from DSM can be consequent to serous neurosensory detachment masquerading as central serous chorioretinopathy [5]. Foveal retinoschisis [4, 7] and choroidal neovascularization [1, 7] are other known complications that can arise during the natural course of DSM. The rate of CNV in DSM is approximately 20%, however, little information is available concerning the morphology of these lesions. Utilizing OCT angiography and other imaging modalities, we show that CNV in DSM can manifest a polypoidal configuration. Polypoidal neovascular changes have also been described in central serous chorioretinopathy [8, 9], choroidal nevi [10, 11], peripheral exudative hemorrhagic chorioretinopathy [12] and optic nerve melanocytoma [13].

Conclusion

Scleral thickness at the site of DSM is increased in contradiction to what is usually found in high myopia [14]. Previous authors used this observation to postulate that control of ocular expansion in myopia may be more complex than initially proposed [2]. Polypoidal changes to type 1 neovascularization in the setting of DSM may reflect the unique stretch and mechanical forces being applied to the macula and choroid in this condition. It will be important to study other cases of CNV in DSM to validate this hypothesis.

Consent

Written informed consent was obtained from the patient for publication of this Case report and any accompanying images. A copy of the written consent is available for review by the Editor-in-Chief of this journal.

Abbreviations

DSM: dome-shaped macula; EDI-OCT: enhanced depth imaging optical coherence tomography; CNV: choroidal neovascularization; PED: pigment epithelial detachment; OCT: optical coherence tomography; BVN: branching vascular network.

Authors' contributions

JN—acquisition of data, conceptualization of manuscript, review of literature, drafting/editing of the report. KD—acquisition of data, conceptualization of manuscript, editing the report, preparation of image panels. CB—conceptualization of manuscript, editing the report, review of literature. KBF—design of project, conceptualization of manuscript, editing the report, analysis and interpretation of data, final approval of manuscript. All authors have contributed significantly. All authors read and approved the final manuscript.

Author details

¹ Vitreous Retina Macula Consultants of New York, 460 Park Avenue, Fifth Floor, New York, NY 10022, USA. ² The LuEsther T. Mertz Retinal Research Center, Manhattan Eye, Ear and Throat Hospital, New York, NY, USA. ³ Department of Ophthalmology, New York University School of Medicine, New York, NY, USA. ⁴ Department of Ophthalmology, North Shore-Long Island Jewish Health System, New York, NY, USA. ⁵ Moorfields Eye Hospital, London, UK. ⁶ Department of Physiology and Pharmacology, Lions Eye Institute, University of Western Australia, Crawley, Australia.

Compliance with ethical guidelines

Competing interests

K. Bailey Freund: is a consultant to Genentech, ThromboGenics, Ohr Pharmaceutical, Optos, Optovue, and Heidelberg Engineering (honorarium for each). The other authors have no conflicting interests to disclose.

Financial support

The LuEsther T. Mertz Retinal Research Center and The Macula Foundation, New York. The funding bodies had no role in the design or conduct of this research or the decision to publish.

Statement of originality

The work submitted here is original and has not been presented or published elsewhere.

Received: 24 June 2015 Accepted: 29 June 2015

Published online: 09 July 2015

References

- Gaucher D, Erginay A, Leclaire-Collet A, Haouchine B, Puech M, Cohen SY et al (2008) Dome-shaped macula in eyes with myopic posterior staphyloma. *Am J Ophthalmol* 145(5):909–914
- Imamura Y, Iida T, Maruko I, Zweifel SA, Spaide RF (2011) Enhanced depth imaging optical coherence tomography of the sclera in dome-shaped macula. *Am J Ophthalmol* 151(2):297–302
- Chebil A, Ben Achour B, Chaker N, Jedidi L, Mghaieth F, El Matri L (2014) Choroidal thickness assessment with SD-OCT in high myopia with dome-shaped macula. *J francais d'ophtalmologie*. 37(3):237–241
- Liang IC, Shimada N, Tanaka Y, Nagaoka N, Moriyama M, Yoshida T et al (2015) Comparison of clinical features in highly myopic eyes with and without a dome-shaped macula. *Ophthalmology*. doi:10.1016/j.ophtha.2015.04.012
- Viola F, Dell'Arti L, Benatti E, Invernizzi A, Mapelli C, Ferrari F et al (2015) Choroidal findings in dome-shaped macula in highly myopic eyes: a longitudinal study. *Am J Ophthalmol* 159(1):44–52
- Deobhakta A, Ross AH, Helal J, Maia A, Freund KB (2015) Localized choroidal thickness variation and pigment epithelial detachment in dome-shaped macula with subretinal fluid. *Ophthalmic Surg Lasers Imagn Retina* 46(3):391–392
- Ellabban AA, Tsujikawa A, Matsumoto A, Yamashiro K, Oishi A, Ooto S et al (2013) Three-dimensional tomographic features of dome-shaped macula by swept-source optical coherence tomography. *Am J Ophthalmol* 155(2):320–328
- Toyama T, Ohtomo K, Noda Y, Ueta T (2014) Polypoidal choroidal vasculopathy and history of central serous chorioretinopathy. *Eye* 28(8):992–997

9. Yang LH, Jonas JB, Wei WB (2015) Conversion of central serous chorioretinopathy to polypoidal choroidal vasculopathy. *Acta Ophthalmol*. doi:[10.1111/aos.12606](https://doi.org/10.1111/aos.12606)
10. Asao K, Hashida N, Nishida K (2014) Choroidal nevus in an eye with polypoidal choroidal vasculopathy. *Case Rep Ophthalmol* 5(3):463–467
11. Peiretti E, Pozzoni MC, Fossarello M, Spaide RF (2009) Polypoidal choroidal vasculopathy in association with choroidal nevus. *Retinal Cases Brief Rep* 3(1):12–14
12. Goldman DR, Freund KB, McCannel CA, Sarraf D (2013) Peripheral polypoidal choroidal vasculopathy as a cause of peripheral exudative hemorrhagic chorioretinopathy: a report of 10 eyes. *Retina* 33(1):48–55
13. Bartlett HM, Willoughby B, Mandava N (2001) Polypoidal choroidal vasculopathy in a patient with melanocytoma of the optic nerve. *Retina* 21(4):396–399
14. Hayashi M, Ito Y, Takahashi A, Kawano K, Terasaki H (2013) Scleral thickness in highly myopic eyes measured by enhanced depth imaging optical coherence tomography. *Eye* 27(3):410–417

**Submit your next manuscript to BioMed Central
and take full advantage of:**

- Convenient online submission
- Thorough peer review
- No space constraints or color figure charges
- Immediate publication on acceptance
- Inclusion in PubMed, CAS, Scopus and Google Scholar
- Research which is freely available for redistribution

Submit your manuscript at
www.biomedcentral.com/submit

