



Bilateral Anterior Shoulder Dislocation with Symmetrical Greater Tuberosity Fracture following Seizure

Ashish Suryavanshi¹, Amber Mittal¹, Snehal Dongre¹, Neeti Kashyap²

ABSTRACT

Introduction: Majority of bilateral shoulder dislocations are posterior. Simultaneous bilateral anterior shoulder dislocations and bilateral anterior fracture-dislocations are rare and mostly of traumatic origin. We present a rare case of bilateral anterior shoulder dislocation with symmetrical greater tuberosity fracture following an episode of seizure with an unusual injury mechanism which was treated conservatively.

Case Report: A 45 year old office worker presented to the Casualty of our hospital with bilateral anterior shoulder dislocations with greater tuberosity fractures following an episode of seizure. Both shoulders were reduced by Kocher manoeuvre using total intravenous anaesthesia (TIVA) & were strapped to the chest for 6 weeks. At the end of 1 year follow-up, there were no reasonable loss of strength or restriction of motion and the shoulders were defined as stable.

Conclusion:

Although bilateral shoulder dislocations are mostly posterior, bilateral anterior dislocations may not be as rare as previously thought and are frequently missed by the orthopaedic residents in the casualty department. Further to the best of our knowledge, our case represents the first case of bilateral anterior shoulder dislocation with symmetrical greater tuberosity fracture with an unusual mechanism of

injury following an episode of seizure in a young male patient that was successfully managed by conservative means.

Keywords: Bilateral; shoulder; dislocation; greater tuberosity

Introduction

Although unilateral anterior shoulder dislocation is the most common major joint dislocation encountered in the casualty department, bilateral glenohumeral dislocations are rare and mostly posterior [1]. Such dislocations are seen usually after trauma, diabetic nocturnal hypoglycemia, grandmal seizures, gymnasium injuries or electric shocks. Bilateral anterior dislocations [2-27] are very rare and bilateral fracture-dislocation is even rarer, with only few case reports available. The purpose of this case report is to present a very rare case of bilateral anterior shoulder dislocation with symmetrical displaced greater tuberosity fracture with an unusual mechanism of injury following an episode of seizure. To the best of our knowledge this is the first case of its kind.

Case report

A 45 year old office worker presented to the Casualty of our hospital following an unwitnessed collapse, while he was standing and watching television. He noticed jerky movements of the limb and tried to take support of the wall on his side. However he could not grab the wall because of involuntary limb movements so he tried to take support with his forehead against the wall and while doing so he lost consciousness and fell down. He had fallen straight on to his forehead forwards with both his arms abducted and externally rotated. He also sustained injury to his forehead. He was found by his wife after door of the house had to be broken up and he appeared to be disorientated. The patient was exhausted with generalised weakness and subsequent difficulty in moving either arm. This was the second episode of seizure in 6 months. Physical examination showed bilateral squaring of

¹Dept of Orthopaedics, Seth G.S. Medical College, Mumbai, India.

²B. J. Medical College, Pune, India.

Address of Correspondence

Dr Ashish Vitthalrao Suryawanshi
Department of Orthopaedics, Seth G.S
Medical College & K.E.M. Hospital, Mumbai
6th Floor, M.S.B. Parel, Mumbai - 400012.
Tel: 09370671319 / 09920701801
E- Mail: ashishvsuryawanshi@gmail.com



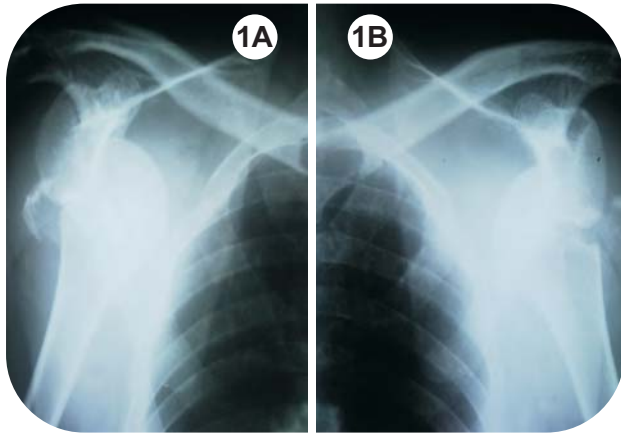


Figure 1 : Radiograph of Right shoulder (A) and Left Shoulder (B) showing anterior dislocation with greater

her shoulders (epaulet sign) without evidence of peripheral motor, sensory and vascular deficit and both two shoulders were in fixed abduction and external rotation. Radiographic examination revealed bilateral anterior shoulder dislocations with greater tuberosity fractures (Fig. 1A, B). Both shoulders were reduced by Kocher manoeuvre under image intensifier using total intravenous anaesthesia (TIVA) with appropriate muscle relaxation. Both the arms were strapped to the chest after keeping cotton pads in

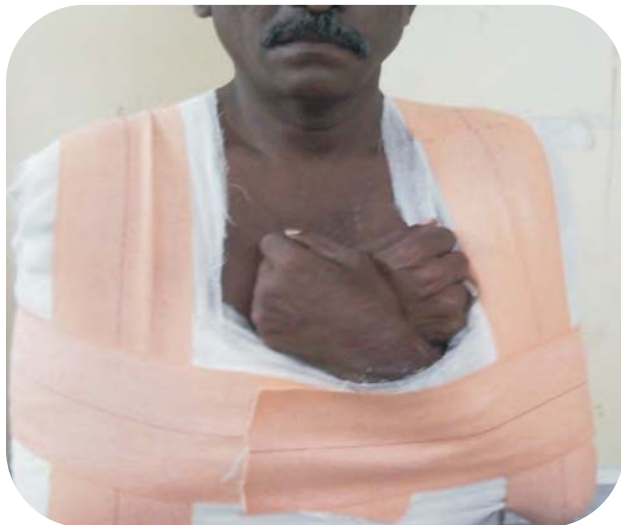

Figure 2 : Photograph of patient having bilateral anterior shoulder dislocation with greater tuberosity fracture after reducing and applying shoulder arm strapping.

the axilla for 6 weeks (Fig. 2). Pendulum exercises were begun after 6 weeks. On radiological confirmation of fracture union (Fig. 3A, B), vigorous physiotherapy of both the shoulders were started. At the end of 1 year follow-up, there were no appreciable loss of strength or restriction of motion and the shoulders were stable with patient able to carry out all functions without limitations.

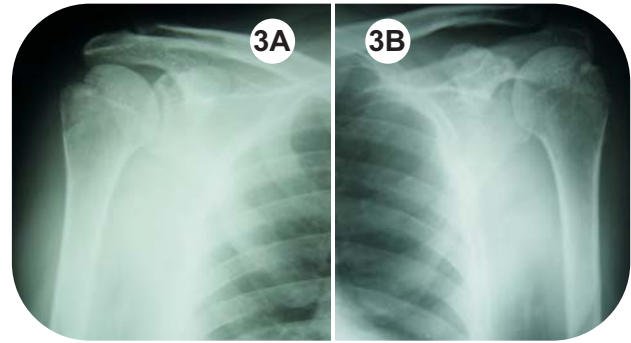


Figure 3: Radiograph of Right (A) and Left (B) shoulder showing healing fractures with good reduction of the shoulder joints.

Discussion

The wide range of motion provided by the shoulder complex allows the glenohumeral joint to be used as a stable fulcrum for placing the upper extremity at various positions in three-dimensional space. A consequence of this flexibility, however, is the propensity for the joint to become unstable. As such, the shoulder is one of the most commonly dislocated joints in the human body, with a reported incidence of 17/100,000 per year [28,29]. Shoulder dislocations occur predominantly in two groups of patients, younger patients following significant trauma and elderly patients having capsular laxity following trivial insult. Of the shoulder dislocations, 96 % are anterior, 3% posterior and 1 % inferior [30]. Bilateral dislocation of the shoulder is a rare entity usually presenting as posterior dislocations following epilepsy, electric shock or electroconvulsive therapy. According to Page et al [3] there are limited reported cases of bilateral posterior dislocations. Bilateral anterior dislocations are still more rare with only handful of cases in the literature.

The posterior dislocations are more common following seizures because contraction of the relatively weak external rotators of the humerus; infraspinatus, teres minor and the posterior fibres of deltoid are overcome by the more powerful internal rotators; subscapularis, pectoralis major, latissimus dorsi and the anterior fibres of deltoid. The resultant adduction and internal rotation is usually sufficient to cause posterior glenohumeral dislocation. The mechanism of injury in our case is fall onto the forehead with both his arms abducted and externally rotated to produce the bilateral anterior displacement. The only external injury to our patient was an injury to forehead in order to sustain this rare presentation.

Cooper in 1839 first reported an association between seizures and posterior shoulder dislocation [24]. In 1902 Mynter first described bilateral posterior shoulder dislocations in a patient following a seizure



Table 1: Review of the cases reported in the international literature with bilateral anterior shoulder dislocation of the glenohumeral joint with their mechanism of injury.

Author	Injury mechanism/ cause	Associated features
Cresswell & Smith[5], Jones M[6]	Bench press	No fracture
Maffulli & Mikhail[7]	Weight lifting	No fracture
Turhan &Demirel[8]	Horse rider	No fracture
Velkes et al [9] , Devalia and Peter[10]	Trauma/fall	No fracture
Ngim et al[11]	Domestic assault	No fracture
Singh and Kumar[12]	Sequential dislocations; traumatic followed by atraumatic dislocation	No fracture
Sreesobh et al[4]	Sequential dislocations; atraumatic followed by traumatic dislocation	No fracture
Laurent Galiois et al [13] and Ioannis Tsionos [14]	Trauma/ fall/ emotional problem	Combined anterior and posterior dislocation
Lin et al[15]	Forklift	Fracture with neurovascular injury
Tughan kalkan[16]	Fall while hanging curtains	No fracture:brachial palsy in 1
Aufranc[17], Ribbans [18]	Seizure	No fracture
Ozer H [19]	Electric Shock	Combined anterior & posterior dislocation
Mynter [20]	Camphor overdose	Subacromial dislocation
Siwach et al [21]	Backward pull by animal	No fracture
Cottias et al[22]	Hypoglycemia induced convulsion	Coracoid and greater tuberosity fracture
Okamura et al[23]	Skiing	No fracture
Our case	Seizure	Symmetrical greater tuberosity fracture

[20]. Aufranc reported the first bilateral anterior shoulder dislocations following a seizure in 1966 [17]. Only few cases have subsequently been reported in the literature and sometimes they are missed [25]. Bilateral anterior dislocations following seizures [17,18] and electric shock are rare [26,27]. The true incidence of rotator cuff tears that occur in association with shoulder dislocations is unknown, but it is believed to increase dramatically with age. As such, although the overall rate of rotator cuff tear may be as low as 15%, its incidence in patients older than 40 years has been reported to be 35% to 40% [31]. In patients older than 60 years of age, the incidence of concomitant rotator cuff tears may be as high as 80%

[31]. Our case had bilateral greater tuberosity fracture not associated with rotator cuff tear.

CONCLUSION

Although bilateral shoulder dislocations are mostly posterior, bilateral anterior dislocations may not be as rare as previously thought and are frequently missed by the orthopaedic residents in the casualty department. Further to the best of our knowledge, our case represents the first case of bilateral anterior shoulder dislocation with symmetrical greater tuberosity fracture with an unusual mechanism of injury following an episode of seizure in a young male patient that was successfully managed by



conservative means

CLINICAL MESSAGE

Bilateral anterior shoulder dislocations are not uncommon and are frequently missed by the orthopaedic residents in the casualty department. Furthermore good result can be obtained by conservative management, even in bilateral dislocations with displaced tuberosity fractures.

REFERENCES

- Brown RJ. Bilateral dislocation of the shoulders. *Injury* 1984;15:267-73.
- Dinopoulos HT, Giannoudis PV, Smith RM, Matthews SJ. Bilateral anterior shoulder fracture-dislocation. A case report and a review of the literature. *Int Orthop* 1999; 23:128-30.
- Page AE, Meinhard BP, Schulz E, Toledano B. Bilateral posterior fracture-dislocation of the shoulders: management by bilateral shoulder hemiarthroplasties. *J Orthop Trauma* 1995;9:526-9.
- Sreesobh KV, Chacko B. An unusual case of bilateral anterior dislocation of shoulder. *J Orthopaedics* 2005;2(4):e6.
- Cresswell TR, Smith RB. Bilateral anterior shoulder dislocations in bench pressing: an unusual cause. *Br J Sports Med.* 1998 Mar;32(1):71-2.
- Jones M. Bilateral anterior dislocation of the shoulders due to the bench press. *Br J Sports Med.* 1987 Sep;21(3):139.
- Maffulli N, Mikhail Bilateral anterior glenohumeral dislocation in a weight lifter. *Injury* 1990 Jul;21(4):254-6.
- Turhan E, Demirel M. Bilateral anterior glenohumeral dislocation in a horse rider: a case report and a review of the literature. *Arch Orthop Trauma Surg* 2008;128:79-82.
- Velkes S, Lokiec F, Ganel A. Traumatic bilateral anterior dislocation of the shoulders. A case report in a geriatric patient. *Arch Orthop Trauma Surg* 1991;110(4):210-211.
- Devalia KL, Peter VK. Bilateral post traumatic anterior shoulder dislocation. *J Postgrad Med* 2005;51(1):72-73.
- Ngim NE, Udorroh EG, Udosen AM. Acute bilateral anterior shoulder dislocation following domestic assault--case report. *West Afr J Med.* 2006; 25(3):256-7.
- Singh S, Kumar S. Bilateral anterior shoulder dislocation: a case report. *Eur J Emerg Med.* 2005 Feb;12(1):33-5.
- Laurent Gallois et al SICOT online report E 024 Feb. 2003
- Tsionos I, Karahalios T, Zibis AH, Malizos KN. Combined anterior and posterior shoulder dislocation as a manifestation of a brain tumour. *Acta Orthop Belg.* 2004 Dec;70(6):612-5.
- CY Lin, SJ Chen, CT Yu, and IL Chang. Simultaneous bilateral anterior fracture dislocation of the shoulder with neurovascular injury: report of a case. *Int Surg,* 2007 92:
- Kalkan T, Demirkale I, Ocguder A, Unlu S, Bozkurt M. [Bilateral anterior shoulder dislocation in two cases due to housework accidents]. *Acta Orthop Traumatol Turc.* 2009 May-Jul;43(3):260-3.
- Aufranc OE, Jones WN, Turner RH. Bilateral shoulder fracture-dislocations. *JAMA.* 1966 Mar 28;195(13):1140-3.
- Ribbans WJ. Bilateral anterior dislocation of the shoulder following a grand-mal convulsion. *Br J Clin Pract.* 1989 May;43(5):181-2.
- Ozer H, Baltaci G, Selek H et al. Opposite-direction bilateral fracture dislocation of the shoulders after an electric shock. *Arch Orthop Trauma Surg.* 2005;125:499-502.
- Mynter H: Subacromial dislocation from the muscular spasm. *Ann Surg* 1902, 36:117.
- Siwach R, Singh R, Rohilla R. Bilateral anterior dislocation of the shoulder - a case report and review of the literature. *Injury Extra.* 2008;39:394-7.
- Cottias P, le Bellec Y, Jeanrot C, Imbert P, Hutten D, Masmejean EH. Fractured coracoid with anterior shoulder dislocation and greater tuberosity fracture--report of a bilateral case. *Acta Orthop Scand.* 2000 Feb;71(1):95-7.
- Okamura K, Seino H, Yamamoto N, Hirose T, Goroku T, Horigome K. Simultaneous Bilateral Anterior Dislocation of the Shoulder caused by Skiing Accident -A Case Report in a Teenager-Jpn. *J. Orthop. Sports Med* 23: 324-328,2004.
- Cooper A. On the dislocation of the Os Humeri upon the dorsum scapulae and upon the shoulder joint. *Guys Hospital Report* 1839, 4:265.
- O'connor-Read L, Bloch B, Brownlow H. A missed orthopaedic injury following a seizure: a case report. *J Med Case Reports.* 2007 May 10;1:20.
- Yuen MC, Tung WK. The use of the spaso technique in a patient with bilateral anterior dislocations. *Am J Emerg Med* 2001;19:64-66.
- Martínez AA, Herrero L, Herrera A. Bilateral anterior shoulder dislocation due to electric shock. *European Journal of Orthopaedic Surgery & Traumatology.* 2001; 11:121-122.
- Kazar B, Relovszky E. Prognosis of primary dislocation of the shoulder. *Acta Orthop Scand* 1969;40:216-224.
- Kroner K, Lind T, Jensen J. The epidemiology of shoulder dislocations. *Arch Orthop Trauma Surg* 1989;108:288-290.
- Kumar KS, O'Rourke S, Pillay JG. Hands up: A case of bilateral inferior shoulder dislocation. *Emerg Med J* 2001;18:404-5.
- Wirth MA, Rockwood CA. Subluxations and dislocations about the glenohumeral joint. In Bucholz R, Heckman J, eds. *Rockwood and Green's fractures in adults*, 5th ed. Philadelphia: Lippincott Williams & Wilkins, 2001:1109-1207.

Conflict of Interest : NONE

Source of Funding : NONE

