



## Acute inferior ST-segment elevation myocardial infarction and previous cryptogenic stroke caused by a paradoxical embolism with a concomitant pulmonary embolism

Hong-Yu ZHANG<sup>1</sup>, Yan ZHANG<sup>2</sup>, Yan-Jun CAO<sup>1\*</sup>, Lian-Lian MEI<sup>1</sup>, Xia ZHANG<sup>1</sup>, Zhi-Guo WU<sup>1</sup>,  
Bao-Hua QIU<sup>1</sup>, Shu-Jing WANG<sup>1</sup>

<sup>1</sup>Department of Cardiology, Tianjin Baodi Hospital, Baodi Clinical College of Tianjin Medical University, Tianjin, China

<sup>2</sup>School of Basic Medical Sciences, Tianjin Medical University, Tianjin, China

*J Geriatr Cardiol* 2017; 14: 421–424. doi:10.11909/j.issn.1671-5411.2017.06.003

**Keywords:** Myocardial infarction; Paradoxical embolism

A 61-year-old woman was hospitalized for a chief complaint of sudden chest tightness with sweating for two hours. The chest tightness and sweating occurred suddenly and without remission after a morning stool. Electrocardiography showed a complete atrioventricular (AV) block and arc-like elevation of the ST-segment in leads II, III, AVF, V<sub>7</sub>–V<sub>9</sub>, and V<sub>3R</sub>–V<sub>5R</sub>, at about 0.05–0.15 mV. After being administered 1 mg of atropine in the emergency room (ER), the patient was admitted to the cardiology department. The patient had been found in a cyanotic state two years previously, but did not receive any treatment; she was diagnosed with a transient ischemic attack (TIA) 1.5 years previously because of limb dyskinesia accompanied by slurred speech. Finally, she had been newly diagnosed with pulmonary hypertension one year previously because of exercise limitations (she developed chest tightness after walking on a flat surface for 250 m, which was alleviated after resting).

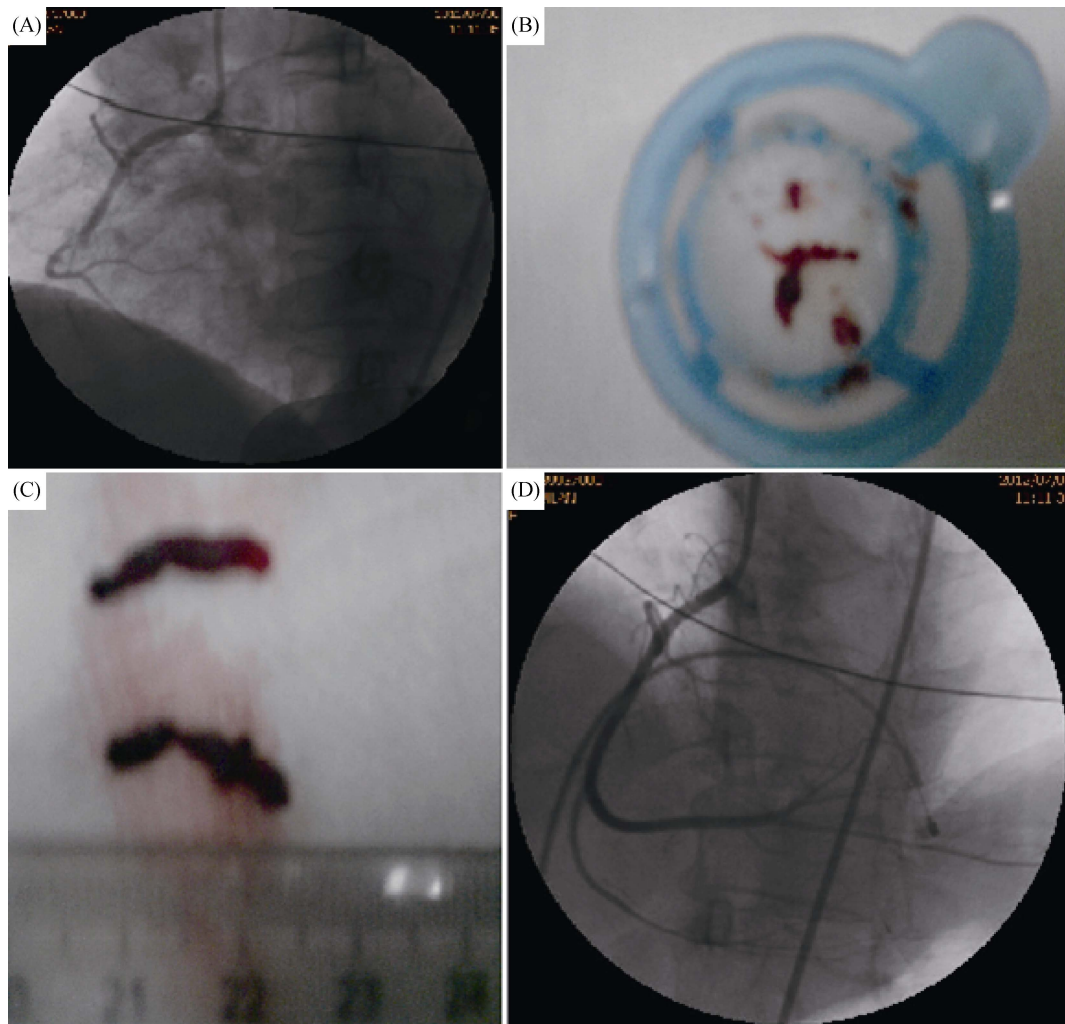
Results of her physical examination revealed the following: blood pressure, 93/65 mmHg (1 mmHg = 0.133 kPa); lip cyanosis; jugular vein engorgement; no evidence of rhonchi and moist rales; bilateral expansion of the heart; heart rate, 78 beats/min; arrhythmia; S1 low blunt; P2 hyperthyroidism and split; and no pathological murmurs.

We performed percutaneous coronary intervention (PCI). Coronary angiography showed that the right coronary artery was completely occluded before the second turn, where a thrombus was seen (Figure 1A). We injected 0.5 mg tirofiban twice by the guide catheter, and a medium-sized thrombus was withdrawn by thrombus aspiration (Figure 1B). The invasive blood pressure decreased during aspiration, and no blood returning was found to be under negative

pressure. We returned the guide wire and catheter, and two 2.0-cm thromboses were removed, respectively, with the catheter during PCI (Figure 1C). Subsequent coronary angiography showed no thrombus, stenosis, or dissection in the right coronary artery with a Thrombolysis in Myocardial Infarction (TIMI) Grade of 3 (Figure 1D). We then began treating the patient with anti-thrombotic and lipid-regulating therapy.

Results of the postoperative examination revealed the following: Blood creatine kinase isoenzyme (CK-MB), 462.9 U/L; hypoxic troponin T (cTnT) > 10,000 ng/L; blood gas analysis: arterial oxygen partial pressure, 44.0 mmHg; and arterial carbon dioxide partial pressure, 36.0 mmHg. Examination with plain radiography revealed pulmonary artery protrusion and an enlarged right ventricle. Subxiphoid four-cavity ECG revealed right-to-left color-cross blood flow at the foramen ovale, expansion of the right heart (right ventricle, 34 mm; right atrium, 61 mm × 48 mm), widening of the main pulmonary artery (31 mm), pulmonary hypertension (mean pulmonary artery pressure, 36 mmHg), and mild tricuspid regurgitation (Figure 2A). On the 18th day of hospitalization, the pulmonary artery pressure was 60/24 mmHg (mean arterial pressure, 37 mmHg), results of the acute pulmonary vasodilation test with iloprost inhalation were negative, and pulmonary angiography showed bilateral pulmonary embolism (Figure 2B, C). Lower-limb phlebography showed thrombosis (Figure 2D). On the 25<sup>th</sup> day of hospitalization, the inferior vena cava was placed in a permanent filter with warfarin to avoid thrombosis. On the 31<sup>st</sup> day of hospitalization, the patient improved and was discharged. The primary diagnosis was a venous thromboembolism (VTE), a presumed paradoxical embolism, and acute myocardial infarction (AMI).

\*Correspondence to: doctoryjc@yahoo.com.cn



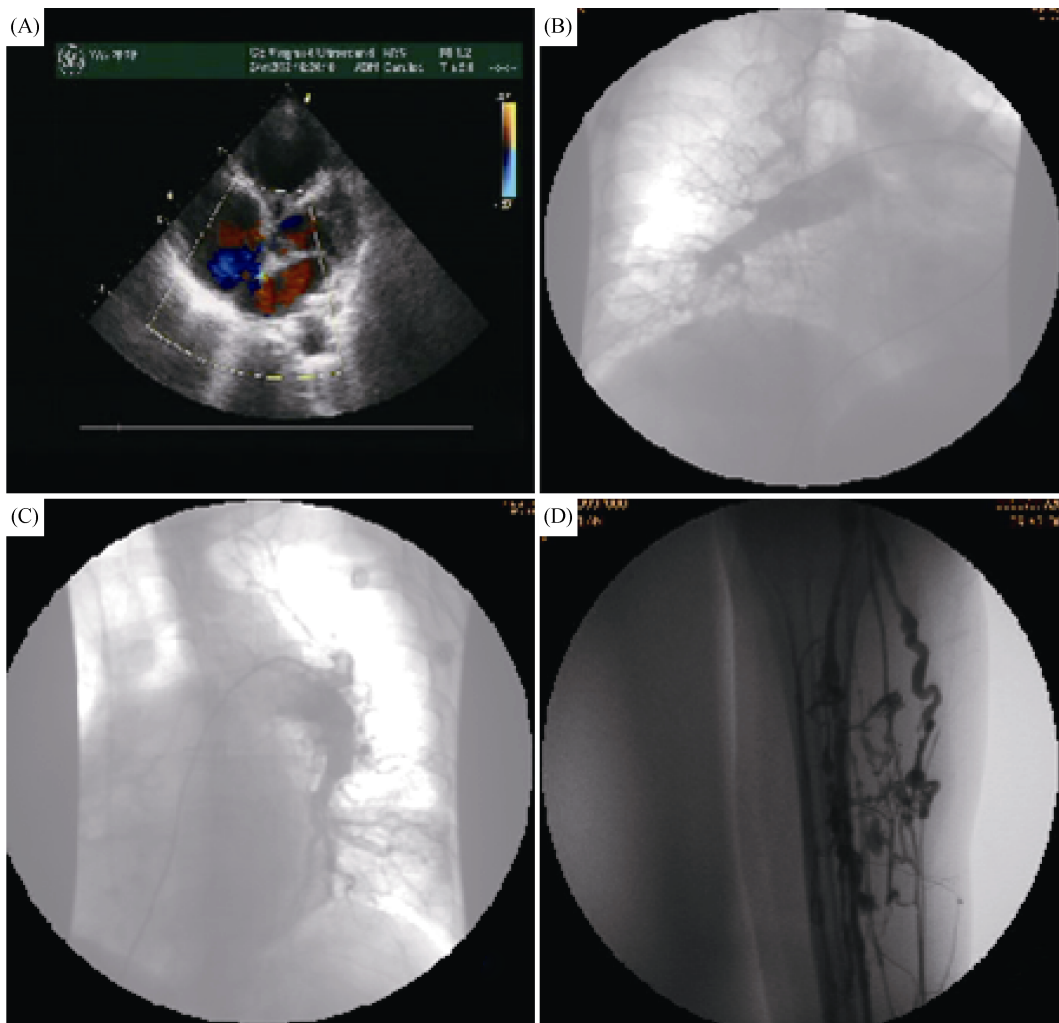
**Figure 1. PCI finding during the surgery.** (A): right coronary angiography before intervention; (B): a miliary size of thrombosis; (C): two thrombotic block of 2.0 cm; (D): results of right coronary angiography after interventional therapy. PCI: percutaneous coronary intervention.

AMI is spontaneously caused by atherosclerotic plaque rupture, ulcers, cracks, erosion, or dissection, which may cause thrombosis in one or more coronary arteries and result in reduced myocardial blood flow together with myocardial necrosis. Rarely, it can also occur secondarily to coronary arterial embolization, which is caused by the shedding of an embolus from other areas, but such other areas are generally the left heart and proximal segment artery.<sup>[1]</sup>

In clinical practice, it is rare to find AMI caused by a paradoxical embolism,<sup>[2]</sup> which usually results in a misdiagnosis, and missed diagnosis would cause improper treatment and worse outcomes. Because its contradictory embolization also involves cerebral vessels, it can trigger ischemic stroke, which is the focus of current studies,<sup>[3]</sup> due to rare cases of contradictory embolisms involving the coronary artery, related studies are generally single-case re-

ports.<sup>[4-6]</sup> Thus, its diagnosis, treatment, and prevention are controversial.

For diagnosis, a paradoxical embolism should meet the following four conditions: (1) deep vein thrombosis with or without pulmonary embolism; (2) abnormal intra-cardiac arteriovenous blood flow, arteriovenous fistula of systemic circulation, or pulmonary circulation; (3) no possibility that the embolus came from the atria sinistrum or proximal segmental artery; and (4) persistent right heart pressure (e.g., pulmonary hypertension) or transiently increased right heart pressure (e.g., during the Valsalva maneuver or cough). However, it can only be speculated as contradictory embolism when the above conditions are met. The diagnosis of paradoxical embolism has been termed definitive when made at autopsy or when the thrombus is seen crossing an intra-cardiac defect during ECG in the face of an arterial



**Figure 2. Post surgery PCI.** (A): Echocardiographic examination results; (B & C): pulmonary angiography; (D): lower limb venography. PCI: percutaneous coronary intervention.

embolus.<sup>[7]</sup> This patient met the above four criteria, but ECG did not reveal an embolus crossing over the patent foramen ovale, so only a hypothetical paradoxical coronary embolism could be diagnosed clinically. In this case, the patient had previously been diagnosed with TIA, which may have been the result of the paradoxical embolism, and AMI occurred because of the paradoxical embolism this time.

For paradoxical coronary embolisms, the first therapeutic options should be selective thrombolysis, anticoagulation therapy, or thrombus aspiration. Balloon dilatation is not advocated for coronary thrombosis because the repeated expansion of the balloon can cause a "stirring effect" and subsequent embolus shedding, thus resulting in slow or no blood flow. If emboli are reduced after aspiration, together with Grade 3 TIMI blood flow, stents should not be used; additionally, it remains controversial whether stenting should be used if Grade 3 TIMI blood flow is not achieved.<sup>[4-6,8]</sup>

In this patient, after two, 2.0-cm thromboses were aspirated, coronary angiography revealed no thrombus, stenosis, or dissection in the right coronary artery with Grade 3 TIMI without the need to use any balloon dilatation or stenting.

Therapeutic approaches for the secondary prevention of paradoxical embolisms include medical treatment to prevent the recurrence of venous thrombosis, elimination of the pathway allowing the paradoxical embolism to occur (percutaneous or surgical closure), or a combination of these.<sup>[2,9]</sup> Controversy remains as to the most effective treatment strategy.

To prevent the recurrence of paradoxical embolism in this patient, warfarin therapy and an inferior vena cava permanent filter was used. No patent foramen ovale closure was performed, which may increase the occurrence of re-contradictory embolization, so this patient should undergo long-term follow-up.

## References

- 1 White HD, Thygesen K, Alpert JS, *et al.* Clinical implications of the third universal definition of myocardial infarction. *Heart* 2014; 100: 424–432.
- 2 Windecker S, Stoeckly S, Meier B. Paradoxical Embolism. *J Am Coll Cardiol* 2014; 64: 403–415.
- 3 Messé SR, Kent DM. Patent foramen ovale and cryptogenic stroke. *N Engl J Med* 2013; 369: 92–93.
- 4 Wasek WC, Samul W, Ryczek R, *et al.* Unique case of ST-segment elevation myocardial infarction related to paradoxical embolization and simultaneous pulmonary embolization: clinical considerations on indications for patent foramen ovale closure in no-guidelines land. *Circulation* 2015; 131: 1214–1223.
- 5 Namasivayam M, Spina R, Bobillo L, *et al.* Acute myocardial infarction due to paradoxical embolism. *Int J Cardiol* 2016; 209: 190–191.
- 6 Neisius U, Northridge DB, Cruden NL, *et al.* Myocardial infarction associated with patent foramen ovale and paradoxical embolism: a case series. *Int J Cardiol* 2014; 180: 34–37.
- 7 Loscalzo J. Paradoxical embolism: clinical presentation, diagnostic strategies, and therapeutic options. *Am Heart J* 1986; 112: 141–145.
- 8 Murthy A, Shea M, Karnati PK, *et al.* Rare case of paradoxical embolism causing myocardial infarction: successfully aborted by aspirationalone. *J Cardiol* 2009; 54: 503–506.
- 9 Stortecky S, Costa BRD, Mattle HP, *et al.* Percutaneous closure of patent foramen ovale in patients with cryptogenic embolism: a network meta-analysis. *Eur Heart J* 2015; 36: 120–128.