



## Case report

# Prolonged survival after intraperitoneal interleukin-2 immunotherapy for recurrent ovarian cancer

David R. Minor<sup>a,\*</sup>, Samantha P. Moores<sup>b</sup>, John K. Chan<sup>c</sup><sup>a</sup> California Pacific Medical Center Research Institute, 2200 Webster St. Suite 511, San Francisco, CA 94115, United States<sup>b</sup> California Pacific Medical Center Research Institute, 2200 Webster St., San Francisco, CA 94115, United States<sup>c</sup> California Pacific Medical Center Research Institute/Palo Alto Medical Foundation, 3838 California St., San Francisco, CA 94118, United States

## 1. Introduction

In the last decade, there has been an explosion in the interest and usage of immunotherapy for cancer beginning with the demonstration that checkpoint inhibitors could produce prolonged treatment-free remissions in patients with advanced melanoma (Shadendorf et al., 2015). Immunotherapy with checkpoint inhibitors and as well as an oncolytic virus are now approved and available for the treatment of multiple advanced cancers. Although there is tremendous interest in using immunotherapy for ovarian cancer, success in this field seems limited at present (Drerup et al., 2015). In addition most efforts emphasize systemic immunotherapy, with little attention to the intraperitoneal route for immunotherapeutic agents. The authors felt the report of a patient with recurrent ovarian cancer successfully treated with intra-peritoneal interleukin-2 14 years ago would be of interest. This report was published with the approval of the Sutter Health institutional review board.

## 2. Case history

In 1992 a 62-year-old woman was found to have malignant ascites. The patient had a hysterectomy in 1970 for endometriosis and had also been treated for ductal carcinoma in situ of the breast in 1988. Her serum CA-125 level was elevated at 2002 U/ml (normal < 35 U/ml). She had an abdominal paracentesis that showed malignant cells consistent with adenocarcinoma. Her CT scan showed ascites and the suggestion of a mesenteric or omental mass. She received preoperative chemotherapy with cyclophosphamide and carboplatin for six cycles. The ascites disappeared after two cycles and her CA-125 levels decreased to 11.5 U/ml after four cycles (Fig. 1). She then had an interval cytoreductive surgery with removal of the omentum, ovaries, fallopian tubes, and other visible disease. She was found to have residual cancer in the omentum (10 × 5 × 1 cm) that invaded the colon, pelvic peritoneum, and part of the bladder with diffuse cancer nodules on the liver, right kidney, and diaphragm. Approximately 98% of the cancer-bulk was resected during surgery. The pathology showed adenocarcinoma in the peritoneum in addition to the surface of the left ovary.

Following surgery, she received intraperitoneal chemotherapy with etoposide and cisplatin for six cycles and intravenous carboplatin and paclitaxel for three cycles. Her cancer went into remission and she continued to take oral cyclophosphamide for an additional 12 months.

In 2001 she relapsed with abdominal pain and was hospitalized for bowel obstruction. Laparotomy showed an obstructed loop of ileum and small implants of carcinoma over the peritoneum and bowel with ascites. Findings from her CT scans showed recurrent ovarian cancer (Fig. 2, where the arrow points at fascial thickening in the paracolic gutter). The cytology of the peritoneal fluid was consistent with adenocarcinoma. Her CA-125 level had risen to 250 U/ml (Fig. 1). Following surgery, she received chemotherapy with paclitaxel and carboplatin for six cycles and carboplatin and docetaxel for three cycles. The CA-125 normalized after the initial chemotherapy cycle.

She was disease free for another two years but relapsed a second time in 2003. She had an elevated CA-125 level at 83 U/ml, but scans failed to show the site of recurrence. The patient was treated with four doses of docetaxel and carboplatin, and then 16 weekly doses of intraperitoneal aldesleukin (interleukin-2, IL-2) 900,000 units per week administered diluted in one liter D5W as described by Edwards (Edwards et al., 1997). She had grade 1 abdominal discomfort and fatigue with therapy but no severe toxicity with this intra-peritoneal immunotherapy. The dosage used for intraperitoneal interleukin-2 is < 1% of the usual intravenous high-dose interleukin-2 dosage. Following the immunotherapeutic treatment with IL-2, the patient has been disease free for 14 years, with repeat clinical exams and CA-125 levels showing no evidence of disease. Subsequent genetic testing has revealed the patient to carry a 2929 deletion in the BRCA2 gene.

## 3. Discussion

Recurrent ovarian cancer is traditionally felt to be a universally fatal disease. The authors feel that this patient's prolonged survival after a second relapse of her cancer was almost certainly due to the beneficial effect of the immunotherapy received, not the four additional cycles of chemotherapy in a patient with multiple relapses after previous chemotherapy. Her tumor demonstrated a favorable biology, with both a

\* Corresponding author.

E-mail addresses: [minord@sutterhealth.org](mailto:minord@sutterhealth.org) (D.R. Minor), [smoores8895@gmail.com](mailto:smoores8895@gmail.com) (S.P. Moores), [chanjohn@sutterhealth.org](mailto:chanjohn@sutterhealth.org) (J.K. Chan).

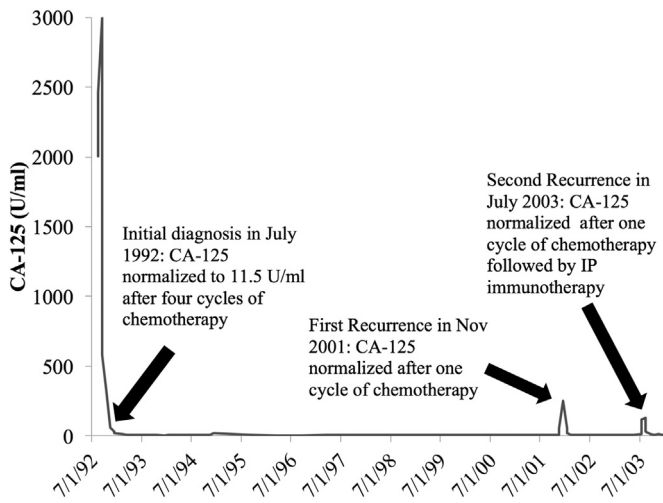


Fig. 1. Timeline showing elevation of CA-125 levels 1992–2003.

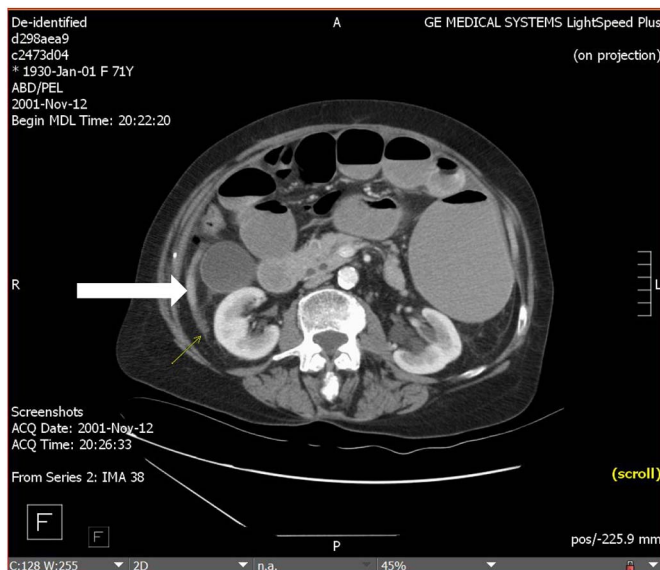


Fig. 2. CT scan showing bowel obstruction and peritoneal thickening due to recurrence.

long remission after her initial chemotherapy and a BRCA2 mutation. The patient's BRCA2 mutation explains the sensitivity of her tumor to platinum chemotherapy but it is unknown whether BRCA mutations

increase sensitivity to immunotherapy. In theory the higher mutational load in tumors with BRCA mutations should increase responsiveness to immunotherapy.

Aldesleukin (interleukin-2) was approved for the treatment of advanced renal cell cancer in 1992 and melanoma in 1998, but its use has been limited by the toxicity of the high doses required to obtain regressions in patients with advanced cancer when administered intravenously. Interleukin-2 causes activation, proliferation, and trafficking of T-cells and natural killer cells (Wei et al., 2007). When administered locally it may change a non-inflamed tumor into an inflamed tumor, perhaps thereby increasing sensitivity of that tumor to further immune attack. Intraperitoneal administration of interleukin-2 was pioneered by Edwards (Edwards et al., 1997; Vlad et al., 2010; Mantia-Smaldone et al., 2011) in a series of phase 1 and 2 trials that showed this treatment capable of causing regression of advanced ovarian cancer with reasonable toxicity. Phase 3 trials of intraperitoneal aldesleukin were never performed because of lack of funding. Currently over 40 trials of immunotherapy for ovarian cancer are underway using a variety of agents singly or in combination. We hope that this case report, demonstrating prolonged survival after a short course of intraperitoneal interleukin-2, will serve to strengthen interest in the immunotherapy of ovarian cancer in general and the use of local immunotherapy in particular.

#### Author's disclosures of potential conflict of interest

Dr. Minor reports honoraria from Merck and honoraria and other from BMS. Dr. Chan and Ms. Moores have no disclosures.

#### References

- Drerup, J.M., Liu, Y., Padron, A.S., et al., 2015. Immunotherapy for ovarian cancer. *Curr. Treat. Options Oncol.* 16 (1), 317. <http://dx.doi.org/10.1007/s11864-014>.
- Edwards, R.P., Gooding, W., Lembersky, B.C., et al., 1997. Comparison of toxicity and survival following intraperitoneal recombinant interleukin-2 for persistent ovarian cancer after platinum: twenty-four-hour versus 7-day infusion. *J. Clin. Oncol.* 15, 3399–3407.
- Mantia-Smaldone, G.M., Edwards, R.P., Vlad, A.M., 2011. Targeted treatment of recurrent platinum-resistant ovarian cancer: current and emerging therapies. *Cancer Manag. Res.* 3, 25–38.
- Shadendorf, D., Hodi, F.S., Roberts, C., et al., 2015. Pooled analysis of long-term survival data from phase II and phase III trials of ipilimumab in unresectable or metastatic melanoma. *J. Clin. Oncol.* 33, 1889–1894.
- Vlad, A.M., Budui, R.A., Lenzner, D.E., et al., 2010. A phase II trial of intraperitoneal interleukin-2 in patients with platinum-resistant or platinum-refractory ovarian cancer. *Cancer Immunol. Immunother.* 59, 293–301.
- Wei, S., Kryczek, L., Edwards, R.P., et al., 2007. Interleukin-2 administration alters the CD4 + FOXP3 + T-cell pool and tumor trafficking in patients with ovarian carcinoma. *Cancer Res.* 67, 7487–7494.