

Characterization of equine hyalocytes: their immunohistochemical properties, morphologies and distribution

Yuto SANO¹), Kazuya MATSUDA¹), Minoru OKAMOTO¹), Kazushige TAKEHANA²), Kazuko HIRAYAMA¹) and Hiroyuki TANIYAMA¹)*

¹)Department of Veterinary Pathology, School of Veterinary Medicine, Rakuno Gakuen University, Ebetsu, Hokkaido 069–8501, Japan

²)Department of Veterinary Microanatomy, School of Veterinary Medicine, Rakuno Gakuen University, Ebetsu, Hokkaido 069–8501, Japan

(Received 1 September 2015/Accepted 2 February 2016/Published online in J-STAGE 18 February 2016)

ABSTRACT. In horse, the characterizations of hyalocytes under the steady state are still unclear. Therefore, we investigated characterizations of hyalocytes in normal equine eyes by their immunohistochemical phenotype, histomorphology and distribution. Thirty-one eyes from 18 horses, divided into 4 groups (G) by age, were used: early (G1) and late gestation (G2) fetuses, 1- to 3-year-old (G3) and 8- to 24-year-old (G4) horses. Equine hyalocytes were histologically classified into 4 types, and they immunohistochemically expressed MHC II and CD163. Hyalocytes were detected on and/or around ciliary processes and pars plana in G2, G3 and G4, but were not located on retina and optic papilla. A significant increase in distribution was found between G2 and both G3 and G4, and the largest distribution was found at ciliary processes in these groups. Equine hyalocytes were characterized as residential ocular macrophage and MHC II antigen-bearing cell, accompanied by a pleomorphic appearance and located in the contiguous ciliary body. Our data provided characterizations of hyalocytes in normal equine eyes and may well contribute to improving the understanding of pathogenesis of equine ocular disease.

KEY WORDS: ciliary body, horse, hyalocytes, vitreous cortex

doi: 10.1292/jvms.15-0511; *J. Vet. Med. Sci.* 78(6): 937–942, 2016

The homogenous population of cells in the cortical layer of the vitreous body is known as “hyalocytes”. Hyalocytes are present in various animal species: human, experimental rodents, various domestic and companion animals, and avian species [1–3, 12, 22–24, 27–29]. Morphological [1–3, 22, 24, 27, 28], functional [1, 3, 23, 24, 27, 28] and immunohistochemical studies [12, 23, 24, 29], have suggested that hyalocytes are resident tissue macrophages, derived from bone marrow and differentiated in the vitreous cavity.

Hyalocytes of human, mouse, rabbit and chicken have been studied in spontaneously and experimentally produced ocular diseases. Their different responsibilities, such as participation in proliferative vitreous disease, an immunological role as antigen-presenting cells, and reactive activation in intraocular tissue damage and restoration processes with phagocytic function, have been reported [10, 11, 14–16, 24, 28, 29]. Although various ocular diseases in many domestic and companion animals including horses have been studied and reported [5, 7, 8, 20], there has not been any study of hyalocytes in relation to those ocular diseases.

In horses, the characterizations of hyalocytes under the steady state are still unclear. Therefore, the present study describes the immunohistochemical phenotype, histomorphology and distribution of hyalocytes in normal equine eyes, so

as to clarify the role of equine hyalocytes in ocular diseases.

MATERIALS AND METHODS

Animals: Thirty-one normal eyes from 18 horses were studied. The horses used in this study were submitted for necropsy to the Laboratory of Veterinary Pathology of Rakuno Gakuen University. The breeding distribution was thoroughbred. The age of the horses ranged from about 90 days of fetus gestation to 24 years of age. The sex distribution was 8 males and 10 females. There were a variety of clinical and pathological diagnoses, but ocular abnormalities were not observed in any horses. Horses used in this study were divided into 4 groups by ages: 6 eyes from early gestation fetuses (Group 1; G1), 6 eyes from late gestation (Group 2; G2) fetuses, 8 eyes from 1- to 3-year-old horses (Group 3; G3) and 11 eyes from 8- to 24-year-old (Group 4; G4) adult horses. The characterizations of horses used in this study and their divided groups are summarized in Table 1.

Tissue preparation: The fixative solution used in the present study was 10% neutral buffered formalin. For adequate fixation, appendages of the eyes were trimmed, and an incision of about 1 cm was made dorsal and sagittal ora serrata. The formalin was injected from the incision, and then, the eyes were immersed for 24 to 48 hr in formalin. Fixated eyes were divided into anterior and posterior ocular segments. The divided anterior ocular segment was cut into pieces of two or three 0.5–10 mm strips of tissue containing cornea, iris and ciliary body. The divided posterior ocular segment was also cut into two or three 0.5–10 mm strips of tissue containing retina and optic papilla. The tissues were embedded in paraffin wax following the immersion of graded ethyl alcohols and xylene. The embedded ocular tissues were sec-

CORRESPONDENCE TO: TANIYAMA, H., Department of Veterinary Pathology, School of Veterinary Medicine, Rakuno Gakuen University, 582 Bunkyo-dai-Midorimachi, Ebetsu, Hokkaido 069–8501, Japan. e-mail: taniyama@rakuno.ac.jp

©2016 The Japanese Society of Veterinary Science

This is an open-access article distributed under the terms of the Creative Commons Attribution Non-Commercial No Derivatives (by-nc-nd) License <<http://creativecommons.org/licenses/by-nc-nd/4.0/>>.

Table 1. Characterizations of horses used in the present study

Group	Eye	Sex	Age	Diagnosis
1	R/L	M	90 d	—
	R/L	F	90 d	—
	R/L	M	90 d	—
2	R/L	M	310 d	Difficult delivery and stillborn
	R/L	M	318 d	Difficult delivery and stillborn
	R/L	M	320 d	Difficult delivery and stillborn
3	R	F	1 y	Osteochondritis dissecans
	R/L	M	1 y	Wobbler syndrome
	L	M	1 y	Wobbler syndrome
	R/L	F	2 y	Wobbler syndrome
	R/L	M	2 y	Wobbler syndrome
4	L	F	8 y	Colonic torsion
	R/L	F	8 y	Rupture of adductor muscle
	R	F	9 y	Chronic laminitis
	L	F	9 y	Spinal cord injury
	R/L	F	15 y	Chronic laminitis
	R/L	F	24 y	Squamous cell carcinoma
	R/L	F	24 y	Mammary gland adenocarcinoma
	R/L	F	24 y	Mammary gland adenocarcinoma

R: right, L: left, M: male, F: female, d: day, y: year-old.

tioned at 5- μ m thickness, routinely stained with hematoxylin and eosin (HE) and then were submitted to light microscopic examination.

Immunohistochemical examinations: Indirect immunofluorescence studies were performed, and the primary antibodies against MHC class II (MHC II), CD163, CD3 and CD20 were used to recognize antigen-presenting cells, monocyte/macrophages and lymphocytes (T and B cells), respectively. Glial fibrillary acidic protein (GFAP) and pan-cytokeratin were also used to differentiate glial cells and epithelial cells, and the S100 protein was used as a functional marker for Ca²⁺ binding protein. The details of the primary antibodies and pretreatments for antigen retrieval are listed in Table 2. After pretreatment, the sections were incubated with 10% normal goat serum (Sigma Chemical Co., St. Louis, MO, U.S.A.) at 37°C for 30 min as a blocking step. Subsequently, the sections with primary antibodies were incubated at 4°C overnight in moist chambers. Following the primary incubation, the sections were reacted with Alexa Fluor 488-labeled goat anti-mouse IgG (Molecular Probes, Eugene, OR, U.S.A., diluted 1:200) or Alexa Fluor 546-labeled goat anti-rabbit IgG (Molecular Probes, diluted 1:200) at room temperature for 30 min in shading moist chambers. The sections were covered with water-soluble mounting medium and then were examined using a confocal microscope (C2; Nikon Instech Co., Ltd., Tokyo, Japan). With each immunofluorescence run, equine lymph node was used as a positive control for the detection of MHC II, CD163, CD3 and CD20. For the detection of GFAP and S100, and pan-cytokeratin, equine retina and epidermis were also used as positive controls, respectively.

Morphometry and statistical analyses: Hyalocytes from each separate ocular segment were manually counted: ciliary processes, pars plana, retina and optic papilla. Counting of

the cells was performed in five different fields under a HE stained microscope image using 400 \times high-power magnifications. The length of the vitreous cortex surface in each image was measured by using public software (Image J). The counted number of hyalocytes was presented as the average per 500 μ m. Statistical analyses were performed using specific software (Excel and Ekuseru-Toukei 2012; Social Survey Research Information Co., Ltd., Tokyo, Japan). To determine the distribution of hyalocytes among different ages, Kruskal-Wallis test and Scheffe's test were used for a priori and post hoc comparison, respectively. To determine the site of the greatest distribution, the number of sites in each group was compared using Mann-Whitney U test. For each analysis, $P < 0.01$ or $P < 0.05$ was considered to be significant.

RESULTS

Histological findings: All HE-stained equine ocular sections used in this study were assessed by microscopic examination, and no abnormalities were recognized. In G3 and 4, hyalocytes located in the vitreous cortex were significantly detected in ciliary processes (Fig. 1) and pars plana. The cells were pleomorphic and were classified according to their 4 different morphological features: round or oval nuclei and cytoplasm (type-1, Fig. 2a), round or oval nuclei and cytoplasm with short or long processes (type-2, Fig. 2b), flattened or elliptical nuclei and flattened or elongated-shaped cytoplasm (type-3, Fig. 2c), and flattened or elliptical nuclei and flattened or elongated-shaped cytoplasm with short or long processes (type-4, Fig. 2d). The cells of type-2 and type-4 were more detectable than those of type-1 and type-3. The free cells of type-1 and type-2 were detected around ciliary processes. In G2, fewer hyalocytes were randomly located in the vitreous cortex of ciliary processes and pars plana. The 4 different morphological features were also detected, but the cells of type-1 and type-3 were more detectable than type-2 and type-4. The free cells of type-1 and type-2 were also detected around ciliary processes. In G1, the cells were not detected on any part of vitreous cortex. Hyalocytes were not found in the vitreous cortex of retina and optic papilla in any groups.

Immunohistochemical findings: All 4 types of hyalocytes in G2, G3 and G4 expressed MHC II (Fig. 3a and 3b) and CD163 (Fig. 4a and 4b). The free cells around ciliary processes also expressed each antibody. These cells did not express CD3, CD20, GFAP, S100 and pan-cytokeratin. In G1, the expressed cell of all antibodies was not detected in the vitreous cortex.

Quantitative analyses: A significant number of hyalocytes were found in the vitreous cortex in G3 and G4 compared to G2, but it was not demonstrated between G3 and G4 (Fig. 5a and 5b). Additionally, the ciliary process was demonstrated as the largest site of hyalocyte distribution in G2, G3 and G4 (Fig. 6a–6c).

Table 2. Primary antibodies used in the present study for immunohistochemical examinations

Primary antibody	Type	Pretreatment	Dilution	Clone	Source
MHC II	MM	Autoclave	1:50	TAL.1B5	Dako
CD163	MM	Proteinase K	1:50	AM-3K	Trans Genic Inc.
CD3	RP	Microwave	1:5	—	Nichirei
CD20	RP	Not done	1:200	—	Thermo Scientific
GFAP	RP	Microwave	1:100	—	Dako
Pan-cytokeratin	MM	Autoclave	RU	AE1/AE3	Nichirei
S100	RP	Microwave	1:300	—	Dako

MM: mouse monoclonal, RP: rabbit polyclonal, RU: ready to use.

DISCUSSION

CD163 expression of equine hyalocytes was demonstrated in the present study. The expression of these cells indicated that they were resident ocular macrophages in the vitreous cavity. In mouse and rat, hyalocytes also expressed CD163, and the cells were demonstrated as resident ocular macrophages [23, 24]. CD163 is a type B crystalline-rich scavenger receptor that is selectively expressed in the cells belonging to the monocyte/macrophage lineage [9]. The expression is specifically identified in subpopulations of resident tissue macrophages in normal tissues, such as interfollicular and sinus macrophages in lymph nodes, red pulp macrophages in spleen, alveolar macrophages in lungs and Kupffer cells in liver [17, 18, 31]. Moreover, equine hyalocytes have a function in antigen presentation, as evidenced by MHC II expression. MHC II expression usually can be identified in normal monocyte/macrophages and lymphocytes, and MHC II antigen-bearing cells are considered to be antigen-presenting cells [26]. The negative immunoreactive results for CD3, CD20, GFAP and pan-cytokeratin suggested that equine hyalocytes are not differentiated to lymphocytes, glial cells and epithelial cells. S100 protein refers to Ca^{2+} binding proteins that have been found in a variety of cell types, and their localization has been found in potent antigen-presenting cells including dendritic and Langerhans cells [6, 25]. The localization of the S100 protein was not detected in equine hyalocytes of all groups in the present study. In human, the immunohistochemical expression of hyalocytes also provided strong evidence that hyalocytes belong to the monocyte/macrophage lineage. However, they antigenically differed from other tissue macrophages in that they express S100 protein and do not express CD68 [19]. The previous study suggested that hyalocytes may originate from a progenitor cell that diverged from the monocyte/macrophage lineage or that expression of these antigens is influenced by differences in the stage of differentiation and/or exposure to modulating signals from the microenvironment. Equine hyalocytes might have an immunohistochemical phenotype different from that of humans, and that property of those hyalocytes might be influenced by their differentiation and function, and by the different normal ocular microenvironment. Further investigation is needed to clarify the dissimilarity of S100 expression and the delineating functional characterization of equine hyalocytes.

By the histological examination of G2, G3 and G4, equine hyalocytes have been characterized as pleomorphic cells and have been further classified into 4 types in the present study. Hyalocytes in other animals have been known as pleomorphic cells *in vivo* and *in vitro* [1, 3, 12, 22, 27, 28]. The cell considered to be a type of macrophage in a past study resembled the type-1 cell in the present study, and the type-2 cell was considered to be a subtype of a macrophage [27]. In addition, a fibrocyte type was equivalent to type-3, and the type-4 cell was equivalent to the cell which was a subtype of a fibrocyte type [27]. The morphological differences of hyalocytes were described to reflect the different functions of the cells. Macrophage type was considered to consist of secretory cells responsible for production of hyaluronic acid [13], and fibrocyte type was considered to be the cell responsible for production of vitreous collagen [21]. However, the evidence of morphological differences in relation to hyalocyte function has not been adequately reproduced. In the present study, the emergence of type-2 and type-4 hyalocytes tended to be increased in adult horses, and therefore, the morphological changes during process formation were responsible for cell maturity or cell activation. In human and murine, hyalocytes have presented a myofibroblast appearance, which is potentially relevant to the pathogenesis of cicatricial contractions in proliferative vitreoretinopathies [14–16]. The present study expounded on the histomorphological variation of hyalocytes in normal equine eyes. These findings regarding equine hyalocytes may be helpful for the identification of morphological changes which are relevant to the ocular pathological conditions of horses.

In the present study, the site of equine hyalocyte distribution was demonstrated and characterized. The vitreous cortex of ciliary body was found to be a restricted site of distribution, and hyalocytes were not located in the vitreous cortex of retina and optic papilla. The free cells found around ciliary processes were also hyalocytes according to the findings from the histological and immunohistochemical examinations. The sites of hyalocyte distribution have been described previously using various animals [1, 12, 22, 27, 28]. Hyalocytes were located in the ciliary body of all animal species, but the localization of hyalocytes on retina was slightly different between animal species, depending on ocular structure. In guinea pig, which has an avascular retina similar to horse, hyalocytes were scattered on retina [22]. In chicken, the pecten oculi, which is known as a vascular

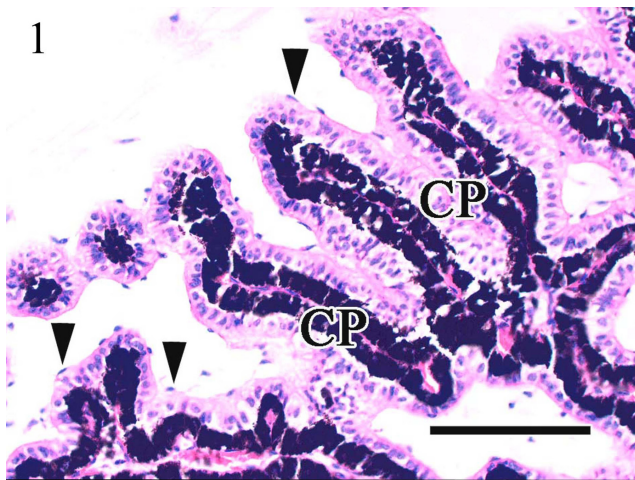


Fig. 1. Histological image of ciliary processes in an adult horse. Hyalocytes are randomly and contiguously located on or around ciliary processes (arrowheads). CP: ciliary process. HE. Bar=100 μ m.

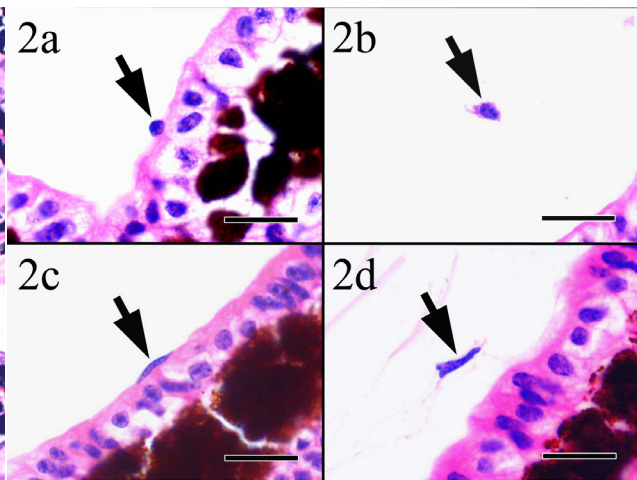


Fig. 2. Histological image of hyalocytes in an adult horse. Note the histomorphological appearance of hyalocytes, and each image shows that hyalocytes are classified into type-1 (a, arrow), type-2 (b, arrow), type-3 (c, arrow) and type-4 (d, arrow). HE. Bar=10 μ m.

structure situated over the head of the optic nerve in this species, was found to be the greatest site of hyalocyte distribution, although they were not distributed on the avascular retina [28]. In human, experimental rodents, and small and large animals, which have blood vessels throughout retina, hyalocytes were found on the retina. Especially in human, cow and cattle eyes, hyalocytes were accumulated linearly along the underlying blood vessels of the retina [1, 27]. In rabbit, hyalocytes have been detected inside the posterior chamber and also have been found on retina [12]. The free cells around the ciliary process were also found in rabbit and guinea pig, as they were in horses [12, 22]. In addition to finding of the site of distribution, the greatest distribution of equine hyalocytes was found at ciliary process. However, pars plana was the site with the greatest number of hyalocytes distributed in calves and cow [27], and has been found inside the vitreous in rabbit [12]. In horses, the results concerning distribution of hyalocytes indicate that ciliary process might play a key role in immigration of equine hyalocytes entering the vitreous via ciliary processes and/or where hyalocytes introduce antigen to the stromal cells.

The finding of equine hyalocyte distributions in G2 suggested that there was immigration of hyalocytes to vitreous cavity before birth. Their site of distribution in G2 was found to be similar to the site of distribution in G3 and G4. In addition, the immunohistochemical expression of hyalocytes in G2 indicated that hyalocytes in G2 had already been differentiated. A significant increase in the number of hyalocytes was detected between fetuses in late gestation and adult horses, and there was no significance between groups of adult horses. This result also indicated that the term from late gestation to after the birth is the time of highest activity for immigration to the vitreous. In a recent study with murine hyalocytes, an age-related increase in the number of subretinal hyalocytes had been described [4, 29, 30]. However, our

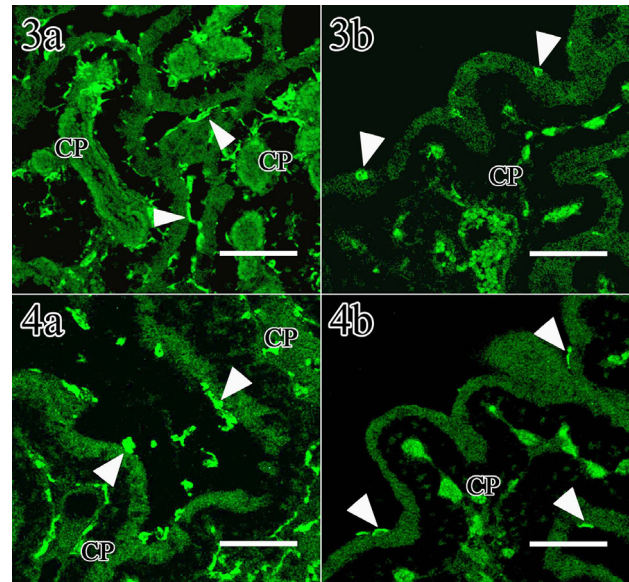


Fig. 3. Immunohistochemical image of the vitreous cortex of ciliary process in an adult horse (a) and a G2 fetus (b). Hyalocytes locating adjacent to ciliary processes express MHC II (arrowheads). CP: ciliary process. Bar=50 μ m.

Fig. 4. Immunohistochemical image of the vitreous cortex of ciliary process in an adult horse (a) and a G2 fetus (b). Hyalocytes locating adjacent to ciliary processes express CD163 (arrowheads). CP: ciliary process. Bar=50 μ m.

data did not provide an age-related increase in the number of equine hyalocytes. The factor that brings about an increased number of hyalocytes in normal eyes might vary depending on different ocular microenvironments and/or intraocular physiological conditions.

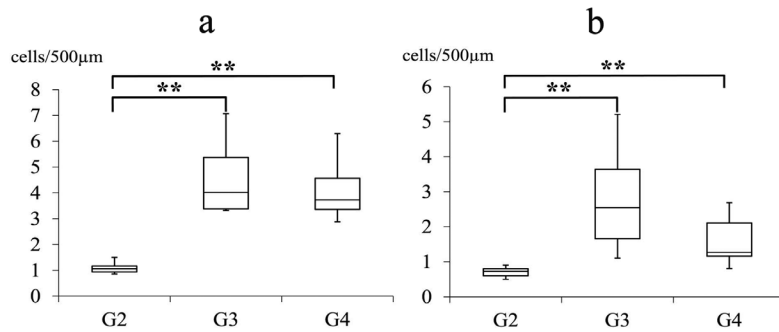


Fig. 5. Quantitative analysis of hyalocytes located on ciliary processes (a) and pars plana (b) of each group. Significance was exhibited between G2 and G3 ($P=0.0039$), G2 and G4 ($P=0.0060$) in ciliary processes, and between G2 and G3 ($P=0.0006$), G2 and G4 ($P=0.0257$) in pars plana, respectively. $**P<0.01$ or $*P<0.05$ was considered to be significant.

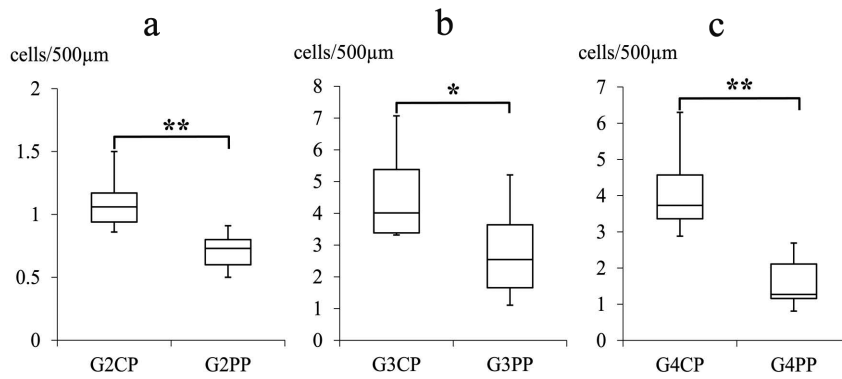


Fig. 6. Quantitative analysis of hyalocytes in each group between ciliary processes (CP) and pars plana (PP). Significant differences are exhibited between ciliary processes and pars plana in all groups. G2: $P=0.0065$ (a), G3: $P=0.0356$ (b), G4: $P=0.0001$ (c). $**P<0.01$ or $*P<0.05$ was considered to be significant.

The present study demonstrated the presence of hyalocytes in the equine vitreous cortex along with their immunohistochemical and histomorphological features and distributions, including the equine fetus. Hyalocytes in other animals including human have been studied under natural and experimental ocular diseases. In human and mouse, hyalocytes participated in proliferative vitreous diseases with myofibroblast appearance and transformation [14–16]. Under experimental ocular diseases, hyalocytes played a role as antigen-presenting cells in ocular immune diseases, responded to systemic LPS exposure and hyperglycemia with increasing their density and productive activation of VEGF in mouse, respectively [14, 24, 29], and represented reactive activations, photocoagulation and vitreous hemorrhage in rabbit [10, 11]. In chicken, hyalocytes exhibited increasing phagocytic activity in maintaining vitreous transparency through the clearance of cellular and extracellular debris, which was provoked by injection of bacteria [28]. Even though there have been many studies of pathological and immunological ocular conditions in domestic and companion

animals, hyalocytes in relation to ocular pathological conditions have not been studied. In horses, a variety of ocular diseases have also been reported, but functional contributions of hyalocytes for ocular diseases are still unclear. However, the presence of equine hyalocytes, made evident from MHC II and CD163 expression, is considered to have great potential to play an important role in treating pathological conditions, such as degenerative, proliferative and inflammatory origin, especially in the vitreous cavity. Equine hyalocytes might contribute to progression of the equine ocular pathological conditions as an antigen-presenting cell, and they might participate to those conditions through a phagocytic activity and productions of various physiological active substances. Further investigation is necessary to elucidate participation and actual functions of equine hyalocytes in particular individual ocular pathological condition.

REFERENCES

1. Balazs, E. A., Toth, L. Z., Eckl, E. A. and Mitchell, A. P. 1964.

- Studies on the structure of the vitreous body. XII. Cytological and histochemical studies on the cortical tissue layer. *Exp. Eye Res.* **3**: 57–71. [Medline] [CrossRef]
2. Bloom, G. D. and Balazs, E. A. 1965. An electron microscopic study of hyalocytes. *Exp. Eye Res.* **4**: 249–255. [Medline] [CrossRef]
 3. Boltz-Nitulescu, G., Grabner, G. and Förster, O. 1979. Macrophage-like properties of human hyalocytes. *Adv. Exp. Med. Biol.* **121B**: 223–228. [Medline]
 4. Chinnery, H. R., McLenachan, S., Humphries, T., Kezic, J. M., Chen, X., Ruitenber, M. J. and McMenamin, P. G. 2012. Accumulation of murine subretinal macrophages: effects of age, pigmentation and CX3CR1. *Neurobiol. Aging* **33**: 1769–1776. [Medline] [CrossRef]
 5. Davidson, M. G. 1991. Equine ophthalmology. pp. 576–610. In: *Veterinary Ophthalmology*, 2nd ed. (Gelatt, K. N. ed.), Lea and Febiger, Philadelphia.
 6. Donato, R. 1991. Perspectives in S-100 protein biology. Review article. *Cell Calcium* **12**: 713–726. [Medline] [CrossRef]
 7. Dubielzig, R. R., Ketring, K. L., McLellan, G. J. and Albert, D. M. 2010. The uvea. pp. 245–322. In: *Veterinary Ocular Pathology: A Comparative Review*, Elsevier, Philadelphia.
 8. Dubielzig, R. R., Ketring, K. L., McLellan, G. J. and Albert, D. M. 2010. The Retina. pp. 349–397. In: *Veterinary Ocular Pathology: A Comparative Review*, Elsevier, Philadelphia.
 9. Fabriek, B. O., Dijkstra, C. D. and van den Berg, T. K. 2005. The macrophage scavenger receptor CD163. *Immunobiology* **210**: 153–160. [Medline] [CrossRef]
 10. Forrester, J. V., Grierson, I. and Lee, W. R. 1980. Vitreous membrane formation after experimental vitreous haemorrhage. *Albrecht Von Graefes Arch. Klin. Exp. Ophthalmol.* **212**: 227–242. [Medline] [CrossRef]
 11. Gloor, B. P. 1969. Mitotic activity in the cortical vitreous cells (hyalocytes) after photocoagulation. *Invest. Ophthalmol.* **8**: 633–646. [Medline]
 12. Haddad, A. and André, J. C. 1998. Hyalocyte-like cells are more numerous in the posterior chamber than they are in the vitreous of the rabbit eye. *Exp. Eye Res.* **66**: 709–718. [Medline] [CrossRef]
 13. Jacobson, B. 1978. Biosynthesis of hyaluronic acid in the vitreous. V. Studies on a particulate hyalocyte glycosyl transferase. *Exp. Eye Res.* **27**: 247–258. [Medline] [CrossRef]
 14. Joshi, M., Agrawal, S. and Christoforidis, J. B. 2013. Inflammatory mechanisms of idiopathic epiretinal membrane formation. *Mediators Inflamm.* Article ID: 192582.
 15. Kawahara, S., Hata, Y., Kita, T., Arita, R., Miura, M., Nakao, S., Mochizuki, Y., Enaida, H., Kagimoto, T., Goto, Y., Hafezi-Moghadam, A. and Ishibashi, T. 2008. Potent inhibition of cicatricial contraction in proliferative vitreoretinal diseases by statins. *Diabetes* **57**: 2784–2793. [Medline] [CrossRef]
 16. Kohno, R. I., Hata, Y., Kawahara, S., Kita, T., Arita, R., Mochizuki, Y., Aiello, L. P. and Ishibashi, T. 2009. Possible contribution of hyalocytes to idiopathic epiretinal membrane formation and its contraction. *Br. J. Ophthalmol.* **93**: 1020–1026. [Medline] [CrossRef]
 17. Komohara, Y., Hirahara, J., Horikawa, T., Kawamura, K., Ki-yota, E., Sakashita, N., Araki, N. and Takeya, M. 2006. AM-3K, an anti-macrophage antibody, recognizes CD163, a molecule associated with an anti-inflammatory macrophage phenotype. *J. Histochem. Cytochem.* **54**: 763–771. [Medline] [CrossRef]
 18. Lau, S. K., Chu, P. G. and Weiss, L. M. 2004. CD163: a specific marker of macrophages in paraffin-embedded tissue samples. *Am. J. Clin. Pathol.* **122**: 794–801. [Medline] [CrossRef]
 19. Lazarus, H. S. and Hageman, G. S. 1994. *In situ* characterization of the human hyalocyte. *Arch. Ophthalmol.* **112**: 1356–1362. [Medline] [CrossRef]
 20. Miller, T. R. and Gelatt, K. N. 1991. Food animal ophthalmology. pp. 611–655. In: *Veterinary Ophthalmology*, 2nd ed. (Gelatt, K. N. ed.), Lea and Febiger, Philadelphia.
 21. Newsome, D. A., Linsenmayer, T. F. and Trelstad, R. L. 1976. Vitreous body collagen. Evidence for a dual origin from the neural retina and hyalocytes. *J. Cell Biol.* **71**: 59–67. [Medline] [CrossRef]
 22. Ogawa, K. 2002. Scanning electron microscopic study of hyalocytes in the guinea pig eye. *Arch. Histol. Cytol.* **65**: 263–268. [Medline] [CrossRef]
 23. Qiao, H., Hisatomi, T., Sonoda, K. H., Kura, S., Sassa, Y., Kinoshita, S., Nakamura, T., Sakamoto, T. and Ishibashi, T. 2005. The characterisation of hyalocytes: the origin, phenotype, and turnover. *Br. J. Ophthalmol.* **89**: 513–517. [Medline] [CrossRef]
 24. Sakamoto, T. 2003. [Cell biology of hyalocytes]. *Nippon Ganka Gakkai Zasshi* **107**: 866–882, discussion 883. [Medline]
 25. Shrestha, P., Muramatsu, Y., Kudeken, W., Mori, M., Takai, Y., Ilg, E. C., Schafer, B. W. and Heizmann, C. W. 1998. Localization of Ca²⁺-binding S100 proteins in epithelial tumours of the skin. *Virchows Arch.* **432**: 53–59. [Medline] [CrossRef]
 26. Snyder, P. W. 2012. Disease of immunology. pp. 242–288. In: *Pathologic Basis of Veterinary Disease*, 5th ed. (Zachary, J. F. and McGavin, M. D. eds.), Elsevier, St. Louis.
 27. Szirmai, J. A. and Balazs, E. A. 1958. Studies on the structure of the vitreous body. III. Cells in the cortical layer. *AMA Arch. Ophthalmol.* **59**: 34–48. [Medline] [CrossRef]
 28. Uehara, M., Imagawa, T. and Kitagawa, H. 1996. Morphological studies of the hyalocytes in the chicken eye: scanning electron microscopy and inflammatory response after the intravitreal injection of carbon particles. *J. Anat.* **188**: 661–669. [Medline]
 29. Vagaja, N. N., Chinnery, H. R., Binz, N., Kezic, J. M., Rakoczy, E. P. and McMenamin, P. G. 2012. Changes in murine hyalocytes are valuable early indicators of ocular disease. *Invest. Ophthalmol. Vis. Sci.* **53**: 1445–1451. [Medline] [CrossRef]
 30. Xu, H., Chen, M., Manivannan, A., Lois, N. and Forrester, J. V. 2008. Age-dependent accumulation of lipofuscin in perivascular and subretinal microglia in experimental mice. *Aging Cell* **7**: 58–68. [Medline] [CrossRef]
 31. Yamate, J., Yoshida, H., Tsukamoto, Y., Ide, M., Kuwamura, M., Ohashi, F., Miyamoto, T., Kotani, T., Sakuma, S. and Takeya, M. 2000. Distribution of cells immunopositive for AM-3K, a novel monoclonal antibody recognizing human macrophages, in normal and diseased tissues of dogs, cats, horses, cattle, pigs, and rabbits. *Vet. Pathol.* **37**: 168–176. [Medline] [CrossRef]