



ELSEVIER

Available online at [www.sciencedirect.com](http://www.sciencedirect.com)

ScienceDirect

journal homepage: [www.elsevier.com/locate/radcr](http://www.elsevier.com/locate/radcr)

## Case report

# Renal artery pseudoaneurysms post percutaneous nephrolithotomy: A case report <sup>☆,☆☆</sup>

Amal Rami<sup>a</sup>, Mariam Kassimi<sup>a,\*</sup>, Jihane Habi<sup>a</sup>, Hind Guerroum<sup>a</sup>,  
Meryem Sara Zineb Sabah<sup>b</sup>, Karim Belhaj<sup>c</sup>, Mohamed Mahi<sup>a</sup>

<sup>a</sup>Department of Radiology, Faculty of Medicine, Mohammed VI University of Health Sciences/Cheikh Khalifa International University Hospital, Casablanca, Morocco

<sup>b</sup>Department of Nephrology, Faculty of Medicine, Mohammed VI University of Health Sciences/Cheikh Khalifa International University Hospital, Casablanca, Morocco

<sup>c</sup>Department of Urology, Faculty of Medicine, Mohammed VI University of Health Sciences/Cheikh Khalifa International University Hospital, Casablanca, Morocco

## ARTICLE INFO

## Article history:

Received 9 December 2021

Accepted 19 December 2021

## Keywords:

Percutaneous nephrolithotomy

Endovascular embolization

Renal artery pseudoaneurysm

## ABSTRACT

Percutaneous Nephrolithotomy (PCNL) is a standard, safe and efficient method for removing large renal calculi. This pathology is associated with a risk of life-threatening Iatrogenic Renal Vascular Injuries, such as pseudoaneurysm (1%-3%). We report the case of a 49 old year male patient with Hematuria post PCNL for renal calculi. Computed tomography renal angiography was indicated which showed a pseudoaneurysm in the lower pole of the left kidney confirmed by digital subtraction angiography. Super selective endovascular embolization was successfully performed with conservation of the left-over vascularization of the kidney. No postoperative complications were seen. We aimed to report this case and to review the literature regarding endovascular management of kidney pseudoaneurysms after PCNL.

© 2021 The Authors. Published by Elsevier Inc. on behalf of University of Washington.

This is an open access article under the CC BY-NC-ND license

(<http://creativecommons.org/licenses/by-nc-nd/4.0/>)

## Introduction

Renal artery pseudoaneurysm (RAP) is a rare renal vascular abnormality that may occur as a complication after percutaneous nephrolithotomy. It can cause gross hematuria or even life-threatening hemorrhage, demanding efficient treatment by transarterial embolization. Super selective transarterial embolization procedure is a minimally invasive, safe, and

efficient procedure in the management of arterial hemorrhage due to PCNL.

## Case report

A 49-year-old male was addressed to the Department of Radiology for computed tomography of abdomen/pelvis for

<sup>☆</sup> Acknowledgments: This study was not funded.

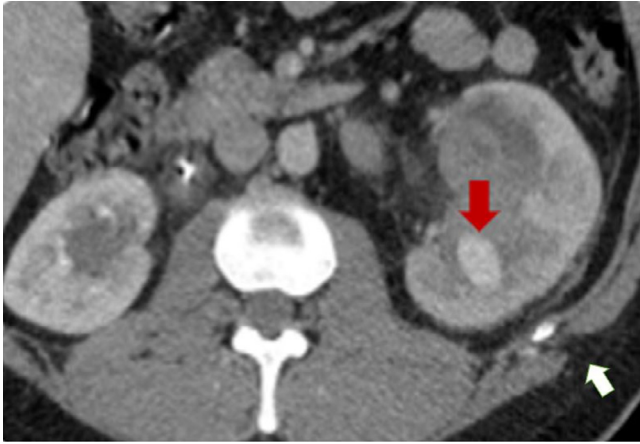
<sup>☆☆</sup> Competing interests: The authors declare that they have no conflict of interest.

\* Corresponding author.

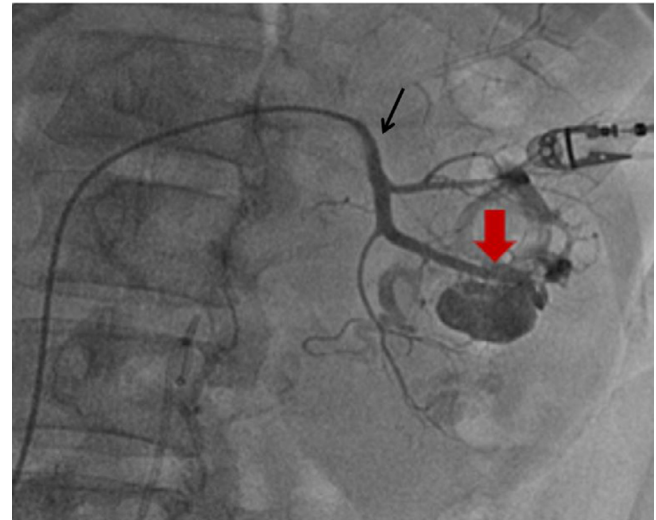
E-mail address: [M.kassimi91@hotmail.com](mailto:M.kassimi91@hotmail.com) (M. Kassimi).

<https://doi.org/10.1016/j.radcr.2021.12.036>

1930-0433/© 2021 The Authors. Published by Elsevier Inc. on behalf of University of Washington. This is an open access article under the CC BY-NC-ND license (<http://creativecommons.org/licenses/by-nc-nd/4.0/>)



**Fig. 1 – Enhanced computed tomography axial image showing the left lower renal pole pseudoaneurysm (Red arrow) at the percutaneous nephrolithotomy “track” (white arrow).**



**Fig. 2 – Digital subtraction angiography before embolization, with the 5F cobra catheter (Thin arrow) selectively positioned at the left renal artery, showing the pseudoaneurysm (Red arrow).**

intermittent hematuria happening 5 days after a standard PCNL of an inferior caliceal stone in the left kidney.

It shows a cystic hyperdense lesion approximately 2 × 3 cm in size in the lower pole of the left kidney highly suggestive of pseudoaneurysm (Fig. 1). Renal angiography was performed, which revealed that the pseudoaneurysm arises from the posterior segmental branch of the left renal (Fig. 1). No arteriovenous fistula was found. All other abdominopelvic organs added to the aorta and the other arteries were normal. No abnormalities were seen in clinical examination. Her blood pressure was 110/80 mm Hg and his laboratory tests were relatively within normal.

Digital subtraction angiography was indicated with Selective renal angiography, through left retrograde femoral access, using a 5F vascular sheath and a 5F cobra catheter. A coaxial microcatheter was advanced, allowing super-selective access to the feeding artery, confirming a pseudoaneurysm arising from the posterior segmental branch of the left renal artery. To perform embolization embolic agents were injected. Exclusion of the pseudoaneurysm was successfully reached with conservation of the remaining vascularization of the left kidney and no evident parenchymal loss (Figs. 2 and 3). The total procedure time was 1 hour. No immediate complications were noticed and hematuria disappeared 4 days after. The patient stayed asymptomatic, and no recurrence was found at two months of CT follow-up.

## Discussion

Renal artery pseudoaneurysm (RAP) is an unusual condition that may occur as a complication associated with percutaneous nephrolithotomy. Hematuria is the most common symptom associated with RAP [1]. It results from trauma to either the anterior or posterior segmental arteries, more than the smaller peripheral interlobular arteries, which are bordered by dense parenchyma and therefore safe to tamponade

with the nephrostomy tube [2]. This is observed in our case as the lesion arises from the segmental arteries.

Noninvasive diagnostic modalities, mainly CT angiography, should be indicated in the initial examination. It has the advantage to show the entire urinary tract and it is the modality of choice for follow-up. RAP is best seen on the arterial phase, as it appears as a focal lesion with a high density similar to that of the adjacent arterial vessels. However, Digital subtraction angiography remains the gold standard when PCNL complicates with bleeding that cannot be managed with conservative treatment. It should be performed both as a diagnostic and therapeutic method [3].

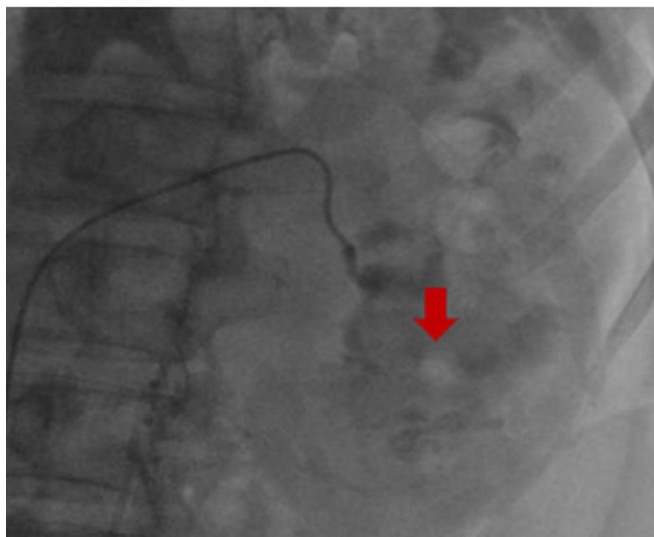
The most common angiographic results associated with hemorrhage after PCNL are arterial pseudoaneurysms and/or AFV [4].

Angiographic embolization is the treatment of choice for RAP due to its minimally invasive and absence of parenchymal loss [5].

It starts with a renal angiogram through a transfemoral approach. Selective embolization of renal artery branches can be achieved by using microcatheters inserted coaxially in a guidewire minimizing loss of viable tissue. Different embolic agents are accessible to treat vascular injuries of PCNL counting coils, particulate agents, and liquid agents. They can be used either alone or combined [6]. The choice should be based on the patient's vascular anatomy and the pathologic process.

In our patient, we used liquid agents (eg, Onyx) due to their availability in our institution.

Many case series and reports have shown that coil embolization is an effective method for treating renal pseudoaneurysms post PCNL with high success rates. Therefore, Onyx can be administered in a slower, accurate, and more commanded way than other embolic agents, reducing remarkably the risk of ischemic complications [7,8]. Nevertheless, the purpose is to ensure adequate occlusion.



**Fig. 3 – Digital subtraction angiography after embolization, that shows Onyx (red arrow) at the distal extremity of the feeding artery.**

In conclusion, Superselective endovascular embolization is a relevant technic that allows early diagnosis and treatment of significant post-PCNL pseudoaneurysms and should be considered as a first-line management tool.

### Key points

- PCNL is currently the modality of choice for removal of large renal calculi.
- Renal artery pseudoaneurysm (RAP) is a rare renal vascular injury that occurs after PCNL.
- Super selective endovascular embolization is an effective, minimally invasive and relatively easy technic, it should be considered as a first-line in the management of renal pseudoaneurysms post PCNL.

### Availability of data and material

Data available within the article

### Code availability

Not Applicable.

### Patient consent

Patient consent has been obtained.

### REFERENCES

- [1] Venkateswarlu J, Kumar MS, Babu RP, Abkari A. Endovascular management of iatrogenic renal vascular injuries complicating percutaneous nephrolithotomy: role of renal angiography and embolization; an analysis of 159 cases. *Indian J Radiol Imaging* 2017;27(3):293–7 PMID: 29089676; PMCID: PMC5644321. doi:10.4103/ijri.IJRI\_54\_17.
- [2] Al Simões Ferreira, Gomes FV, Bilhim T, É Coimbra. Embolization with Onyx® of an arterial pseudoaneurysm with an arteriovenous fistula complicating a percutaneous nephrolithotomy: a case report and review of literature. *Urol Ann* 2018;10(2):225–8. doi:10.4103/UA.UA\_29\_17.
- [3] Kervancioglu S, Gelebek Yilmaz F, Erturhan S. Endovascular management of vascular complications after percutaneous nephrolithotomy. *Vasa* 2014;43:45964.
- [4] Loffroy R, Rao P, Kwak BK, Ota S, De Lin M, Liapi E, Geschwind JF. Transcatheter arterial embolization in patients with kidney diseases: an overview of the technical aspects and clinical indications. *Korean J Radiol* 2010;11(3):257–68 Epub 2010 Apr 29. doi:10.3348/kjr.2010.11.3.257.
- [5] Chataut D, Maharjan S, Ghimire R, Panta O. A rare case of spontaneous asymptomatic renal artery pseudoaneurysm treated with coil embolization: a case report. *J Clin Interv Radiol ISVIR* 2017;01:056–60. doi:10.1055/s-0036-1597841.
- [6] Loffroy R, Rao P, Kwak B-K, Ota S, De lin M, Liapi E, et al. Transcatheter arterial embolization in patients with kidney diseases: an overview of the technical aspects and clinical indications. *Korean J Radiol* 2010;11(3):257–68.
- [7] Irwine C, Kay D, Kirsch D, Milburn JM. Renal artery embolization for the treatment of renal artery pseudoaneurysm following partial nephrectomy. *Ochsner J* 2013;13(2):259–63.
- [8] Jinga V, Dorobat B, Youssef S, Radavoi GD, Braticević B, Filipoiu F, Balgradean M. Transarterial embolization of renal vascular lesions after percutaneous nephrolithotomy. *Chirurgia (Bucur)* 2013;108(4):521–9 PMID: 23958096.