

## ORIGINAL ARTICLE

# Efficacy and adequacy of conventional transbronchial needle aspiration of IASLC stations 4R, 4L and 7 using endobronchial landmarks provided by the Wang nodal mapping system in the staging of lung cancer

Qinghua Liu<sup>1</sup>, Songyan Han<sup>2</sup>, Sixto Arias<sup>3</sup>, J Francis Turner<sup>4</sup>, Hans Lee<sup>3</sup>, Robert Browning<sup>5</sup> & Ko-Pen Wang<sup>3</sup>

1 Department of Respiratory Medicine, Shandong Provincial Hospital Affiliated to Shandong University, Jinan, China

2 Department of Respiratory Diseases, Shanxi Cancer Hospital, Taiyuan, China

3 Interventional Pulmonology, Division of Pulmonary Medicine and Critical Care, Johns Hopkins University, School of Medicine, Baltimore, Maryland, USA

4 Division of Pulmonary and Critical Care Medicine, University of Tennessee Graduate School of Medicine, Knoxville, Tennessee, USA

5 Interventional Pulmonology, Walter Reed National Military Medical Center, Bethesda, Maryland, USA

## Keywords

Bronchoscopy; EBUS; lung cancer; transbronchial needle aspiration.

## Correspondence

Ko-Pen Wang, Interventional Pulmonology, Division of Pulmonary Medicine and Critical Care, Johns Hopkins University, School of Medicine, 1800 Orleans Street, Suite 7125L, Baltimore, MD 21287, USA.  
Tel: +1 443 691 7696  
Fax: +1 410 630 7491  
Email: kwang7@jhmi.edu

Received: 2 April 2015;

Accepted: 1 June 2015.

doi: 10.1111/1759-7714.12288

Thoracic Cancer 7 (2016) 118–122

## Abstract

**Background:** The role of transbronchial needle aspiration (TBNA) in the diagnosis and staging of lung cancer has been well established. Recently, the efficacy of conventional TBNA in the staging of lung cancer has been enhanced by the use of endobronchial ultrasound (EBUS)-TBNA. Our study sought to evaluate the adequacy of TBNA of International Association for the Study of Lung Cancer (IASLC) stations 4R, 4L and 7 using endobronchial landmarks provided by the Wang nodal mapping system in the staging of lung cancer.

**Methods:** We retrospectively analyzed all bronchoscopic cases with conventional TBNA punctures positive for malignancy at our institution from 1 January to 31 October 2014. The endobronchial puncture site was guided by the Wang nodal mapping system. The Wang stations were correlated with the IASLC lymph node map. No endobronchial ultrasound or rapid on-site evaluation was used. Pathological analysis included cytological and histological examination.

**Results:** Diagnosis by histological analysis was obtained in 115 (55.3%) out of 208 puncture sites. The metastatic lymph nodes were distributed at IASLC stations 4R (W1, 3, 5) 46.6%, 7 (W2, 8, 10) 19.7%, 4L (W4, 6) 11.5%, 11R (W7, W9) 11.1% 11L (W11) 9.6%, 2R (high station W3) 0.5%, and the proximal portion of station 8 (station W10 beyond the middle lobe orifice) 1%. No complications were observed.

**Conclusion:** IASLC station 4R (W1, 3, 5), 7 (W2, 8, 10) and 4L (W4, 6) are adequate for the staging of lung cancer.

## Introduction

Conventional transbronchial needle aspiration (C-TBNA) has been utilized for more than 30 years and has a well-established role in the diagnosis and staging of lung cancer.<sup>1–4</sup> However, the variable sensitivity (37.0–94.7%) among operators has limited the adoption of this procedure for lung cancer staging.<sup>5–7</sup> In contrast, endobronchial ultrasound (EBUS)-TBNA has been demonstrated to be more reliable and has been recommended to aid the staging of lung cancer in recent years.<sup>8,9</sup> Nonetheless, C-TBNA remains a popular

procedure in countries with limited access to EBUS technologies. Improved methodologies of C-TBNA need to be implemented to improve its sensitivity, making it more acceptable for the general pulmonologist.<sup>4,10–12</sup>

Many factors may alter the sensitivity of TBNA, such as the experience of the bronchoscopists, which include technique skill and knowledge of the anatomy to appropriately selecting the puncture site.<sup>4,5,10</sup> The International Association for the Study of Lung Cancer (IASLC) and the Wang lymph node (LN) mapping system are crucial for the selection of the correct puncture site for TBNA and the staging of lung

**Table 1** Positive puncture sites and relationship between Wang and IASLC maps

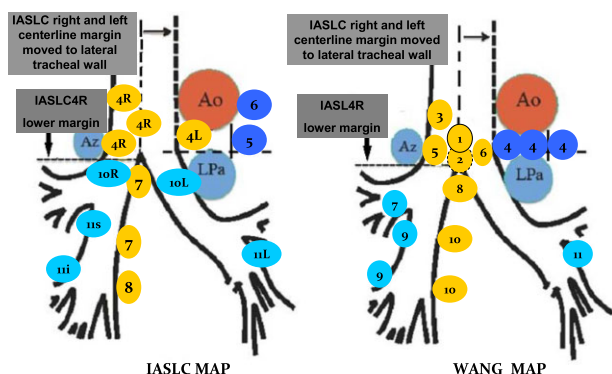
Station	Wang station	Number	Stage of LN	N (%)
7	2, 8, 10	41	N2	41 (19.7)
8	10	2	N2	2 (1)
2R	3 (high W3)	1	N2	1 (0.5)
4R	1, 3, 5	97	N2	97 (46.6)
4L	4, 6	24	N2	24 (11.5)
11L	11	20	N1	20 (9.6)
11R	7, 9	23	N1	23 (11.1)

IASLC, International Association of the Study of Lung Cancer; LN, lymph node.

cancer.<sup>3,13–15</sup> The aim of this study is to illustrate the efficacy and adequacy of C-TBNA using endobronchial landmarks for sampling of lymphadenopathy in the staging of lung cancer.

## Material and methods

We retrospectively analyzed cases with C-TBNA punctures positive for malignancy from the Department of Respiratory Diseases, Shanxi Cancer Hospital, from bronchoscopies performed during the period 1 January to 31 October 2014. Only patients undergoing bronchoscopy for diagnosis and staging of lung cancer that had at least one diagnostic C-TBNA sample during the procedure were included in the study. The C-TBNA puncture sites were guided by the Wang map, computed tomography (CT) images, and endobronchial anatomical landmarks, and correlated to the IASLC nodal stations.<sup>3</sup> Correlation of the Wang and IASLC maps were performed as described in our previous work (Table 1 and Fig 1).<sup>16</sup> Eleven stations in the Wang map were divided into three groups designated as right LN (station W1, 3, 5, 7, 9), middle mediastinal LN (station W2, 8, 10) and left LN (station W4, 6, 11). Station W4 (A-P window) was classified



**Figure 1** International Association for the Study of Lung Cancer (IASLC) and Wang maps. Ao, aortic arch; Az, azygos arch; Lpa, left pulmonary artery.

as inner, middle, and outer windows, according to the distance from the LNs to the left edge of the trachea and ligamentum arteriosum. Except for station W7, 9, and 11, all others were considered mediastinal LNs based on their location and relationship with the IASLC map. C-TBNA for mediastinal staging was carried out according to institutional protocol (based on published criteria) in patients fulfilling one or more of the following criteria: (i) central tumor; (ii) enlarged (>10 mm) mediastinal LNs on CT; or (iii) positron emission tomography (PET)-positive mediastinal LNs.<sup>17</sup> EBUS and rapid on-site cytology evaluation were not available for these cases. All examinations were performed under topical anesthesia only. Cytologic needles (model 122; ConMed, Utica, NY, USA) were preferentially used during most procedures. Histologic needles (model 319; ConMed,) were occasionally used. Two or more aspirations were taken from all LN stations. Aspirated material was expelled onto glass slides and smeared for cytological examination, with or without core specimen and cellblock for histology.

## Statistical analysis

Statistical analysis was performed using the Statistical Package for the Social Sciences v 21.0 (SPSS Inc., Chicago, IL, USA). Continuous variables were represented as mean and categorical variables and summarized as a percentage of the study population.

## Results

A total of 208 C-TBNA punctures were positive for malignancy diagnosed by cytology or histology; 165 of these (79.3%) were considered to be mediastinal LNs according to IASLC and Wang definitions.

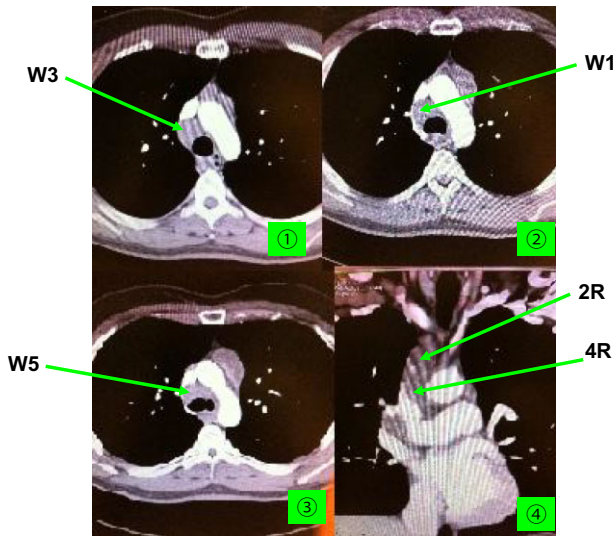
Core tissues and/or cellblock histologic diagnosis were obtained in 115 of 208 (55.3%) C-TBNA punctures positive for malignancy. The other 93 puncture sites were all diagnosed by cytology.

A total of 97 (46.6%) LNs were positive in station 4R (W1, 3, 5) (Fig 2), 41 (19.7%) in station 7 (W2, 8, 10) (Fig 3), 24 (11.5%) in station 4L (W4, 6) (Fig 4), 23 (11.1%) in station 11R (W7, 9), 20 (9.6%) in station 11L (W11) (Fig 1), 1 (0.5%) in station 2R (the high station W3), and 2 (1%) in the proximal portion of station 8 (distal portion of station W10) (Table 1).

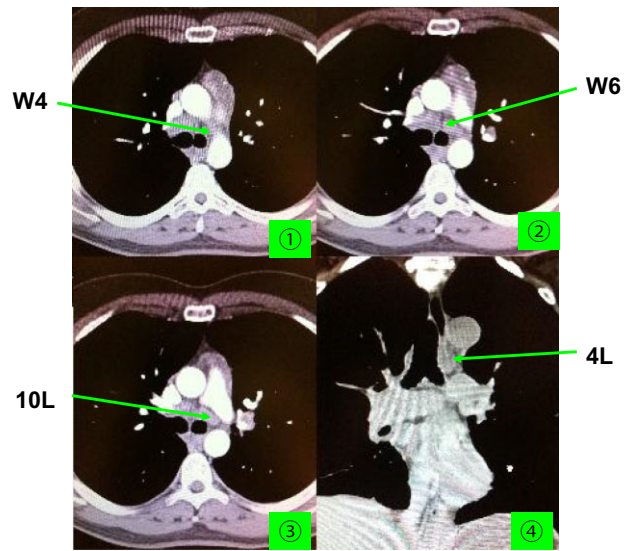
No complications were reported in any of the cases.

## Discussion

Whether utilizing C-TBNA or EBUS-TBNA, adequacy and efficacy are extremely important for the staging of lung cancer. Many recent reports have reported successful results using EBUS-TBNA for the staging of lung cancer.<sup>8,9,18</sup> EBUS



**Figure 2** Right tracheobronchial mediastinal lymph nodes station 4R (W1,W3,W5).



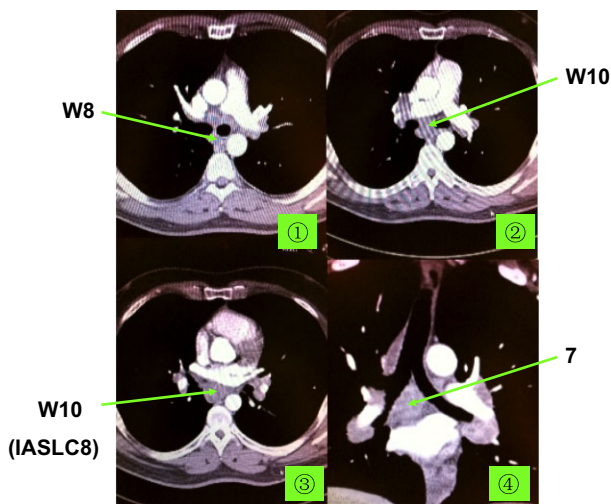
**Figure 4** Left tracheobronchial mediastinal lymph node station 4L (W4, W6).

equipment is not as readily available as conventional bronchoscopes in many medical centers because of its high cost. The efficacy and adequacy of C-TBNA, a basic technique for any bronchoscopist, has been demonstrated to benefit patients.<sup>19-21</sup> Our results showed that nearly all of the malignant mediastinal or hilar LNs for the staging of lung cancer could be obtained by utilizing the 11 stations in the Wang map to sample IASLC stations bilaterally at 4, 7, 8, 10, 11, and 12. IASLC stations 5 and 6 are not usually accessible by TBNA (Fig 5). Moreover, core tissues and a histology diagnosis were obtained in 115 (55.3%) cases, even with cytological needles preferentially used. No complications were demonstrated.

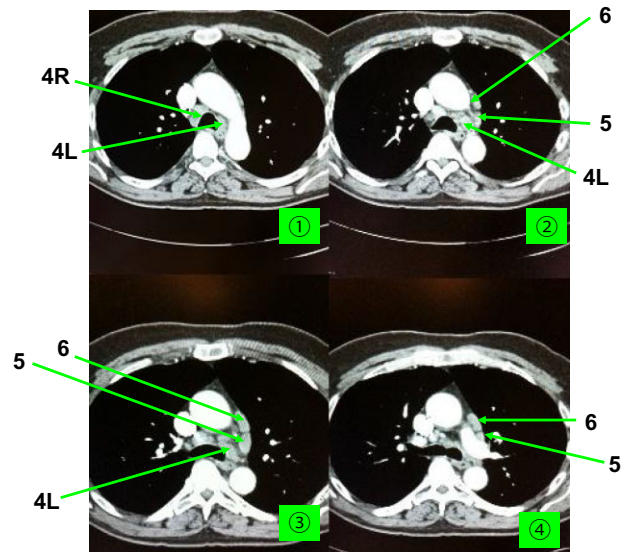
Therefore, we conclude that C-TBNA can be adequately utilized in the staging of lung cancer.

Tucakovic and Wang reported the adequacy and efficacy of C-TBNA.<sup>22</sup> Rong *et al.* also found that TBNA puncture sites at the spaces equivalent to IASLC zone 2, 3, and 4 using Wang landmarks were highly accurate when later confirmed with EBUS.<sup>23</sup>

Nearly 80% of the LN metastases were distributed at IASLC station 4R (W1, 3, 5), 4L (W4, 6) and 7 (W2, 8, 10), which were considered mediastinal LNs. Of 208 cases, only



**Figure 3** Central mediastinal lymph node station 7 (W2, W8, W10).



**Figure 5** Right and left tracheobronchial mediastinal lymph node stations 4R, 4L, 5, and 6 (W1,W3,W5,W4,W6).

one was located at station 2 and two were located at the beginning of station 8. As mentioned above, IASLC station 2R is known as high station W3, and the proximal part of IASLC station 8 is the same as the caudal part of station W10. In fact, lymphadenopathy of station 2 without station 4 or the involvement of station 8 without station 7 is very rare, and in our study, could all be obtained with C-TBNA. By Wang LN map definition, the subcarina LN can extend below the right middle lobe opening, which by IASLC definition is the proximal portion of station 8 LN. In two cases, TBNA was performed at the level of the terminal portion of the bronchus intermedius to sample the LN below this level (proximal portion of IASLC level 8 but below the distal margin for IASLC level 7). Malignant involvement of the LNs in the outer window of station W4 (station 5), without the inner or middle window (station 4L), is also very rare in clinical practice (Fig 5). Special needles or techniques can be used to help in the diagnosis of lymphadenopathy in station 5 (outer window of station W4), if necessary.<sup>24</sup> In the staging of mediastinal LNs in lung cancer, station 4R (W1,3,5), 4L (W4,6), and 7 (W2,8,10) are usually adequate in most cases.

Exactly how to achieve consistent and efficacious results with C-TBNA for the staging of lung cancer needs to be discussed. First, how to find a correct puncture site for TBNA without EBUS is crucial. A clear understanding of the anatomy of intrathoracic LNs in relation to tracheobronchial landmarks plays an important role. This relationship may be enhanced by a careful pre-procedure review of available imaging, such as a CT scan. Second, the relationship between IASLC and Wang maps should also be emphasized in guiding selection to an ideal puncture site in the staging of lung cancer.

Although these hopeful and exciting results have suggested the efficacy and adequacy of C-TBNA of mediastinal and hilar lymphadenopathy for the staging of lung cancer, this study is limited by the retrospective design and the skills of the operator. A prospective study is needed to confirm these results.

## Conclusion

In conclusion, C-TBNA is an effective, adequate, and safe procedure. Clear understanding of the anatomy of intrathoracic LNs in relation to endobronchial landmarks, as defined by the Wang map, is the key step for successful staging of lung cancer. Station 4R (W1, 3, 5), 4L (W4, 6), and 7 (W2, 8, 10) are usually effective and adequate for the staging of lung cancer by TBNA.

## Disclosure

No authors report any conflict of interest.

## References

- Bonifazi M, Zuccatosta L, Trisolini R, Moja L, Gasparini S. Transbronchial needle aspiration: A systematic review on predictors of a successful aspirate. *Respiration* 2013; **86**: 123–34.
- Wang KP, Brower R, Haponik EF, Siegelman S. Flexible transbronchial needle aspiration for staging of bronchogenic carcinoma. *Chest* 1983; **84**: 571–6.
- Wang KP. Staging of bronchogenic carcinoma by bronchoscopy. *Chest* 1994; **106**: 588–93.
- Zhang Y, Wang KP. Evolution of transbronchial needle aspiration – a hybrid method. *J Thorac Dis* 2013; **5**: 234–9.
- Agarwal R, Aggarwal AN, Gupta D. Efficacy and safety of conventional transbronchial needle aspiration in sarcoidosis: A systematic review and meta-analysis. *Respir Care* 2013; **58**: 683–93.
- Schenk DA, Chambers SL, Derdak S et al. Comparison of the Wang 19-gauge and 22-gauge needles in the mediastinal staging of lung cancer. *Am Rev Respir Dis* 1993; **147**: 1251–8.
- Mohamed SAA, Ahmed Y, Hussein K Abd El-Aziz N, Gamal Y. Diagnostic utility of transbronchial needle aspiration in malignant endobronchial lesions: Relevance to lesions' characteristics. *J Respir Med* 2013; **2013**.
- Figueiredo VR, Jacomelli M, Rodrigues AJ, Canzian M, Cardoso PF, Jatene FB. Current status and clinical applicability of endobronchial ultrasound-guided transbronchial needle aspiration. *J Bras Pneumol* 2013; **39**: 226–37.
- VanderLaan PA, Wang HH, Majid A, Folch E. Endobronchial ultrasound-guided transbronchial needle aspiration (EBUS-TBNA): An overview and update for the cytopathologist. *Cancer Cytopathol* 2014; **122**: 561–76.
- Xia Y, Wang KP. Transbronchial needle aspiration: Where are we now? *J Thorac Dis* 2013; **5**: 678–82.
- Dasgupta A, Mehta AC. Transbronchial needle aspiration. An underused diagnostic technique. *Clin Chest Med* 1999; **20**: 39–51.
- Wang KP. Continued efforts to improve the sensitivity of transbronchial needle aspiration. *Chest* 1998; **114**: 4–5.
- Rusch VW, Asamura H, Watanabe H, Giroux DJ, Rami-Porta R, Goldstraw P. The IASLC lung cancer staging project: A proposal for a new international lymph node map in the forthcoming seventh edition of the TNM classification for lung cancer. *J Thorac Oncol* 2009; **4**: 568–77.
- Jawad H, Sirajuddin A, Chung JH. Review of the International Association for the Study of Lung Cancer lymph node classification system: Localization of lymph node stations on CT imaging. *Clin Chest Med* 2013; **34**: 353–63.
- Wang KP, Browning R. Transbronchial needle aspiration with or without endobronchial ultrasound. *Thorac Cancer* 2010; **1**: 87–93.
- Xia Y, Ma Y, Arias S, Lee H, Wang KP. Utilization of the International Association for the Study of Lung Cancer and

- Wang's nodal map for the identification of mediastinum and hilar lymph nodes. *Thorac Cancer* 2015; **6**: 464–8.
- 17 Omark Petersen H, Eckardt J, Hakami A, Olsen KE, Jorgensen OD. The value of mediastinal staging with endobronchial ultrasound-guided transbronchial needle aspiration in patients with lung cancer. *Eur J Cardiothorac Surg* 2009; **36**: 465–8.
  - 18 Zhang J, Ren Y. Endobronchial ultrasound-guided transbronchial needle aspiration: A maturing technique. *J Thorac Dis* 2014; **6**: 1665–7.
  - 19 Medford AR, Bennett JA, Free CM, Agrawal S. Endobronchial ultrasound guided transbronchial needle aspiration. *Postgrad Med J* 2010; **86**: 106–15.
  - 20 Medford AR. Endobronchial ultrasound-guided versus conventional transbronchial needle aspiration: Time to re-evaluate the relationship? *J Thorac Dis* 2014; **6**: 411–5.
  - 21 Jiang J, Browning R, Lechtzin N, Huang J, Terry P, Wang KP. TBNA with and without EBUS: A comparative efficacy study for the diagnosis and staging of lung cancer. *J Thorac Dis* 2014; **6**: 416–20.
  - 22 Tucakovic M, Wang KP. Use of Lymph node map for transbronchial needle aspiration of mediastinal lymph nodes. Proceedings of the 12th World Congress for Bronchology and Bronchoesophagology, June 16–19, 2002, Boston, Massachusetts.
  - 23 Rong F, Xiao SH, Liu J, Li YX, Mai HY, Lu YS. [A comparative research on the conventional transbronchial needle aspiration and endobronchial ultrasound-guided transbronchial needle aspiration for the diagnosis of mediastinum lesions]. *Zhonghua Jie He He Hu Xi Za Zhi* 2011; **34**: 120–2. (In Chinese.)
  - 24 Kim D, Browning RF, Wang K-P. Transbronchial needle aspiration (TBNA) using an extended length needle under fluoroscopic guidance for accessing the lateral aortopulmonary window (A-P window). *Chest* 2008; **134** (4\_Meeting Abstracts): c25002–c25002.