

Oncology

Metastatic breast cancer masquerading as a renal malignancy: A literature review and case report



Brent Gilbert^{a,b,*}, Leonardo Zandavalli Cordova^a, Anthony Eaton^{a,c}

^a Royal Hobart Hospital, Department of Urology, Hobart, Tasmania, Australia

^b University of Queensland, School of Medicine, Herston, Queensland, Australia

^c Calvary Hospital, Hobart, Tasmania, Australia

ABSTRACT

Breast cancer is the most common non-cutaneous cancer affecting women. Despite this high incidence, few cases of non-disseminated breast cancer metastasizing to the kidneys have been reported. This report documents a 78-year-old female in remission for twelve years following lobular breast cancer treatment who presents with haematuria associated with a right renal pelvis lesion. Histological analysis revealed this lesion was metastatic lobular breast carcinoma.

A systematic review yielded 15 documented cases of non-disseminated breast cancer metastasizing to the kidneys. This systematic review represents that most comprehensive review of the clinical presentation, pathology, prognosis and management of this rare presentation.

Introduction

Metastatic urinary tract lesions usually arise when there is multi-organ involvement and seldom present as a solitary lesion.¹ Carcinoma of the lung, colon, stomach and lymphomas commonly metastasise to kidneys.²

Breast cancer has two predominant histological variants invasive ductal carcinoma (IDC) and invasive lobular carcinoma (ILC). Both invade lymph nodes of the axilla and chest via lymphatics and can metastasise to distant sites such as bone, liver, lung and brain. Despite being the second most common cause of female cancer related deaths; breast cancer rarely metastasises to the kidney.³

Case report

An otherwise healthy 66-year-old female smoker underwent a left lumpectomy for a lesion found during routine screening mammogram. Histological analysis confirmed ILC with oestrogen receptor positive (ER+) (70%), progesterone receptor positive (PG+) (50%) and human epidermal receptor-2 (HER2) negative. Subsequent left axillary clearance found a single positive node. The patient underwent radiotherapy and was started on Tamoxifen. The patient remained disease free for the next seven years and was discharged from oncology services.

Five years later she presented with macroscopic haematuria and was diagnosed with a solitary non-muscle invasive urothelial cell carcinoma. She subsequently underwent induction Bacillus Calmette-Guerin (BCG) treatment. Routine CT surveillance imaging later revealed an

enhancing thick-walled proximal right ureter and hydronephrosis (Fig. 1) which was suspicious for upper urinary tract malignancy. She underwent a right nephro-ureterectomy. Histopathology confirmed metastatic ILC with an identical endocrine receptor profile as the initial breast cancer resected twelve years prior. CT staging showed no recurrence of breast cancer or metastatic lesions elsewhere in the body.

Literature review

This literature review aimed to find all published cases of breast cancer that presented as solitary lesions in the kidney. Using PRISMA guidelines a systematic review of MEDLINE, Cochrane and EMBASE databases was performed which generated 547 results. Nine English speaking language articles documenting 14 cases matched eligibility criteria. The published case reports ranged from 1967 to 2016 (Table 1).

All patients were female ranging from 30 to 66 years of age at time of breast cancer diagnosis. (Median 56 years). The relapse time from breast cancer diagnosis to renal metastasis ranged from 6 months to 20 years (Median 6.7 years). Oncological management was rarely recorded. Most common symptoms associated with renal metastasis was macroscopic haematuria (33%), followed by abdominal or loin pain (27%) and recurrent urinary tract infections (7%). One third of patients were asymptomatic and found to have renal metastasis incidentally on imaging.

Of the 15 cases reported, 7 had left breast cancer, 4 had right sided breast cancer, and 4 did not specify. Eight patients had left sided renal

* Corresponding author. Urology Department, Royal Hobart Hospital, 48 Liverpool St, Hobart, TAS, 7000, Australia.
E-mail address: brentgilbert@gmail.com (B. Gilbert).

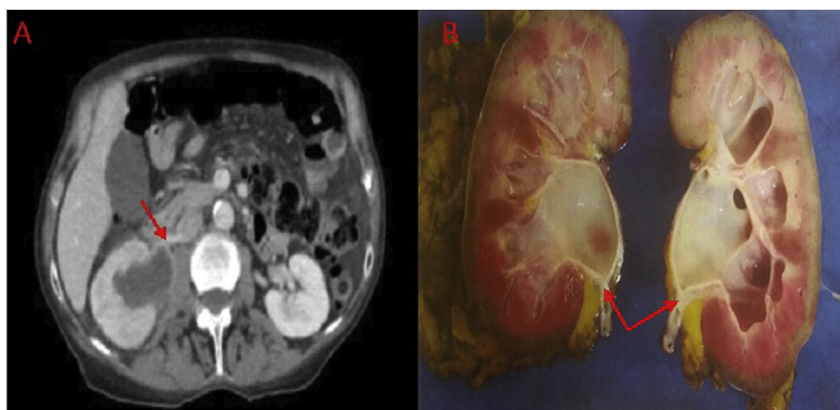


Fig. 1. A) CT imaging showing enhancing pelvic-ureteric stricture (red arrow) and corresponding hydronephrosis. B) Macroscopic image of right kidney showing hydronephrosis with neoplastic stricture at pelvic-ureteric junction (red arrows). (For interpretation of the references to colour in this figure legend, the reader is referred to the Web version of this article.)

Table 1

A summary of existing cases of solitary breast cancer metastatic lesions in the kidney.

| Case Reference | Age When Breast Cancer Diagnosed (years) | Presenting Symptoms | Histopathology |
|-----------------------------------|--|-------------------------------------|----------------------------|
| Nasu et al. (2015) | 40 | Asymptomatic | Invasive ductal carcinoma |
| Gacci et al. (2005) | 66 | Not described | Invasive ductal carcinoma |
| Akin et al. (2012) | 56 | Gross haematuria | Invasive ductal carcinoma |
| Karamouzis et al. (2006) | 65 | Asymptomatic | Invasive ductal carcinoma |
| Joo et al. (2006) | 47 | Asymptomatic | Invasive ductal carcinoma |
| Aydin et al. (2016) | 45 | Abdominal pain | Invasive ductal carcinoma |
| Al-Jarrah et al. (2013) | 58 | Recurrent loin pain | Invasive lobular carcinoma |
| Karczmarek-Borowska et al. (2015) | 41 | Gross haematuria and abdominal pain | Phylloides tumour |
| Takehara et al. (1999) | 51 | Asymptomatic | Not recorded |
| Ridlon et al. (1967) | 67 | Gross haematuria | Not recorded |
| Desai et al. (1982) | 50 | Flank pain | Not recorded |
| Fukushima et al. (1988) | 30 | Gross haematuria | Not recorded |
| Herzberg et al. (1991) | 57 | Gross haematuria | Adenoid Cystic Carcinoma |
| Komura et al. (1993) | 56 | Asymptomatic | Not recorded |
| Current Case | 66 | Gross haematuria | Invasive lobular carcinoma |

metastasis, four had right sided renal metastasis and the remainder was not described. Of the 11 cases in which both breast primary and renal secondary sites were specified, 7 had ipsilateral tumours and 4 had contralateral tumours. Malignancy involved the renal parenchyma and collecting system. Histologically, six cases of IDC, two cases of ILC, one case of phylloides tumour and one case of adenoid cystic carcinoma were diagnosed. Five cases did not identify the histology.

Twelve patients underwent nephrectomy. Two patients were poor surgical candidates and received chemotherapy alone, one patient's treatment was not specified. Follow up after treatment was rarely recorded.

Discussion

Renal cell carcinoma (RCC) and urothelial cell carcinoma (UCC) account for > 95% of renal tumours.⁴ In contrast, metastatic lesions has been estimated to be as low as 1%.⁴ Interestingly, in patients with pre-existing non-renal oncological history, a new renal lesion has a similar likelihood of being metastatic deposit or a synchronous primary renal tumour.⁴

IDC and ILC display different renal metastatic potentials. It is suggested that ILC may pose greater risk of renal metastasis due to significantly higher rates of spread to the gastrointestinal tract, peritoneum and retroperitoneum compared to IDC.³ However, our literature indicates that the majority of metastatic renal lesions were IDC (six vs. two cases). Although, it must be noted that breast cancer type remained unreported in five cases and IDC is more common than ILC.

Metastatic deposits to kidneys are prevalent in autopsies.⁴ Deposit of haematogenous metastasis in glomerular vascular plexuses, away from the urothelial collecting system, suggests that tumours can likely grow at these sites while remaining asymptomatic.⁴ In fact, only two-

thirds of patients in this review presented with urological symptoms and half the documented cases had significant latency periods from breast cancer diagnosis to development of renal metastasis. Similar paucity of symptoms has been described in renal metastasis from other solid-organ malignancies.^{1,5} Breast cancer has been shown to have a slow growing, indolent progression.³ These features highlight that there is no optimal length of follow-up for women with breast cancer and clinicians should remain vigilant.

Despite studies suggesting metastatic renal lesions show less contrast enhancement compared to primary renal malignancy, features between metastatic and primary renal lesions are often indistinguishable on CT and MRI imaging. In contrast, this case showed a metastatic renal lesion with definite contrast enhancement. Surgery is considered the standard of care in patients with primary renal malignancy. However, no established guidelines exist for surgical management of metastatic tumours to the kidney. A small retrospective study showed that survival appeared to be improved in patients with oligo-metastatic disease who underwent surgical resection.⁵ Most guidelines suggest avoiding renal biopsy to avoid seeding of a primary renal tumour. However, in patients with previous oncological history or high suspicion of non-primary renal malignancy, renal biopsy may help identify the lesion and preserve renal function for future oncological management.²

Conclusion

Breast cancer metastasis to the kidney is rare and may occur several years after primary treatment of breast cancer.⁵ Previous oncological history is an important part of the assessment for any new renal lesion. Metastatic lesions may mimic primary renal tract malignancy and definitive diagnosis can only be made through histological analysis. At

present there are no guidelines for management of metastatic lesions in the kidney and with the advance of nephron-sparing surgical modalities this remains an area that requires further study.

Funding

This research did not receive any specific grant from funding agencies in the public, commercial or not-for-profit sectors.

Appendix A. Supplementary data

Supplementary data to this article can be found online at <https://doi.org/10.1016/j.eucr.2019.100859>.

References

1. Adamy A, Von Bodman C, Ghoneim T, Favaretto RL, Bernstein M, Russo P. Solitary, isolated metastatic disease to the kidney: memorial Sloan-Kettering Cancer Center experience. *BJU Int.* 2010;108:338–342.
2. Sánchez-Ortiz RF, Madsen LT, Bermejo CE, et al. A renal mass in the setting of a nonrenal malignancy: when is a renal tumor biopsy appropriate? *Cancer.* 2004;101:2195–2201.
3. Tao Z, Shi A, Lu C, Song T, Zhang Z, Zhao J. Breast cancer: epidemiology and etiology. *Cell Biochem Biophys.* 2015 Jun;72(2):333–338. <https://doi.org/10.1007/s12013-014-0459-6>.
4. Patel U, Ramachandran N, Halls J, et al. Synchronous renal masses in patients with a nonrenal malignancy: incidence of metastasis to the kidney versus primary renal neoplasia and differentiating features on CT. *AJR Am J Roentgenol.* 2011;197:W680.
5. Zhou C, Urbauer DL, Fellman BM, et al. Metastases to the kidney: a comprehensive analysis of 151 patients from a tertiary referral center. *BJU Int.* 2016 May;117(5):775–782.