

## A rare case of congenital aniridia with an unusual run-on mutation in *PAX6* gene

Ria Ratna<sup>1</sup>, Shailja Tibrewal<sup>1,2</sup>, Abha Gour<sup>3</sup>,  
Reena Gupta<sup>4</sup>, Umang Mathur<sup>3</sup>, Vanita Vanita<sup>5</sup>

**Key words:** Aniridia, genetics, *PAX6*, run-on mutation, sanger sequencing

Congenital aniridia is characterized by partial or complete absence of the iris.<sup>[1]</sup> The disease manifestations extend to almost every part of the eye, including the cornea, anterior chamber angle, lens, fovea, and the optic nerve.<sup>[2]</sup> It has a global prevalence of approximately one in 40,000–100,000 live births.<sup>[2]</sup> Some of the clinical features like congenital nystagmus and foveal hypoplasia are present since birth, while others like cataract, aniridia-associated keratopathy (AAK),

and glaucoma may develop later in life.<sup>[1–3]</sup> Two-third of the aniridia cases are familial and one-third are a result of *de novo* (sporadic) germline mutations in the parent of the affected individual.<sup>[1]</sup> The most common inheritance pattern is autosomal dominant (AD) with high penetrance and variable expression.<sup>[1–3]</sup> However, rare autosomal recessive forms have been reported.<sup>[4]</sup> Aniridia might present as a part of the WAGR syndrome (OMIM 194072; Wilms tumor, aniridia, genitourinary anomalies, and mental retardation) due to a contiguous gene deletion encompassing the *PAX6* and *WT1* genes.<sup>[1]</sup> Around 30% of individuals detected with sporadic aniridia are likely to develop symptoms of WAGR syndrome, making abdominal ultrasound screening among children mandatory up to 7 years of age.<sup>[5,6]</sup> Another phenotypically distinct disease entity called the Gillespie syndrome presents itself as a triad of partial aniridia, non-progressive cerebellar ataxia and intellectual disability.<sup>[7]</sup> However, a causative gene has recently been identified as *ITPR1*, an inosine triphosphate receptor with calcium channel activity which is genotypically distinct from *PAX6*-associated variations.<sup>[7]</sup>

Aniridia can broadly be divided into two subgroups: classic aniridia, encompassing mutations in the *PAX6*; and aniridia-like, which includes mutations in other genes like *FOXC1*, *PITX2*, *CYP1B1*, *FOXD3* and *TRIM44*.<sup>[3]</sup> Although, non-*PAX6* genes are increasingly being identified to be linked with aniridia, *PAX6* defects remain the leading cause of congenital aniridia. Majority of aniridia cases (90%) result from haploinsufficiency in the *PAX6*, either due to mutations or chromosomal rearrangements and are inherited in AD manner.<sup>[2,6]</sup>

Genotype–phenotype correlations have been described based on the type of intragenic mutations in the *PAX6* gene, wherein the premature termination codon and C-terminal

Access this article online	
Quick Response Code:	Website: www.ijo.in
	DOI: 10.4103/ijo.IJO_433_22

<sup>1</sup>Departments of Ocular Genetics, <sup>2</sup>Pediatric Ophthalmology, Strabismus and Neuro-Ophthalmology, <sup>3</sup>Cornea and Anterior Segment, Dr Shroff's Charity Eye Hospital, Daryaganj, New Delhi, <sup>4</sup>Regional Institute of Ophthalmology, Post-Graduate Institute of Medical Sciences, Rohtak, Haryana, <sup>5</sup>Department of Human Genetics, Guru Nanak Dev University, Amritsar, Punjab, India

**Correspondence to:** Dr. Shailja Tibrewal, Department of Pediatric Ophthalmology, Strabismus and Neuro-Ophthalmology, Dr. Shroff's Charity Eye Hospital, Daryaganj, New Delhi - 110 002, India. E-mail: shailja1408@gmail.com, shailja@sceh.net

Received: 20-Feb-2022

Revision: 20-Mar-2022

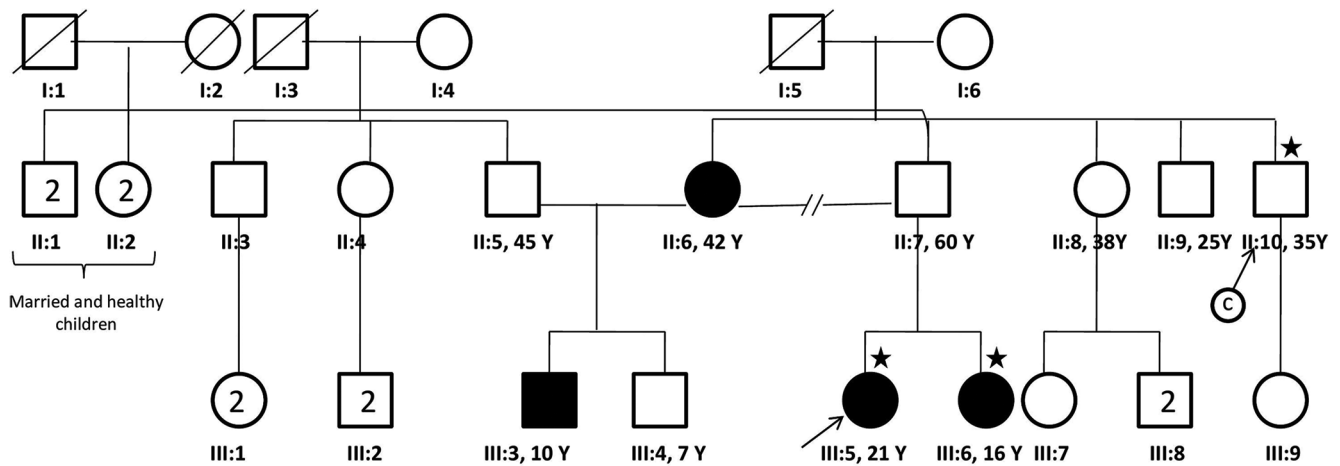
Accepted: 20-May-2022

Published: 30-Jun-2022

This is an open access journal, and articles are distributed under the terms of the Creative Commons Attribution-NonCommercial-ShareAlike 4.0 License, which allows others to remix, tweak, and build upon the work non-commercially, as long as appropriate credit is given and the new creations are licensed under the identical terms.

**For reprints contact:** WKHLRPMedknow\_reprints@wolterskluwer.com

**Cite this article as:** Ratna R, Tibrewal S, Gour A, Gupta R, Mathur U, Vanita V. A rare case of congenital aniridia with an unusual run-on mutation in *PAX6* gene. Indian J Ophthalmol 2022;70:2661-4.



**Figure 1:** Pedigree of an aniridia family of Indian origin harboring a heterozygous c.1268A>T; p.\*423L variant in *PAX6*. Proband (III: 5) is highlighted with an arrow. Star is used to denote members who gave their blood samples and participated in genetic testing

extensions (CTE) lead to a more severe phenotype as compared to the missense mutations.<sup>[8,9]</sup> The present case report describes a rare run-on mutation in the *PAX6* gene and the specific clinical phenotype of congenital aniridia linked with it. Ethical approval was obtained from the institutional review board of Dr Shroff's Charity Eye Hospital and was consistent with the provisions of the Declaration of Helsinki.

A 21-year-old female presented at Dr Shroff's Charity Eye Hospital in October 2018 with complaints of gradually increasing whitish lesion over the black part of both eyes (B/E) associated with photophobia since past few years. The proband (III: 5), her mother (II: 6), younger sister (III: 6), and younger half-brother (III: 3) [Fig. 1] had shaky eyeballs and poor vision in both the eyes since birth. The best corrected visual acuity (BCVA) of the proband was finger counting at 20 cm in right eye (R/E) and finger counting one meter in the left eye (L/E). Media opacity precluded refraction in the R/E. The refractive error was  $-18.0$  D/ $-8.0$  D at  $180^\circ$  in the L/E. Anterior segment examination revealed complete aniridia with only a thin stump of iris tissue in both eyes (B/E). There was centripetal growth of superficial vascularization from the limbus over the cornea, and adjacent stromal opacification. The severity of this AAK was more in the R/E, consequently involving the visual axis [Fig. 2a]. In the L/E, a central island of relatively clear cornea was present [Fig. 2b]. There was superior subluxation of the lens with zonular weakness in meridians 4–8 o'clock in the R/E and 4–7 o'clock in the L/E [Fig. 2c and 2d]. There was diffuse lenticular haze and dot-like lenticular opacities in B/E. Gonioscopy (Ocular Sussman four mirror handheld gonioscope, Ocular Instruments, USA) showed open angles with increased pigmentation, and multiple thin strands of iris tissue bridging the angle [Fig. 2e and 2f]. The intraocular pressure (IOP) measured with rebound tonometry (IC 200, iCare, Finland) was 10 mmHg and 9 mmHg in the R/E and L/E, respectively. The details of the fundus were hazy in the R/E and only mild pallor could be appreciated. The retina findings of the L/E revealed disc pallor, normal cup/disc ratio and absent foveal reflex [Fig. 3]. The corneal thickness was  $784 \mu\text{m}$  and  $720 \mu\text{m}$  in R/E and L/E, respectively. The younger sister had similar phenotype in B/E except that the AAK was less severe than the proband. The mother was not available for evaluation.

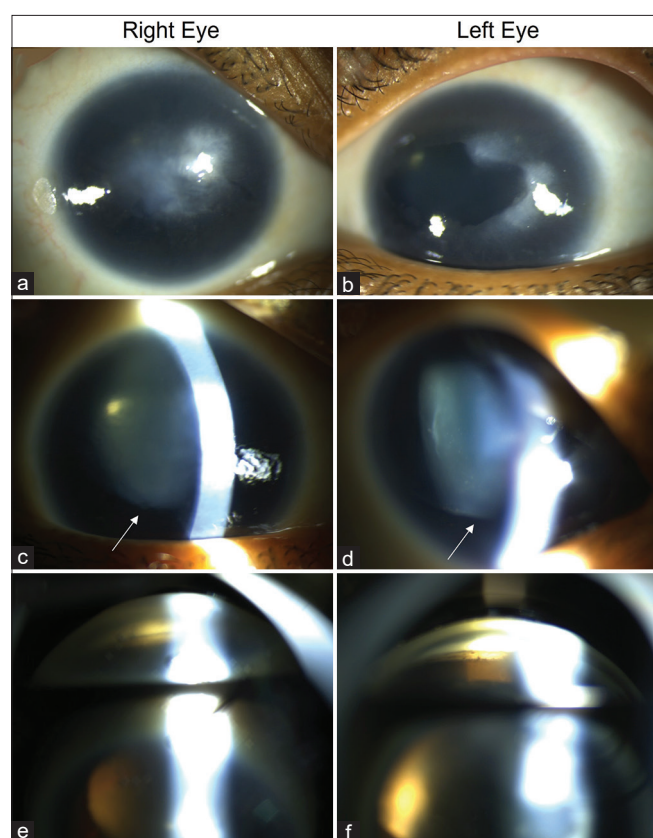
The proband was visually rehabilitated with photochromatic glasses. Preservative-free artificial tears eye drops (carboxymethylcellulose, Allergan) were prescribed for the AAK. She was advised for simple limbal stem cell transplantation followed by penetrating keratoplasty for the right eye. However, she denied any surgery considering the high rates of recurrences. She was referred for low vision and assistive devices. Given the unique aniridia phenotype and positive family history, members of the family (III: 5, III: 6, II: 10) were counselled about importance of molecular diagnosis and assessing recurrence risk to offer prenatal diagnostic options. The proband was a young, married individual planning to start a family and her younger sister was unmarried. Pre-conceptual counselling for the proband, and pre-marital counselling for her sister was carried out as they were keen to have unaffected children. Post counselling, they consented for the genetic investigation. Subsequently, molecular genetic investigations were carried out for individuals III: 5, III: 6 and II: 10.

Blood samples were collected in EDTA solution. Clinical exome analysis was carried out for the proband (III: 5) by next generation sequencing.<sup>[10]</sup> Genomic DNA was isolated and in-solution hybridization of the coding exons and flanking intronic regions within the genes tested was performed on the DNA. Illumina NextSeq system was used for paired read sequencing of the amplified captured regions. Sequence obtained was aligned to the human reference genome (GRCh37/hg19) and variant calling was performed using BWAGATK. The analyzed region included all the coding exons and  $\pm 10$  base pairs (bp) of flanking intronic region on both sides. Only variants in the coding region and the flanking intronic regions with a minor allele frequency of  $<5\%$  were evaluated. The mutation annotation was carried out using published variants in literature and set of disease databases such as ClinVar, OMIM, GWAS, HGMD and SwissVar. Based on results of the above-mentioned bioinformatics analysis, the mutation identified in the proband was a heterozygous variant (c.1268A>T; p.\*423L) causing a stop loss change in *PAX6*. Sanger sequencing was performed for individuals II: 10 and III: 6. High-fidelity polymerase chain reaction (PCR) was performed on their genomic DNA for amplification of *PAX6* gene covering the variant identified in individual III: 5 using separate primer sets. The amplified

**Table 1: Aniridia cases reported to be linked with c.1268A>T; p.\*423L in PAX6**

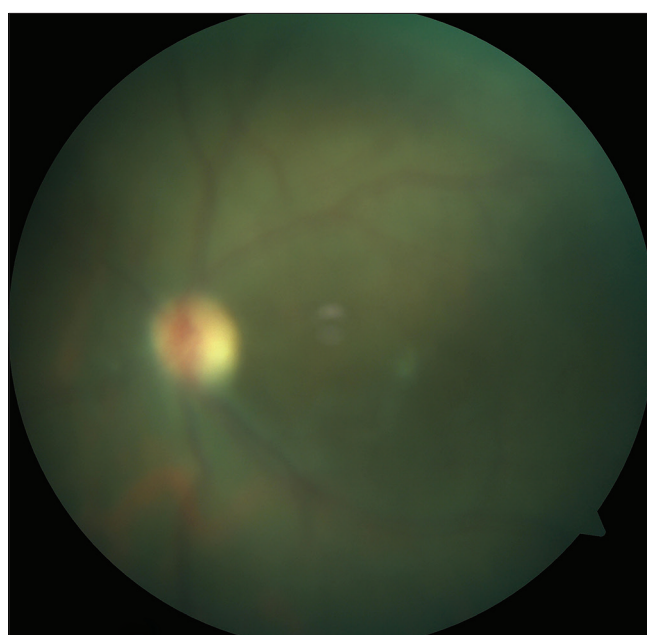
Author/year	Origin of the family	Number of families	Familial/Sporadic case	Phenotype
Baum, 1999 <sup>[16]</sup>	Chinese (Hong Kong)	1	NM	Bilateral affection, vision of 20/200, aniridia, nystagmus, keratopathy, cataract, macular hypoplasia
Singh, 2001 <sup>[14]</sup>	Hispanic	1	Sporadic	Bilateral poor vision, nystagmus, moth-eaten appearance of pupil due to absence of inner part of iris, anterior capsular plaque type cataract
Chao, 2003 <sup>[17]</sup>	NM	1	Sporadic	Aniridia, strabismus, ptosis, corneal pannus, glaucoma, preauricular ear pits
Bobilev, 2016 <sup>[18]</sup>	NM	2	Sporadic	Aniridia <sup>†</sup>
Vasilyeva, 2017 <sup>[19]</sup>	Russian	1	Sporadic	Aniridia <sup>†</sup>
Souzeau, 2018 <sup>[15]</sup>	Cambodia	1	Familial, AD	Five individuals affected in the family. All had similar features of total aniridia, nystagmus, foveal hypoplasia, poor vision (ranging from 20/200 to HM), high myopia, high CCT (ranging from 584 to 779) and no glaucoma. Additionally, one family member had mild keratopathy, three had cataract, one had lens subluxation and two had chorio-retinal atrophy due to high myopia
Present study	Indian	1	Familial, AD	Four individuals (II: 6, III: 3, III: 5, III: 6) affected in the family. III: 5 had total aniridia, nystagmus, foveal hypoplasia, keratopathy, high CCT, superior lens subluxation, high myopia, and optic atrophy.

NM, Not mentioned; AD, Autosomal dominant; HM, Hand movements; CCT, Central corneal thickness. Only English language literature has been mentioned here. <sup>†</sup>Detailed description of phenotype not mentioned



**Figure 2:** Clinical photographs of anterior segment of proband. (a and b) show the aniridia-associated keratopathy, (c and d) show superior subluxation of the lens (arrow), and (e and f) show the gonioscopic view of the inferior angle

product was sequenced bi-directionally as described elsewhere by Vanita *et al.* in 2006.<sup>[11]</sup> The nucleotide sequence was extracted in FASTA format and aligned using CodonCode Aligner to identify variants and was verified for quality using ChromasLite



**Figure 3:** Fundus photograph of the left eye of proband (III: 5) showing average-sized disc with pallor, a normal cup/disc ratio and the absence of foveal reflex

software. The final result confirmed c.1268A>T; p.\*423L in the affected sister (III: 6) too and the unaffected maternal uncle (II: 10) showed wild-type (AA) genotype.

## Discussion

*PAX6* (OMIM: 607108) is a crucial transcription factor gene for oculogenesis that is expressed during developmental stages of eye.<sup>[12]</sup> Several types of mutations in the *PAX6* gene such as frameshifts, nonsense, splice site, insertions, deletions, and CTE have been reported for aniridia with other co-occurring ocular anomalies (*PAX6* webpage - MRC Human Genetics



Unit LOVD at MRC IGMM - Leiden Open Variation Database, 2022)).<sup>[13]</sup> C-terminal extensions in *PAX6* cause the reading frame to continue protein coding into the 3' UTR and leads to gain-of-function and severe aniridic phenotype.<sup>[2]</sup> The c.1268A>T substitution observed in present study is a CTE mutation leading to loss of the stop codon at the 3' end and leading to addition of 21 to 24 Poly-dAs, as also previously reported by Singh *et al.*<sup>[14]</sup> c.1268A>T has previously been reported in few individuals with aniridia in different studies across the globe [Table 1]. Compared to the earlier reports, the unique clinical features of the affected individuals with aniridia in the current study are superior subluxation of the lens, high myopia and optic atrophy. These features are similar to those reported by Souzeau *et al.* in a Cambodian family.<sup>[15]</sup>

The minor allele frequency for c.1268A>T substitution is not reported in the general population. *In silico* analysis of c.1268A>T supports its deleterious effect. Mutation Taster, CADD, DANN, FATHMM, Eigen and GenoCanyon predicted it to be disease causing/damaging. Validation by Sanger sequencing confirmed c.1268A>T substitution in *PAX6* in the proband as well her sister in heterozygous form, while their unaffected maternal uncle had wild-type genotype. Affected mother of proband could not be tested for c.1268A>T in *PAX6* due to geographical limitations. Based on the segregation of variant with the phenotype in the present study and previously published reports [Table 1], c.1268A in *PAX6* seems to be a mutation hot-spot for aniridia.

The treatment of aniridia entails treating its various clinical manifestations individually.<sup>[1,3]</sup> The foveal hypoplasia and the nystagmus do not have any definitive treatment. Cataract surgery may benefit those with significant lenticular opacities or lens subluxation.<sup>[20]</sup> Since the lenticular opacity and subluxation were mild in this patient, they did not warrant any treatment. Cataract extraction, when indicated, may be combined with iris reconstruction with various iris prosthetic devices.<sup>[21]</sup> AAK may benefit in early stages with artificial tears and autologous serum.<sup>[1]</sup> However, in advanced stages when the visual axis is affected, restoration of the limbal stem cell niche followed by keratoplasty has been shown to have limited success.<sup>[1]</sup>

To conclude, through this case report, we have described the detailed phenotype of the c.1268A>T; p.\*423L run-on mutation in the *PAX6* gene in an Indian family. We have demonstrated the likely pathogenic modality of this mutation by segregation analysis among affected and unaffected members of this family, as well as *in silico* analysis. To the best of our knowledge, this mutation has not been reported previously in the Indian population.

#### Declaration of patient consent

The authors certify that they have obtained all appropriate patient consent forms. In the form the patient(s) has/have given his/her/their consent for his/her/their images and other clinical information to be reported in the journal. The patients understand that their names and initials will not be published and due efforts will be made to conceal their identity, but anonymity cannot be guaranteed.

#### Financial support and sponsorship

Nil.

#### Conflicts of interest

There are no conflicts of interest.

## References

1. Landsend ECS, Lagali N, Utheim TP. Congenital aniridia - A comprehensive review of clinical features and therapeutic approaches. *Surv Ophthalmol* 2021;66:1031-50.
2. Hingorani M, Hanson I, van Heyningen V. Aniridia. *Eur J Hum Genet* 2012;20:1011-7.
3. Samant M, Chauhan BK, Lathrop KL, Nischal KK. Congenital aniridia: Etiology, manifestations and management. *Expert Rev Ophthalmol* 2016;11:135-44.
4. Reis LM, Semina EV. Genetics of anterior segment dysgenesis disorders. *Curr Opin Ophthalmol* 2011;22:314-24.
5. Shannon RS, Mann JR, Harper E, Harnden DG, Morten JE, Herbert A. Wilms's tumour and aniridia: Clinical and cytogenetic features. *Arch Dis Child* 1982;57:685-90.
6. Grønsvov K, Olsen JH, Sand A, Pedersen W, Carlsen N, BakJylling AM, *et al.* Population-based risk estimates of Wilms tumor in sporadic aniridia. A comprehensive mutation screening procedure of *PAX6* identifies 80% of mutations in aniridia. *Hum Genet* 2001;109:11-8.
7. Gerber S, Alzayady KJ, Burglen L, Brémond-Gignac D, Marchesin V, Roche O, *et al.* Recessive and dominant De Novo ITPR1 mutations cause Gillespie syndrome. *Am J Hum Genet* 2016;98:971-80.
8. Vasilyeva TA, Marakhonov AV, Voskresenskaya AA, Kadyshev VV, Käsmann-Kellner B, Sukhanova NV, *et al.* Analysis of genotype-phenotype correlations in *PAX6*-associated aniridia. *J Med Genet* 2021;58:270-4.
9. Neethirajan G, Solomon A, Krishnadas SR, Vijayalakshmi P, Sundaresan P. Genotype/phenotype association in Indian congenital aniridia. *Indian J Pediatr* 2009;76:513-7.
10. Seaby EG, Pengelly RJ, Ennis S. Exome sequencing explained: A practical guide to its clinical application. *Brief Funct Genomics* 2016;15:374-84.
11. Vanita V, Singh D, Robinson PN, Sperling K, Singh JR. A novel mutation in the DNA-binding domain of MAF at 16q23.1 associated with autosomal dominant "cerulean cataract" in an Indian family. *Am J Med Genet A* 2006;140:558-66.
12. Klann M, Seaver EC. Functional role of *pax6* during eye and nervous system development in the annelid *Capitella teleta*. *Dev Biol* 2019;456:86-103.
13. Lsdb.hgu.mrc.ac.uk. 2022. *PAX6* homepage - MRC Human Genetics Unit LOVD at MRC IGMM - Leiden Open Variation Database. Available from: [http://lsdb.hgu.mrc.ac.uk/home.php?select\\_db=PAX6](http://lsdb.hgu.mrc.ac.uk/home.php?select_db=PAX6). [Last accessed on 2022 Mar 30].
14. Singh S, Chao LY, Mishra R, Davies J, Saunders GF. Missense mutation at the C-terminus of *PAX6* negatively modulates homeodomain function. *Hum Mol Genet* 2001;10:911-8.
15. Souzeau E, Rudkin AK, Dubowsky A, Casson RJ, Muecke JS, Mancel E, *et al.* *PAX6* molecular analysis and genotype-phenotype correlations in families with aniridia from Australasia and Southeast Asia. *Mol Vis* 2018;24:261-73.
16. Baum L, Pang CP, Fan DS, Poon PM, Leung YF, Chua JK, *et al.* Run-on mutation and three novel nonsense mutations identified in the *PAX6* gene in patients with aniridia. *Hum Mutat* 1999;14:272-3.
17. Chao LY, Mishra R, Strong LC, Saunders GF. Missense mutations in the DNA-binding region and termination codon in *PAX6*. *Hum Mutat* 2003;21:138-45.
18. Bobilev AM, McDougal ME, Taylor WL, Geisert EE, Netland PA, Lauderdale JD. Assessment of *PAX6* alleles in 66 families with aniridia. *Clin Genet* 2016;89:669-77.
19. Vasilyeva TA, Voskresenskaya AA, Käsmann-Kellner B, Khlebnikova OV, Pozdeyeva NA, Bayazutdinova GM, *et al.* Molecular analysis of patients with aniridia in Russian Federation broadens the spectrum of *PAX6* mutations. *Clin Genet* 2017;92:639-44.
20. Neuhann IM, Neuhann TF. Cataract surgery and aniridia. *Curr Opin Ophthalmol* 2010;21:60-4.
21. Srinivasan S, Ting DS, Snyder ME, Prasad S, Koch HR. Prosthetic iris devices. *Can J Ophthalmol* 2014;49:6-17.