



# Oral Infections in Ancient Human Skulls in 2000 BC/Iron Age, Iran

*\*Dariush D. Farhud<sup>1,2,3</sup>, Mahsa Azari<sup>2,3,4</sup>, Mehdi Rahbar<sup>5</sup>*

1. School of Public Health, Tebran University of Medical Sciences, Tebran, Iran
2. Research Center for Paleogenomics, Tebran University of Medical Sciences, Tebran, Iran
3. Farhud Genetic Clinic, Tebran, Iran
4. Department of Archeology, Faculty of Literature and Humanities, Tebran University, Tebran, Iran
5. Organization of Cultural Heritage, Handicrafts and Tourism, Tebran, Iran

**\*Corresponding Author:** Email: farhud@sina.tums.ac.ir

(Received 12 Jun 2023; accepted 09 Aug 2023)

## Abstract

**Background:** Oral infections have been seen in humans since ancient times. Excessive penetration of this infection can cause human death. Most of these infections are gum cysts and abscesses. The cyst creates large hard lumps in the gums, which causes loose, and protruding teeth and abscesses, causing cavities in the jawbone and teeth. In this article, we have discussed for this infectious disease in 4000 – year - old ancient humans from Qazvin Province, Iran. The bone remains of our research are related to Sagezabad ancient cemetery in Qazvin plain.

**Methods:** We tried to use reliable international atlases to get detailed information about ancient oral infections. The bones were extracted from the 2019 excavation of the Ghara Tappe area of Sagezabad for the Iron Age 2<sup>nd</sup> and 3<sup>rd</sup> Qazvin plains of Iran. This cemetery belongs to the period of the Medes Kingdom (pre - Achaemenian kingdom) in Iran.

**Results:** We have discussed one of the ancient cemeteries with a large number of ancient populations. In this cemetery, there are signs of war and infectious diseases on the bones, which can be clearly seen. We have specially mentioned the abscess as the cause of oral infection from Sagezabad cemetery.

**Conclusion:** Oral infection existed in Iran since 2000 BC. Of course, this infection was common in ancient times and even Paleolithic period, like Homo Heidelbergensis.

**Keywords:** Oral disease; Abscess; Homo heidelbergensis; Ancient human; Iran

## Introduction

Sagezabad region is one of the most populated (societies or villages) of the Medes period in Iran (1). The Medes kingdom was made up of tribes allied with the king. This means the existence of an army, government, and law in the territory.

However, we see signs of war between tribes so followed by looting and lack of food (2).

One of the common diseases is oral infection, abscess and gum cyst, caused by bacteria and the lack of vitamins C and D suitable for the body's immunity. If the intensity of the infection is



greater and the penetration is deeper, so it could affect the bones. Perhaps one of the simple reasons for creating an abscess, is the cut off the gum by the hunt bone and lack of nutrients, which over time, bacteria accumulate in the damaged part and finally create an infection. Another common disease of oral infection is a gum cyst. This disease occurs as hard lumps filled with pus at the end of the roots of the teeth and near the position of the tooth in the bone. The greater the severity of the infection, to create big the cyst glands. Eventually their hardness, it causes displacement, compression and loosening of the teeth. This type of disease enters infection to the lungs and digestive system from the throat (3-4). The oral infection has existed since the Paleolithic period also in Neanderthal Societies.

Oral diseases are one of the most common human diseases in every era. Oral diseases there were in human societies since ancient times; infections are related to bacterial activity in the mouth. Most of the infections caused by bacteria in the mouth are abscesses and dental cysts. We have seen the existence of these two types of infections since ancient times. A dental cyst, called a gland filled with liquid or semi-solid material. Cysts are usually formed in the soft tissues of the mouth and face, such as the gums, lips, and even in the spaces around the teeth that have not yet fully erupted from the jaw (5). Oral cysts usually start as non-infectious growths, but the inflammation of the cyst has an effect over time and causes the pulp (the central part of the tooth) to destroy and swell. As the size of the cyst increases, a lot of pressure is applied to the bone, around the tooth. This pressure causes degeneration and destruction of the bone around the tooth and loosening. A Dental abscess is a cavity or tissue filled with pus that forms around the root of the tooth. This complication is caused by the growth of bacterial activity. If not treated,

can cause a hole in the jaw. The bacterial infection penetrates from the jaw to the neck and other parts of the body, including the lungs and the digestive system and causes severe disturbances. Not having a proper diet and not getting nutrients, such as vitamins, D and C to the body leads to the weakness of the immune system and causes the growth and penetration of bacteria in the body (6).

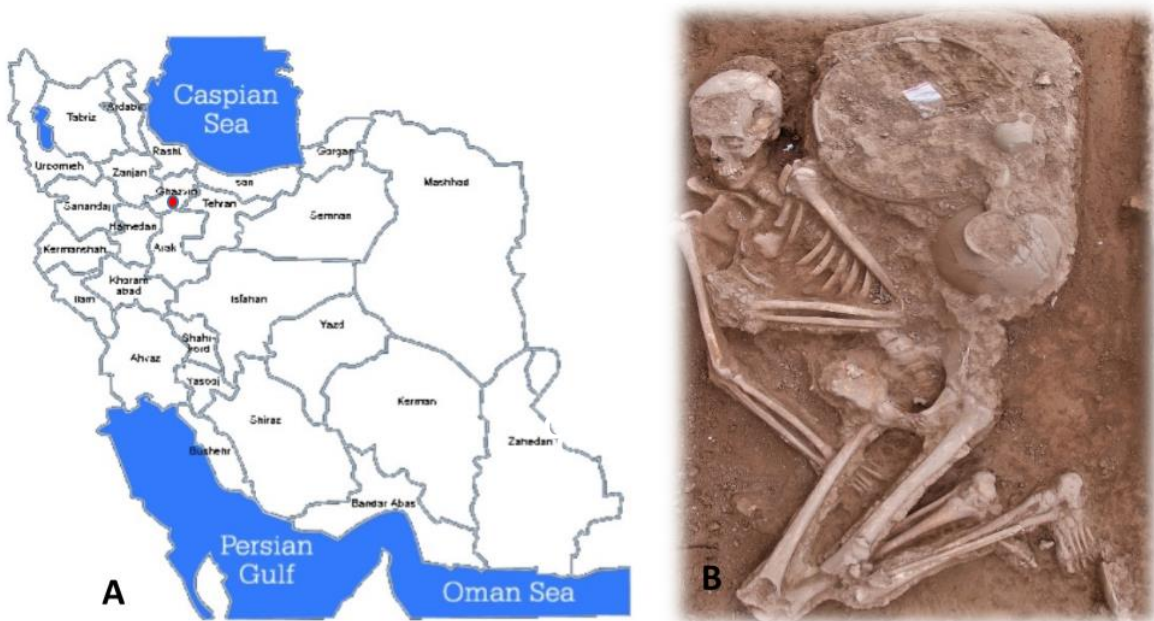
By understanding the type of signs of this infection on the bones, we examined the human bones obtained from the excavation of the cemetery around 2000 BC. This type of infection existed in ancient Iran; infected bones, similar to the symptoms of the disease in question, are available in Sagezabad cemetery. The infections are numerous enough to show exact similarities.

## **Materials and Methods**

We used human remains extracted from the cemetery of Ghara Tappe, Sagezabad, in the Qazvin plain, central Iran.

The human bones of this cemetery are extracted by one of the archaeological writers of this article. This cemetery is located in Qazvin Plain (Fig. 1. A-B) near to the capital of Iran. Sagezabad cemetery belongs to the 2<sup>nd</sup> and 3<sup>rd</sup> Iron Age (1), which is 4000 years old. In its own period, this cemetery is part of the territory of the kingdom of Medes (rule before the Achaemenids) in Iran. In order to check the symptoms of the disease more closely, according to reliable international atlases.

Sagezabad cemetery contains 5 burial layers (one after the other). The time interval between layers is maximum 5-10 years. Layer 5 is the oldest layer with a depth of 4 meters, in which only one horse is buried; from layer 4 we came across human burials, which were about 2.5 meters deep.



**Fig. 1:** A: The place of exploration and extraction of remains (Free of internet). B. The remains of an adult woman with burial gifts (Original)

In layer 2 and 1, the number of remains decreases and the signs of famine and lack of food and vitamins are evident on the bones. (The zero layer in ar-

cheology is the surface layer). In the figure, a small section of this excavation trench related to layer 5, 4 and 3 is given (**Fig. 2**).



**Fig. 2:** A view of a part of the trench that includes layers (from bottom to top) 5, 4 and 3 (Original)



The remains we studied are related to layers 2 and 3; in layer 4 there were signs of war (war weapons: swords, daggers, bows) along with the dead. In Layers 3, there was a large number of deformed bones. This shape creates infection so it is possible to notice the lack of nutrients (7) (Fig. 3).

### *Ethics approval*

The relevant license was obtained from the Institute of Archeology of Tehran University with number 713/1798.

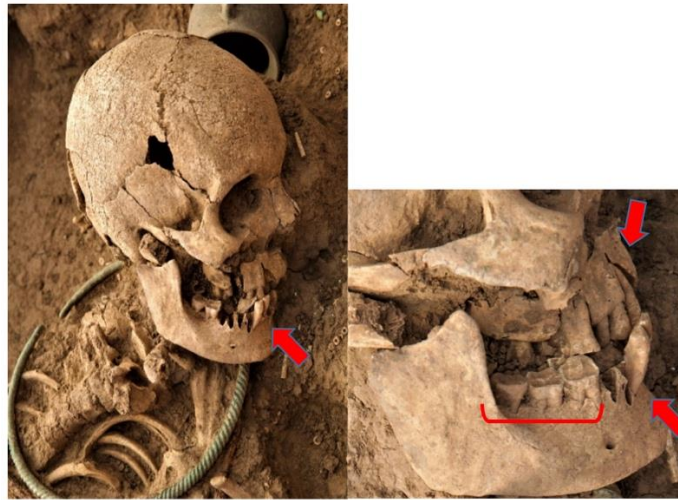
### Results

In Fig. 3. A, the mandible is from an adult female, which is most likely under the teeth of the central incisor to the first molar, there was a gland from the

cyst and it caused upward pressure, the jaw bone is forward and the roots of the teeth have risen and protruded from the cavity. The jaw has an arch and thin bone in the front part. There is a hole on the left side of the mandible, which is probably due to infection and abscess. May be the teeth were loose at the time of death because some teeth were found inside the mandible. The presence of deep and non – standard cavities on the bone in the position of the teeth, indicates which, this person had lost several teeth at the time of her death; the jaw has had a severe infection to the extent that the mandible bones have become calcified, arched, thin and hollow. Fig. 3. B, a female that seems due to the presence of cysts in her gums, her teeth were knocked out and loosened before her death by war.



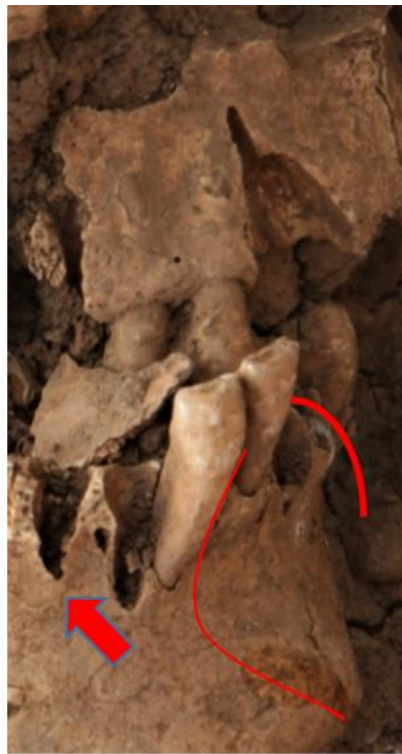Fig. 3. A. Adult female mandible with teeth in soil (Original)



**Fig. 3: B 1.** The skull is of a female who had a mouth infection before she was killed (Original)

Fig. 3. B 1, the roots of the teeth coming up from the position, from the front teeth to the molars, the small position of the teeth and not being in a row increases the possibility of cysts. Fig. 3. B 2, the presence of an arch, protrusion of the teeth and jaw towards the

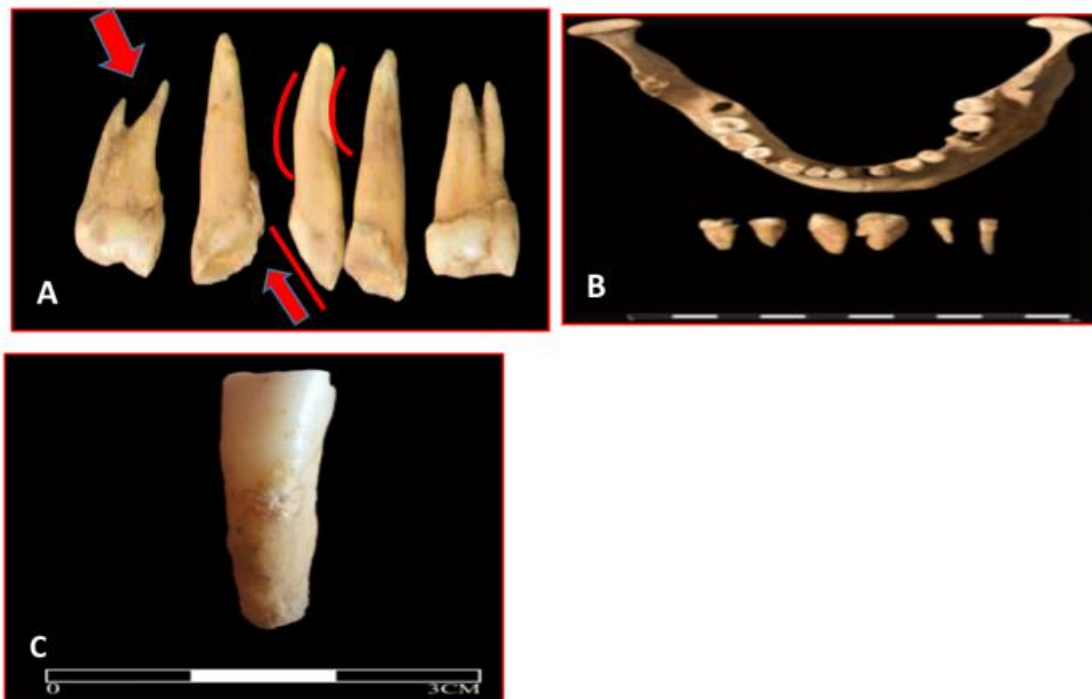front and loose teeth indicate the pressure of a gland from the inside to the outside, it is possible that she had a cyst and the pressure of the gland caused these complications.



**Fig. 3: B 2:** There is a possibility of cyst glands in the mouth of an adult female, which has caused teeth and jaw to protrude (Original)

Fig. 4. A: There was a prominent deposit of infection from the enamel to the root of the tooth. In this Fig., we can see a molar whose root has been under pressure to such an extent that the amount of penetration of the tooth the root into the jawbone is very limited and unstable. Therefore, teeth loosening and falling out are easily possible. Due to the low wear of the tooth enamel, it is possible that there was a cyst near the tooth root before the tooth erupted so root shape and surface is not normal. Fig. 4. B, is related to the mandible of an adult man. The central incisor teeth were very thin, more than 50% of these teeth were outside the gums, which indicated the presence of several years of cysts, this means that at the time of death due to the presence of infection, a number of teeth were

probably loose, so that after death they were easily removed from their bone position and placed in the soil inside the jaw. The thinness or wideness of the roots and calcite and cuts in the roots, mean the presence of infection; A wide root is probably due to a cyst under the root that puts pressure upwards, and a thin root is caused by the pressure of the teeth that have a gland under them. The enamel of the teeth showed signs of infection and damage. In Fig. 4. C, the presence of signs of damage in the enamel body was seen in most of these types of teeth. Fig. 4. D, is related to the mandible of an adult man. As we can see in the picture, the existence of a cyst is quite clear. All of his teeth were more than half outside the gum, which means that the tooth loses in its position.



**Fig. 4:** A. Calcification of teeth with attached infectious mass (Original). B. Non-Standard mandibular tooth roots of an adult man (Original). C. The effect of caries and calcination in the middle surface of tooth enamel (Original)



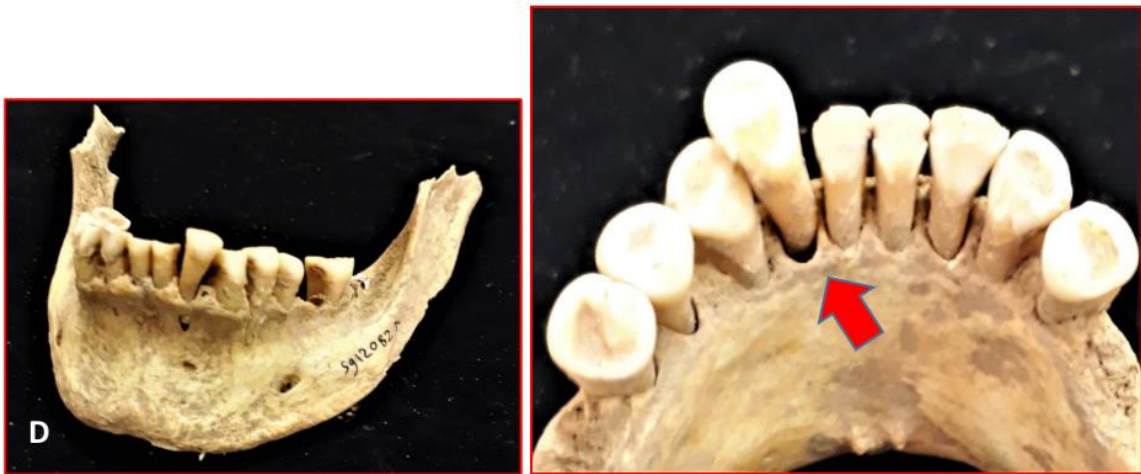

Fig. 4: D. Loose teeth of the mandible of an adult male (Original)

Fig. 5 is the mandible of an adult female, with the presence of a cyst and its sign is quite clear from inside the mandible. She also had several abscess cavities on both sides of her jaw, a gum cyst, and the intensity of the infection was so high that caused fall out the teeth to due to the cyst glands

and the teeth enamel was perforated due to the abscess. There is pressure between the teeth, and the thinness of the front jaw bone and infection have caused the body of the tooth cavities to fall out and calcite has occurred; So it is possible that she died from this infection.

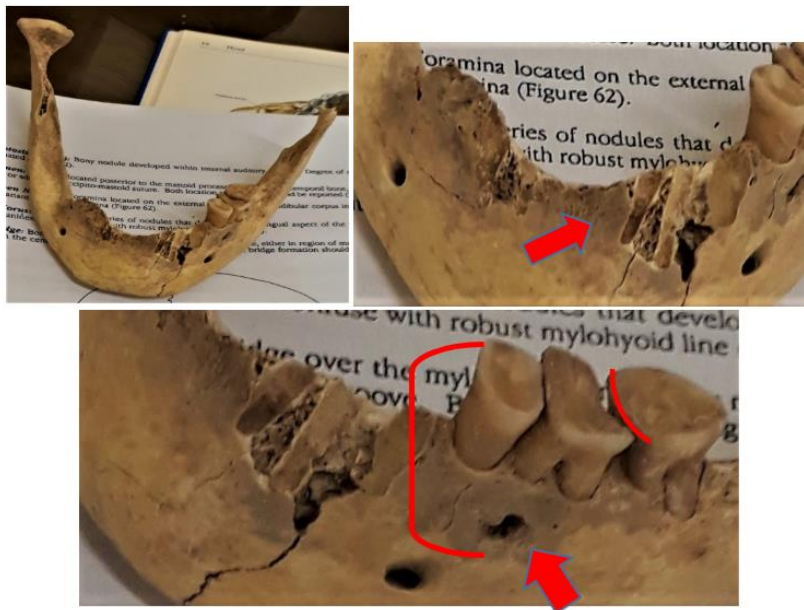


Fig. 5: The presence of symptoms of cyst and abscess cavity in the mandible of an adult female (Original)

Fig. 6, is related to the radiograph of several jaws, where the pressure and shrinking of the pulp can be clearly seen. Like all these symptoms of oral

infection (cysts and abscesses), we adapted them to the international reliable atlas (8-9).

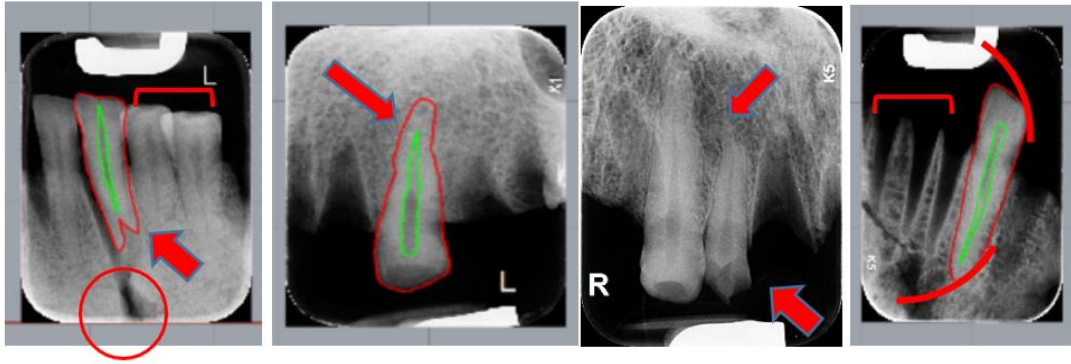


Fig. 6: Examples of jaw scans to identify cysts and abscesses (Original)

Fig. 7: This skull is for an adult man who had a severe oral infection. The oral infection penetrated to the pulp of the teeth and moved from the maxilla to the occipital, causing calcification and bone changes.

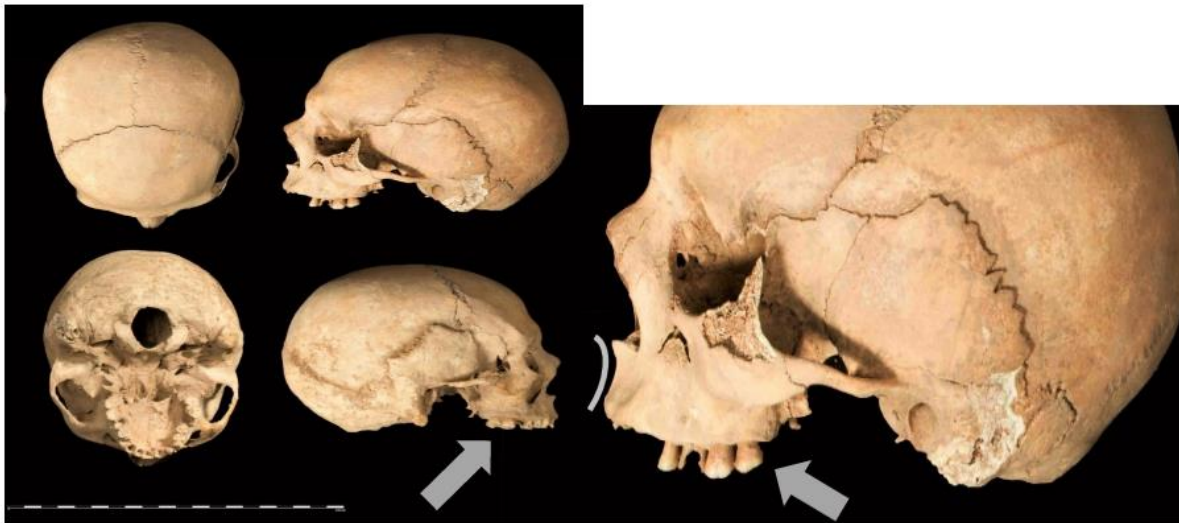
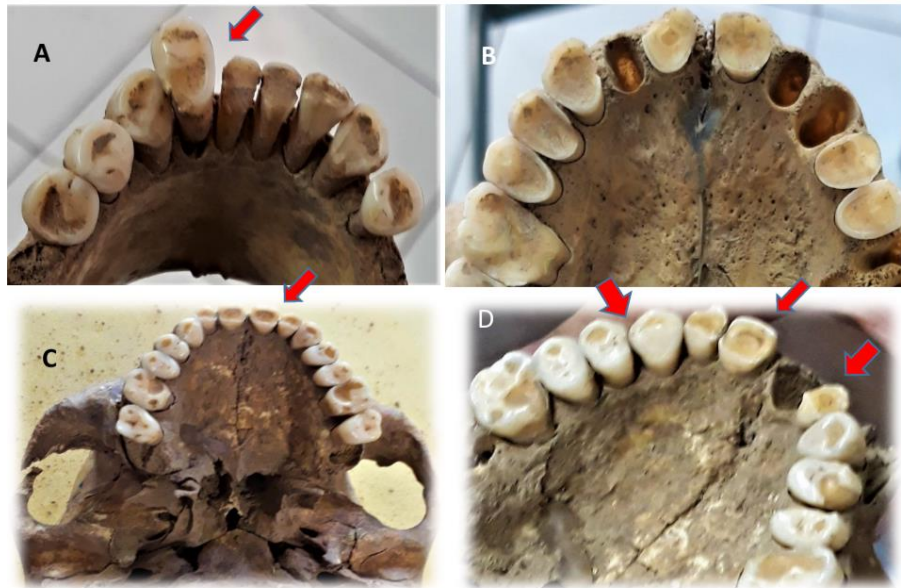


Fig. 7: Infection skulls of adult male (Original)

Fig. 8. A: The mandible of an adult female, may have had an oral infection and the cyst glands (Due to the presence of signs of this type of infection in the layer and compression and protrusion of the tooth). Fig. 8. B: Tooth enamel wear due to a hard diet was seen in the teeth of some remains of the cemetery. The presence of a hard diet increases the possibility of wounding the soft part of the mouth, so infection to be active in the same wound. Fig. 8. C: Perhaps there was the use of tools by the teeth and mouth in the people of that period, which is the reason for the wounding of the soft part of the part near the teeth

and the way of infection to the mouth and gums. The picture shows the wear of the central part of the tooth enamel in the incisors and premolars. Fig. 8. D: Maxilla of another individual, she is a young adult. Severe wear can be seen in the center of the incisors and molars outwards. Considering that most of these abrasions are in specific areas of the teeth are likely that most of these types of activities were related to the women's community, of course, more data is needed to plan this issue, which will be followed up in the future.

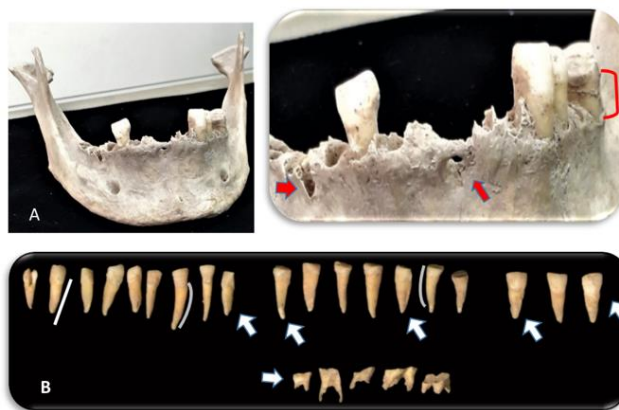



**Fig. 8:** **A:** Excessive protrusion and loosening of the teeth and wear of the central surface of the mandibular teeth of an adult woman (Original). **B:** Wear to the surface of the maxilla bone of an adult male (Original). **C:** Abrasion of the central surface of the teeth of the young adult woman maxilla (Original). **D:** Wear of the central surface and around the teeth of an adult female maxilla (Original)

Fig. 9. A: Mandible of an adult man who had lost his molar teeth. He has an abscess hole in the mandible, where we see a deep and excessively thin cavity of the mandible bone in the upper part. Excessive protrusion of premolar teeth indicates the pressure of the cyst glands in the root. Fig. 9. B: Excessive thinness of the body of the tooth, a group of canines and incisors (from sev-


eral individuals), with crooked enamel and complete root corrosion of several premolars and molars were shown at the bottom of the image, which is probably the result of infection and cysts root destruction without any signs of damage on the surface. So maybe this destruction is for severe calcification and porosity.



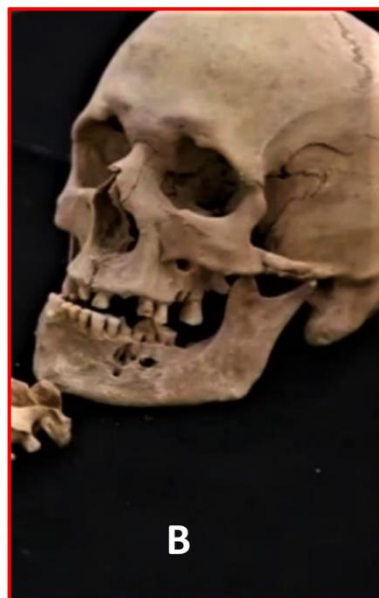**Fig. 9:** **A:** Protrusion and abscess cavity in the mandible of an adult man (Original). **B:** The change in the shape of the tooth, the excessive narrowness of the root, and the calcification of the tooth root can be seen (Original)

**Fig. 10. A:** The mandible belongs to the adult male. The narrowness of the center of the mandible can be seen in the inner and outer parts of the incisors to the jawbone. The teeth are inclined to the outside and it can be imagined that a hard gland, near to the root, pushes the teeth upwards. According to the presence of wear on the surface of this man's teeth, it is possible that he used his teeth as a tool and pulled an object like a rope with strength during his life. The swelling and narrowness of the mandible bone on the right side is completely palpable. Due to the presence of multiple sharp object scratches from

two opposite directions on the bone on the molar root, the destruction of the bone position of that tooth, is possible that this procedure is to extract the tooth to help drain the pus, because the other molar tooth shows no signs of damage. According to the presence of tooth sockets (tooth position) and the lack of signs of bone repair in the area scratched with a sharp object, it is possible that this issue happened near the time of his death. Fig. 10. B: Adult male skull, with several abscess cavities in the maxilla; the bone cavity is so deep and wide, that the roots of the teeth are visible.



**Fig. 10: A.** Adult male mandibular loose teeth and a cut mark on the bone (Original)



**Fig. 10: B:** Adult male with several abscess cavities (Original)

**Fig. 11:** The mandible belongs to the adult male. A tiny abscess hole was seen near the socket of the incisors. The bony position of the teeth is very narrow and the teeth are inclined upwards and loose. There is a pus deposit around the mo-

lar root on the left side of the mandible, which caused the calcification of his tooth (if he survived). So most likely, his jaw had an infection and cyst.



**Fig. 11:** The presence of abscess cavity and loose teeth in the mandible of a young adult man (Original)

**Fig. 12:** This disease does not only include an era with a distance of 4 thousand years from us, Rather, this type of infection existed in the society of people from the Middle Pleistocene period, i.e. humans beyond Homo Sapiens, i.e. Heidelberg and it has affected their lives and even caused their death due to the lack of treatment and the severity of the infection. In a research on the skull bone of Homo Heidelbergensis No.5 of Sima de los Huesos site (Atapuerca, Spain), signs of wear, fracture and cut in the tooth enamel area, abscess cavities, calcification of the maxilla bone. All indicate the severity of the infection in this person. It is possible that the infection has

progressed to the blood of this person and has contaminated his/her blood and caused his/ her death (10). Homo Heidelbergensis, was a human species that lived during the middle Pleistocene. Humans, which some consider to be the ancestors of Neanderthals and Homo sapiens. Researchers have considered the age of this type of species from 780 – 130 thousand years ago (11). The reason for the name Heidelberg for this species is due to the first discovery of this type of species in south west Germany from “Mauer” near Heidelberg city. This discovery was made by accident in 1907.



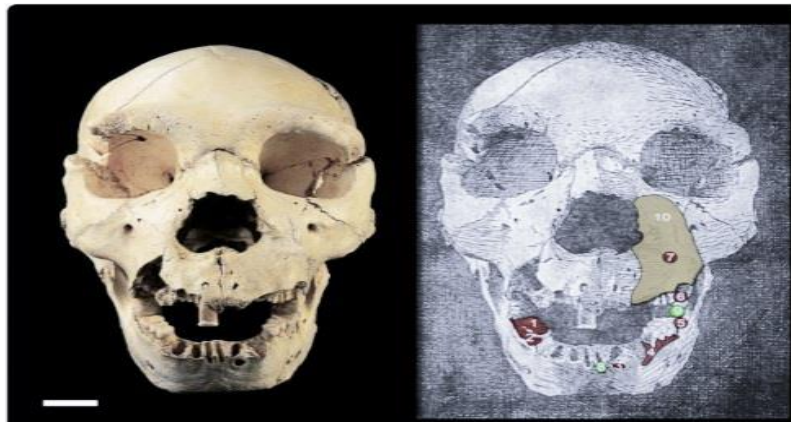

Fig. 12: Skull with infection in Homo Heidelbergensis No.5 (10)

## Discussion

Oral infection was one of the common diseases of the ancient people, and it may be easy to get this infection due to a lack of vitamins and nutrients and a lack of hygiene, so this disease does not only include people from 4 thousand years ago. Rather, this disease has gone beyond prehistoric people such as primitive Homo sapiens and reaches as far as Homo Heidelbergensis, which is 400,000 years old (11-12). Neglecting the wound of the gums due to tooth extraction or cutting by a sharp bone, causes infection and growth of bacteria and ultimately tooth loss and infection of the lung of the patient (13-14).

This disease existed in prehistoric and Paleolithic times (15). In the period when Neanderthals, used their teeth more than ancient people to cut meat and anything else, it causes the gum to be cut or the tooth to be pulled out and as a result, the infection penetrates into the wound. This disease was detected by scanning and extracting DNA (16-17). The existence of this type of disease is caused by the mixing of Neanderthals with Homo sapiens (18-19).

It needs further research and more information about the existence of this disease from ancient times. To reach a 100% answer, it is necessary to extract DNA and perform various analysis that are currently being done.

## Conclusion

Oral diseases such as cysts and abscess occurred in ancient times due to lack of hygiene and nutrients to build immunity, and because there was no knowledge to treat and eliminate the infection, this disease could cause a person's death; Including these cases, there are also among a number of people of the ancient cemetery of Sagezabad, Iran. The symptoms are clearly visible on the bones due to the severity of the disease and infection, so it is likely to have caused their death.

## Journalism Ethical considerations

Ethical issues (Including plagiarism, informed consent, misconduct, data fabrication and/ or falsification, double publication and/ or submission, redundancy, etc.) have been completely observed by the authors.

## Acknowledgements

The authors gratefully acknowledge the financial support for this work that was provided by Dr. Farhud Scientific Foundation.

## Conflict of interest

The authors declare that there is no conflict of interest.

## References

1. Tala H (1983). *Late bronze age and Iron Age I architecture in saqqabad-Qazvin plain –the central plateau of Iran*. Iranica Antiqua, pp.: 18-51.
2. The Cambridge History of Iran. Volume 7. Edited by P. Avery, University of Cambridge, G. R. G. Hambly, University of Texas, Dallas, C. Melville, University of Cambridge
3. Hengen OP (1971). *Cribrorbitalia: Pathogenesis and probable aetiology*. Homo, pp.: 57-76.
4. Johnson D, Wilkie AM (2011). Craniosynostosis. *Eur J Hum Genet*, 19(4): 369-376.
5. Slavkin H C, Baum B J (2000). Relationship of dental and oral pathology to systemic illness. *JAMA*, 284 (10): 1215-1217.
6. Gunville C F, Mourani P M, Ginde A A (2013). The role of vitamin D in prevention and treatment of infection. *Inflamm Allergy Drug Targets*, 12(4): 239-245.
7. Marks J (2012). *A guide to the vitamins: their role in health and disease*. SSBM, pp.:3-31.
8. Aufderheide A, Rodriguez-martin C (2006). *The Cambridge encyclopedia of human paleopathology*. CUP, pp.: 175-417.
9. Ortner D J (2003). *Identification of pathological conditions in human skeletal remains*. Smithsonian Institution NMNH, pp.: 153-268.
10. Gracia-Tellez A, Arsuaga JL, Martinez I, et al (2013). Orofacial pathology in Homo heidelbergensis: The case of Skull 5 from the Sima de los Huesos site (Atapuerca, Spain). *Quat Int*, 295: 83-93.
11. Buck LT, Stringer CB (2014). Homo heidelbergensis. *Curr Biol*, 24 (6): R214-5.
12. Godswill A G, Somtochukwu I V, Ikechukwu A O et al (2020). Health benefits of micronutrients (vitamins and minerals) and their associated deficiency diseases: A systematic review. *Int J Food Sci Nutr*, 3 (1): 1-32.
13. Botelho J, Machado V, Proenca L et al (2020). Vitamin D deficiency and oral health: a comprehensive review. *Nutrients*, 12 (5): 1471.
14. Amano Y, Komiyama K, Makishima M (2009). Vitamin D and periodontal disease. *J Oral Sci*, 51 (1): 11-20.
15. Riga A, Boggioni M, Papini A et al (2020). In situ observations on the dentition and oral cavity of the Neanderthal skeleton from Altamura (Italy). *PLoS One*, 15(12): e0241713.
16. Heim JL (1976). *Les hommes fossils de la ferrassiel*. Arch Inst paleontol Hum, pp.: 1-331.
17. Lacy SA (2014). *Oral health and its implications in Late Pleistocene western Eurasian humans*. Doctoral disertatin, washington university inst. Louis, pp.: 6-177.
18. Jensen TZT, Niemann J, Iversen K H et al (2019). A 5700 years old human genome and oral microbiome from chewed birch pitch. *Nat Commun*, 10(1): 5520.
19. Charlier P, Gaultier F, Hery-Arnaud G (2019). Interbreeding between Neanderthals and modern humans: remarks and methodological dangers of a dental calculus microbiome analysis. *J Hum Evol*, 126: 124-126.