

Case Report

Rapid Progression of Intracranial Dural Metastases in a Patient with Carcinoma of Unknown Primary Site

Hiroyuki Takeda^a Rintaro Ohe^b Tadahisa Fukui^a Shuhei Suzuki^a
Sho Nakamura^{a, c} Kaname Watanabe^a Takashi Yoshioka^a

^aDepartment of Clinical Oncology, Yamagata University Faculty of Medicine, Yamagata, Japan; ^bDepartment of Pathological Diagnostics, Yamagata University Faculty of Medicine, Yamagata, Japan; ^cCancer Prevention and Control Division, Kanagawa Cancer Center Research Institute, Yokohama, Japan

Keywords

Dural metastases · Carcinoma of unknown primary site · Prognosis · Chemotherapy

Abstract

Dural metastases are uncommon in cancer patients, but can have as much of an effect on the lives of patients as brain metastases. Dural metastases are most commonly associated with primary cancers of the breast, prostate, and lung, and it is rare that the primary site of the tumor is unknown. In this study, we encountered a 51-year-old woman who had developed multiple bone tumors, with no known primary cancer lesion. A tumor biopsy of the sacral bone revealed non-keratinizing squamous cell carcinoma; the patient was therefore diagnosed as having multiple bone metastases of an unknown primary cancer. Magnetic resonance imaging revealed cranial metastases and partial thickening of the dura with suspected dura metastases. Platinum-based chemotherapy reduced the bone metastases and the thickened dura. However, as resistance to chemotherapy developed, invasions progressed rapidly and diffusely throughout the dura. This was accompanied by the development of dysarthria, visual impairments, and delirium. The patient died 10 months after being diagnosed with dural metastases. This report provides information on the clinical course and prognosis of patients with dural metastases of unknown primary cancer. Furthermore, it may help to construct a treatment strategy for dural metastases.

© 2019 The Author(s)
Published by S. Karger AG, Basel

Introduction

Intracranial metastases are common in cancer patients, most often of the brain, but meningeal and dural metastases can also occur [1]. Dural metastases are found in approximately 9% of cancer patients on autopsy [2, 3]. However, symptomatic dural metastases have only been reported retrospectively and therefore their rate of occurrence is still unclear. Dural metastases may cause headaches, cranial nerve symptoms, visual impairments, mental symptoms and convulsions [1]. Dural metastases are thought to be caused by direct invasion from cranial or hematogenous metastases. The primary cancers most often associated with dural metastases are breast, prostate and lung cancers [1]. Cancers of an unknown primary site (metastatic tumors from an unidentified primary site) that cause dural metastases are rare [4]. To the best of the authors knowledge, there have been no case reports of unknown primary cancers in which dural metastases contributed to symptoms and prognosis. The worsening of dural metastases with cancer of an unknown primary site is therefore a largely an uncharacterized process. In this study, we report a patient with an unknown primary cancer whose symptoms worsened due to rapid progression of dural metastases.

Case Presentation

A 51-year-old woman was admitted with back pain, dysuria, and dyschezia. Her medical history included salivary gland pleomorphic adenoma, parathyroid adenoma, and ovarian dermoid cyst. Spinal magnetic resonance imaging (MRI) showed multiple bone metastases including sacral metastases which were implicated in cauda equina syndrome. Computed tomography (CT) and positron emission tomography (PET) showed no primary tumor lesions other than bones of the whole body. Various screening examinations were performed, including urinalysis, esophagogastroscope, colonoscopy, and mammography, but the primary tumor could not be identified. The sacral tumor biopsy results indicated non-keratinized squamous cell carcinoma based on positive immunohistochemical staining of the tumor cells for CK 5/6 and CK 7, and negative staining for CK 20, ER, PgR, p40, TTF-1, and GCDPF-15 (Fig. 1). Cephalic MRI detected partial thickening of the dura membrane adjacent to the calvarial metastases and to the masses protruding from the cranial base to the middle cranial fossa (Fig. 2a). There were no brain parenchyma metastases or leptomeningeal metastases. Whilst tumor markers CA125 and CYFRA were elevated, soluble interleukin-2 receptor and other tumor markers were not. We therefore concluded that the patient had carcinoma of an unknown primary site with no visceral metastases but multiple bone and dural metastases.

The patient received platinum-based chemotherapy (carboplatin 5 AUC and paclitaxel 175 mg/m², every 3 weeks), and palliative radiotherapy (30 Gy/10 fr) for the sacral tumors [5]. One month after treatment, the thickened dura became thinner and back pain and bladder rectal disorder improved to some extent. Unfortunately, paclitaxel allergy occurred during the second cycle of chemotherapy, so paclitaxel was changed to docetaxel (60 mg/m², every 3 weeks) [6]. However, she also developed docetaxel allergy during the second cycle. Therefore, docetaxel was changed to S-1 (tegafur-gimeracil-oteracil, 80 mg/m² on day 1–14, every 3 weeks) [7]. After four cycles of the carboplatin plus S-1 regimen, CT and MRI examinations showed progression of bone metastases and middle cranial fossa masses. Consequently, a single gemcitabine treatment was administered for palliative chemotherapy. After two months, the patient experienced dysarthria and nausea, at which point cranial MRI detected diffuse thickening of the dura membrane which indicated rapid progression of the dural metastases

(Fig. 2b). To alleviate symptoms, whole brain irradiation was started. Immediately after the start of irradiation, the patient experienced visual loss and delirium; thus, it became difficult to continue the treatment. The patient was transferred to a palliative care unit at another hospital and died within a month. The survival time from diagnosis of dural metastases was 10 months.

Discussion

The case of an unknown primary cancer patient whose symptoms have worsened due to dural invasion from the skull metastases is discussed here. The dural metastases in this case started with partial dural thickening at the site consistent with skull metastases, and was followed by a rapid process of progression. Therefore, it is considered that the deterioration of dural metastasis determined the prognosis of this patient.

Dural metastases are caused by hematogenous metastases or direct invasion from the cranial metastases [1, 3]. The process of deterioration in cases of dural metastases includes local exacerbation and progression of lesions to distant dura, cerebral parenchyma, and leptomeninges [1]. In addition, cases of subdural hemorrhage from dural metastases have also been reported [3, 8]. The dural metastases in our patient began with a partial thickening of the dura and developed diffusely throughout the dura within 2 months after developing resistance to chemotherapy. Simultaneously, symptoms of dysarthria, visual impairment, and delirium appeared. Thus, the cancer in our patient was thought to have rapidly progressed to the leptomeninges and cerebral parenchyma by direct invasion from cranial metastases.

The survival time from the diagnosis of dural metastases in this patient was 10 months. In a report summarizing patients with dural metastases in various cancer types, the median survival time was 9.5 months [1]. On the contrary, the median survival time of patients with carcinomas of an unknown primary site, which have poor prognosis, is approximately 6 months [4, 9]. However, for squamous cell carcinomas of an unknown primary site, the median survival time is reported to be 10 months [10]. Thus, the prognosis of our patient was similar to that reported in these previous reports. The patient had a similar prognosis as that of other cancers of an unknown primary site because of the effect of chemotherapy, as the dural metastases were not affected by the blood-brain barrier [11]. Therefore, we believe that it is possible to use published prognostic data to predict the prognosis of patients with carcinomas of an unknown primary site with dural metastases.

Although the utility of radiation therapy in cases of dural metastases has not yet been proven, several reports have suggested its usefulness. A retrospective review of 122 patients with dural metastases reported that although not statistically significant, radiation therapy tended to prolong the survival of patients [1]. Additionally, in a report of eight breast cancer patients with dural metastases who received whole-brain irradiation, no deterioration was observed in any of the patients [12]. In our patient, chemotherapy was given priority over radiotherapy since the dural metastases were partial and there were no symptoms of the central nervous system being affected at the time of diagnosis. However, radiation therapy commenced after the onset of symptoms and could not be completed; the patient died without gaining any benefit from radiation therapy. Since both chemotherapy and radiation therapy can be effective for dural metastases, treatment management should be conducted so that the patients do not miss any treatment opportunities.

This case report shows the rapid progression of dural metastases in a patient with carcinoma of an unknown primary site. The fact that dural metastases may indicate rapid

progression emphasizes the importance of developing a therapeutic strategy that does not miss the optimal timing for treatment. The treatment strategy should include aggressive chemotherapy and radiotherapy prior to the development of neurological symptoms of dural metastases. We believe that this case report will help in understanding the clinical course of dural metastases in carcinoma of an unknown primary site or possibly other cancers, and will contribute to the improvement in survival time and quality of life of patients.

Statement of Ethics

Ethical approval for disclosure was obtained from the patient.

Disclosure Statement

The authors have no conflicts of interest to disclose.

Funding Sources

The authors received no financial support for this study.

References

- 1 Nayak L, Abrey LE, Iwamoto FM. Intracranial dural metastases. *Cancer*. 2009 May;115(9):1947–53.
- 2 Meyer PC, Reah TG. Secondary neoplasms of the central nervous system and meninges. *Br J Cancer*. 1953 Dec;7(4):438–48.
- 3 Laigle-Donadey F, Taillibert S, Mokhtari K, Hildebrand J, Delattre JY. Dural metastases. *J Neurooncol*. 2005 Oct;75(1):57–61.
- 4 Pavlidis N, Pentheroudakis G. Cancer of unknown primary site. *Lancet*. 2012 Apr;379(9824):1428–35.
- 5 Briasoulis E, Kalofonos H, Bafaloukos D, Samantas E, Fountzilas G, Xiros N, et al. Carboplatin plus paclitaxel in unknown primary carcinoma: a phase II Hellenic Cooperative Oncology Group Study. *J Clin Oncol*. 2000 Sep;18(17):3101–7.
- 6 Greco FA, Erland JB, Morrissey LH, Burris HA 3rd, Hermann RC, Steis R, et al. Carcinoma of unknown primary site: phase II trials with docetaxel plus cisplatin or carboplatin. *Ann Oncol*. 2000 Feb;11(2):211–5.
- 7 Tsuya A, Kurata T, Tamiya A, Okamoto I, Ueda S, Sakai D, et al. A phase II study of cisplatin /S-1 in patients with carcinomas of unknown primary site. *Invest New Drugs*. 2013 Dec;31(6):1568–72.
- 8 Bergmann M, Puskas Z, Kuchelmeister K. Subdural hematoma due to dural metastasis: case report and review of the literature. *Clin Neurol Neurosurg*. 1992;94(3):235–40.
- 9 Losa F, Soler G, Casado A, Estival A, Fernández I, Giménez S, et al. SEOM clinical guideline on unknown primary cancer (2017). *Clin Transl Oncol*. 2018 Jan;20(1):89–96.
- 10 Hemminki K, Bevier M, Hemminki A, Sundquist J. Survival in cancer of unknown primary site: population-based analysis by site and histology. *Ann Oncol*. 2012 Jul;23(7):1854–63.
- 11 Oechsle K, Lange-Brock V, Kruell A, Bokemeyer C, de Wit M. Prognostic factors and treatment options in patients with leptomeningeal metastases of different primary tumors: a retrospective analysis. *J Cancer Res Clin Oncol*. 2010 Nov;136(11):1729–35.
- 12 Sakaguchi M, Maebayashi T, Aizawa T, Ishibashi N. Whole-brain Radiation Therapy for Breast Cancer Patients with Dural Metastasis Without Concomitant Brain Metastasis and Leptomeningeal Metastasis. *Anticancer Res*. 2018 Nov;38(11):6405–11.

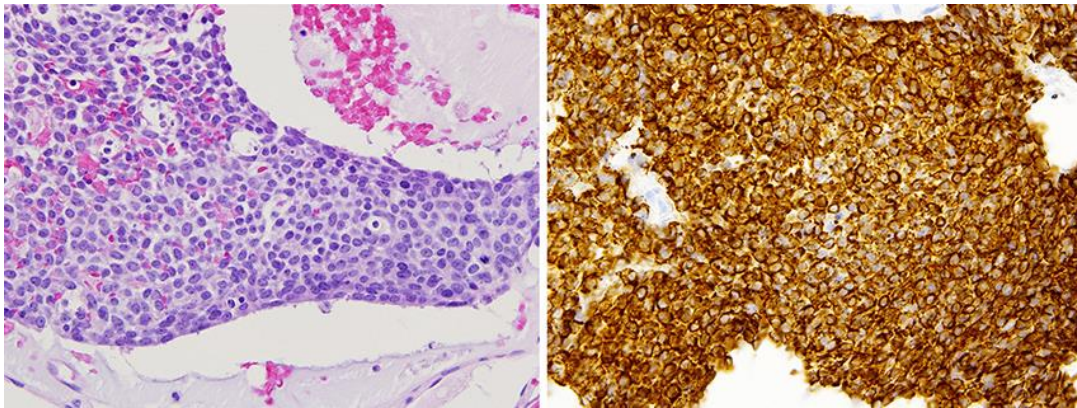


Fig. 1. Pathological images are shown. In hematoxylin-eosin staining, proliferation of poorly differentiated cells with a high nuclear-cytoplasmic ratio is observed. Immunostaining for CK 5/6 is positive.

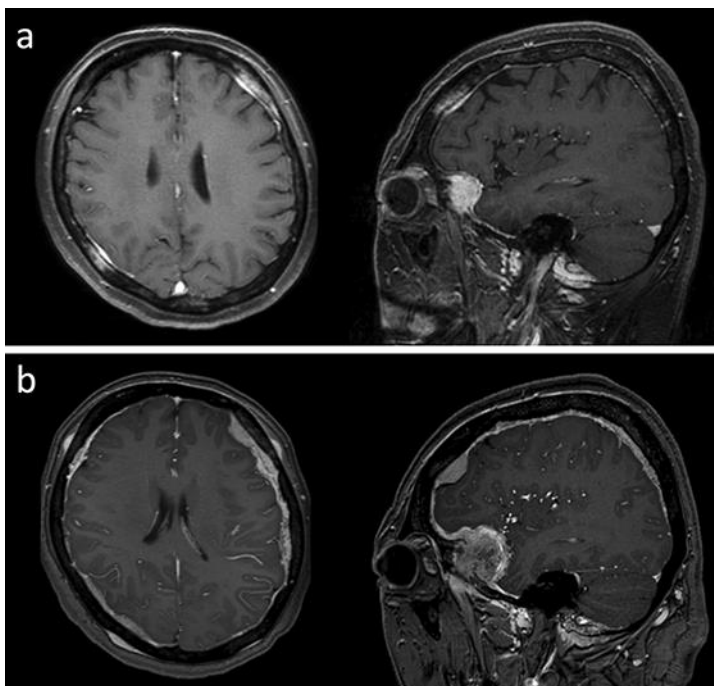


Fig. 2. Brain MR images, (a) when the patient was diagnosed with dural metastases and (b) when the patient developed dysarthria and was hospitalized. Dural metastases indicated diffuse progression in a short period of time.