

Thermal therapy for Sporothrix endogenous endophthalmitis of the anterior segment

Brian Chou, K. Matthew McKay, Thellea K. Leveque*

Department of Ophthalmology, University of Washington, Box 359608 325 Ninth Ave Seattle, WA, 98104-2499, USA

ARTICLE INFO

Keywords:

Sporothrix shenkii
Endophthalmitis
Endogenous endophthalmitis
Sporothrix endophthalmitis
Thermal therapy
Heat therapy

ABSTRACT

Purpose: To report a case of *Sporothrix shenkii* endophthalmitis successfully treated with local thermal therapy after failure of conventional systemic and local antifungal therapy.

Observations: A 44-year-old female on long-term immunosuppressive therapy for extrapulmonary sarcoidosis presented with bilateral *Sporothrix shenkii* endophthalmitis. Despite prolonged systemic antifungal therapy, numerous intraocular antifungal injections, and surgical intervention with vitrectomy and lensectomy, her condition worsened with progressively increased fungal burden in the anterior chamber. At the patients request, interventional ocular procedures including intraocular injections were withdrawn and enucleation was considered secondary to pain and severe scleral thinning. Local thermal therapy was initiated as a palliative measure, supported by evidence for *Sporothrix* growth inhibition above 38.5 °C and efficacy with cutaneous *Sporothrix*. Initiation of ocular thermal therapy with a commercially available electronic heat mask was followed by a dramatic and durable improvement in pain and fungal burden.

Conclusions and Importance: Thermal therapy may be an effective alternative for *Sporothrix* endophthalmitis affecting the anterior segment with lower risk for toxicity than intraocular injection of antimicrobial therapy.

1. Introduction

Sporotrichosis is a mycosis with worldwide distribution caused by *Sporothrix schenckii*. Infection is generally associated with traumatic inoculation in the presence of organic matter. Hematogenous spread and extracutaneous manifestations are generally limited to immunocompromised patients. Endogenous *Sporothrix* endophthalmitis is a rare entity, with 10 cases reported between 1960 to 2016.¹ Posterior segment involvement is common, though isolated granulomatous anterior uveitis is a reported clinical entity.² Systemic and local antifungal therapy may be effective, though rates of irreversible vision loss are high.¹ Here we report a case of anterior segment endogenous *Sporothrix* endophthalmitis in an immunocompromised patient. After failure of systemic and local antifungal therapy, we report a dramatic and durable response with ocular thermal therapy using a commercially available electronic heat mask.

2. Case report

A 44-year-old female with a history of cutaneous sarcoidosis on long-

term methotrexate at 15mg weekly and prednisone between 20mg and 60mg daily presented with worsening skin lesions, bilateral eye pain and decreased vision. Cutaneous sarcoidosis was diagnosed by skin biopsy more than 1 year prior after she developed multiple hypopigmented facial papules up to 6mm in diameter. Despite initial improvement of her facial lesions, she ultimately developed new lesions of her face, torso, and extremities with areas of ulceration (Fig. 1 A and B). Skin lesion and peripheral blood cultures ultimately grew *Sporothrix shenkii* resistant to voriconazole and the patient was started on systemic amphotericin, followed by itraconazole. No source of inoculation could be identified.

On presentation to ophthalmology, best corrected visual acuity was 20/20 in both eyes, and intraocular pressure was 11 and 32 mmHg in the right and left eyes, respectively. Slit lamp examination demonstrated bilateral conjunctival injection and granulomatous keratic precipitates. The left eye had low grade anterior chamber and anterior vitreous cell while the right eye had no inflammatory cells. Dilated fundus examination revealed a single inactive punctate gray choroidal lesion in each eye with sharply demarcated borders and no associated vitreous inflammation.

Despite systemic antifungal therapy and topical steroids, anterior

* Corresponding author. Department of Ophthalmology, University of Washington, Box 359608 325 Ninth Ave Seattle, WA, 98104-2499, USA.

E-mail addresses: bwc885@uw.edu (B. Chou), kmmckay@uw.edu (K.M. McKay), leveque@uw.edu (T.K. Leveque).

<https://doi.org/10.1016/j.ajoc.2022.101257>

Received 21 March 2021; Received in revised form 26 September 2021; Accepted 13 January 2022

Available online 20 January 2022

2451-9936/© 2022 Published by Elsevier Inc. This is an open access article under the CC BY-NC-ND license (<http://creativecommons.org/licenses/by-nc-nd/4.0/>).

segment inflammation and vision worsened over 1 month. An iris nodule of the right eye (Fig. 1C) and iris nodules and hypopyon of the left eye developed with absent posterior segment inflammation. Left eye diagnostic anterior chamber paracentesis confirmed *Sporothrix schenckii* on fungal PCR. Over the ensuing three months, the patient received numerous ocular injections of amphotericin. Intravitreal injection of the left eye was initially attempted but the patient declined further intravitreal therapy due to pain. In total, the patient received 17 amphotericin injections in the left eye (intravitreal: 3, intracameral: 6, and subconjunctival: 8) and 6 in the right eye (intracameral: 5 and subconjunctival: 1) with partial clinical response followed by recurrence. Four months after initial presentation, scleral thinning, anterior chamber shallowing and lens-cornea touch prompted pars plana vitrectomy and lensectomy with amphotericin injection of the left eye. In the post-operative period, a large anterior segment mass similar in appearance to prior fungal nodules underwent rapid growth associated with severe pain (Fig. 2B). At the patients request, interventional ocular procedures including intraocular injections were withdrawn and enucleation of the left eye was considered secondary to pain and severe scleral thinning. Systemic therapy was continued without change. Local thermal therapy was proposed as a palliative measure, supported by evidence for *Sporothrix* growth inhibition above 38.5 °C and efficacy with cutaneous *Sporothrix*.³ Initiation of ocular thermal therapy with a commercially available electronic heat mask (Heated Eye Mask, Esonmus USB Sleep Mask, temperature range 43–60 °C) was followed by a dramatic and durable improvement in pain and fungal burden. The patient was instructed to apply the maximum tolerated temperature for 45 minutes of every hour during the day and continuously at night. The patient experienced a rapid improvement in pain. Her conjunctival injection nearly resolved, and the size of the presumed fungal mass in her anterior chamber visibly decreased in size within 2 weeks. After 1 month, the patient decreased day time thermal therapy to about 30 minutes of every 1 hour and despite this tapering of therapy, complete resolution of the

anterior segment mass was achieved within 2 months. Three months after initiation, thermal therapy was transitioned to night time use only. Resolution of any evident fungal disease was maintained at 6 months (Fig. 2D) and at 1 year, with visual acuity improving to 20/400 (measured aphakic).

3. Discussion

We present a rare case of *Sporothrix* endogenous endophthalmitis of the anterior segment and describe a novel treatment with thermal therapy. Consistent with previous reports, this case highlights the increased risk of disseminated Sporotrichosis in hosts with impaired immunity and potential for devastating visual outcomes despite antifungal therapy.¹ Skin manifestations observed in this case were characteristic of cutaneous disseminated sporotrichosis, a rare entity typically seen in immunocompromised hosts.³ Our patient demonstrated progressive ocular disease despite extensive systemic and local antifungal therapy. Only after initiation of local thermal therapy was a durable response achieved despite discontinuation of intraocular antifungal injections and unchanged systemic antifungal therapy.

Thermal therapy (42–43 °C) has been used to effectively treat cutaneous sporotrichosis in pregnant women for whom specific antifungals are contraindicated.⁴ Animal models support this, with greater clearance of the fungus at 40 °C compared to 37 °C.⁵ The isolated anterior segment disease in this case may be more amenable to thermal therapy than cases with posterior involvement as the temperature gradient moving towards the posterior segment is unknown.

4. Conclusions

Thermal therapy may be an effective alternative for *Sporothrix* endophthalmitis affecting the anterior segment with lower risk for toxicity than intraocular injection of antimicrobial therapy.

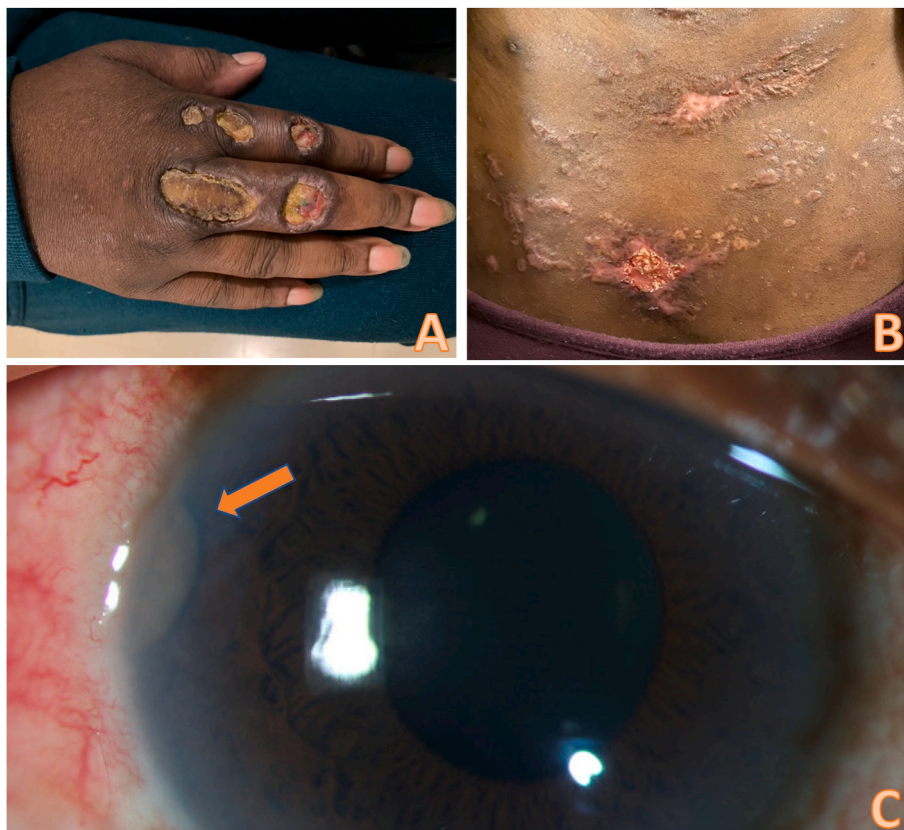

Fig. 1. Active skin lesions of A: right hand and B: upper chest. C: Iris nodule right eye.

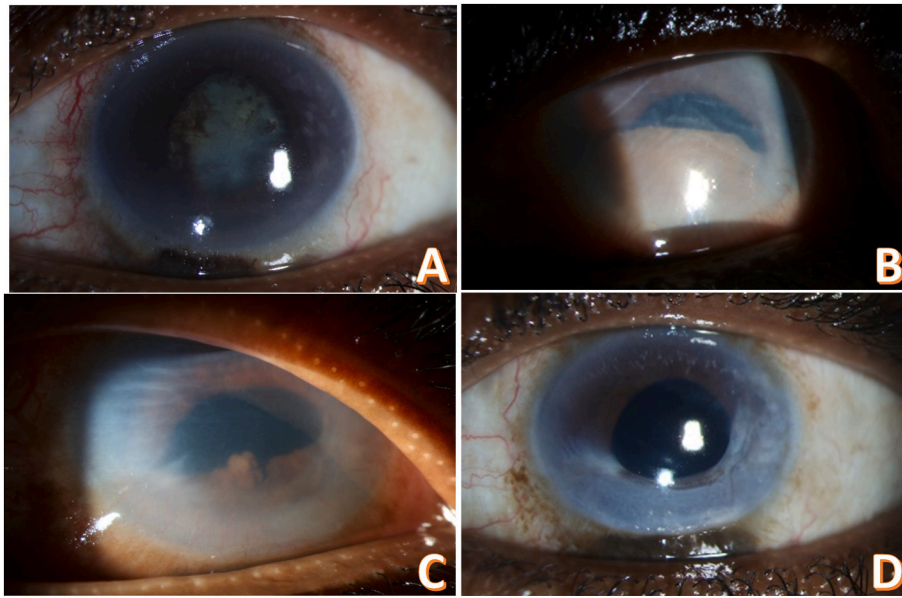


Fig. 2. A: Cataract formation and extensive anterior segment fungal debris prior to pars plana vitrectomy and lensectomy and prior to initiation of thermal therapy. B: After pars plana vitrectomy there was rapid development of a large anterior chamber fungal ball. C: Reduction in anterior chamber disease burden 1 month after initiation of thermal therapy. D: Complete resolution of anterior chamber disease after 3 months with thermal therapy.

Patient consent

Consent to publish the case report was not obtained. This report does not contain any personal information that could lead to the identification of the patient.

Authorship

All authors attest that they meet the current ICMJE criteria for Authorship.

CRediT analysis

Thellea Leveque: Conceptualization, Methodology, writing-review and editing, data curation; **Brian Chou:** Writing Original draft; **Matt McKay:** writing-review and editing, data curation.

Intellectual property

We confirm that we have given due consideration to the protection of intellectual property associated with this work and that there are no impediments to publication, including the timing of publication, with respect to intellectual property. In so doing we confirm that we have followed the regulations of our institutions concerning intellectual property.

Research ethics

We further confirm that any aspect of the work covered in this manuscript that has involved human patients has been conducted with the ethical approval of all relevant bodies and that such approvals are acknowledged within the manuscript.

IRB approval was obtained (required for studies and series of 3 or

more cases).

Written consent to publish potentially identifying information, such as details or the case and photographs, was obtained from the patient(s) or their legal guardian(s).

Funding

This work is supported by an unrestricted departmental grant from the Research to Prevent Blindness.

Declaration of competing interest

The following authors have no financial disclosures: BC, KMM, TKL.

Acknowledgements

Funding: Dr. McKay is the Gensheimer Fellow in Ocular Inflammatory Disease at the University of Washington, no other acknowledgements.

References

- Ramirez Soto MC. Difference in clinical ocular outcomes between exogenous and endogenous endophthalmitis caused by *Sporothrix*: a systemic review of published literature. *Br J Ophthalmol*. 2018;102:977–982.
- Cartwright MJ, Promersberger M, Stevens GA. *Sporothrix schenckii* endophthalmitis presenting as granulomatous uveitis. *Br J Ophthalmol*. 1993 Jan;77(1):61–62.
- Bonifaz A, Tirado-Sánchez A. Cutaneous disseminated and extracutaneous sporotrichosis: current status of a complex disease. *J Fungi*. 2017 Mar;3(1):6.
- Kauffman CA, Bustamante B, Chapman SW, Pappas PG. Clinical practice guidelines for the management of sporotrichosis: 2007 update by the Infectious Diseases Society of America. *Clin Infect Dis*. 2007;45:1255–1265.
- Barros MB, Paes R, Schuback AO. *Sporothrix schenckii* and sporotrichosis. *Clin Microbiol Rev*. Oct. 2011:633–654.