



Clinical Outcomes of Surgical Repair with a Composite Graft for Abdominal Aortic Aneurysm Accompanied by Iliac Artery Aneurysm

Bongyeon Sohn, M.D., Hak Ju Kim, M.D., Hyoung Woo Chang, M.D., Ph.D., Jae Hang Lee, M.D., Ph.D., Dong Jung Kim, M.D., Jun Sung Kim, M.D., Ph.D., Cheong Lim, M.D., Ph.D., Kay Hyun Park, M.D., Ph.D.

Department of Thoracic and Cardiovascular Surgery, Seoul National University Bundang Hospital, Seoul National University College of Medicine, Seongnam, Korea

ARTICLE INFO

Received April 8, 2020

Revised June 26, 2020

Accepted July 1, 2020

Corresponding author

Kay Hyun Park

Tel 82-31-787-7141

Fax 82-31-787-4050

E-mail 00913@snuh.org

ORCID

<https://orcid.org/0000-0002-1111-9627>

[†]This study was presented at the 51st Annual Meeting of the Korean Society of Thoracic and Cardiovascular Surgery in Changwon, Republic of Korea, October 24–26, 2019.

Background: Iliac artery aneurysm is frequently found in patients undergoing surgical repair of an abdominal aortic aneurysm. The use of commercial bifurcated grafts is insufficient for aorto-biiliac replacement with complete iliac artery aneurysm resection. We evaluated the effectiveness of handmade composite grafts for this purpose.

Methods: A total of 233 patients underwent open surgery for abdominal aortic aneurysm between 2003 and 2019, including 155 patients (67%) treated with commercial grafts and 78 patients (33%) treated with handmade composite grafts. Their operative characteristics, postoperative outcomes, and late outcomes were retrospectively reviewed.

Results: The early mortality rate did not differ significantly between the groups. On average, the handmade composite graft technique took approximately 15 minutes longer than the commercial graft technique ($p=0.037$). Among patients who underwent elective surgery, no significant differences between the conventional and composite groups were observed in the major outcomes, including red blood cell transfusion volume (2.8 ± 4.7 units vs. 3.1 ± 4.7 units, respectively; $p=0.680$), reoperation for bleeding (2.7% vs. 3.1%, respectively; $p>0.999$), bowel ischemia (0% vs. 1.6%, respectively; $p=0.364$), and intensive care unit stay duration (1.9 ± 6.6 days vs. 1.6 ± 2.4 days, respectively; $p=0.680$). The incidence of target vessel occlusion also did not differ significantly between groups.

Conclusion: The increased technical demand involved with handmade composite grafting did not negatively impact the outcomes. This technique may be a viable option because it overcomes problems associated with commercial grafts.

Keywords: Abdominal aorta, Aneurysm, Iliac aneurysm, Graft

Introduction

The use of endovascular aortic repair (EVAR) in the treatment of patients with abdominal aortic aneurysms (AAAs) is increasing. In previous studies, no significant differences in all-cause mortality were observed between endovascular and open repair [1-3]. However, the limitations of EVAR become noticeable when patients lack suitable vascular anatomy.

As reported in the literature, up to 20% of AAA patients have large common iliac arteries, and open repair is recommended for these patients [4]. The aim of surgical treat-

ment for AAA accompanied by iliac artery aneurysm is complete resection of the dilated abdominal aorta and iliac arteries to prevent further growth and rupture. A concern with these operations is that the use of commercial bifurcation grafts frequently creates a size mismatch. Therefore, it is often necessary to modify the surgical technique and graft configuration. Aggressive resection of dilated iliac arteries and the use of handmade composite grafts to maintain native perfusion have been the procedures of choice at our center; therefore, in the present study, we aimed to evaluate the technical complexity, safety, and outcomes associated with various graft configurations used to



repair AAA accompanied by iliac artery aneurysm.

Methods

Patient characteristics

Between August 2003 and July 2019, 233 patients underwent open surgery for AAA at Seoul National University Bundang Hospital. The medical records of these patients

were reviewed to identify the details of the surgical procedures and postoperative outcomes. The Institutional Review Board of Seoul National University Bundang Hospital approved this research and waived the requirement for informed consent (IRB approval no., B-2001-589-104). The mean patient age was 71.5 ± 10.3 years, and 196 of the patients (84%) were male. The baseline characteristics of the enrolled patients are summarized in Table 1.

Surgical procedures and strategy

The surgical approaches used included median laparotomy incision in most cases, left thoracoabdominal incision in 23 cases (9.9%), and additional sternotomy incision due to combined coronary artery bypass grafting in 2 cases. We classified the graft strategies used as AAA repair using commercial straight or bifurcated grafts (termed the conventional group; $n=155$, 67%) and handmade composite grafting using multiple vascular grafts to manage graft-vessel size mismatch (termed the composite group; $n=78$, 33%). Our strategy for AAA patients is summarized in Fig. 1. The operative technique was selected based on the location of the aneurysm and the condition of the vessels at the anastomotic site. When the external iliac artery (EIA) or internal iliac artery (IIA) was larger than 20 mm or the patient had a porcelain common iliac artery (CIA), we used handmade composite grafts for separate anastomosis of the EIA or IIA. When the EIA and IIA exhibited no aneurysmal change, but the CIA was enlarged (greater than 25 mm) or a size mismatch of greater than 6 mm between the graft and the native artery was present, we performed distal anastomosis at the CIA using composite grafting. If the patient had no conditions that required composite grafting, conventional repair was performed. Handmade composite grafts were designed and constructed during the operation after exposing the aneurysm and determining the distal anastomotic sites. When technical difficulty was anticipated

Table 1. Preoperative characteristics (N=233)

Characteristic	Value
Age (yr)	71.5±10.3
Male-to-female ratio	196:37
Body mass index (kg/m ²)	23.7±3.4
Smoking (current)	71 (30.5)
Hypertension	158 (67.8)
Diabetes mellitus	34 (14.6)
Chronic kidney disease	27 (11.6)
Dyslipidemia	50 (21.5)
History of stroke	37 (15.9)
Chronic obstructive pulmonary disease	31 (13.3)
Coronary artery occlusive disease	94 (40.3)
Previous surgical history	
Any laparotomy procedure	8 (3.4)
Aortic surgery	17 (7.3)
EVAR	16 (6.9)
Abdominal aortic aneurysm diameter (mm)	64.3±19.8
Right CIA diameter (mm)	21.5±11.3
Left CIA diameter (mm)	19.2±9.5
CIA aneurysm ^{a)}	76 (32.6)
Etiology of aneurysm	
Atherosclerosis	197 (84.5)
Chronic aortic dissection	6 (2.6)
Mycotic aneurysm	12 (5.1)
Endoleak of EVAR	11 (4.7)
Others	7 (3.0)

Values are presented as mean±standard deviation or number (%). EVAR, endovascular aortic repair; CIA, common iliac artery. ^{a)}CIA aneurysm was defined as a CIA larger than 25 mm in diameter.

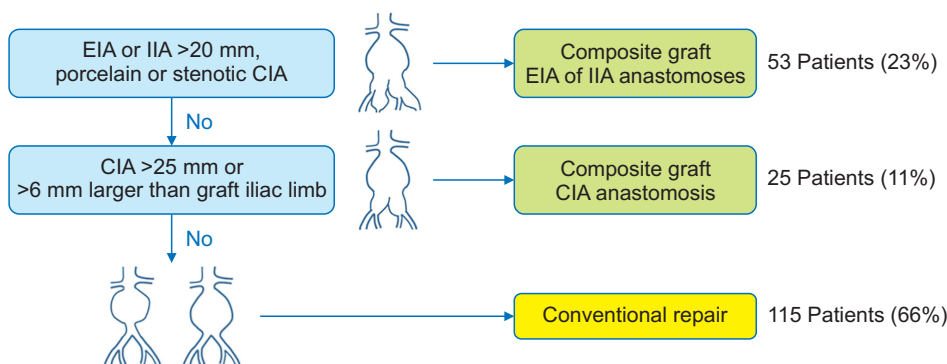


Fig. 1. Seoul National University Bundang Hospital strategy for abdominal aortic aneurysm patients. EIA, external iliac artery; IIA, internal iliac artery; CIA, common iliac artery.

ed for the distal anastomosis, such as in cases of a deep-seated IIA, massive retroperitoneal hematoma in the pelvic cavity, or severe obesity, the composite graft was not pre-sewn in advance. Instead, the graft-to-graft anastomosis was made after completion of the distal graft-to-iliac anastomosis. Surgical glue (BioGlue; CryoLife Inc., Kennesaw, GA, USA) was applied to each graft-to-graft anastomosis while the grafts were kept dry. Concomitant procedures included coronary artery bypass grafting (n=2), bowel resection (n=2), and nephrectomy (n=3) (Table 2).

Evaluation of clinical outcomes

Operative mortality was defined as any death within 30 days after surgery or during the same hospitalization as surgery. Contrast-enhanced computed tomography (CT) angiography was performed before discharge in all cases except for those of operative mortality. Postoperative follow-up was performed on an outpatient basis at regular 3- to 12-month intervals. Patients who did not visit the clinic on the scheduled date were contacted by telephone to confirm their condition. Data regarding overall and cardiovascular death were obtained from death certificates available at Statistics Korea (<http://kostat.go.kr>). Clinical follow-up ended on July 31, 2019.

Table 2. Operative data

Variable	Conventional (n=155)	Composite (n=78)	Total (N=233)
Emergency (rupture)	43 (27.7)	14 (17.9)	57 (24.5)
Distal anastomotic site			
Aorta	28 (18.1)	0	28 (12.0)
Both CIA	108 (69.7)	25 (32)	133 (57.0)
Unilateral IIA separate anastomosis	0	27 (34.6)	27 (11.6)
Both IIA separate anastomosis (quadrifurcation)	0	24 (30.8)	24 (10.3)
Both EIA (all IIA sacrificed)	3 (1.9)	0	3 (1.3)
Both femoral artery	3 (1.9)	0	3 (1.3)
CIA+EIA/FA or EIA+FA	13 (8.4)	2 (2.6)	15 (6.4)
Re-implantation of inferior mesenteric artery	12 (7.8)	7 (9.0)	19 (8.2)
Concomitant procedures			
Cardiac surgery	0	2 (2.6)	2 (0.9)
Others	4 (2.6)	1 (1.3)	5 (2.1)

Values are presented as number (%).

CIA, common iliac artery; IIA, internal iliac artery; EIA, external iliac artery; FA, femoral artery.

Statistical analysis

IBM SPSS ver. 25.0 for Windows (IBM Corp., Armonk, NY, USA) was used for the statistical analysis. The data were expressed as means±standard deviations, medians with interquartile ranges, or proportions. Comparisons of categorical and continuous variables were performed using the chi-square test or the Fisher exact test and the Student t-test or the Mann-Whitney U-test, respectively. A p-value <0.05 was considered to indicate statistical significance.

Results

Operative data and diversity of composite grafts

The various graft configurations used for surgery are described in Fig. 2. The commercially available ready-made grafts (Fig. 2A, B) and handmade composite grafts using various combinations of Dacron grafts (Fig. 2C–J) were used selectively. The procedural differences between the conventional and composite groups were noteworthy with regard to the distal anastomotic site and re-implantation of the iliac vessels. In the conventional group, 108 patients (69.7%) underwent surgery with distal anastomoses at both CIAs. Separate anastomosis of the external or internal iliac arteries was performed in 53 patients (67.9%) in the composite group. The operative data of the conventional and composite groups are shown in Table 2.

Comparison of early outcomes

Early death occurred in 12 cases (5.2%), 11 of which were rupture (emergency) cases. Major postoperative outcomes, including operative mortality, acute bowel ischemia, and massive transfusion, were significantly worse in cases involving rupture. Excluding cases of rupture (n=57, 24%), 112 patients (64%) and 64 patients (36%) were in the conventional and composite groups, respectively. When the clinical outcomes were compared based on the graft configuration among elective surgery cases, no significant difference was found between the groups in terms of early mortality (conventional, n=1 [0.9%]; composite, n=0 [0%]; p>0.999). Similarly, no significant differences were observed in the major postoperative outcomes, including bowel ischemia (conventional, n=0 [0%]; composite, n=1 [1.6%]; p=0.364), reoperation for bleeding (conventional, n=3 [2.7%]; composite, n=2 [3.1%]; p>0.999), packed red blood cell transfusion volume (conventional, 2.76±4.66 units; composite, 3.06±4.70 units; p=0.680), postoperative

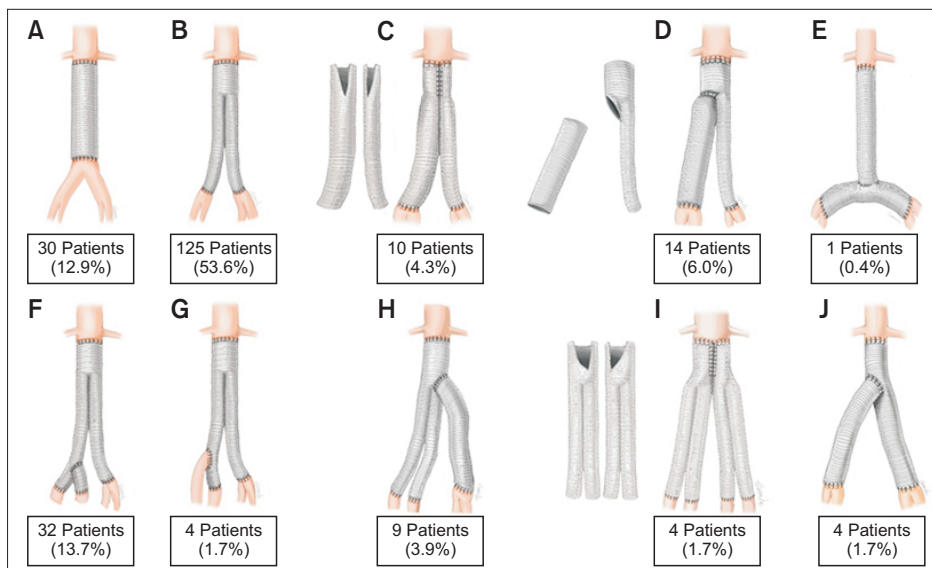


Fig. 2. (A–J) Configurations of conventional and composite grafts.

Table 3. Early clinical outcomes

Variable	Elective surgery			Emergency surgery		
	Conventional (n=112)	Composite (n=64)	p-value	Conventional (n=43)	Composite (n=14)	p-value
Early death	1 (0.9)	0	>0.999	9 (20.9)	2 (14.3)	0.714
Operation time (min)	199.2±63.1	215.9±42.7	0.037	203.1±60.4	217.1±41.9	0.422
Red blood cell transfusion volume (units)	2.8±4.7	3.1±4.7	0.680	11.5±10.4	17.9±24.9	0.361
Intensive care unit stay duration (day)	1.9±6.6	1.6±2.4	0.680	3.9±5.5	4.3±8.9	0.828
Hospital stay (day)	14.9±14.7	15.1±12.1	0.917	24.9±26.2	28.4±35.9	0.703
Nothing-by-mouth duration (day)	3.1±2.6	3.7±4.7	0.297	5.9±5.9	4.6±2.7	0.486
Bowel ischemia	0	1 (1.6)	0.364	9 (20.9)	2 (14.3)	0.714
Reoperation due to external iliac artery occlusion	5 (4.5)	2 (3.1)	>0.999	1 (2.4)	1 (7.1)	0.441
Reoperation due to bleeding	3 (2.7)	2 (3.1)	>0.999	3 (7.1)	2 (14.3)	0.590
Chyloperitoneum	2 (1.8)	3 (4.7)	0.355	3 (7.0)	0	0.568

Values are presented as number (%) or mean±standard deviation.

nothing-by-mouth duration (conventional, 3.1±2.6 days; composite, 3.7±4.7 days; p=0.297), and length of the intensive care unit stay (conventional, 46.98±158.19 hours; composite, 38.51±56.76 hours; p=0.680). The only significant difference was in operation time, as the composite graft technique took approximately 15 minutes longer on average than the conventional technique (215.9±42.7 minutes versus 199.2±63.1 minutes, respectively; p=0.037). These early outcomes were also compared in the AAA patients who underwent emergency surgery due to rupture, and the results were similar (Table 3). The only difference was that, unlike in the elective cases, the operation time was not significantly different between groups in the AAA patients who experienced rupture.

Early patency

Postoperative CT was performed before discharge in all patients except those who died perioperatively (Fig. 3). The rate of reoperation due to EIA occlusion was not significantly different between groups (conventional, n=6 [3.9%]; composite, n=3 [3.8%]; p>0.999). We used various handmade composite grafts to preserve the IIA flow, and we performed separate anastomoses of a total of 75 IIAs. The patency of the anastomoses to the IIA were evaluated using CT, and 70 of 75 anastomoses (93%) were patent in the early postoperative period.

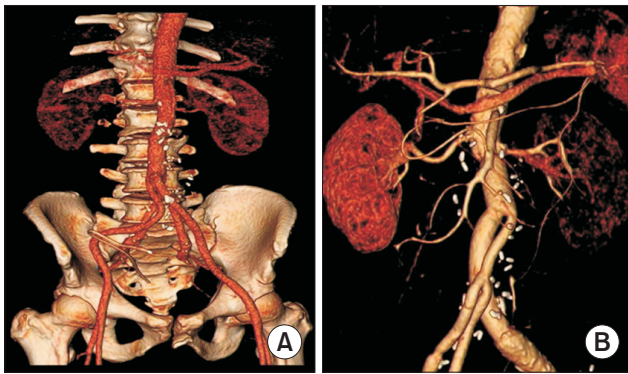


Fig. 3. Postoperative computed tomography images of the composite graft technique. (A) Quadrifurcation graft. (B) Asymmetrical/secondary Y graft.

Late outcomes

The mean follow-up duration was 4.0 ± 3.8 years. During follow-up, 84 patients (36%) underwent CT angiography beyond 1 year after surgery. Late new occlusion of the graft with the re-implanted IIA was found in 1 patient. The conventional and composite groups did not differ significantly in AAA-related readmission (conventional, $n=12$ [10.7%]; composite, $n=11$ [17.2%]; $p=0.220$) or reintervention (conventional, $n=0$ [0%]; composite, $n=2$ [3.1%]; $p=0.131$) rates. Causes of AAA-related readmission included surgical wound problems, incisional hernia, graft occlusions or infections, postoperative ileus, and other gastrointestinal problems. The indication for the 2 cases of reintervention in the composite group was vascular graft infection.

Discussion

This study had 2 main findings. First, major postoperative outcomes, including operative death, hospital course, and severe complications, were favorable in the composite graft group compared with the conventional group. Second, graft patency did not significantly vary based on graft configuration. The only disadvantage of the composite graft technique was its longer operation time. However, this included the time required to construct the patient-tailored composite graft. Therefore, the actual amount of additional time taken to perform the anastomosis using the handmade composite graft was not meaningful. Since composite grafts are usually prepared outside of the abdominal cavity, anastomosis to the aorta and iliac artery does not increase the technical difficulty relative to using a commercial bifurcated graft. As previous studies of the technical details and outcomes of such procedures are rela-

tively rare, the optimal treatment option is not well established in patients with AAA accompanied by iliac artery aneurysm. The clinical importance of this study is that we demonstrated how to address aorto-iliac aneurysms with varying vessel characteristics using patient-tailored composite grafts.

Isolated CIA aneurysms account for fewer than 2% of all aneurysms; however, they are frequently found in association with AAA as aorto-iliac aneurysms. In up to 20% of AAA patients who have large CIAs, the expansion rate of aneurysms increases significantly as the diameter increases over 3 cm [4]. The reported growth rates of iliac artery aneurysms are similar to those of AAAs, at approximately 1–4 mm/yr [5,6]. The most widely accepted definition of iliac artery aneurysm is dilatation of the vessel to more than 1.5 times its normal diameter [7], and a fairly normal distribution curve was seen in patients with CIA diameters less than 2.5 cm [4]. Therefore, we used diameter as the indication for the management of accompanying iliac artery aneurysms with composite grafts. In addition to diameter, freedom from calcification or severe atherosclerosis at the anastomotic site were crucial factors in the determination of proper graft configuration. We pursued our strategy of using handmade composite grafts because conventional repair using commercially available ready-made grafts is frequently limited not only by artery size, but also by other characteristics of the vessels. Our surgical goal was to exclude any residual iliac aneurysm and to maintain the blood supply to at least 1 IIA. We found that at least 1 IIA was saved in 229 patients (98%) via our strategy. Practitioners may have concerns about the technical complexity of preparing handmade composite grafts intraoperatively; nevertheless, only an additional 15 minutes was required on average, and postoperative morbidity or mortality were not increased.

In addition to handmade composite grafting, other techniques or modifications could be considered. One alternative is beveled anastomosis for size mismatches between the graft and the aneurysmal iliac artery. However, extreme size discrepancies are not overcome by using beveled anastomoses. If the size mismatch between the graft and target artery is greater than 6 mm (Fig. 1), beveled anastomosis is unfavorable and carries increased risks of anastomotic site bleeding and vessel occlusion. A second option is not to perform revascularization of heavily calcified or dilated iliac artery segments [8,9]. However, concerns about compromised pelvic circulation and increased risk of distal anastomotic site infection are major disadvantages of these approaches. Loss of the bilateral IIAs during AAA

repair has been associated with an increased risk of bowel ischemia [10,11]. In the presence of heavily calcified iliac arteries, an aorto-bifemoral bypass may be required. This entails femoral incisions, which are associated with a substantial risk of access-related infections [12]. Moreover, leaving the diseased artery as-is can result in progression of aneurysmal dilation [13-15]. The timing of construction of composite grafts can also be controversial. Theoretically, when high-resolution preoperative CT angiography is available, composite grafts can be prepared before surgery. This strategy reduces the operation time, which is noteworthy because an increased operation time was the only disadvantage of composite grafting identified in the present study. Obviously, however, composite grafts cannot be prepared in advance in emergency cases. Furthermore, even in elective cases, graft configuration, elongation, and length can be determined precisely based on operative findings alone. Intraoperative construction of a composite graft allows for flexible changes to the anastomosis sequence. We sometimes performed separate anastomosis of the IIA or EIA before constructing the composite graft. With this anastomotic flexibility, a favorable operative field and technical feasibility were secured.

Limitations

The present study had several limitations that must be recognized. First, this was a retrospective observational study conducted at a single institution. Second, the number of patients enrolled was relatively small. Third, because late follow-up CT evaluations were not performed in all patients, analysis of the long-term outcomes was limited. We focused on the early outcomes of our strategy.

Conclusions

The technical demands of handmade composite grafting and iliac artery anastomoses did not negatively impact the outcomes of AAA repair. We found no significant differences between the groups in terms of major postoperative outcomes, including early mortality, intensive care unit stay duration, blood transfusion volume, and rates of target vessel occlusion, bleeding, and reoperation. These findings applied to both elective and emergency cases. This technique may be an alternative to avoid aortofemoral bypass or ligation of internal iliac arteries in the repair of AAA combined with iliac artery aneurysm. In the era of endovascular aneurysm repair, using patient-tailored composite grafts may be a viable option for surgical repair of AAA

accompanied by iliac artery aneurysm.

Conflict of interest

No potential conflict of interest relevant to this article was reported.

ORCID

Bongyeon Sohn: <https://orcid.org/0000-0003-0613-8273>
 Hak Ju Kim: <https://orcid.org/0000-0003-0830-3287>
 Hyoung Woo Chang: <https://orcid.org/0000-0001-5516-0333>
 Jae Hang Lee: <https://orcid.org/0000-0003-4769-5340>
 Dong Jung Kim: <https://orcid.org/0000-0003-0332-3430>
 Jun Sung Kim: <https://orcid.org/0000-0003-4285-8200>
 Cheong Lim: <https://orcid.org/0000-0003-0913-7014>
 Kay Hyun Park: <https://orcid.org/0000-0002-1111-9627>

References

1. Lederle FA, Kyriakides TC, Stroupe KT, et al. *Open versus endovascular repair of abdominal aortic aneurysm*. N Engl J Med 2019;380:2126-35.
2. Patel R, Sweeting MJ, Powell JT, Greenhalgh RM; EVAR trial investigators. *Endovascular versus open repair of abdominal aortic aneurysm in 15-years' follow-up of the UK endovascular aneurysm repair trial 1 (EVAR trial 1): a randomised controlled trial*. Lancet 2016;388:2366-74.
3. Van Schaik TG, Yeung KK, Verhagen HJ, et al. *Long-term survival and secondary procedures after open or endovascular repair of abdominal aortic aneurysms*. J Vasc Surg 2017;66:1379-89.
4. Armon MP, Wenham PW, Whitaker SC, Gregson RH, Hopkinson BR. *Common iliac artery aneurysms in patients with abdominal aortic aneurysms*. Eur J Vasc Endovasc Surg 1998;15:255-7.
5. Santilli SM, Wernsing SE, Lee ES. *Expansion rates and outcomes for iliac artery aneurysms*. J Vasc Surg 2000;31(1 Pt 1):114-21.
6. Richards T, Dharmadasa A, Davies R, Murphy M, Perera R, Walton J. *Natural history of the common iliac artery in the presence of an abdominal aortic aneurysm*. J Vasc Surg 2009;49:881-5.
7. Johnston KW, Rutherford RB, Tilson MD, Shah DM, Hollier L, Stanley JC. *Suggested standards for reporting on arterial aneurysms. Subcommittee on Reporting Standards for Arterial Aneurysms, Ad Hoc Committee on Reporting Standards, Society for Vascular Surgery and North American Chapter, International Society for Cardiovascular Surgery*. J Vasc Surg 1991;13:452-8.
8. Hiromatsu S, Hosokawa Y, Egawa N, Yokokura H, Akaiwa K, Aoyagi S. *Strategy for isolated iliac artery aneurysms*. Asian Cardiovasc Thorac Ann 2007;15:280-4.
9. Chaer RA, Barbato JE, Lin SC, Zenati M, Kent KC, McKinsey JF.

- Isolated iliac artery aneurysms: a contemporary comparison of endovascular and open repair.* J Vasc Surg 2008;47:708-13.
10. Bosanquet DC, Wilcox C, Whitehurst L, et al. *Systematic review and meta-analysis of the effect of internal iliac artery exclusion for patients undergoing EVAR.* Eur J Vasc Endovasc Surg 2017;53:534-48.
 11. Kouvelos GN, Katsargyris A, Antoniou GA, Oikonomou K, Verhoeven EL. *Outcome after interruption or preservation of internal iliac artery flow during endovascular repair of abdominal aorto-iliac aneurysms.* Eur J Vasc Endovasc Surg 2016;52:621-34.
 12. Ploeg AJ, Lardenoye JW, Peeters MP, Hamming JF, Breslau PJ. *Wound complications at the groin after peripheral arterial surgery sparing the lymphatic tissue: a double-blind randomized clinical trial.* Am J Surg 2009;197:747-51.
 13. Dube B, Unlu C, de Vries JP. *Fate of enlarged iliac arteries after endovascular or open abdominal aortic aneurysm repair.* J Endovasc Ther 2016;23:803-8.
 14. Brown PM, Zelt DT, Sobolev B. *The risk of rupture in untreated aneurysms: the impact of size, gender, and expansion rate.* J Vasc Surg 2003;37:280-4.
 15. Lee JH, Choi JH, Kim EJ. *The influence of unfavorable aortoiliac anatomy on short-term outcomes after endovascular aortic repair.* Korean J Thorac Cardiovasc Surg 2018;51:180-6.