

CASE REPORT

Clin Endosc 2018;51:491-494
https://doi.org/10.5946/ce.2018.011
Print ISSN 2234-2400 • On-line ISSN 2234-2443



CLINICAL
ENDOSCOPY



Open Access

Removal of Esophageal Variceal Bands to Salvage Complete Esophageal Obstruction

Ala' A Abdel Jalil, Ghassan Hammoud, Jamal A Ibdah and Sami Samiullah

Division of Gastroenterology & Hepatology, University of Missouri-Columbia, Columbia, MO, USA

Esophageal varices develop in almost half of the patients with cirrhosis, and variceal hemorrhage constitutes an ominous sign with an increased risk of mortality. Variceal banding is considered an effective and mostly safe measure for primary and secondary prophylaxis. Although adverse events related to banding including dysphagia, stricture formation, bleeding, and ligation-induced ulcers have been described, complete esophageal obstruction is rare, with only 10 reported cases in the literature. Among those cases, 6 were managed conservatively; 1 patient had esophageal intraluminal dissection from an attempt to remove the bands using biopsy forceps but ultimately recovered with conservative management. Three patients developed strictures following removal of the bands, requiring repeated sessions of dilation therapy. We report on a patient who developed absolute dysphagia and complete esophageal obstruction after variceal banding. We successfully used the endoloop cutter hook to release the bands intact and restore luminal integrity.

Clin Endosc 2018;51:491-494

Key Words: Band ligation; Cirrhosis; Dysphagia; Esophageal obstruction; Endoscopy

INTRODUCTION

Portal hypertension is a progressive complication of cirrhosis, and gastroesophageal varices occur in almost half of the cirrhotic patients.¹ The risk of variceal hemorrhage increases with the presence of large varices (>5 mm), a red wale sign, and alcoholic cirrhosis, and indicates the severity of liver disease. Although the risk of first variceal hemorrhage is approximately 20%, the risk of rebleeding approaches 70%, and secondary prophylaxis becomes an important measure to mitigate such high risk.² Variceal hemorrhage continues to show a high mortality rate (20% at 6-weeks) despite advances in therapeutic measures (vasoactive medications, antibiotics, and endoscopic interventions).³ Two large meta-analyses found lower rates of

first variceal hemorrhage with use of endoscopic variceal ligation (EVL) than with β -blockade therapy, although there was no significant difference in mortality rates.^{4,5} EVL carries a risk of ligation-induced ulceration in 0.5%–3.6% of patients.⁶ Complete esophageal obstruction secondary to EVL is rare, with only 10 cases described in the literature.

CASE REPORT

A 68-year-old woman with a history of diabetes mellitus, living-donor renal transplant on current immunosuppression, and compensated cirrhosis secondary to hepatitis C genotype 1a presented for esophageal variceal surveillance. The patient had no history of variceal bleeding, encephalopathy, or ascites. Liver function indices were unremarkable. Upon her first endoscopy, 2 large columns of varices were found with high-risk stigmata of a red wale sign, and 5 bands were applied successfully. She presented to us for her third session of surveillance and 3 additional variceal bands were applied (Fig. 1A, B; before and after banding). Immediately after the procedure the patient could not swallow any liquids or secretions, with persistent spitting up of saliva admixed with small streaks of blood. Viscous

Received: December 26, 2017 **Revised:** April 10, 2018

Accepted: April 10, 2018

Correspondence: Sami Samiullah

Division of Gastroenterology & Hepatology, University of Missouri-Columbia, 1 Hospital Dr. CE 405, Columbia, MO 65212, USA

Tel: +1-573-884-6044, **Fax:** +1-573-884-4595, **E-mail:** samiullah@health.missouri.edu

ORCID: <https://orcid.org/0000-0002-1498-0527>

© This is an Open Access article distributed under the terms of the Creative Commons Attribution Non-Commercial License (<http://creativecommons.org/licenses/by-nc/3.0>) which permits unrestricted non-commercial use, distribution, and reproduction in any medium, provided the original work is properly cited.

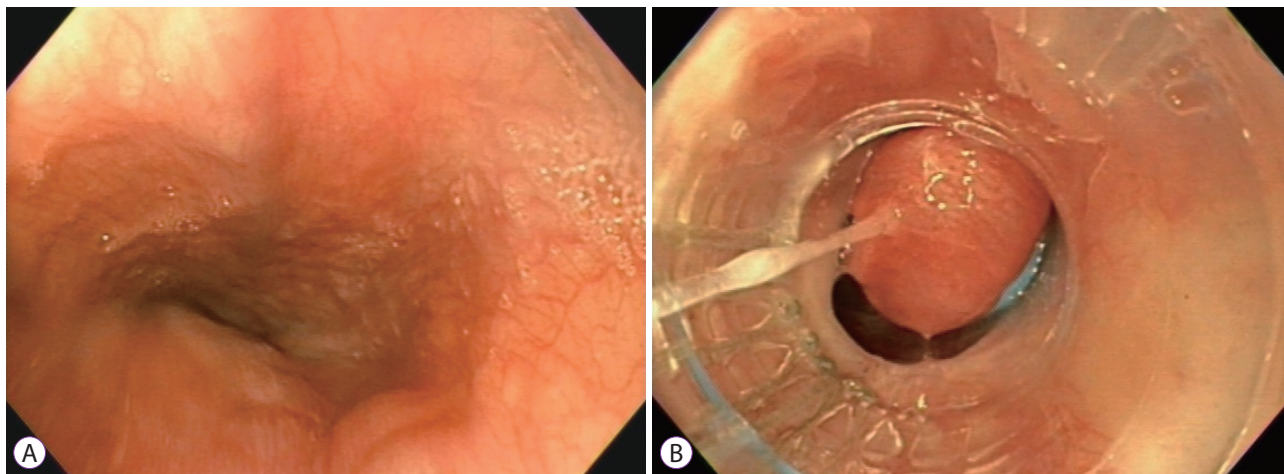


Fig. 1. (A) Pre-band ligation endoscopic image showing 2 large columns of varices in distal esophagus. (B) Post-band ligation endoscopic image.

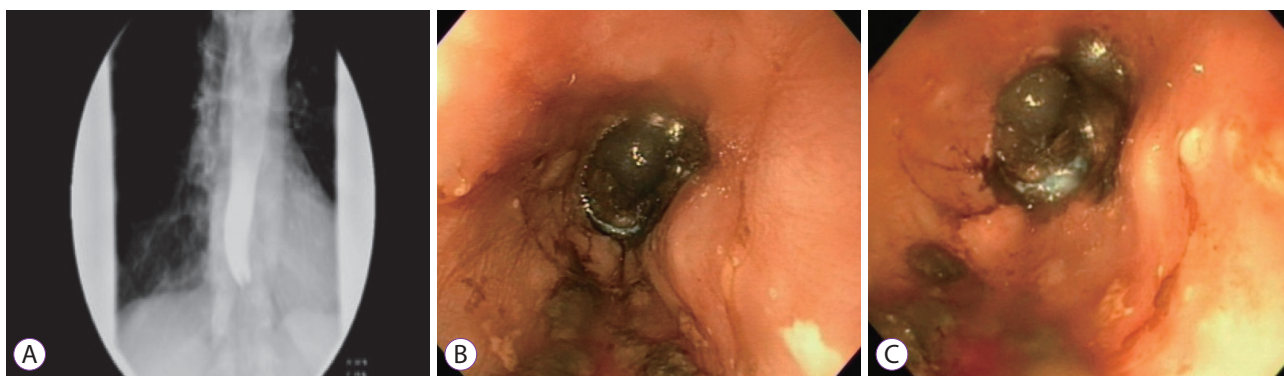


Fig. 2. (A) Barium esophagram showing complete distal esophageal obstruction. (B, C) Complete esophageal obstruction, necrotic varix with band at its base.




Fig. 3. (A, B) Endloop cutter (closed & open).

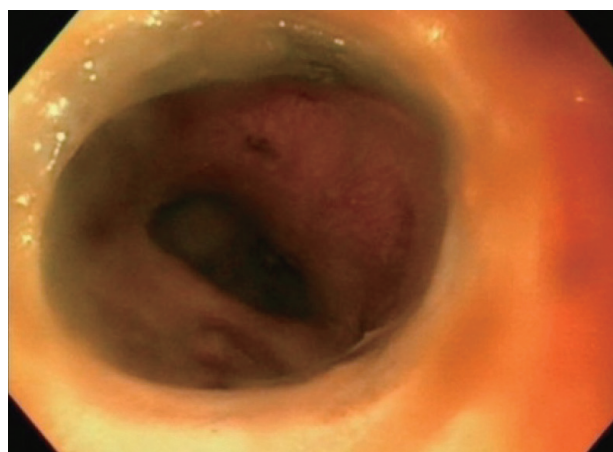


Fig. 4. Restoration of esophageal lumen after removal of variceal bands using endloop cutter hook.

lidocaine mixed with water failed to provide any relief. The patient was admitted for observation with nothing by mouth. Sucralfate was started along with proton-pump inhibitor therapy. By the second day, the patient was still unable to swallow any liquids including her own saliva. A barium esophagram showed complete obstruction of the distal esophagus (Fig. 2A). Repeat esophagogastroduodenoscopy (EGD) the following day showed pooling of saliva in the distal esophagus, which was suctioned, along with necrotic and ulcerated esophageal mucosa at the base of the banded varices causing complete luminal obstruction (Fig. 2B, C). We grasped the 3 bands with the hook of an endloop cutter (Olympus America, Melville, NY, USA) (Fig.

3A, B), and the bands were removed intact from the base of necrotic varices one-by-one without any bleeding. This restored the esophageal lumen (Fig. 4) and led to resolution of symptoms. The patient was discharged home the following day tolerating a regular diet. Upon follow-up endoscopy, scars were seen

in the area without any varices.

DISCUSSION

To date, 10 cases of complete esophageal obstruction following variceal banding have been described (Table 1).⁷⁻¹⁶ Saltzman and Arora described the first case in 1993 in a 58-year-old man who had 2 prior sessions of sclerotherapy.⁷ After the second treatment with variceal banding, the patient developed sialorrhea and chest discomfort. Repeat EGD showed impact-

ed food above edematous and swollen varices, with 4 bands in place.⁷ Elizondo-Rivera et al. reported a case in which a large nonbleeding varix was banded with over-suctioning of mucosa resulting in complete obstruction of the esophageal lumen.⁸ The patient had prior banding and at the time of index endoscopy there was evidence of scarring along with mild stenosis in the distal esophagus.⁸ Following conservative management, Nawaz et al. managed a case in 2010 in which banding small varices resulted in complete esophageal occlusion and subsequent ulcer and stricture formation.⁹ In 2011, de Melo removed an occluding band successfully using a clear cap

Table 1. Published Cases of Complete Esophageal Obstruction Secondary to Endoscopic Variceal Band Ligation

Study	Timing of symptoms	EGD	Management	Outcome
Mansour et al. (2017) ¹⁶	3 days later with nausea & vomiting.	Complete obliteration of lumen at the GEJ Esophageal band with inadvertent gastric tissue was seen	Conservative management	Distal esophageal stricture requiring 4 sessions of dilation
Maric et al. (2016) ¹⁵	Immediate nausea, vomiting, sialorrhea & dysphagia	Necrotic mucosa with luminal occlusion & retained band in mid-esophagus	Band was removed 10 days later using snare technique with minimal cautery effect to cut the band	Mild luminal narrowing status post band removal
Kwiatk et al. (2016) ¹¹	Inability to control secretions 2 hours post banding	Complete esophageal obstruction, necrotic & ulcerated tissue at banding site	Successful removal with endoloop cutter	Immediate relief of obstruction
Elizondo-Rivera et al. (2014) ⁸	Dysphagia, chest pain & vomiting (unspecified timing)	Black mucosa at banding site, complete esophageal obstruction	NPO for 7 days, liquid diet for 4 days	Tolerated regular diet after 11 days
Chahal et al. (2013) ¹²	Immediate nausea, vomiting & dysphagia	Occluded esophageal lumen with entrapped varix with surrounding necrosis	Attempt to remove band with biopsy forceps failed and complicated by esophageal intraluminal dissection	TPN for 5 days Repeat EGD concluded resolution of dissection
de Melo (2011) ¹⁰	Immediate inability to swallow water	Complete esophageal obstruction with subsequent stricture formation	Attempts to remove occluding band using forceps & snare were unsuccessful Cap-assisted technique (can opener maneuver) dislodged the band	Stricture requiring 2 sessions of TTS dilation
Nikoloff et al. (2011) ¹⁴	Immediate chest pain, dysphagia & sialorrhea	Not repeated	TPN for 1 week	Tolerated soft diet after 7 days
Nawaz et al. (2010) ⁹	Complete occlusion	Not repeated	NS	Stricture formation
Verma et al. (2009) ¹³	1 day of chest pain & inability to tolerate oral liquids	Obstructing necrotic varices with 3 bands at the periphery	TPN for 2 weeks	No complications
Saltzman et al. (1993) ⁷	Immediate chest pain & sialorrhea	Food impacted proximal to variceal bandings	NS	NS

EGD, esophagogastroduodenoscopy; GEJ, gastroesophageal junction; NPO, nil per os; TPN, total parenteral nutrition; TTS, through the scope; NS, not specified.

fitted to the gastroscope with a “can opener” maneuver, after unsuccessful attempts with snare and biopsy forceps.¹⁰

Kwiatk et al. described successful removal of a variceal band that caused complete esophageal obstruction.¹¹ After unsuccessful attempts with rat-tooth and hot biopsy forceps, the variceal band was released using an endoloop cutter to grasp the band, with immediate restoration of a patent esophageal lumen. Suctioning of the opposite esophageal walls was thought to be the cause of obstruction in this case.¹¹ A prior case of esophageal obstruction after variceal banding was complicated by intraluminal dissection in which an attempt to remove the variceal band with biopsy forceps was unsuccessful. The patient recovered with conservative management and parenteral nutrition for 5 days.¹² Two other cases managed conservatively with parenteral nutrition for 1–2 weeks had resolution of symptoms.^{13,14} Recently, a 79-year-old female with nonalcoholic steatohepatitis cirrhosis who developed acute onset of dysphagia after variceal banding was successfully managed 10 days later, using a 1.5-cm snare technique along with blended cutting current to remove the occlusive band. The patient developed mild stricture afterward, but the obstruction was relieved.¹⁵ Mansour et al. described a patient with alcoholic cirrhosis and sliding hiatal hernia, who had a portion of the gastric mucosa inadvertently entrapped within the band, resulting in complete esophageal obstruction.¹⁶ That was treated conservatively, but resulted in distal esophageal stricture requiring multiple sessions of dilation therapy.¹⁶

Dysphagia following EVL can present late as a result of stricture formation, or early because of altered esophageal motility.¹⁷ Complete esophageal obstruction can occur when the mucosa is over-suctioned, especially on opposing walls. In addition, propagation of banded varices by peristaltic effect toward a more distal stricture (Schatzki ring or stricture from prior banding) is another potential mechanism for complete esophageal obstruction after banding.

We believe the preferred method is to remove the bands, to allow prompt restoration of the lumen and alleviate symptoms of pain and obstruction. Leaving the bands could carry potential risks of post-banding ulcers, bleeding, or future stricture formation. However, removing the bands using an endoloop hook cutter is an easy and safe procedure to perform and alleviates further pain.

The endoloop hook cutter is introduced in the working channel of the endoscope. The assistant opens the hook cutter and the endoscopist maneuvers the endoscope so the band hooks onto the endoloop hook cutter. The endoscope is then advanced gently and by turning the large wheel upward, the band is lifted away. We recommend against cutting the band due to risk of accidental injury to the mucosa or nearby varices.

Prompt evaluation of patients who develop symptoms con-

cerning for esophageal obstruction after variceal band ligation is essential for timely management of this rare complication. In experienced hands, removal of variceal bands using an endoloop cutter hook is useful to promptly salvage the obstruction. Our case is the second to show successful removal of occluding bands using an endoloop cutter. This can avoid prolonged symptoms, hospital stays, and need for parenteral nutrition.

Conflicts of Interest

The authors have no financial conflicts of interest.

REFERENCES

- Garcia-Tsao G, Sanyal AJ, Grace ND, Carey W. Prevention and management of gastroesophageal varices and variceal hemorrhage in cirrhosis. *Hepatology* 2007;46:922-938.
- Merli M, Nicolini G, Angeloni S, et al. Incidence and natural history of small esophageal varices in cirrhotic patients. *J Hepatol* 2003;38:266-272.
- D'Amico G, De Franchis R. Upper digestive bleeding in cirrhosis. Post-therapeutic outcome and prognostic indicators. *Hepatology* 2003;38:599-612.
- Khuroo MS, Khuroo NS, Farahat KL, Khuroo YS, Sofi AA, Dahab ST. Meta-analysis: endoscopic variceal ligation for primary prophylaxis of oesophageal variceal bleeding. *Aliment Pharmacol Ther* 2005;21:347-361.
- Gluud LL, Krag A. Banding ligation versus beta-blockers for primary prevention in oesophageal varices in adults. *Cochrane Database Syst Rev* 2012;CD004544.
- Petrascu F, Grothaus J, Mössner J, Schiefke I, Hoffmeister A. Differences in bleeding behavior after endoscopic band ligation: a retrospective analysis. *BMC Gastroenterol* 2010;10:5.
- Saltzman JR, Arora S. Complications of esophageal variceal band ligation. *Gastrointest Endosc* 1993;39:185-186.
- Elizondo-Rivera RL, González-González JA, García-Compeán D, Maldonado-Garza HJ. Complete esophageal obstruction after endoscopic variceal band ligation. *Endoscopy* 2014;46 Suppl 1 UCTN:E457-E458.
- Nawaz A, Sarwar S, Batul A. Complete esophageal occlusion following esophageal variceal band ligation: an unusual complication: a case report. *Visible Human Journal of Endoscopy* 2010;9:1-4.
- de Melo SW. Complete esophageal occlusion after band ligation. *Endoscopy* 2011;43 Suppl 2 UCTN:E259.
- Kwiatk JT, Merchant P. Successful removal of an esophageal band causing complete esophageal obstruction after variceal ligation. *Gastrointest Endosc* 2016;83:1030-1031.
- Chahal H, Ahmed A, Sexton C, Bhatia A. Complete esophageal obstruction following endoscopic variceal band ligation. *J Community Hosp Intern Med Perspect* 2013;3.
- Verma D, Pham C, Madan A. Complete esophageal obstruction: an unusual complication of esophageal variceal ligation. *Endoscopy* 2009;41 Suppl 2:E200-E201.
- Nikoloff MA, Riley TR 3rd, Schreibman IR. Complete esophageal obstruction following endoscopic variceal ligation. *Gastroenterol Hepatol (N Y)* 2011;7:557-559.
- Maric L, Alonso Y, Alvarez A, Erim T. Endoscopic variceal band ligation leading to acute onset dysphagia. *Am J Gastroenterol* 2016;111:S692.
- Mansour M, Abdel-Aziz Y, Awadh H, Shah N, Ajmera A. Complete esophageal obstruction after endoscopic variceal band ligation in a patient with a sliding hiatal hernia. *ACG Case Rep J* 2017;4:e8.
- Goff JS, Reveille RM, Van Stiegmann G. Endoscopic sclerotherapy versus endoscopic variceal ligation: esophageal symptoms, complications, and motility. *Am J Gastroenterol* 1988;83:1240-1244.