

Extend of Skipped Multifocal Noncontiguous Spinal Tuberculosis Beyond Imagination: A Rare Case Report and Literature Review

Abstract

Skipped multifocal extensive spinal tuberculosis involving the whole spine is very rare, which presents with atypical presentations and imaging features. So far, only five cases have been reported. Most of these patients have only two noncontiguous lesions. We are reporting a case of an 18-year-old boy with noncontiguous multifocal spinal tuberculosis involving cervical, thoracic, thoracolumbar, and lumbar segments. The patient was treated with antituberculous drug therapy and was operated for thoracolumbar spinal lesion. He made an excellent recovery. The possibility of tuberculosis is considered for any skip lesions involving the spine cautiously. Careful physical examination, trials of antitubercular therapy, and using the whole spine magnetic resonance imaging routinely also play an important role in the diagnosis and treatment of this disease. In patients with noncontiguous spinal involvement, there is a high percentage of requirement of surgical treatment due to fulminant behavior of the disease in these patients.

Keywords: Multifocal, Pott's disease, spinal instrumentation, spinal tuberculosis

Introduction

Usually, two or more contiguous vertebrae are involved in spinal tuberculosis owing to hematogenous spread through one intervertebral artery feeding two adjacent vertebrae.^[1] Noncontiguous multiple tuberculous spondylitis is rare, and most of the reported cases have lesions only in two levels.^[2] There were only five cases with extensive spinal involvement in literature.^[3] We are reporting a case of an 18-year-old boy with noncontiguous multifocal spinal tuberculosis involving cervical, thoracic, thoracolumbar, and lumbar segments.

Case Report

An 18-year-old boy was admitted with complaints of back pain and weight loss for 5 months. On physical examination, he was cachectic and his body weight was 37 kg. There was no neurodeficit. Erythrocyte sedimentation rate (ESR) was 130 mm/h. C-reactive protein (CRP) was 9.5. Serological tests for HIV were negative. Chest radiographs showed a suspicious active tuberculosis focus. On spinal radiographs collapse of the fifth cervical, second dorsal, ninth dorsal, and

twelfth dorsal, vertebral bodies were seen. Cervical magnetic resonance imaging revealed granulation tissue around C1–C2 bodies, retropharyngeal abscess, destruction of C5 body with spondylodiscitis at C4–C5, C5–C6 disc level, and epidural granulation tissue compressing the thecal sac around both C1–C2 and C4–C6 vertebral levels. C4–C6 vertebral levels. On thoracic and lumbosacral spinal magnetic resonance imaging examinations, there were signal intensity changes around bodies of D2–D3, ninth dorsal, twelfth dorsal, fourth lumbar, and fifth lumbar vertebral bodies, epidural abscesses compressing thecal sac around 2–D3, ninth dorsal and twelfth dorsal vertebra, collapse of D2–D3, ninth dorsal, twelfth dorsal vertebral bodies [Figure 1]. Transpedicular biopsy from D2–D3 level was done. On histopathology, necrotizing granulomatosis was seen. However, acid-fast-resistant bacteria had not been identified. A quartet antituberculous therapy (isoniazid 300 mg/day, rifampicin 600 mg/day, ethambutol 1.5 g/day, and pyrazinamide 1.5 g/day) was started with a possible diagnosis of tuberculosis. However, after 2 months, condition worsened; so, after consulting pulmonologist again,

**Dhiraj Vithal
Sonawane, Bipul
Kumar Garg, Kishor
Bapuji Jadhav**

*Department of Orthopaedic and
Spine, Grant Medical College,
Sir J. J. Group of Hospitals,
Mumbai, Maharashtra, India*

Address for correspondence:
Dr. Bipul Kumar Garg,
Department of Orthopaedic and
Spine, Grant Medical College,
Sir J. J. Group of Hospitals,
Mumbai, Maharashtra, India.
E-mail: garg.bipul@gmail.com

Access this article online

Website: www.asianjns.org

DOI: 10.4103/ajns.AJNS_345_19

Quick Response Code:



This is an open access journal, and articles are distributed under the terms of the Creative Commons Attribution-NonCommercial-ShareAlike 4.0 License, which allows others to remix, tweak, and build upon the work non-commercially, as long as appropriate credit is given and the new creations are licensed under the identical terms.

For reprints contact: reprints@medknow.com

How to cite this article: Sonawane DV, Garg BK, Jadhav KB. Extend of skipped multifocal noncontiguous spinal tuberculosis beyond imagination: A rare case report and literature review. Asian J Neurosurg 2020;15:136-9.

Submission: 26-11-2019 **Accepted:** 10-01-2020
Published: 25-02-2020

transpedicular biopsy was taken from previous D2–D3 level and from new ninth dorsal and twelfth dorsal vertebral levels, but report was inconclusive. Multidrug-resistant antituberculous therapy started looking at gross vertebral involvement. The patient improved clinically over 2 months as back pain decreased from visual analog scale score of seven to two; the patient gained weight of 2 kg; but, on 2-month follow-up, a knuckle was seen around dorsolumbar junction. Hence, we did sequential radiographs on every 2 months [Figure 2] and showed gradual collapse of D12 vertebra on 2-month and 4-month lateral radiographs; but, as the patient was improving clinically without any neurological deficit, we continued with antituberculous therapy and kept the patient following up; 6 monthly lateral radiograph showed complete collapse of D12 vertebra. So, we proceeded with magnetic resonance imaging and computed tomography scan. Six-month magnetic resonance imaging [Figure 3] and computed tomography scan [Figure 4] show excellent results in all the lesions of C1–C2, C5, D2–D3, D9 vertebral bodies, that were

well consolidated except D12 vertebral level where D12 vertebral body is totally destroyed with sagittal translation of eleventh dorsal vertebra over first lumbar vertebra associated with toppling, significant cord compression, and angular kyphosis of 30°. We decided to stabilize the D12 segment with circumferential decompression with fusion between D11 and L1 vertebra with the use of intraoperative neuromonitoring as the patient does not have any neurodeficit preoperatively. On postoperative radiographs, there was complete correction of sagittal translation [Figure 5]. Drug therapy was continued with following the improvement in clinical symptoms and signs associated with hematological investigation such as ESR, CRP, and radiological investigation like sequential radiographs, on every 6-month MRI. CRP level was normal 6 weeks after operation, and ESR was normal after 4 months. Antituberculous therapy was discontinued 12 months after operation as there were no active complaints, there were no back pain (visual analog scale score 0), there was weight gain of 8 kg from the day of starting of antituberculous therapy, radiographs showed maintenance of alignment, and magnetic resonance imaging showed resolution of prevertebral and epidural abscess.

Discussion

Usually, two or more contiguous vertebrae are involved in spinal tuberculosis owing to hematogenous spread through one intervertebral artery feeding two adjacent vertebrae.^[1] Noncontiguous multifocal tuberculous spondylitis is rare. Tuberculosis is not an uncommon disease in developing and underdeveloped countries. Its incidence is also increasing in developed countries because of immigration from underdeveloped and developing countries and increased incidence of human immune deficiency virus.^[4] Tuberculous spondylitis occurs in 1% of the patients with pulmonary tuberculosis.^[5] In the vast majority of the cases, lesions are at the thoracic and lumbar spine, and that at the cervical spine is present at about 5% of all tuberculous spondylitis cases.^[6]

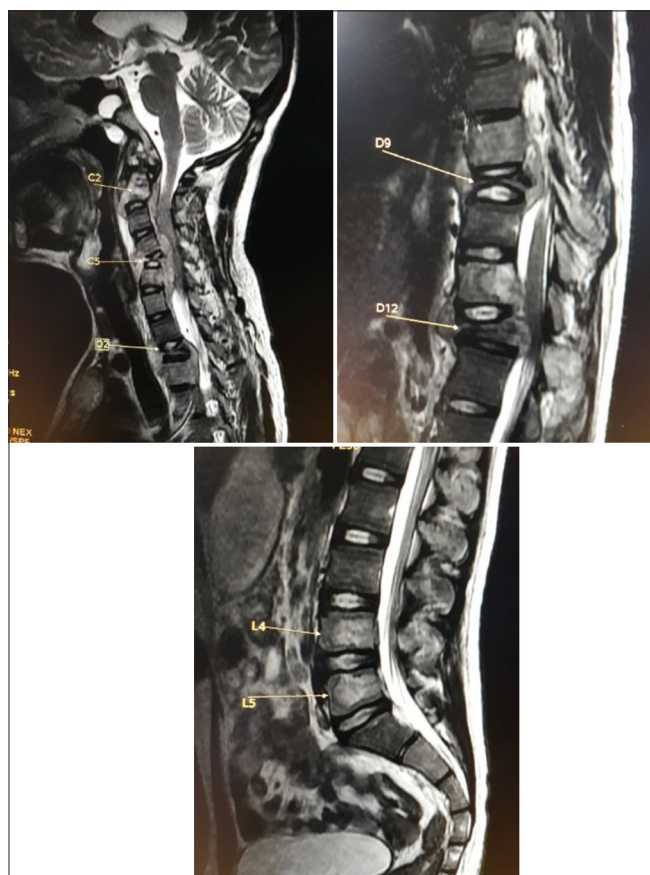


Figure 1: Magnetic resonance imaging of whole spine revealed granulation tissue around C1–C2 vertebral bodies, retropharyngeal abscess, destruction of C5 body with spondylodiscitis at C4–C5 and C5–C6 disc level, and epidural granulation tissue compressing the thecal sac around both C1–C2 and C4–C6 vertebral levels, signal intensity changes around vertebral bodies of D2–D3, D9, D12, L4, and L5, epidural abscesses compressing thecal sac around D2–D3, D9, and D12 vertebra, collapse of D2–D3, D9, D12 bodies, intensity changes in L4 and L5 vertebra were seen without any compression on thecal sac

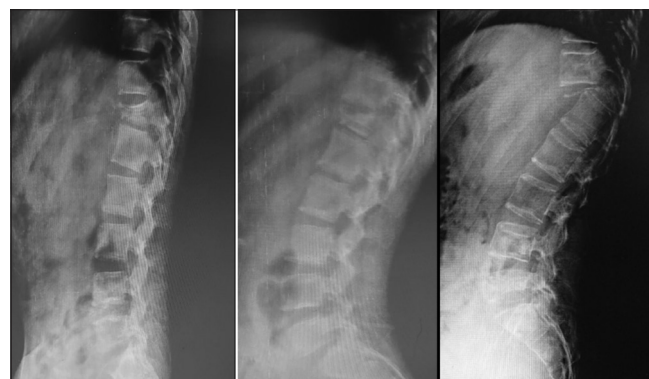

Figure 2: Sequential lateral radiographs of dorsolumbar spine done at 2 months, 4 months, and 6 months (from left to right) after starting multidrug-resistant antituberculous therapy showing gradual collapse of D12 vertebra at 2-month and 4-month radiograph whereas complete collapse at 6-month radiograph

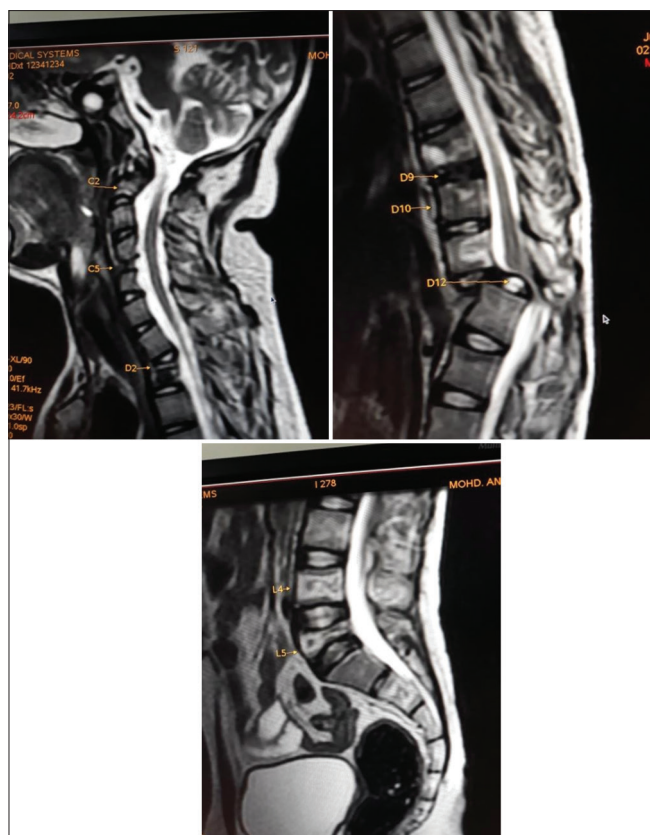

Figure 3: Six-month follow-up magnetic resonance imaging showing lesions of C1–C2, C5, D2–D3, D9 were well consolidated except D12 region where D12 is totally destroyed with sagittal translation of D11 over L1, toppling, and significant cord compression with angular kyphosis of 30°

There are multiple reported cases with two noncontiguous lesions. Turgut^[5] reported only one patient with noncontiguous thoracic and lumbar involvement in 694 patients on his meta-analysis. Rezai *et al.*^[7] reported one patient with thoracic and thoracolumbar involvement in twenty patients. Nussbaum *et al.*^[8] reported one case with cervical and thoracic involvement in 29 cases. This case was operated by laminectomy, grafting, and posterior instrumentation for both lesions because of neurodeficit. Janssens and de Haller^[2] reported one case with thoracic and lumbar involvement in 26 cases. This case was operated by curettage and spongiosa grafting because of the progression of the abscess in spite of the appropriate treatment. Kulali *et al.*^[1] reported one case with two noncontiguous circumferential thoracic involvement. They treated the patient by posterior decompression, fusion, and instrumentation. In all of those reported cases, there are two noncontiguous lesions.

There are only five reported cases with extensive involvement in whole spinal regions in the literature. Turgut^[3] reported a case with cervical, thoracic, and lumbar spondylitis. In this case, there was progressive quadriparesis and was treated by an anterior approach to the cervical spine and lateral retroperitoneal approach to the lumbar spine. Emel *et al.*^[9] reported a case of noncontiguous

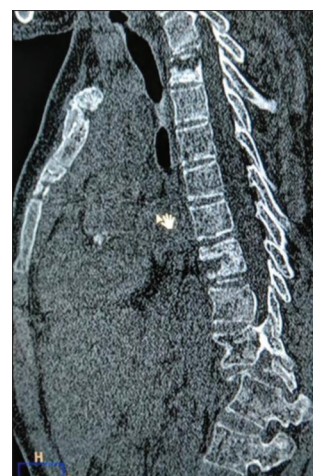

Figure 4: Six-month follow-up computed tomography scan showing lesions of C1–C2, C5, D2–D3, D9 were well consolidated except D12 region where D12 is totally destroyed with sagittal translation of D11 over L1, toppling, and significant spinal canal compromise with angular kyphosis of 30°

multifocal spinal tuberculosis involving cervical, thoracic, thoracolumbar, lumbar, and sacral segment for which the patient was operated twice. First for thoracolumbar lesion by anterolateral approach for neurodeficit and second for cervical spine lesions by anterior cervical spine approach for dysphagia not improved on chemotherapy after thoracolumbar surgery. Thawani *et al.*^[10] reported a case of multifocal tubercular osteomyelitis involving cervical, thoracic, lumbar, and sacral segment for which the patient was started on quadruple antituberculous drug and two-stage surgical decompression and stabilization with instrumentation for cervical spine by anterior approach and lumbar spine by posterior approach, respectively. Wang *et al.*^[11] reported a case of atypical noncontiguous multiple spinal tuberculosis involving cervical, thoracic, lumbar, and sacral segment with weakness of all four limbs managed conservatively with antituberculous drug for 12 months and brace. The recent most case reported by Wu *et al.*^[12] on 2018 was a case of skipped multifocal extensive spinal tuberculosis involving cervical, thoracic, lumbar, and sacral segment managed conservatively with antituberculous therapy for total 12 months. Our patient is the sixth reported case with extensive spinal involvement in literature.

Conclusion

Skipped multifocal extensive noncontiguous spinal tuberculosis involving the whole spine is very rare. Careful physical examination, trials of anti-tubercular therapy, sequential radiographs, and whole spine magnetic resonance imaging routinely play an important role in the diagnosis and treatment of this disease. In patients with noncontiguous spinal involvement, there is a high percentage of requirement of surgical treatment due to fulminant behavior of the disease in these patients.

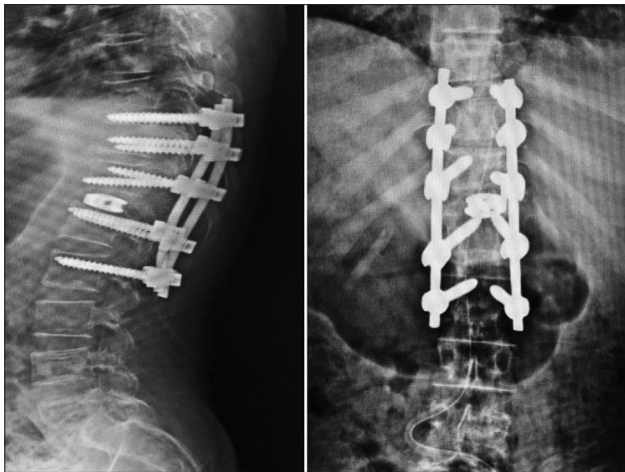


Figure 5: Postoperative radiograph of the thoracolumbar spine showing complete correction of sagittal translation

Declaration of patient consent

The authors certify that they have obtained all appropriate patient consent forms. In the form the patient(s) has/have given his/her/their consent for his/her/their images and other clinical information to be reported in the journal. The patients understand that their names and initials will not be published and due efforts will be made to conceal their identity, but anonymity cannot be guaranteed.

Financial support and sponsorship

Nil.

Conflicts of interest

There are no conflicts of interest.

References

1. Kulali A, Cobanoğlu S, Ozyilmaz F. Spinal tuberculosis with circumferential involvement of two noncontiguous isolated vertebral levels: Case report. *Neurosurgery* 1994;35:1154-8.
2. Janssens JP, de Haller R. Spinal tuberculosis in a developed country. A review of 26 cases with special emphasis on abscesses and neurologic complications. *Clin Orthop Relat Res* 1990;257:67-75.
3. Turgut M. Multifocal extensive spinal tuberculosis (Pott's disease) involving cervical, thoracic and lumbar vertebrae. *Br J Neurosurg* 2001;15:142-6.
4. Lee TC, Lu K, Yang LC, Huang HY, Liang CL. Transpedicular instrumentation as an adjunct in the treatment of thoracolumbar and lumbar spine tuberculosis with early stage bone destruction. *J Neurosurg* 1999;91:163-9.
5. Turgut M. Spinal tuberculosis (Pott's disease): Its clinical presentation, surgical management, and outcome. A survey study on 694 patients. *Neurosurg Rev* 2001;24:8-13.
6. Hsu LC, Leong JC. Tuberculosis of the lower cervical spine (C2 to C7). A report on 40 cases. *J Bone Joint Surg Br* 1984;66:1-5.
7. Rezai AR, Lee M, Cooper PR, Errico TJ, Koslow M. Modern management of spinal tuberculosis. *Neurosurgery* 1995;36:87-97.
8. Nussbaum ES, Rockswold GL, Bergman TA, Erickson DL, Seljeskog EL. Spinal tuberculosis: A diagnostic and management challenge. *J Neurosurg* 1995;83:243-7.
9. Emel E, Güzey FK, Güzey D, Bas NS, Sel B, Alatas I. Non-contiguous multifocal spinal tuberculosis involving cervical, thoracic, lumbar and sacral segments: A case report. *Eur Spine J* 2006;15:1019-24.
10. Thawani M, Hale E, Habte-Gabr E. Multifocal tubercular osteomyelitis: A case with atypical manifestations. *Tuberc Res Treat* 2011;2011:3.
11. Wang L, Liu L, Song Y. A rare case of atypical noncontiguous multiple spinal tuberculosis. *Spine J* 2015;15:e5-7.
12. Wu M, Su J, Yan F, Cai L, Deng Z. Skipped multifocal extensive spinal tuberculosis involving the whole spine: A case report and literature review. *Medicine (Baltimore)* 2018;97:e9692.