

Stuck aortic valve treated by reteplase in a Bentall patient

Ömer Tanyeli, Yüksel Dereli, Mehmet Akif Düzenli*, Niyazi Görmüş
Departments of Cardiovascular Surgery and *Cardiology, Meram
Faculty of Medicine, Necmettin Erbakan University; Konya-Turkey

Introduction

Reteplase, a recombinant plasminogen activator, is indicated for the thrombolytic treatment of suspected myocardial infarction with persistent ST elevation or recent left bundle-branch block within 12 h; however, its use on stuck mechanical valves remains controversial.

Case Report

A 55-year-old woman was admitted to the cardiology clinic with acute onset chest pain, shortness of breath, and palpitation. She had undergone a Bentall operation because of type 1 aortic dissection 3 years ago; however, she did not use her warfarin properly. She had 1 mm of ST elevation in AVR and V1 and 2 mm ST depression in D2, D3, aVF, and V4-V6. She was emergently taken to an angio laboratory, and a huge thrombus material strictly blocking the movement of the aortic valve with resultant severe aortic stenosis was detected. The coronary angiogram was normal. The ejection fraction was 25%. She was sent to the cardiovascular surgery intensive care unit for emergent re-do surgery for the stuck valve. Because the patient had previously undergone the Bentall operation, operative mortality was thought to be considerably high.

Until the patient was prepared for operation, the medical treatment strategy was decided. Reteplase (Rapilysin 10U, Actavis Group, Hafnarfjörður, Iceland) was administered as a 10 U bolus dose followed by a second 10 U bolus dose 30 min later. Each bolus was administered as a slow intravenous injection within 2 min. Heparin and acetylsalicylic acid were also administered before and following the administration of reteplase to reduce the risk of rethrombosis. The patient's clinical status dramatically improved within hours, and the surgery was postponed. Initially, the shortness of breath partially resolved and oxygen saturation began to increase from 85% to 91% in the initial 3 h. During this period, hourly bedside echocardiographic controls were made and the partial movement of the mechanical valve was confirmed. The heparin administration was continued for the following 48 h with control of aPTT every 6 h, with concomitant echocardiographic bedside evaluation of the valve movements. These movements were also confirmed by fluoroscopy at the end of the second day of treatment (Fig. 1). Video 1 shows the recovery of leaflet motion of the

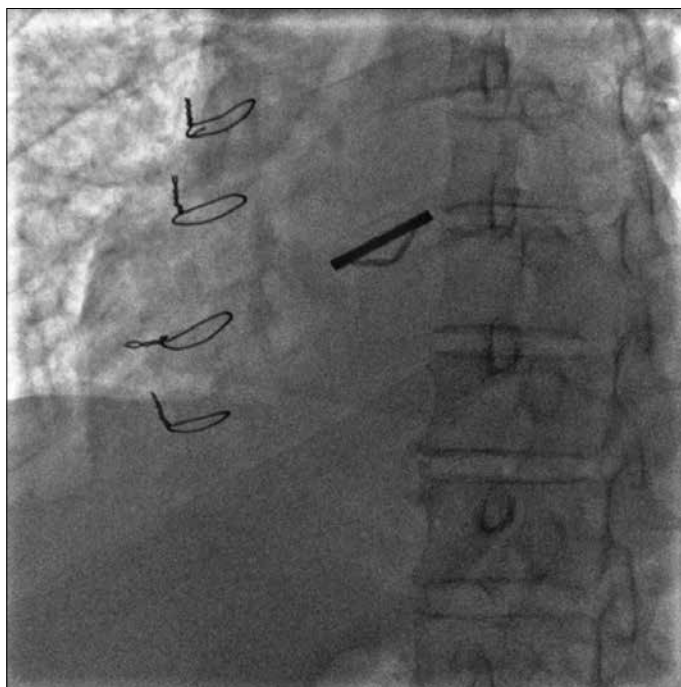


Figure 1. Fluoroscopy showing functional prosthetic valve in aortic position

mechanical valve in the aortic position. On echocardiographic evaluation, the patient's maximum gradient on the aortic valve decreased from 100 mm Hg to 66 mm Hg during the 24th h and to 32 mm Hg during the second day of treatment. Severe aortic regurgitation regressed to minimal aortic regurgitation with a functional aortic valve. The patient was discharged after 7 days of warfarin therapy after the target INR reached 2.5.

Discussion

Reteplase is a thrombolytic agent derived from the human tissue plasminogen activator. Reteplase has been shown to have fibrin specificity similar to that of alteplase but with a lower binding affinity for fibrin. This enables reteplase to bind to the thrombus repeatedly and increases its fibrinolytic potential (1). Reteplase is mainly used for acute myocardial infarction that presents within 12 h of symptom onset in addition to ST-segment elevation on ECG or new-onset left bundle-branch block, unless an alternative reperfusion strategy is planned (2). However, for the last few years it is also used for the treatment of acute pulmonary embolism and deep venous thrombosis and for thrombosed catheters (3, 4). The use of reteplase for stuck valves is limited in the literature and has been published for few cases of prosthetic mitral and

of aortic valve stenosis (5). This is the first case in the literature with a previous history of the Bentall operation, rather than isolated mechanical valve stenosis. If the patient had no benefit from reteplase, she would have undergone re-do surgery, for not only the stuck aortic valve but also for the previous Bentall operation, which would certainly increase the operative mortality.

Conclusion

The clinical use of reteplase in stuck valves is limited in the literature, and this is the first case of a Bentall patient reported in the literature. By choosing the right indication, reteplase may be an alternative in re-functioning of the stuck mechanical valves, particularly in high-risk patients, as in this case. The decision and follow-up should be made with close collaboration between the cardiologists and cardiovascular surgeons.

Video 1. Fluoroscopy showing recovery of leaflet motion of the mechanical valve in the aortic position.

References

1. Wooster MB, Luzier AB. Reteplase: a new thrombolytic for the treatment of acute myocardial infarction. *Ann Pharmacother* 1999; 3: 318-24. [\[CrossRef\]](#)
2. White HD, Van de Werf FJ. Thrombolysis for acute myocardial infarction. *Circulation* 1998; 16: 1632-46. [\[CrossRef\]](#)
3. Simpson D, Siddiqui MA, Scott LJ, Hilleman DE. Reteplase: a review of its use in the management of thrombotic occlusive disorders. *Am J Cardiovasc Drugs* 2006; 6: 265-85. [\[CrossRef\]](#)
4. Bush RL, Lin PH, Bates JT, Mureebe L, Zhou W, Lumsden AB. Pharmacomechanical thrombectomy for treatment of symptomatic lower extremity deep venous thrombosis: safety and feasibility study. *J Vasc Surg* 2004; 5: 965-70. [\[CrossRef\]](#)
5. Akhtar N, Khan YJ, Ahmed W. Thrombolysis with reteplase for recurrent mechanical heart valve thrombosis. *J Pak Med Assoc* 2011; 2: 189-92.

This paper was previously published as an oral presentation at the "10th International Congress of Update in Cardiology and Cardiovascular Surgery, March 13-16, 2014, Antalya, Turkey".

Address for Correspondence: Dr. Ömer Tanyeli,
Necmettin Erbakan Üniversitesi, Meram Tıp Fakültesi
Kalp ve Damar Cerrahisi, Meram, 42080, Konya-Türkiye
Phone: +90 532 767 89 09
Fax: +90 332 223 61 81
E-mail: otanyeli@gmail.com



©Copyright 2015 by Turkish Society of Cardiology - Available online at www.anakarder.com
DOI:10.5152/akd.2015.6024