

Factors associated with pericolic fat stranding of colon cancer on computed tomography colonography

Tsuyoshi Morimoto¹, Takayuki Yamada¹, Kuniyoshi Miyakawa²
and Yasuo Nakajima³

Acta Radiologica Open
7(2) 1–6
© The Foundation Acta Radiologica
2018
Reprints and permissions:
sagepub.co.uk/journalsPermissions.nav
DOI: 10.1177/2058460118757578
journals.sagepub.com/home/arr



Abstract

Background: Pericolic fat stranding on computed tomography (CT) scans has been an important feature for staging colon cancer. However, the factors associated with pericolic fat stranding have not been elucidated to date.

Purpose: To determine factors associated with pericolic fat stranding of colon cancer on CT colonography (CTC).

Material and Methods: Overall, 150 patients with 155 colon cancer lesions were retrospectively assessed by two radiologists for pericolic fat stranding on CTC. Circumferential proportion of the tumor (CPTumor; <50%, 50–75%, and ≥75%), longitudinal length, depth of invasion (≤T2, T3, T4), lymph node and distant metastasis, and lymphovascular invasion were recorded. Univariate and multivariate logistic regression analyses were performed between pericolic fat stranding and each factor. Multi-group comparisons were performed for the CPTumor and depth of invasion.

Results: Pericolic fat stranding was identified in 57 lesions (36.8%). Univariate analysis revealed significant associations of pericolic fat stranding with all factors ($P < 0.027$), except for lymph node metastasis ($P = 0.087$). Multi-group comparisons revealed that pericolic fat stranding was more frequent with increasing CPTumor ($P < 0.001$); however, no significant differences were observed beyond subserosal infiltration ($P = 0.225$). Logistic regression analysis revealed the CPTumor (<75% vs. ≥75%; $P = 0.008$, <50% vs. 50–75%; $P = 0.047$) and longitudinal length ($P = 0.001$) as explainable variables.

Conclusion: Pericolic fat stranding identified on CT images of colon cancer is demonstrated more frequently with increasing circumferential proportion of the tumor and longitudinal length.

Keywords

Computed tomography colonography, colon cancer, pericolic fat stranding, circumferential proportion of the tumor, depth of invasion

Date received: 27 November 2017; accepted: 14 January 2018

Introduction

Colon cancer staging is closely related to treatment strategies and prognosis. Computed tomography (CT) has been used to diagnose lymph node and distant metastasis. However, CT examinations have often yielded unsatisfactory results when evaluating depth of invasion, and it is difficult to detect lesions and obtain satisfactory images of the structure of the wall layers due to the collapse of the intestinal tract (1,2). Therefore, the depth of invasion is determined by assessing wall deformities on profile views of barium enema images (3), pit patterns on endoscopic images, and endoscopic ultrasound images. However, advances in multidetector CT technology have allowed a detailed assessment of multiplanar reconstruction (MPR)

images. In addition, the use of CT colonography (CTC) with large bowel inflation has widely increased.

Inflation of the large bowel when performing CTC markedly improves the image quality of tumors;

¹Department of Radiology, St. Marianna University School of Medicine, Yokohama City Seibu Hospital, Kanagawa, Japan

²Department of Radiology, Kawasaki Municipal Tama Hospital, Kanagawa, Japan

³Department of Radiology, St. Marianna University School of Medicine, Kanagawa, Japan

Corresponding author:

Tsuyoshi Morimoto, 1197-1, Yasashi-cho, Asahi-ku, Department of Radiology, St. Marianna University School of Medicine, Yokohama City Seibu Hospital, Yokohama, Kanagawa, 241-0811, Japan.
Email: tuyosi-m@marianna-u.ac.jp



therefore, this technique is used in both colon screening and preoperative assessment of colon cancer. These improvements in the image quality have led to the use of CTC to re-evaluate the diagnostic ability of depth of invasion. Previously, diagnosis of depth of invasion through CT was performed by assessing the degree of intestinal wall thickening caused by the tumor and by pericolic fat stranding. In the previous studies (1,2,4), pericolic fat stranding was considered an indication of tumor invasion into the pericolic tissue or the serosa (T4). Although this finding was used in daily clinical practice, a subsequent pathological study reported that this finding indicated inflammation and fibrosis in addition to T4 (5). Recent studies using CTC have reported that pericolic fat stranding suggests tumor invasion through the muscularis propria into the pericorectal tissues (T3) and deeper infiltration (T4), and differentiation between T3 and T4 is difficult (6,7). However, other factors that may be associated with pericolic fat stranding have not been elucidated to date.

The purpose of this study was to clarify the factors associated with pericolic fat stranding with respect to CTC and pathological findings.

Materials and Methods

This study was approved by the Bioethics Institutional Review Board of our institution. The requirement for informed consent was waived due to retrospective study.

Patients

We enrolled 194 patients with a histopathological diagnosis of colon cancer and who had undergone CTC preoperative assessment at our hospital between January 2015 and December 2016. The exclusion criteria were as follows: cases involving additional surgical resection following endoscopic resection; cases that did not undergo surgical resection; cases of adventitious tunica invasion; cases involving preoperative chemotherapy; cases in which surgery was performed at other hospitals and histopathological diagnosis could not be confirmed; and cases in which lesions could not be identified on CT images. Cases involving surgical resection at other hospitals but whose detailed histopathological diagnostic results could be obtained were included. The study population comprised 150 patients with 155 lesions (82 men, 68 women; age range = 20–90 years; mean age = 69.3 ± 12.2 years).

CTC procedure

On the day before the CTC procedure, the patients ingested low-residue foods (FG-two: Fushimi Pharmaceutical, Kagawa, Japan) and colon cleansing

was performed using a cathartic drug. The examination was performed by inserting a transanal catheter, intravenously administering an antispasmodic drug (butylscopolamine, 20 mg, or glucagon, 1 mg), and inflating the intestinal tract (pressure setting: 18 mmHg) by using an automatic CO₂ insufflator (PROTOCO2L; Bracco, Princeton, NJ, USA). Images were obtained using a 320-detector-row CT scanner (Aquilion ONE ViSION Edition; Toshiba Medical Systems, Tokyo, Japan). CT images were obtained with following parameters: 120 kV; 30–550 mA with automatic exposure control; 80 rows \times 0.5 mm collimation; and beam pitch 0.813. For dynamic contrast enhancing (DCE) studies, a non-ionic contrast agent was used at a dose of 630 mgI/kg for right hemocolic lesions (RHL) and 660 mgI/kg for left hemocolic lesions (LHL); the injection time was 30 s for RHL and 35 s for LHL. The scan delay was set at 6 s for RHL and 18 s for LHL after achieving the targeted enhancement at the abdominal aorta. The region of interest was set to the abdominal aorta at the level of the first lumbar vertebra for RHL and third lumbar vertebra for LHL; the threshold value was set to 200 HU. In case of RHL, a second scan was obtained 18 s after the first scan. The patients maintained a prone position during plain CT and supine position during DCE-CT. In cases of rectal lesions, plain CT was performed with patients in the supine position and DCE-CT with patients in the prone position. In cases where a contrast medium could not be used, images were obtained in both positions through plain CT imaging.

Image assessment

The CTC images were analyzed using the CTC analysis software (Ziostation2; Ziosoft, Tokyo, Japan). MPR, virtual endoscopic, and virtual barium enema images were assessed. The CTC images were reviewed by two observers (A, a radiologist with 15 years of experience, and B, a radiologist with 33 years of experience), who were aware of the lesion location and macroscopic types to retrospectively determine the presence of pericolic fat stranding (Figs. 1 and 2). When the observers' results differed, a consensus was reached after discussion. Observer A measured the circumferential proportion of the tumors (CPTumor: proportion of the intestinal tract circumference that was occupied by the tumor) and the longitudinal length, as well as assessing distant metastasis. CPTumor results were assigned to one of the following categories: <50%; 50–75%; and \geq 75%.

Pathological assessment

The pathological diagnostic results of the resected lesions were retrieved from electronic medical records.

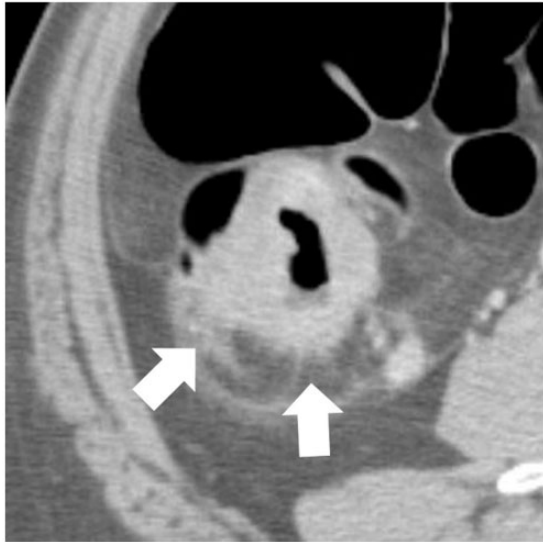


Fig. 1. CT image of a 70-year-old man with ascending colon cancer whose longitudinal length was 42 mm. An axial CT image revealed that the circumferential proportion of the tumor was $\geq 75\%$, and pericolic fat stranding was identified around the lesion (arrow). Pathological diagnosis of depth of invasion was T4.

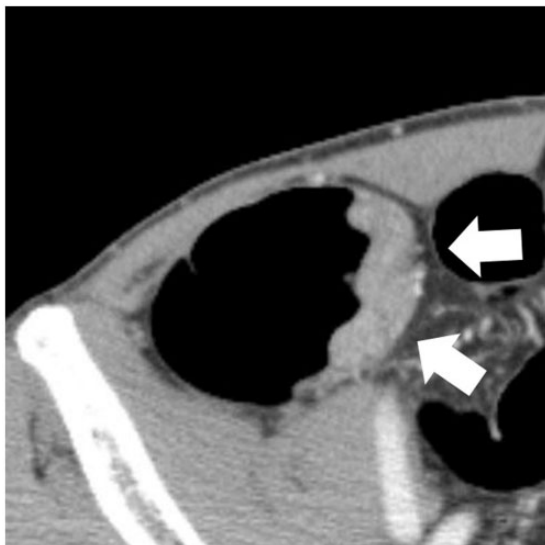

Fig. 2. CT image of a 54-year-old man with ascending colon cancer whose longitudinal length was 23 mm. The margin of the lesion was smooth (arrow), and pericolic fat stranding was not observed around the lesion. The circumferential proportion of the tumor was $< 50\%$, and pathological diagnosis of depth of invasion was T2.

We assessed the following factors: depth of invasion (T factor) and the presence of lymph node metastasis, lymphatic invasion, and venous invasion, in accordance with the Japanese Classification of Colorectal

Carcinoma, 8th edition (8). Pericolic fat stranding was not investigated in association with surgical/pathological findings.

Statistical analysis

Univariate analysis, using either the chi-squared or Fisher's exact test, was performed to investigate the association between pericolic fat stranding and all factors. In cases in which univariate analysis revealed a significant difference, multi-group comparison by using the Steel–Dwass test was conducted for assessing the CPTumor and depth of invasion. Normality of the longitudinal length measurements was confirmed using the Shapiro–Wilk test, and in cases in which normality was not shown, we used the Mann–Whitney U test.

Multivariate logistic regression analysis by stepwise method was performed to reveal explainable variables among all factors. In all cases, $P < 0.05$ was considered as the level of statistical significance. JMP 13 Pro (SAS Institute, Cary, NC, USA) was used for all analyses.

Results

The locations of the 155 lesions were as follows: 17 in the cecum; 31 in the ascending colon; 20 in the transverse colon; nine in the descending colon; 47 in the sigmoid colon; and 31 in the rectum.

Table 1 shows the correlations among multiple factors. Although the CPTumor was correlated with the longitudinal length and depth of invasion in all groups, the correlation coefficient for all factors was < 0.6 , indicating no strong correlations. Pericolic fat stranding was identified in 57 cases (36.8%). Table 2 shows the association between pericolic fat stranding and all factors. The longitudinal length was significantly larger in patients with pericolic fat stranding than in those without it ($P < 0.001$). Univariate analysis indicated a statistically significant association of pericolic fat stranding with all factors, except for lymph node metastasis. Steel–Dwass test indicated statistically significant differences among all groups of CPTumor ($< 50\%$, $50\text{--}75\%$, and $\geq 75\%$). Depth of invasion analysis revealed an association between \leq muscularis propria (T2) and T3 as well as between \leq T2 and T4 ($P < 0.001$), although no significant difference was observed between T3 and T4 ($P = 0.225$).

Multivariate logistic regression analysis indicated that pericolic fat stranding was significantly associated with the CPTumor and longitudinal length (Table 3).

Discussion

In this study, multivariate analysis indicated that pericolic fat stranding identified on CT images was

Table 1. Correlation coefficient among CTC and pathological factors.

		CTC results		Pathological results				
		CP _{tumor}	LG	DI	N	Ly	V	M
CTC results	CP _{tumor}		0.51	0.55	0.25	0.25	0.27	0.27
	LG	0.51		0.46	0.08	0.13	0.23	0.2
	DI	0.55	0.46		0.31	0.34	0.39	0.23
	N	0.25	0.08	0.31		0.35	0.29	0.23
Pathological results	Ly	0.25	0.13	0.34	0.35		0.25	0.05
	V	0.27	0.23	0.39	0.29	0.25		0.18
	M	0.27	0.2	0.23	0.23	0.05	0.18	

CTC, CT colonography; CP_{tumor}, circumferential proportion of the tumor; LG, longitudinal length; DI, depth of invasion; N, lymph node metastasis; Ly, lymphatic invasion; V, venous invasion; M, distant metastasis.

Table 2. Univariate analysis between pericolic fat stranding and assessment factors.

		Pericolic fat stranding		P value
		+(n = 57)	-(n = 98)	
CTC results	Longitudinal length (mm)	46 (35–58.5)	30 (22–39.3)	<0.001*
	CP _{tumor}			<0.001†
	<50%	1	46	
	50–75%	13	31	
	≥75%	43	21	
Pathological results	Depth of invasion			<0.001†
	≤T2	1	39	
	T3	44	53	
	T4	12	6	
	Distant metastasis			0.016‡
	+	9	4	
	–	48	94	
	Lymph node metastasis			0.112‡
	+	24	28	
	–	33	70	
Lymphatic invasion			0.04‡	
+	41	53		
–	16	45		
Venous invasion			<0.001‡	
+	43	42		
–	14	56		

Longitudinal lengths are expressed as median (interquartile range).

*Mann–Whitney U test.

†Chi-square test.

‡Fisher's exact test.

CTC, CT colonography; CP_{tumor}, circumferential proportion of the tumor.

significantly associated with the CP_{tumor} and longitudinal length.

We found that 98.2% (56/57) of cases of pericolic fat stranding had a strong association with ≥T3. Univariate analysis indicated a significant association

between pericolic fat stranding and depth of invasion, but multi-group comparison showed no significant difference between the frequency of pericolic fat stranding in cases of T3 and T4. Therefore, the presence of pericolic fat stranding cannot determine the stage as T3 or

Table 3. Multivariate logistic regression analysis among assessment factors.

	Factors	P value
CTC results	CP _{tumor}	
	(<75% vs. ≥75%)	0.008
	(<50% vs. 50–75%)	0.047
Pathological results	Longitudinal length	0.001
	Depth of invasion	0.092
	Distant metastasis	0.636
	Lymph node metastasis	0.593
	Lymphatic invasion	0.742
	Venous invasion	0.088

CTC, CT colonography; CP_{tumor}, circumferential proportion of the tumor.

T4. Moreover, multivariate analysis did not show a significant correlation with the depth of invasion. Some studies have reported high sensitivity and low specificity of pericolic fat infiltration in detecting stage ≥T3 and mentioned that the presence of abnormal pericolic fat does not necessarily indicate the presence of extramuscular extension of tumor (9,10). These findings are consistent with those of the present study.

Univariate and multivariate analysis revealed a significant association between the CP_{tumor} and pericolic fat stranding. Flor et al. reported that lesions whose CP_{tumor} was less than half the circumference did not present pericolic fat stranding (11). In the present study, only 1/47 cases (2.13%) with a lesion whose CP_{tumor} was <50% was found to have pericolic fat stranding. Utano et al. reported many cases (81.5%) of ≥T3 when the CP_{tumor} was ≥50% (7). Some studies have reported that pericolic fat stranding could be due to the presence of inflammatory changes and fibrosis, in addition to tumor invasion (5,12,13). This finding suggests obstructive inflammation with increasing CP_{tumor}.

Our study indicated that the longitudinal length was the significant explainable variable for pericolic fat stranding. To our knowledge, no studies have focused on the relationship between the pericolic fat stranding and longitudinal length. A previous study mentioned that the longitudinal length was correlated with depth of invasion (7). However, it seemed a confounding factor and was not selected for explainable variables in the present study. In addition, another study reported a significant positive correlation between the maximum longitudinal length and CP_{tumor} (14). Both of them were independent explainable factors in our study and their correlation did not prove the association between the pericolic fat stranding and longitudinal length. At this moment, we cannot list the reasons why pericolic fat stranding was encountered more

frequently in association with the greater longitudinal length. This should be further clarified.

This study has several limitations. First, this study had a retrospective design. Second, we only examined patients who underwent preoperative CTC, resulting in a selection bias. Third, although the number of T4 cases was small, which may also have been because of selection bias. Fourth, pericolic fat stranding was not investigated pathologically. Further prospective studies that consider these limitations are warranted.

In conclusion, pericolic fat stranding identified on CT images of colon cancer is demonstrated more frequently with increasing circumferential proportion of the tumor and longitudinal length. The presence of pericolic fat stranding suggests tumor invasion of T3 or more, but cannot distinguish between T3 and T4.

Declaration of conflicting interests

The author(s) declared no potential conflicts of interest with respect to the research, authorship, and/or publication of this article.

Funding

The author(s) received no financial support for the research, authorship, and/or publication of this article.

References

1. Freeny PC, Marks WM, Ryan JA, et al. Colorectal carcinoma evaluation with CT: preoperative staging and detection of postoperative recurrence. *Radiology* 1986; 158:347–353.
2. Thompson WM, Halvorsen RA, Foster WL Jr, et al. Preoperative and postoperative CT staging of rectosigmoid carcinoma. *Am J Roentgenol* 1986;146:703–710.
3. Ushio K, Goto H, Matsumura Y, et al. Significance of profile view in the x-ray diagnosis of cancer of the digestive tract: diagnosis of invasion by double-contrast study. *Stomach Intestine* 1986;21:27–41.
4. Balthazar EJ, Megibow AJ, Hulnick D, et al. Carcinoma of the colon: detection and preoperative staging by CT. *Am J Roentgenol* 1988;150:301–306.
5. Hulsmans FJ, Tio TL, Fockens P, et al. Assessment of tumor infiltration depth in rectal cancer with transrectal sonography: caution is necessary. *Radiology* 1994;190: 715–720.
6. Watanabe Y, Okada Y. Preoperative local staging of colorectal cancer using a CT: investigation of imaging data for CT colonography. *J Saitama Medical University* 2015;41: 135–138.
7. Utano K, Endo K, Togashi K, et al. Preoperative T staging of colorectal cancer by CT colonography. *Dis Colon Rectum* 2008;51:875–881.
8. Japanese Society for Cancer of the Colon and Rectum. *Japanese classification of colorectal carcinoma*, 8th ed. Tokyo: Kanehara & Co., Ltd, 2013.

9. Ng CS, Doyle TC, Dixon AK, et al. Histopathological correlates of abnormal pericolic fat on CT in the assessment of colorectal carcinoma. *Br J Radiol* 2002;75:31–37.
10. Zeina AR, Mahamid A, Walid S, et al. The diagnostic accuracy of pericolonic fat extension and attenuation for colorectal tumors. *Eur J Radiol* 2015;84:1724–1728.
11. Flor N, Mezzanica M, Rigamonti P, et al. Contrast-enhanced computed tomography colonography in preoperative distinction between T1-T2 and T3-T4 staging of colon cancer. *Acad Radiol* 2013;20:590–595.
12. Jin KN, Lee JM, Kim SH, et al. The diagnostic value of multiplanar reconstruction on MDCT colonography for the preoperative staging of colorectal cancer. *Eur Radiol* 2006;16:2284–2291.
13. Hundt W, Braunschweig R, Reiser M. Evaluation of spiral CT in staging of colon and rectum carcinoma. *Eur Radiol* 1999;9:78–84.
14. Kurihara H, Mochizuki H, Hase K, et al. A trial of new classification of tumor size in colorectal cancer. *Nippon Daicho Komonbyo Gakkai Zasshi* 1993;46:175–181.