

Assessment of Osteoimmunological Changes Following Orthognathic Surgery

Sara Soliman^{1*}, Mohammad Dehis¹, Mamdouh Ahmed¹, Engy EL Kateeb²

¹Oral and Maxillofacial Surge, Pharos University in Alexandria, Alexandria, Egypt; ²Clinical Pathology Department, Pharos University in Alexandria, Alexandria, Egypt

Abstract

Citation: Soliman S, Dehis M, Ahmed M, EL Kateeb E. Assessment of Osteoimmunological Changes Following Orthognathic Surgery. Open Access Maced J Med Sci. 2019 Feb 28; 7(4):632-636. <https://doi.org/10.3889/oamjms.2019.158>

Keywords: Orthognathic surgery; Immunosuppression; Stress response

***Correspondence:** Sara Soliman, Oral and Maxillofacial Surge, Pharos University in Alexandria, Alexandria, Egypt. E-mail: vivis5854@gmail.com

Received: 11-Dec-2018; **Revised:** 06-Feb-2019; **Accepted:** 07-Feb-2019; **Online first:** 27-Feb-2019

Copyright: © 2019 Sara Soliman, Mohammad Dehis, Mamdouh Ahmed, Engy EL Kateeb. This is an open-access article distributed under the terms of the Creative Commons Attribution-NonCommercial 4.0 International License (CC BY-NC 4.0)

Funding: This research did not receive any financial support

Competing Interests: The authors have declared that no competing interests exist

BACKGROUND: There is a scarcity in the published literature which evaluates the postoperative inflammatory response and patients' immunity following orthognathic surgery.

AIM: The present prospective study aimed to evaluate the changes in two immunological callipers to measure the traumatic effect of orthognathic surgery

METHODS: In the present prospective cohort study, we included women (age range 16-30 years) with severe dentofacial deformities who were scheduled for bimaxillary osteotomy. Blood samples were collected for measurement of transforming growth factor beta one (TGF- β 1) and osteoprotegerin (OPG) levels. The statistical analysis was carried with SPSS software.

RESULTS: In the present study, nine patients with severe dentofacial deformity were operated successfully under general anaesthesia. All patients reported decreased energy and fatigue in the early days after surgery and had difficulties with nutrition due to pain, oedema and paresthesia; however, no massive weight loss was reported. The levels of OPG started to increase immediately postoperatively (mean = 0.46 ± 0.08 ; $p = 0.001$). A significant increase in the concentration of OPG begun postoperatively and continued to rise significantly until the six weeks to reach 2.24 ± 0.30 ng/mL ($p < 0.001$). Similarly, the concentration of TGF- β 1 increased at three days postoperatively and continued to rise until the six weeks to reach 1.28 ± 0.19 ng/mL ($p < 0.001$).

CONCLUSION: In conclusion, orthognathic surgery is associated with a significant rise in the pro-inflammatory cytokines until the six weeks postoperatively. These observed results may indicate a significant alteration in the immunity of the patients to undergoing orthognathic surgery.

Introduction

Orthognathic surgery is a common surgical procedure that aims to restore the normal anatomical and functional position in patients with severe dentofacial deformities [1]. It is usually indicated in the case of occlusal malfunction, improper aesthetic facial appearance, and temporomandibular joint dysfunction [2]. According to recent figures from England and Wales, more than 2600 orthognathic surgical procedures are performed annually [3]; a similar rate was reported from the United States (US) as well [4]. As patients with severe dentofacial deformities are more likely to suffer from poor psychological status

related to their facial appearance, orthognathic surgery was reported to have a positive impact on patients' psychology and well-being [5]. However, the procedure is associated with some intra and postoperative complications such as severe haemorrhage, facial oedema, pain, and neurological injuries [6]. Intraoperative blood loss is inevitable as well which, in severe cases, may lead to a systemic inflammatory response with subsequent infection and end-organ failure due to lowered immunity [7].

On the other hand, the surgical stress response is a well-established consequence of surgical or accidental trauma; it is defined as the endocrine/metabolic changes resulted from injury-induced activation of hypothalamic-pituitary axis and

eventually led to the release of hormones such as the stress hormone, cortisol [8]. The response has significant associations with a wide range of postoperative complications, surgical stress response was reported to increase body demands and affect immune competence [9]; patients with surgical stress showed significant increase in the release of a number of key cytokines (prostaglandin (PG) E2 and transforming growth factor TGF β) and suppression in the cellular immunity components until two weeks postoperatively [10], [12]. Thus, patients who undergo elective surgery are at increased risk of selective immunosuppressive effects during surgical stress and high rate of septic complications [13].

Few studies have evaluated the role of surgical stress in postoperative outcomes following oral and maxillofacial surgery; the level of IL-6 was reported to decrease following orthognathic surgery [7] markedly. To date, there is a lack in the published literature which evaluates the postoperative inflammatory response and patients' immunity following orthognathic surgery. Therefore, the present prospective study aimed to evaluate the changes in two immunological callipers to measure the traumatic effect of orthognathic surgery.

Material and Methods

Ethical approval

The study was conducted by the International and local ethical standards; the study was approved by the institutional review board of the Faculty of Oral and Dental Medicine, Cairo University, Egypt. Informed consent was obtained from all patients.

Sample size calculation

Prior data indicated that the difference in the response of matched pairs is normally distributed with standard deviation of 3661(pg/ml). If the true difference in the mean response of matched pairs is 7225 (pg/ml), 5 pairs of subjects at least needed to be studied to reject the null hypothesis that this response difference is zero with probability (power) 0.9. The Type I error probability associated with this test of this null hypothesis is 0.05.

Study design and Patients

The present study was a prospective cohort study; patients were randomly selected from those who were scheduled for bimaxillary osteotomy to correct severe dentofacial deformities. The deformities ranged between skeletal class III, vertical maxillary excess and mandibular retrognathia. Patients who had a history of previous orthognathic surgery, under

steroids therapy, or suffered from bone disease were excluded from the study; smokers were excluded as well. The age ranges from 16 to 30 years old.

Preoperatively, patients underwent detailed clinical examinations and. Preoperative orthodontic treatment. Surgical procedures were performed at the Dental Educational Hospital, Cairo University. Mandibular and maxillary incisions were done through mucosa, muscles and periosteum using diathermy knife. Osteotomies were performed by surgical burs (Lindeman, fissure) and a reciprocating saw (Figure 1).

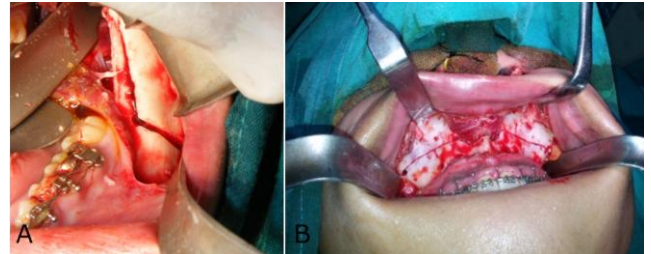


Figure 1: Bilateral sagittal split and Lefort 1 osteotomies; A) Osteotomy cuts through the cortical side on the medial side of the ramus and the lateral cortical plate; B) Osteotomy is done using a reciprocating saw through the buttress and lateral maxillary wall to the piriform rim followed by sectioning the lateral nasal wall by spatula osteotome

Postoperatively, cold compress, in the form of ice packs, were applied for 20 minutes every hour for 12 hours, fluid intake was carefully monitored, and antibiotics, analgesics, and intermediate-acting glucocorticoids were given for three days (IM 8 mg/2 ml of hydrocortisone was given intra-operatively and continued in the first operative day every 8hours, followed by half the dose in the second postoperative day followed by Methyl Prednisolone I.M. 40 mg/vial given once in the third day after surgery).

The patients spent an overnight hospital stay and discharged on the second day. Panorama, lateral cephalogram and posteroanterior views were taken one week postoperatively, the position of the jaw segments and condyle position were compared to pre-surgery films. Blenderized foods and high-calorie liquid dietary was consumed to prevent catabolism commonly associated with surgery.

Patients were instructed to maintain oral hygiene and returned for follow up visits during the first week, and then every two weeks. The pain was assessed using the visual analogue scale (VAS), swelling and paresthesia were evaluated subjectively by the patients marking yes or no. The patients returned to the orthodontist after two to three months postoperatively. Photographs were taken after three months.

Measurements of Osteoprotegerin (OPG) and Transforming growth factor beta one (TGF-β1)

Blood samples were collected preoperatively, immediately after the procedure, three days later, after one week, and then every two weeks till the six weeks postoperatively. Blood samples were allowed to clot for two hours at room temperature or overnight at 4°C in a serum separator tube. Centrifugation was done for 15 minutes at 1000 × g, and the aliquot was removed immediately and stored at -80°C. TGF-β1 level was measured by ELISA kit for TGF-β1 (catalogue no: ET3102-1), and OPG level was measured by Human ELISA Kit for OPG (catalogue noCSB-E04692h).

ELISA kit for TGF-β1

The Assay Max Human TGF-β1 ELISA kit was designed for the detection of TGF-β1 in cell culture supernatants. The assay employed a quantitative sandwich enzyme immunoassay technique that measures TGF-β1 in less than 5 hours. A murine monoclonal antibody specific for human TGF-β1 has been pre-coated onto a microplate. Samples were sandwiched by the immobilised antibody and a biotinylated polyclonal antibody specific for human TGF-β1, which were recognised by a streptavidin-peroxidase conjugate. All unbound material was then washed away, and a peroxidase enzyme substrate is added. The colour development is stopped, and the intensity of the colour was measured.

Human Osteoprotegerin (OPG) ELISA Kit

The assay employed the quantitative sandwich enzyme immunoassay technique. Antibody specific for OPG has been pre-coated onto a microplate. Samples were pipetted into the wells and OPG were bound by the immobilised antibody. After removing any unbound substances, a biotin-conjugated antibody specific for OPG was added to the wells. After washing, avidin conjugated Horseradish Peroxidase (HRP) was added to the wells. Following a wash to remove any unbound avidin-enzyme reagent, a substrate solution was added to the wells and colour develops in proportion to the amount of OPG bound in the initial step. The colour development was stopped, and the intensity of the colour was measured.

Statistical analysis

The statistical analysis was carried with SPSS software (Statistical Package for the Social Sciences, version 24, SSPS Inc, Chicago, IL, USA). Frequency tables with percentages were used for categorical variables, and descriptive statistics (mean and

standard deviation) were used for numerical variables. The Kolmogorov-Smirnov test was used to verify the normality of distribution. Quantitative data were described using range (minimum and maximum), mean, standard deviation and median. The significance of the obtained results was judged at the 5% level. ANOVA repeated measures test was used for normally distributed quantitative variables, to compare between more than two periods or stages. Post Hoc test (Bonferroni adjusted) was used to compare the values of the post-operatives to the pre-operative one and the immediate to the sixth week postoperative.

Results

In the present study, ten patients with severe dentofacial deformity were operated successfully under general anaesthesia, the operative time ranged from four to six hours. The second patient was not committed to the blood test appointments and dropped off from the study leading to decrease the sample size to nine patients. The estimated blood loss was about 650 cc to 850 cc, and none of the patients had a blood transfusion or experienced haemorrhage. Patients had phases of mild postoperative pain that declined progressively. Patients were encouraged to resume their normal activities as early as possible; they were discharged from the hospital on the second post operative day.

All patients reported decreased energy and fatigue in the early days after surgery and had difficulties with nutrition due to pain, oedema and paresthesia; however, no massive weight loss was reported. High caloric liquid diet was advised in the early postoperative period followed by a soft diet. Patients were instructed for oral health care at home and checked through the out-patient department.

Changes detected in Osteoprotegerin (OPG)

The levels of OPG started to increase immediately postoperatively (mean = 0.46 ± 0.08; p = 0.001). A significant increase in the concentration of OPG began at 3 days postoperatively and continued to raise significantly till the sixth week to reach 2.24 ± 0.30 ng/mL (p < 0.001) (Table 1 and Figure 2).

Table 1: Comparison between the different periods according to OPG and TGF-b ng/ml (n = 9)

	Pre	Immediate	3 days	1 Week	2 Weeks	4 Weeks	6 Weeks
OPG ng/ml							
Min. – Max.	0.24 – 0.46	0.35 – 0.54	0.45 – 0.68	0.54 – 0.98	0.97 – 1.80	1.20 – 2.40	1.80 – 2.90
Mean ± SD.	0.35 ± 0.07	0.46 ± 0.08*	0.59 ± 0.08*	0.84 ± 0.17*	1.24 ± 0.27*	1.73 ± 0.34*	2.24 ± 0.30*
Median	0.35	0.49	0.62	0.95	1.23	1.70	2.30
TGF-b ng/ml							
Min. – Max.	0.03 – 0.06	0.04 – 0.08	0.07 – 0.40	0.40 – 0.68	0.50 – 0.91	0.78 – 1.30	0.90 – 1.50
Mean ± SD.	0.04 ± 0.01	0.06 ± 0.01	0.21 ± 0.11	0.52 ± 0.09	0.77 ± 0.12	0.99 ± 0.16	1.28 ± 0.19
Median	0.04	0.05	0.20	0.51	0.80	0.93	1.30

*: Statistically significant at p ≤ 0.05. OPG, Osteoprotegerin; TGF-b, Transforming Growth Factor Beta.

Changes detected in Transforming Growth Factor Beta (TGF-β1)

There was an increase in the level of TGF-β1 level immediately post-operatively. However, the increase in TGF-β1 level was not statistically significant (mean = 0.06 ± 0.01 ng/mL; p = 0.135).

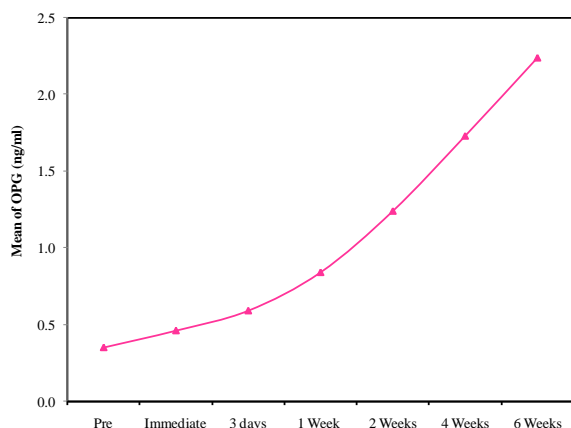


Figure 2: Comparison between the different periods according to OPG ng/ml

The concentration of TGF-β1 then significantly increased at three days postoperatively and continued to rise till the sixth week to reach 1.28 ± 0.19 ng/mL (p < 0.001) (Table 1 and Figure 3).

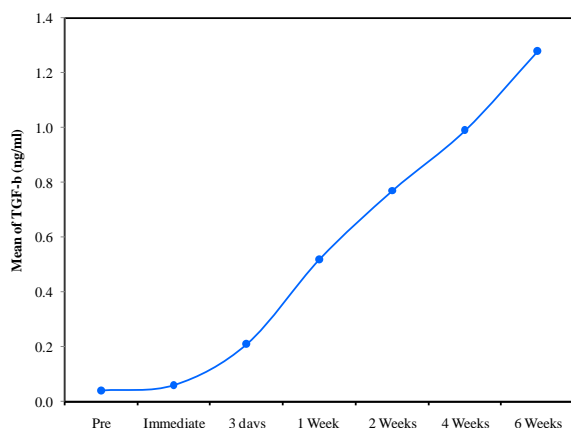


Figure 3: Comparison between the different periods according to TGF-β ng/ml

Discussion

The surgical stress response associated with orthognathic surgery may lead to significant immunosuppression and rise in the pro-inflammatory cytokines. Our results showed that both Osteoprotegerin (OPG) and Transforming Growth Factor Beta (TGF-β1) increased significantly postoperatively, the rise remained significant till the sixth week. These observed results may indicate a

significant alteration in the immunity of the patients undergoing orthognathic surgery.

Orthognathic surgery is a type of elective surgery in which patients should be free from any associated co-morbidities, and the intra-operative complications are largely controlled [1]. Therefore, any changes in the postoperative immunological callipers can be attributed to surgery. In the present study, OPG and TGF-β1 levels were assessed as immunological callipers to measure the traumatic effect of orthognathic surgery. TGF-β1 plays an important role in suppressing the immune system and wound healing. It increases during fracture healing as it is known as a potent cytokine and growth factor that controls a wide range of cellular responses [14]. While OPG is an antiresorptive cytokine that controls bone homeostasis through regulation of osteoclasts formation and activities [15], it is also believed that OPG/RANKL/RANK system participates in the regulation of pro-inflammatory cytokines and immune response [16], [17]. Recently, a growing body of evidence showed a significant increase in OPG after major elective surgery [18], [19].

Our results showed that the levels of OPG and TGF-β1 steadily increased throughout the postoperative period. In concordance with our findings, Soliman and colleagues [20] reported a significant postoperative increase in OPG level among patients who underwent orthognathic surgery, the level of OPG remained high till the six weeks of follow-up. Similarly, Kunisada and colleagues [21] showed that OPG local serum levels significantly increased time-dependently after osteotomy (P < 0.01). Another report demonstrated an increase in TGF-β1 appeared at the later postoperative time and remained at higher levels compared with preoperative levels among patients who underwent orthognathic surgery [22].

The findings of these reports suggest the presence of significant inflammatory response following orthognathic surgery. The surgical stress response, which is known to be a spontaneous protective mechanism can be harmful and severe if prolonged during the perioperative settings [23]. Kasahara and colleagues [7] followed 46 patients for the occurrence of postoperative complications in patients who showed systemic inflammatory response syndrome (SIRS) following maxillary and mandibular orthognathic surgery, the incidence of SIRS was 50% and the rate of postoperative complications was significantly higher among the SIRS group compared to non-SIRS group (27.3% vs 0%; p < 0.01). On the one hand, the increased levels of the two immunological callipers prove and demonstrate the immunosuppressive effect of orthognathic surgery. OPG and TGF-β1 both are inhibitory cytokines as OPG inhibits the differentiation of osteoclast precursors and TGF-β1 inhibits the proliferation of T cells, the activation of macrophages and also inhibits the formation of osteoclast precursors. On the other hand, the inhibitory activity of both callipers induces

bone remodelling and tissue healing. The increased OPG expression following bone osteotomies induces bone healing by the increase in the OPG/RANKL and the inhibition of RANKL/RANK ratios.

The present study has some strength points. All of the included patients were females, unifying the gender should control for the hormonal, metabolic, and general condition influence in the immune system and body response. Moreover, we assessed the changes in the immune callipers following orthognathic surgery which is an elective surgery indicated for young, immunocompetent, and systemically free patients, so any change in the immune parameters are presumed to be a direct consequence for the surgery itself. However, we acknowledge that the present study has limitations. The sample size of the included studies was relatively small which may affect the generalizability of our findings. Also, the rate of postoperative complications was not systematically assessed.

In conclusion, orthognathic surgery is associated with a significant rise in the pro-inflammatory cytokines till the sixth week postoperatively. These observed results may indicate a significant alteration in the immunity of the patients undergoing orthognathic surgery. Alertness of the immunosuppressive effect which may occur because of the surgery should be highly taken into consideration and has the top priority to avoid it perioperatively.

References

1. Posnick JC, Wallace J. Complex orthognathic surgery: assessment of patient satisfaction. *Journal of Oral and Maxillofacial Surgery*. 2008; 66(5):934-42. <https://doi.org/10.1016/j.joms.2008.01.014> PMID:18423283
2. Bauer RE, Ochs MW. Maxillary orthognathic surgery. *Oral Maxillofac Surg Clin North Am*. 2014; 26:523-537. <https://doi.org/10.1016/j.coms.2014.08.005> PMID:25199863
3. Hunt N. Commissioning of Orthognathic Treatment in England. *Fac Dent J*. 2015; 6:52-53. <https://doi.org/10.1308/204268515X14163115404610>
4. Venugoplan SR, Nanda V, Turkistani K, Desai S, Allareddy V. Discharge patterns of orthognathic surgeries in the United States. *Journal of Oral and Maxillofacial Surgery*. 2012; 70(1):e77-86. <https://doi.org/10.1016/j.joms.2011.09.030> PMID:22182664
5. Song YL, Yap AU. Orthognathic treatment of dentofacial disharmonies: its impact on temporomandibular disorders, quality of life, and psychosocial wellness. *CRANIO®*. 2017; 35(1):52-7. <https://doi.org/10.1080/08869634.2016.1147676> PMID:27077246
6. Kim Y-K. Complications associated with orthognathic surgery. *J Korean Assoc Oral Maxillofac Surg*. 2017; 43:3. <https://doi.org/10.5125/jkaoms.2017.43.1.3> PMID:28280704 PMID:PMC5342970
7. Kasahara K, Yajima Y, Ikeda C, Kamiyama I, Takaki T, Kakizawa T, Shibahara T. Systemic Inflammatory Response Syndrome and postoperative complications after orthognathic surgery. *The Bulletin of Tokyo Dental College*. 2009; 50(1):41-50. <https://doi.org/10.2209/tdcpublication.50.41> PMID:19622879
8. Finnerty CC, Mabvuure NT, Ali A, Kozar RA, Herndon DN. The surgically induced stress response. *Journal of parenteral and enteral nutrition*. 2013; 37(5 suppl):21S-9S.
9. Iwasaki M, Edmondson M, Sakamoto A, Ma D. Anesthesia, surgical stress, and "long-term" outcomes. *Acta Anaesthesiologica Taiwanica*. 2015; 53(3):99-104. <https://doi.org/10.1016/j.aat.2015.07.002> PMID:26235899
10. Ogawa K, Hirai M, Katsube T, Murayama M, Hamaguchi K, Shimakawa T, Naritake Y, Hosokawa T, Kajiwara T. Suppression of cellular immunity by surgical stress. *Surgery*. 2000; 127(3):329-36. <https://doi.org/10.1067/msy.2000.103498> PMID:10715990
11. Lennard TW, Shenton BK, Borzotta A, Donnelly PK, White M, Gerrie LM, Proud G, Taylor RM. The influence of surgical operations on components of the human immune system. *British Journal of Surgery*. 1985; 72(10):771-6. <https://doi.org/10.1002/bjs.1800721002> PMID:2412626
12. Guillou PJ. Adjuvant biological response modifiers after major surgery or trauma. *British journal of surgery*. 1995; 82(6):721-3. <https://doi.org/10.1002/bjs.1800820602> PMID:7627496
13. Weledji EP. Cytokines and the metabolic response to surgery. *J Clin Cell Immunol*. 2014; 5(2):1-5.
14. Li MO, Wan YY, Sanjabi S, Robertson AK, Flavell RA. Transforming growth factor- β regulation of immune responses. *Annu. Rev. Immunol*. 2006; 24:99-146. <https://doi.org/10.1146/annurev.immunol.24.021605.090737> PMID:16551245
15. Lacey DL, Timms E, Tan HL, Kelley MJ, Dunstan CR, Burgess T, Elliott R, Colombero A, Elliott G, Scully S, Hsu H. Osteoprotegerin ligand is a cytokine that regulates osteoclast differentiation and activation. *Cell*. 1998; 93(2):165-76. [https://doi.org/10.1016/S0092-8674\(00\)81569-X](https://doi.org/10.1016/S0092-8674(00)81569-X)
16. Maruyama K, Takada Y, Ray N, Kishimoto Y, Penninger JM, Yasuda H, Matsuo K. Receptor activator of NF- κ B ligand and osteoprotegerin regulate proinflammatory cytokine production in mice. *The Journal of Immunology*. 2006; 177(6):3799-805. <https://doi.org/10.4049/jimmunol.177.6.3799> PMID:16951341
17. Ohigashi I, Nitta T, Lkhagvasuren E, Yasuda H, Takahama Y. Effects of RANKL on the thymic medulla. *European journal of immunology*. 2011; 41(7):1822-7. <https://doi.org/10.1002/eji.201141480> PMID:21706487
18. Galeone A, Brunetti G, Rotunno C, Oranger A, Colucci S, de Luca Tuppiti Schinosa L, Zallone A, Grano M, Paparella D. Activation of the receptor activator of the nuclear factor- κ B ligand pathway during coronary bypass surgery: comparison between on-and off-pump coronary artery bypass surgery procedures. *European Journal of Cardio-Thoracic Surgery*. 2013; 44(2):e141-7. <https://doi.org/10.1093/ejcts/ezt244> PMID:23671202
19. Doshi BM, Perdrizet GA, Hightower LE. Wound healing from a cellular stress response perspective. *Cell Stress and Chaperones*. 2008; 13(4):393-9. <https://doi.org/10.1007/s12192-008-0059-8> PMID:18626792 PMID:PMC2673931
20. Soliman S, Ahmed M. The Effect of Orthognathic Surgery on Osteoprotegerin as Immunological Caliper of Bone Healing. *Open access Macedonian journal of medical sciences*. 2016; 4(4):705-8. <https://doi.org/10.3889/oamjms.2016.123> PMID:28028419 PMID:PMC5175527
21. Kunisada Y, Shimo T, Masui M, Yoshioka N, Ibaragi S, Matsumoto K, Okui T, Kurio N, Domae S, Kishimoto K, Nishiyama A. Detection of sonic hedgehog in patients undergoing orthognathic surgery. *International Journal of Surgery Open*. 2016; 5:1-4. <https://doi.org/10.1016/j.ijso.2016.09.002>
22. Zingler S, Hakim E, Finke D, Brunner M, Saure D, Hoffmann J, Lux CJ, Erber R, Seeberger R. Surgery-first approach in orthognathic surgery: Psychological and biological aspects—A prospective cohort study. *Journal of Cranio-Maxillofacial Surgery*. 2017; 45(8):1293-301. <https://doi.org/10.1016/j.jcms.2017.05.031> PMID:28684072
23. Ahlers O, Nachtigall I, Lenze J, Goldmann A, Schulte E, Höhne C, Fritz G, Keh D. Intraoperative thoracic epidural anaesthesia attenuates stress-induced immunosuppression in patients undergoing major abdominal surgery. *British journal of anaesthesia*. 2008; 101(6):781-7. <https://doi.org/10.1093/bja/aen287> PMID:18922851