



An older male with an unusual presentation of disseminated coccidioidomycosis



Matthew S. Lokant^a, Joy J. Juskowich^{b,*}, Shu Xian Lee^c, Arif R. Sarwari^d

^a West Virginia University Department of Medicine, Department of Medicine, P.O. Box 9168, Morgantown, WV 26506, United States of America

^b West Virginia University Department of Medicine, Sections of Hospital Medicine and Infectious Diseases, Department of Medicine, P.O. Box 9160, Morgantown, WV 26506, United States of America

^c West Virginia University Department of Medicine, Section of Infectious Diseases, Department of Medicine, P.O. Box 9163, Morgantown, WV 26506, United States of America

^d West Virginia University Department of Medicine, Section of Infectious Diseases, Department of Medicine, P.O. Box 9156, Morgantown, WV 26506, United States of America

ARTICLE INFO

Article history:

Received 10 July 2021

Received in revised form 25 August 2021

Accepted 30 August 2021

Available online xxxx

Keywords:

Peritoneal coccidioidomycosis

Disseminated coccidioidomycosis

Coccidioides species

Endemic mycoses

ABSTRACT

Coccidioidomycosis is a fungal disease endemic to the southwestern United States and other areas in the Western Hemisphere. Infection is usually acquired through inhalation. While infection is most often asymptomatic, early respiratory illness and infrequently extrapulmonary dissemination may occur. Immunocompromised individuals, particularly those with impaired cell-mediated immunity, are at greatest risk for dissemination. We present an atypical case of disseminated coccidioidomycosis in an immunocompetent male manifesting as peritoneal disease diagnosed during elective inguinal herniorrhaphy.

© 2021 The Authors. Published by Elsevier Ltd.

CC-BY-NC-ND 4.0

Introduction

Coccidioidomycosis, endemic to the southwestern United States – with increasing recognition in more northern parts of the country – as well as parts of Mexico and Central and South America, is a systemic dimorphic fungal disease with a growing impact on public health. Infection is caused by *Coccidioides immitis* or *Coccidioides posadasii*, which have distinct geographic niches but are indistinguishable based on clinical presentation and microbiologic testing. Primary pulmonary infection is acquired by inhalation. Extrapulmonary spread is rare, with immunocompromised persons being at increased risk [1,2]. Given its variety of presentations, ranging from respiratory illness to meningitis, clinicians must be vigilant in considering coccidioidomycosis. We present a case of atypical disseminated coccidioidomycosis in an immunocompetent patient with a pertinent exposure history.

Case presentation

A seventy-one-year-old immunocompetent Caucasian male born and raised in West Virginia who wintered in Tucson, Arizona, developed sudden onset of severe influenza-like illness (ILI), characterized by fevers, rigors, and nonproductive cough. His medical history included an asymptomatic left inguinal hernia diagnosed two years prior to his presentation. He was a retired chemical engineer who enjoyed golfing and gardening. Laboratory data revealed an absolute eosinophil count of $2.94 \times 10^3/\mu\text{L}$ (reference range $\leq 0.50 \times 10^3/\mu\text{L}$) and C-reactive protein (CRP) of 80.3 mg/L (reference range ≤ 8.0 mg/L), with otherwise normal results. A chest radiograph was normal.

The patient's initial symptoms improved spontaneously over two months. He subsequently experienced night sweats, unintentional weight loss of twenty-five pounds, and pain and swelling of his ankles and feet bilaterally. Four months after onset of his ILI symptoms, he underwent uncomplicated elective left inguinal herniorrhaphy. Intraoperative findings noted a thickened distal end of the hernia sac with a shaggy internal appearance. At a postoperative follow-up appointment, he was afebrile but noted to have coarse crackles at the right lung base and subtle left ankle edema.

* Corresponding author.

E-mail addresses: mlokant1@hsc.wvu.edu (M.S. Lokant),

jjuskowi@hsc.wvu.edu (J.J. Juskowich), shuxian.lee@hsc.wvu.edu (S.X. Lee), asarwari@hsc.wvu.edu (A.R. Sarwari).

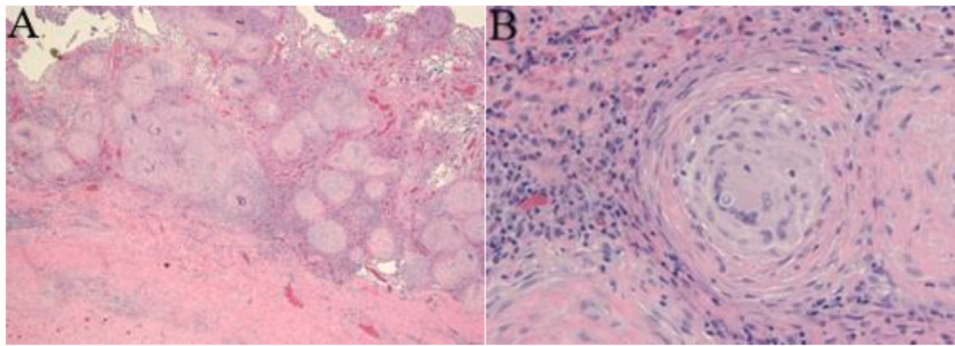


Fig. 1. H&E staining showing granulomatous inflammation involving peritoneal aspect of hernia sac (A) Numerous rounded small granulomas containing multinucleated histiocytes and associated fibrosis (200x) (B) Occasional large round organisms with refractile boarder (400x).

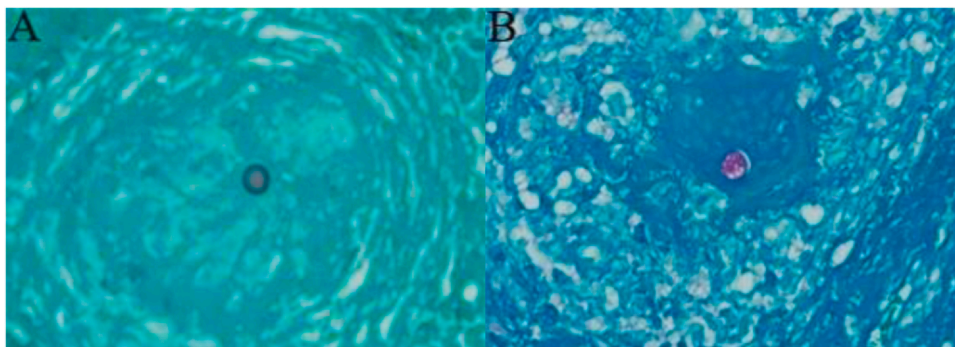


Fig. 2. GMS (A) and PAS (B) staining showing spherules containing endospores (400x).

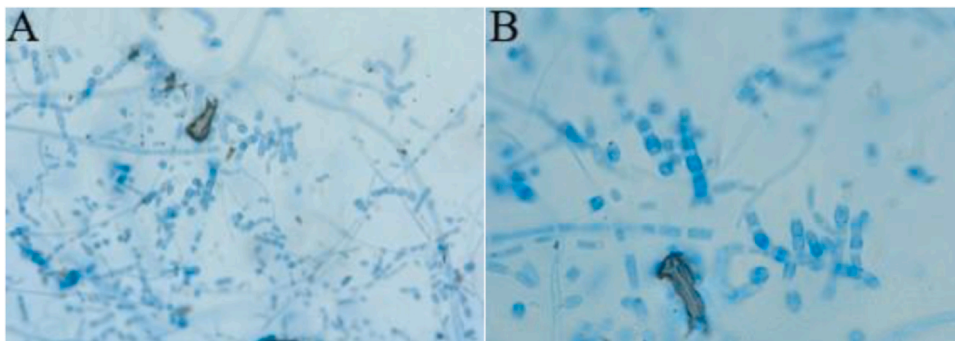


Fig. 3. Lactophenol cotton blue staining showing barrel-shaped arthroconidia (A) (400x) and (B) (1000x).

Coccidioides IgM and IgG by immunodiffusion were both positive and compliment fixation antibody titer was 1:4. Surgical pathology of the hernia sac showed granulomatous inflammation with fungal organisms identified, favoring *Coccidioides* species. Hematoxylin and eosin (H&E) staining revealed focally necrotizing granulomatous inflammation involving the peritoneal aspect of the hernia sac with numerous rounded small granulomas containing multinucleated histiocytes and associated fibrosis as well as occasional large round organisms with a refractile border (Fig. 1). Grocott methenamine silver (GMS) staining and Periodic acid-Schiff (PAS) staining showed spherules containing endospores (Fig. 2). Lactophenol cotton blue staining showed barrel-shaped arthroconidia (Fig. 3). Fontana-Masson staining was also positive. Operative fungal culture grew *Coccidioides* species, confirming the diagnosis of peritoneal coccidioidomycosis. Following a three-month course of fluconazole, the patient's constitutional symptoms had resolved and his absolute eosinophil count and CRP normalized.

Discussion

Coccidioidomycosis is emerging as a severe public health problem due to its increasing incidence, large number of undiagnosed cases, and when compared to other North American endemic mycoses, a greater propensity for severe and disseminated disease [1,3]. As most infections are either asymptomatic or mildly symptomatic and resolve without treatment, reported cases of coccidioidomycosis likely underestimate the actual number. Annually, there are an expected 150,000 coccidioid infections with severe disease observed in approximately one-third of cases [4]. The proportion of severe and disseminated disease is expected to rise over time, owing to increased pathogen exposure related to more soil disruption, larger immunocompromised population due to greater longevity in the setting of medical advancements, and expanded travel opportunities [1]. In the environment, *Coccidioides* species grow as mycelia and produce arthroconidia, which remodel into spherules when inhaled

in mammalian hosts [5]. Exposure to only one or a small number of arthroconidia may result in disease. Early respiratory illness, commonly consisting of cough, chest pain, shortness of breath, fever, and fatigue, is the hallmark of primary infection [1]. While most episodes are self-limited, approximately 5–10% of persons develop complications or chronic pulmonary disease [2]. Following pulmonary infection, dissemination may occur primarily through the hematogenous route; however, extrapulmonary disease is only observed in approximately 0.5% of coccidioidal infections [6]. Although most persons with extrapulmonary spread do not have an identified immunodeficiency, immunocompromised hosts are particularly susceptible [7]. It has historically been well-recognized that African or Filipino ancestry are risk factors for dissemination, though the magnitude is unclear. Other risk factors for dissemination include decreased cell-mediated immunity, infection during pregnancy, and male gender. While complications of dissemination may present quickly within weeks to months, nearly all cases emerge within two years. Disseminated disease is divided into meningeal, the most serious form of disseminated infection, and nonmeningeal, most often involving skin, joints, and bone. Peritoneal coccidioidomycosis is a rare manifestation [1].

Clinical suspicion in the setting of endemic exposure is paramount for diagnosing coccidioidomycosis. Patients are often treated with multiple courses of oral antibacterials before a diagnosis is established. Laboratory data may show mild increases in the peripheral leukocyte count and inflammatory markers. Chest radiographs are abnormal in more than half of patients with early respiratory infection. Diagnosis is typically established by detecting anticoccidioidal antibodies, identifying spherules in histopathology, or recovering *Coccidioides* species from fungal culture [1]. Although anticoccidioidal complement fixation antibody titers of 1:16 or greater have been associated with extrapulmonary dissemination, definitive diagnosis of disseminated disease requires identification of *Coccidioides* species via histopathology, culture, and/or ribosomal ribonucleic acid sequencing from at least one extrapulmonary site [8,9].

In most cases, treatment of disseminated disease consists of oral antifungal therapy with either fluconazole or itraconazole. Lipid formulation of amphotericin B may be required for those with azole failure, rapidly progressive disease, or disease in critical locations, such as extensive or limb-threatening bone disease or vertebral infection resulting in cord compromise. In some persons, particularly those with extensive skeletal involvement, surgical debridement is required [1,7]. Monitoring anticoccidioidal complement fixation antibody titers may be useful for following disease activity [1].

With a greater proportion of older adults living with a variety of chronic diseases and immunocompromising conditions, populations are at heightened risk for serious coccidioidal infections. Groups with compromised cellular immunity due to disease or immunosuppressive medications are especially susceptible [1,8]. With advancements in treatment and prevention of fungal infections, clinicians must understand this increasingly relevant disease process and maintain vigilance for its presence in patients with appropriate epidemiologic risk factors. Our patient demonstrates the remarkable potential for coccidioidomycosis to present atypically. Peritoneal involvement, which is extremely unusual, may present as an inguinal hernia, peritonitis, or abdominal or pelvic masses, often in absence of significant pulmonary symptoms or chest radiograph abnormalities. Intraoperatively, hernia sacs involved with coccidioidomycosis demonstrate nodular studding as can be seen with tuberculosis, other fungal infections, or metastatic disease as well as thickening and granulomatous inflammation like that found in our patient [6,8,9]. In the case of peritoneal coccidioidomycosis presenting as an inguinal hernia, hernia repair in combination with

antifungal therapy is recommended as definitive management to minimize granulomatous seeding and avoid fistulous tracking [10].

In conclusion, our immunocompetent patient had a unique presentation of disseminated coccidioidomycosis (following resolution of early ILI) manifesting as peritoneal disease confirmed during elective inguinal herniorrhaphy.

Ethical Approval

This case was carried out according to the laws and guidelines set forth by the West Virginia University School of Medicine. This case report meets the standards of the West Virginia University Medicine Ethics Committee. The manuscript is in line with the Recommendations for the Conduct, Reporting, Editing, and Publication of Scholarly Work in Medical Journals. All authors have seen and approved the final version of the manuscript. The article is our original work, has not received prior publication, and is not under consideration for publication elsewhere.

Consent

Written informed consent was obtained from the patient for publication of this case report and accompanying images. A copy of the written consent is available for review by the Editor-in-Chief of this journal on request.

CRediT authorship contribution statement

Matthew S. Lokant: Investigation, Writing – original draft, Writing – reviewing and editing. Joy J. Juskowich: Investigation, Writing – original draft, Writing – reviewing and editing, Visualization. Shu Xian Lee: Resources, Writing – reviewing and editing. Arif R. Sarwari: Conceptualization, Writing – reviewing and editing, Supervision, Project administration.

Disclosures

The authors have no conflicts of interest to disclose. No funding was provided.

References

- [1] Galgiani JN. Coccidioidomycosis. In: Bennett JT, Dolin R, Blaser MJ, editors. *Mandell, Douglas, and Bennett's Principles and Practice of Infectious Diseases*. 9th ed. Philadelphia, PA: Elsevier Inc; 2020. p. 3190–200.
- [2] Valley fever (coccidioidomycosis), Centers for Disease Control and Prevention. (<https://www.cdc.gov/fungal/diseases/coccidioidomycosis/index.html>). (Updated March 29, 2021) (Accessed May 30, 2021).
- [3] McCotter OZ, Benedict K, Engelthaler DM, Komatsu K, Lucas KD, Mohle-Boetani JC, et al. Update on the epidemiology of coccidioidomycosis in the United States. *Med Mycol* 2019;57(1):S30–40. <https://doi.org/10.1093/mmy/myy095>
- [4] Blair JE. Coccidioidal meningitis: update on epidemiology, clinical features, diagnosis, and management. *Curr Infect Dis Rep* 2009;11:289–95. <https://doi.org/10.1007/s11908-009-0043-1>
- [5] Nguyen C, Barker BM, Hoover S, Nix DE, Ampel NM, Frelinger JA, et al. Recent advances in our understanding of the environmental, epidemiological, immunological, and clinical dimensions of coccidioidomycosis. *Clin Microbiol Rev* 2013;26(3):505–25. <https://doi.org/10.1128/CMR.00005-13>
- [6] Perez Jr. JA, Arsura EL. Peritoneal coccidioidomycosis diagnosed incidentally at herniorrhaphy. *West J Med* 1993;158(4):406.
- [7] Galgiani JN, Ampel NM, Blair JE, Catanzaro A, Geertsma F, Hoover SE, et al. Infectious Diseases Society of America (IDSA) clinical practice guideline for the treatment of coccidioidomycosis. *Clin Infect Dis* 2016;63(6):e112–46. <https://doi.org/10.1093/cid/ciw360>. (2016).
- [8] Phillips P, Ford B. Peritoneal coccidioidomycosis: case report and review. *Clin Infect Dis* 2000;30(6):971–6. <https://doi.org/10.1086/clinids/31.2.628>
- [9] Storage TR, Segal J, Brown J. Peritoneal coccidioidomycosis: a rare case report and review of the literature. *J Gastrointest Liver Dis* 2015;24(4):527–30. <https://doi.org/10.15403/jgld.2014.1121.244.coc>
- [10] Buchmiller-Craig TL. Initial presentation of coccidioidomycosis during inguinal herniorrhaphy. *Hernia* 2003;7(2):92–4. <https://doi.org/10.1007/s10029-002-0100-2>