

Single Case

Appendicitis after Appendectomy: A Rare Presentation of Acute Appendicitis as Stump Appendicitis

Fareed Ahmed^a Sadia Asad^a Shaharyar Salim^b
Salman Muhammad Soomar^a

^aDepartment of Emergency Medicine, Aga Khan University Hospital, Karachi, Pakistan;

^bDepartment of Emergency Medicine, Aga Khan University, Karachi, Pakistan

Keywords

Stump · Appendicitis · Inflammation · Emergency · Gastroenterology

Abstract

Appendicitis is one of the frequent complaints for which patients visit the Emergency Department. Appendectomy is one of the most commonly performed procedures. Stump appendicitis is a rare but severe complication of appendectomy due to the inflammation of the remaining part of the appendix. Because it is rare and partly due to physicians' lack of understanding of this entity, the diagnosis is highly delayed, leading to severe complications including perforation or peritonitis. This article aims to raise the importance and awareness and shed light on how possibly it could be avoided.

© 2022 The Author(s).

Published by S. Karger AG, Basel

Introduction

Abdominal pain is one of the most common complaints for which patients present to ER, and of the differentials of abdomen pain, appendicitis is the most common surgical disorder [1]. Appendicitis is one of the frequent complaints for which patients visit ER.

They usually present with classic lower abdominal pain, fever, and anorexia [2]. Diagnosis is usually suggestive from the typical history and classic pattern of the pain confirmed with the abdominal imaging. These patients are typically planned for appendectomy, one of the most common surgical procedures performed in children and adults [2]. Post-operative

short-term complications include bleeding, wound infection, and intra-abdominal abscess, and delayed complications can include nerve injury, adhesions hernias, and small bowel obstruction. Stump appendicitis (SA) is one of the rare long-term complications under-reported in literature, with the incidence of 1 in 50,000 cases [3].

SA, also known as remnant appendicitis, is the inflammation that develops in the remaining part of the appendix after an unintentional incomplete appendectomy [4] and gives a clinical presentation similar to that of acute appendicitis ranging from a few days to a few years after the procedure. SA is under-recognized partly due to clinicians' and radiologists' lack of acquaintance with this entity [5]. Therefore, given a clear history of appendectomy, the emergency physician usually rules out the differential of SA, leading to severe complications like perforation or peritonitis. We write this case report to raise awareness of this rare but clinically significant diagnosis.

Case Report

A sixty-six-year-old gentleman known for having hypertension, ischemic heart disease, rheumatoid arthritis, cerebrovascular accident, mitral valve replacement presented to the Emergency Room with complaints of fever for 4 days, high-grade continuous, without chills and rigors, which was relieved after taking paracetamol, diarrhea for 2 days, 3–4 episodes per day, watery in consistency, no blood or mucous, not foul-smelling, and lower abdominal pain since morning. Initially, the pain was diffuse that later became sharp and localized to the right iliac fossa. It was moderate to severe in intensity, with a subjective pain score of 7 out of 10. It had a sudden onset without any radiation. There were no aggravating factors, but I used to get mild relief by taking pain killers. Along with this, the patient had experienced multiple fever spikes of 101–103 F degrees and diarrheal episodes of 4–5 that were watery.

On arrival, the patient was febrile (temperature 38.2 C), but the rest of his vitals were unremarkable. He was sick-looking, lethargic, and in pain. On examination, McBurney's scar was visible in the right iliac fossa. The region was tender with positive Rovsing's sign and rebound tenderness on palpation. The rest of the examination was unremarkable.

In the Emergency Room, the patient was resuscitated. He was kept nothing per oral with adequate analgesia given to the patient, and he was hydrated well. Baseline investigations were done that showed a high total leukocyte count ($15.7 \times 10^9/L$ [range 4.8–11.3]) with a neutrophilic shift (88.4% [range 4.9–76.2]). The rest of the labs were unremarkable. The pain was not settling despite adequate analgesia, CT abdomen was done, and the general surgery team was taken on board.

The CT scan showed findings suggestive of appendicitis. It demonstrated small inflamed appendicular stumps, thickening walls, and intraluminal free air. Based on this, a diagnosis of SA was made (Fig. 1a, b). The patient was admitted in special care under the general surgery team. Similar management was continued with appropriate antibiotics, analgesics, hydration, anti-emetics, and the patient kept nothing per oral. The patient improved clinically within a few days, and the inflammatory markers began to decline. As he started tolerating an oral diet, he was eventually discharged on antibiotics and follow-up in the clinic.

Discussion

Emergency Department is a place where there is an encounter of various surgical and medical complaints. Also, patients usually present with an imprecise history, and thereby examining such patients is not easy. However, timely diagnosis and early treatment are

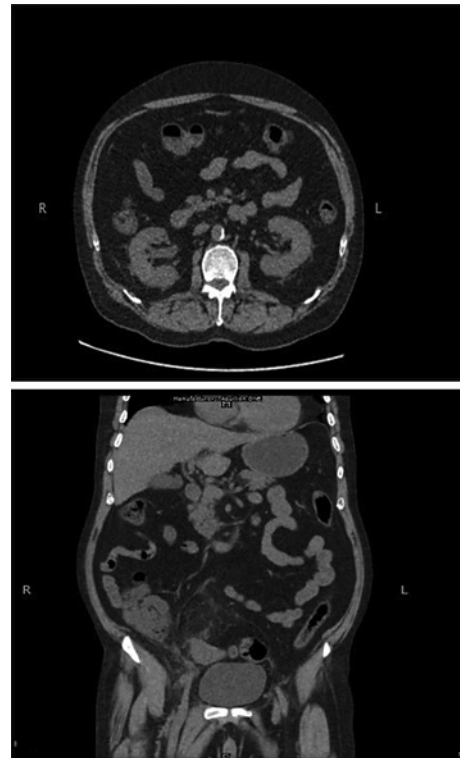


Fig. 1. **a** Representing axial view and **(b)** representing coronal view of the inflamed base of appendix known as SA. **a, b** Showing axial and coronal view, respectively, which represent small appendicular stump with evidence of wall thickening with significant surrounding inflammatory changes suggestive of SA.

paramount for good outcomes. Typically, in ED, making differentials diagnosis and management plan starts from a broad manner which is then narrowed down as per investigation findings. But sometimes, a typical presentation is very indicative of ruling in or excluding any particular diagnosis. This saves time and resources and more importantly helps to start the management earlier.

SA is a rare under-reported complication after appendectomy, with a reported incidence of 1 in 50,000 cases, first described by Rose in 1945 and Baumgartner in 1949 [3]. The true incidence of SA is unknown but is thought to be between 0.002% and 0.15% [5]. It has been seen to happen at any age (11–72 years) and at any time following appendectomy (2 months–50 years) [6]. The most common presenting symptoms are right lower abdominal pain, nausea, vomiting, and history of appendectomy, as seen in this case. Partly owing to physicians' lack of knowledge and being a rare entity, it can pose a diagnostic challenge to the treating physicians if they are unfamiliar with it.

SA is believed to happen after complicated appendicitis, but other factors like extensive inflammation, incomplete surgical field view, and poor surgical experience also contribute. Liang et al. [7] reported inadequate visualization of the appendiceal base essentials, most important factor in developing SA, because it increases the risk of subtotal resection and subsequent luminal occlusion and inflammation (i.e., SA) [5]. Therefore, it is partly related to the severity of the disease over the surgical technique used, open versus laparoscopic [4]. Many authors and literature suggest leaving behind a stump length of less than 5 mm as a longer length could allow for the fecalith impaction [8]. Therefore, it is recommended not to leave the appendiceal stump larger than 3 mm during an appendectomy [9]. Specific positional factors including a retrocecal appendix, subserosal appendix, and a duplicated appendix make it challenging to identify the cecal appendicular junction, contributing to this complication. It can be overcome by correctly identifying the appendicular base by following the cecal tenia coli and a complete dissection of any subserosal appendix [9].

A few differentials also clinically mimic SA, including Crohn's disease, residual surgical drain tract, and epiploic appendicitis. Therefore, emergency physicians' familiarity with SA may lead to earlier diagnosis and treatment, preventing unnecessary complications.

SA is a rare and dangerous complication post-appendectomy. Being unfamiliar with this entity, it can be tough to diagnose it. Our case report is aimed to raise awareness for it as a differential for right lower quadrant abdominal pain in any patient, despite a prior history of appendectomy or a surgical scar seen.

Statement of Ethics

Approval was provided by Ethical Review Committee of Department of Emergency Medicine, Aga Khan University, Karachi, Pakistan (Reference Number 312-2022). Written informed consent was obtained from the patient for publication of the details of their medical case and any accompanying images.

Conflict of Interest Statement

The authors declare no conflict of interest.

Funding Sources

No funding received.

Author Contributions

Conceptualization: Dr. Fareed Ahmed and Mr. Salman Muhammad Soomar. Investigation: Dr. Fareed Ahmed and Dr. Sadia Asad. Writing original draft: Dr. Fareed Ahmed and Mr. Salman Muhammad Soomar. Writing – review and editing: Drs. Fareed Ahmed, Sadia Asad, and Shahryar Salim.

Data Availability Statement

Data will be available upon the reasonable request as it has patient identifiers and proper permissions are required to handover/share.

References

- 1 Hou SK, Chern CH, How CK, Kao WF, Chen JD, Wang LM, et al. Diagnosis of appendicitis with left lower quadrant pain. *J Chin Med Assoc.* 2005;68(12):599–603.
- 2 Stringer MD. Acute appendicitis. *J Paediatr Child Health.* 2017;53(11):1071–6.
- 3 Geraci G, Lena A, D'Orazio B, Cudia B, Rizzuto S, Modica G. A rare clinical entity: stump appendicitis. Case report and complete review of literature. *Clin Ter.* 2019;170(6):e409–e17.
- 4 Johnston J, Myers DT, Williams TR. Stump appendicitis: surgical background, CT appearance, and imaging mimics. *Emerg Radiol.* 2015;22(1):13–8.
- 5 Enzerra MD, Ranieri DM, Pickhardt PJ. Stump appendicitis: clinical and CT findings. *AJR Am J Roentgenol.* 2020;215(6):1363–9.

- 6 Yuksel Y, Ergun T, Torun E, Ozen O. Recurrent stump appendicitis. [Am J Emerg Med](#). 2021;44:481.e3–e5.
- 7 Liang MK, Lo HG, Marks JL. Stump appendicitis: a comprehensive review of literature. [Am Surg](#). 2006 Feb; 72(2):162–6.
- 8 Casas MA, Dreifuss NH, Schlottmann F. High-volume center analysis and systematic review of stump appendicitis: solving the pending issue. [Eur J Trauma Emerg Surg](#). 2021. official publication of the European Trauma Society.
- 9 Mejri A, Arfaoui K, Aloui B. Stump appendicitis: a myth that can become reality. [Pan Afr Med J](#). 2020;36:274.