

Contents lists available at [ScienceDirect](http://www.sciencedirect.com)

International Journal of Surgery Case Reports

journal homepage: www.casereports.com

Isolated hydatid cyst of spleen: A rare case with rare presentation



Dr. Purushottam Kumar (Senior Resident)^{a,*}, Dr. Arshad Hasan (Senior Resident)^b,
Dr. Manoj Kumar (Associate Professor)^c, Dr. Veena Singh (Assistant Professor)^d

^a Dept. of General Surgery, AIIMS, Patna, India^b Dept. of Surgery, AIIMS, Patna, India^c Dept. of Surgery, AIIMS, Patna, India^d Dept. of Plastic Surgery, AIIMS, Patna, India

ARTICLE INFO

Article history:

Received 9 August 2016

Received in revised form 6 October 2016

Accepted 6 October 2016

Available online 12 October 2016

Keywords:

Hydatid cyst

Spleen

Splenectomy

ABSTRACT

Hydatid cyst is a common health problem of world in sheep grazing area. Liver is the most commonly involved organ. Splenic hydatid cyst is uncommon and its isolated involvement is very rare. We are presenting a case of isolated hydatid cyst of spleen in a sixty one year old female patient with complaints of pain in the left hypochondrium, dyspepsia and features of gastritis for the last 1 year. The diagnosis was confirmed by Contrast enhanced CT scan (CECT). Laparoscopic splenectomy was performed. The aim of this case report is to emphasize that the most important factor in diagnosing splenic hydatid cyst is the awareness of its possibility and the intraoperative precautions which will decrease morbidity and mortality in the postoperative period.

© 2016 Published by Elsevier Ltd on behalf of IJS Publishing Group Ltd. This is an open access article under the CC BY-NC-ND license (<http://creativecommons.org/licenses/by-nc-nd/4.0/>).

1. Introduction

Hydatid disease caused by the tapeworm *Echinococcus granulosus*. It is prevalent in sheep grazing area. Humans are intermediate host. Liver followed by lung are common sites of involvement. Surgery is the mainstay of treatment. Splenic hydatid is a rare entity and isolated involvement of spleen is an exceptional. We are reporting a case of isolated hydatid cyst of spleen in a sixty one year female patient who was treated by laparoscopic splenectomy. This case report was prepared according to the SCARE guidelines, which aim for consensus-based, clinical case reporting guideline development [1].

2. Case report

A sixty one year old female patient presented with complaints of pain in the left hypochondrium with dyspepsia and heart burn for the past one year. Pain was dull aching and intermittent in nature, and increases after intake of meal. It resolved spontaneously after 1–2 h. There was no history of pet dogs or sheep at home. Abdominal examination showed no organomegaly. Laboratory blood tests were all within normal limits. X-ray chest and abdomen were unremarkable. Upper GI endoscopy was also normal (Figs. 1–4).

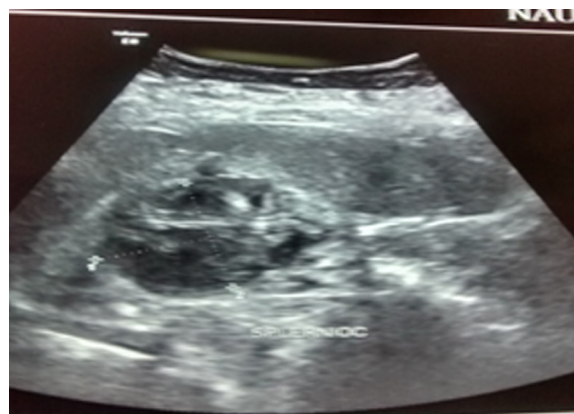

Fig. 1. Abdominal ultrasonography showed a well defined cystic lesion of about 46 ml volume is seen in the splenic parenchyma near the splenic hilum showing thick internal membranes and echoes.

An ultrasound abdomen showed a well defined cystic lesion of about 46 ml volume in the splenic parenchyma near the hilum showing thick internal membranes and echoes.

CECT abdomen confirmed the USG findings demonstrating evidence of well defined complex cystic lesion of approximate size of 4.3 × 3.2 cm in medial aspect of splenic parenchyma with wall calcification and internal floating hyper dense membranes, suggestive of hydatid cysts. There was no involvement of liver or other organs. Patient was negative for serum IgG antibodies against *Echinococcus*.

* Corresponding author at: Balaji nagar, Shaguna more, C/O Shri Narayan Singh, Patna-801503, Bihar, India.

E-mail addresses: drpkumar2k3@gmail.com (P. Kumar), arshadsurgery@gmail.com (A. Hasan), docmk.2002@yahoo.co.in (M. Kumar), drsveena@gmail.com (V. Singh).

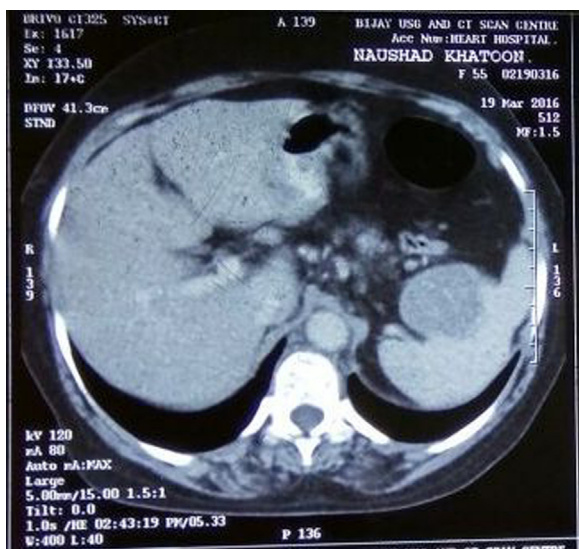


Fig. 2. Contrast enhanced CT scan abdomen demonstrating evidence of well defined complex cystic lesion of approximate size of 4.3 × 3.2 cm in medial aspect of splenic parenchyma with wall calcification and internal floating hyperdense membranes, suggestive of hydatid cysts.

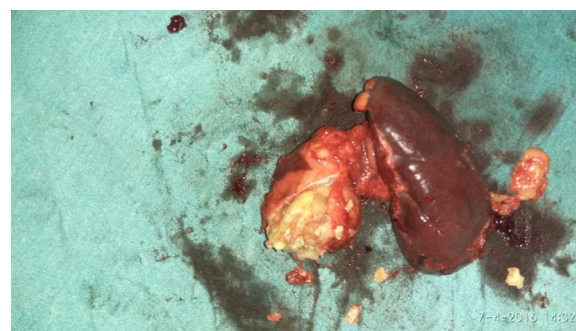

Fig. 4. Cut section of cyst wall.

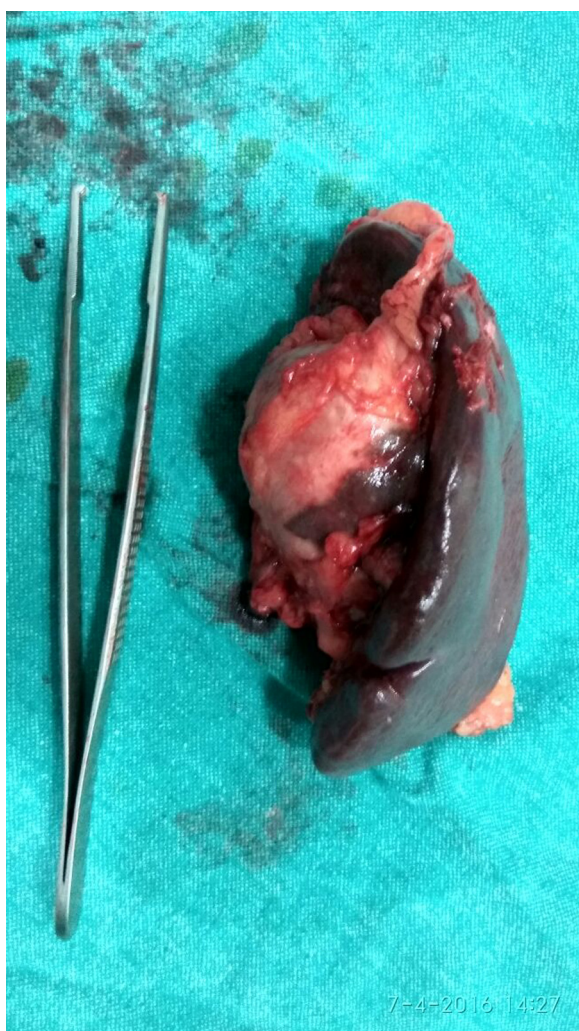

Fig. 3. Gross specimen of the spleen following its removal.

After Pneumococcal and H.influenza vaccination, laparoscopic splenectomy was performed. Four trocars were placed. First one (10 mm) was placed in the anterior axillary line below the left costal margin, second operating trocar (5 mm) at mid-axillary line below the left costal margin, third operating trocar (5 mm) at mid-clavicular line and fourth operating trocar (10 mm) was placed at 2–3 cm below the left costal margin.

After placement of the trocars, dissection of the splenophrenic ligament and splenocolic ligament was done. Tissues and vessels in the gastrosplenic ligament were transected. Splenorenal ligament and splenic hilum were dissected and splenic artery and vein were identified and stapled. Following, the spleen was removed and extracted via a 3 cm incision over left para-umbilical region.

Postoperative period was uneventful. Patient was followed at 2 weeks, at 1 month, 3 months and 6 months with no specific complains.

3. Discussion

Hydatid disease occurs mainly in sheep-grazing areas of the world. Man is an accidental host of *Echinococcus granulosus* after ingestion of eggs. Larva liberated from eggs penetrates the bowel mucosa to enter the portal system thereby spreading to various organs [2]. Although hydatid disease can affect any part of the body, the cysts are by and large found in the liver (55.6%) and lungs (30%) [3,4]. According to Gupta et al., cysts are found in the liver (55%–60%), lungs (30%), kidney (2.5%), heart (2.5%), bones (2%), muscles (1%), brain (0.5%) and spleen (1.5%) [5]. The incidence of splenic involvement by hydatid cysts in relation to the rest of the abdominal viscera is extremely low, constituting 0.5 to 4% of all cases of hydatidosis [5].

Symptoms of splenic hydatidosis are left hypochondriac mass, dull aching pain, dyspepsia, heart burn, constipation and dyspnea, infection, rupture or fistulization to the colon. Differential diagnosis includes other splenic cystic lesions, such as simple cyst, abscess, hematoma, and neoplasm.

Diagnosis is confirmed by abdominal ultrasound and CT scan. On ultrasound of abdomen, splenic hydatid cyst may present as an anechoic spherical cystic lesion with hyperechoic marginal calcification. CT abdomen confirms the cystic lesion with or without daughter cysts within the spleen. Other tests are casoni test and enzyme linked immunoabsorbent assay (ELISA).

This case report emphasizes that we should always suspect the uncommon presentation of isolated hydatid cyst of spleen whenever a patient presents with splenomegaly. Since splenectomy is the treatment of choice proper precautions should be taken during surgery to prevent dissemination, seeding or anaphylactic shock. This will decrease the morbidity and mortality in the postoperative period.

Conflict of interest

None.

Funding

No.

Ethical approval

Not applicable.

Consent

Yes.

Author contribution

1. Purushottam Kumar - Writing the paper.
2. Arshad Hasan - Writing the paper.

3. Manoj Kumar - Study concept and design.
4. Veena Singh - Study concept and design.

Research studies

Not applicable.

References

- [1] R.A. Agha, A.J. Fowler, A. Saetta, I. Barai, S. Rajmohan, D.P. Orgill, for the SCARE Group, The SCARE statement: consensus-based surgical case report guidelines, *Int. J. Surg.* (2016) (article in press).
- [2] N. Sekar, K.K. Madhavan, R.V. Yadav, R.N. Katara, Primary retroperitoneal hydatid cyst: a case report and review of literature, *J. PostGraduate Med.* 28 (1982) 112–148.
- [3] C. Dziri, Hydatid disease: continuing serious public health problem: introduction, *World J. Surg.* 25 (2001) 1–3.
- [4] D.P. McManus, W. Zhang, J. Li, et al., Echinococcosis, *Lancet* 362 (2003) 1295–1304.
- [5] A. Gupta, A. Kakkar, M. Chadda, et al., A Primary intrapelvic Hydatid cyst presenting with foot drop and a gluteal swelling, *Br. J. Bone Joint Surg.* 80B (1998) 1037–1038.

Open Access

This article is published Open Access at scimedirect.com. It is distributed under the [IJSCR Supplemental terms and conditions](#), which permits unrestricted non commercial use, distribution, and reproduction in any medium, provided the original authors and source are credited.