

A Safe and Effective Technique of Paraesophageal Hernia Reduction Using Combined Laparoscopy and Nonsutured PEG Gastropepy in High-Risk Patients

Khalid Shehzad, MBBS, MSc, FRCS, Alan Askari, MB ChB, MSc DIC, PhD, MRCS, Alistair A. P. Slesser, MBBS, MD, FRCS, Amjid Riaz, BSc, MBBS, FRCS, FRCSI, PhD

ABSTRACT

Background: Paraesophageal hernias (PHs) can cause significant morbidity and even mortality in untreated patients. While formal surgical repair remains the ideal treatment option, patients who are elderly and/or frail and who have with multiple comorbidities may be unsuitable candidates for a surgical repair. We present a case series of 5 patients treated with a combined laparoscopic reduction of PH and 2-point percutaneous endoscopic gastropepy (PEG).

Methods: Data on the 5 patients were collated, and a review of the literature was performed to determine similar cases and outcomes.

Results: Five elderly patients (mean age 80 y, range 71–89 y) with significant existing comorbidities (average ASA 3) presented acutely with large PH at our institution. All had abdominal pain, nausea/vomiting, symptoms of gastric outlet obstruction, and an element of hypoxia. Computed tomography examination results confirmed the diagnosis. Because the patients were elderly and frail, a formal surgical repair of the PHs was not feasible. A combined laparoscopy/PEG gastropepy was undertaken to reduce the PH, and a 2-point PEG fixation was performed. Four of the 5 patients returned to normal oral intake before discharge. A fifth patient was successfully fed via the PEG. There were no complications, and all were discharged to their usual place of residence.

Conclusion: A combination of laparoscopic reduction

and nonsutured PEG gastropepy is a safe and effective alternative treatment for high-risk patients (with significant morbidity and mortality) with symptomatic PHs. Most patients (80%) returned to normal oral intake postprocedure and were discharged home within 3 d.

Key Words: Percutaneous endoscopic gastrostomy, High-risk patients, Paraesophageal hernia, Hiatal hernia, Elderly, Medical comorbidities.

INTRODUCTION

A combined laparoscopic and percutaneous endoscopic gastrostomy (PEG) insertion technique for high-risk patients with paraesophageal hernias (PH) was first described by Kercher and colleagues in 2001.¹ Although uncommon, accounting for only 5%–10% of all hiatal hernias, they tend to occur in elderly comorbid patients, who often have a significant multitude of preexisting medical comorbidities.^{2–4} A 4-category system classifies the different hiatal hernia types, with type I being the most common. Type I hernias (“sliding” hernias) occur when the gastroesophageal junction (GEJ) herniates through the diaphragm. Type II hiatal hernias are PHs and are referred to as “rolling” hernias. Typically, a portion of the fundus herniates through the diaphragm while the GEJ remains in its usual anatomical position. Type III hernias are a combination of types I and II, resulting in both the GEJ and a portion of the fundus herniating into the chest. Recently, the classification has been extended to incorporate a type IV hernia, referred as a “giant” hernia, whereby the entire stomach, sometimes with another organ (typically the colon), protrudes into the chest.⁵

Often, PHs are asymptomatic, particularly if small. However, they can be associated with symptoms of reflux, dyspepsia, dysphagia, and serious complications of bleeding, gastric volvulus, and gastric perforation in 30% to 40% of cases.^{1–3,6} Recently, the Society of American Gastrointestinal and Endoscopic Surgery guidelines recommended that types II–IV should be repaired to prevent the development of any of these life-threatening complications, whereas type I hernia repairs are determined on a patient-

West Hertfordshire Hospitals NHS Trust (Drs Shehzad, Askari, Slesser, and Riaz).

Disclosures: none.

Funding/Financial Support: none.

Conflicts of Interest: The authors have no conflicts of interest directly relevant to the content of this article.

Informed consent: Dr. Riaz declares that written informed consent was obtained from the patient/s for publication of this study/report and any accompanying images.

Address correspondence to: Amjid Riaz, BSc, MBBS, FRCS, FRCSI, PhD, West Hertfordshire Hospitals Trust, Vicarage Road, Watford, WD18 0HB, United Kingdom. Tel: 01923 244366 ext 7876, E-mail: amjid.riaz@nhs.net

DOI: 10.4293/JSLs.2019.00041

© 2019 by JSLs, *Journal of the Society of Laparoendoscopic Surgeons*. Published by the Society of Laparoendoscopic Surgeons, Inc.

by-patient basis, depending on the symptoms experienced and the size of the hernia.⁷

The current operative approach is the laparoscopic reduction of the hiatus hernia, defect repair (with or without mesh), and fundoplication. On average, the procedure takes 1.5–4 h³; however, in the elderly and those with a high ASA grade, it is associated with significant morbidity and mortality.^{1,2} To mitigate the risk of complications and possible mortality, PEG gastropexies have been introduced since the 1980s. The aim of the PEG gastropexy is to provide effective reduction of the hernia and 2- or 3-point fixation of the stomach to the abdominal wall in patients who would otherwise be poor surgical candidates.⁸ However, PEG insertion without intraperitoneal visualization of the stomach is not always safe because of conditions affecting transillumination or organs overlying the stomach.⁹ The combination of laparoscopy and PEG gastropexy allows both the reduction of the hernia and the safe placement of the PEGs to perform a gastropexy in high-risk patients.^{1,6}

We describe a case series of 5 patients in whom we used a modified Kercher technique in high-risk elderly patients with emergency PHs, and we present a review of the literature in terms of outcomes for combined laparoscopic/PEG gastropexy.

METHODS

Prospective data were collated on the 5 patients who underwent a combined laparoscopy/PEG fixation. The PubMed, Ovid, and Google Scholar databases were searched for relevant articles and reports describing gastropexy for PHs using either PEG fixation alone or the combined PEG/laparoscopic approach using the keywords “paraesophageal hernia,” “PEG,” and “gastropexy.”

Case Series: New Modified Surgical Technique

In all cases, careful preoperative resuscitation was performed. All 5 patients were assessed and had ASA scores calculated by a consultant anesthetist. All patients had the procedure performed under general anesthesia. At induction, the patients received intravenous antibiotics and were placed in a supine position with the legs apart. In the combined cases, laparoscopy was performed first using a 10-mm 0° laparoscope. An open Hasson technique was used, and a 12-mm Hasson port was inserted to establish a pneumoperitoneum of 13 mm Hg at the umbilicus. A 5-mm port was inserted under vision in the right upper quadrant (RUQ), and 1 port was placed in the left upper

quadrant (LUQ). A full exploratory laparoscopy was performed.

The stomach was reduced using an atraumatic grasper and held in position close to the anterior abdominal wall. On reduction of the hernia, an assistant applied traction to the stomach to prevent prolapse of the stomach back into the mediastinum. While under laparoscopic visualization, with the aid of the anesthetist a gastroscope was placed in the stomach. The first site of the PEG insertion was selected in the antrum along the greater curvature, ensuring laparoscopically that the site is free of adhesions or overlying organs. A PEG guidewire was then inserted using a sheathed needle through the anterior abdominal wall into the stomach under gastroscopic and laparoscopic visualization. The guidewire was then snared, endoscopically pulled out through the mouth, and attached to the PEG tube. The tube was then pulled through the stomach and anterior abdominal wall and fixed into place. The second PEG site was chosen 5–10 cm proximally to the first site along the greater curvature and checked for safety using the laparoscope. The second PEG was inserted using the aforementioned technique. The stomach was then deflated using the gastroscope, and the correct anatomical position of the stomach was confirmed with the laparoscope before closure of the port sites.

RESULTS

Between January 2013 and December 2018, 5 patients underwent nonelective PEG and gastropexy during an acute admission for their symptomatic PH. At our institution, all patients undergo a formal anesthetic review by an experienced (consultant/attending) anesthetic specialist to determine a patient’s medical fitness for a general anesthetic before any surgical procedure. All of the patients were deemed unfit for extensive anesthesia and therefore a more definitive surgical procedure such as a formal PH repair was not undertaken. The median age of the patients was 78 y (interquartile range [IQR] 73–87 y). Patients were followed for a median 3.5 y (IQR 2.7–4.1 y), and in all patients, the PEG tube was removed at 6 wk in the outpatient clinic except for 1 patient who had a permanent PEG because the patient required long-term enteral feeding.

Case 1

A 78-y-old woman was admitted with sudden-onset abdominal pain and associated shortness of breath. She reported a loss of appetite and had not moved her bowels or passed flatus for 4 days. Her past medical history

included a previous right total knee replacement, a known hiatus hernia, osteoporosis, idiopathic thrombocytopenic purpura, varicose veins, and spondylosis. On examination, the patient was tachycardic (120/min) and afebrile with blood pressure of 148/94 mm Hg, oxygen saturations of 89% on room air, respiratory rate of 32/min. On auscultation, there was bilateral basal reduced air entry, and her abdomen was distended with lower abdominal tenderness and reduced bowel sounds. Investigations revealed a raised white blood cell count of $14.2^3/\mu\text{L}$; the remaining blood counts, urea and electrolytes and liver function tests were normal. A plain erect chest radiograph demonstrated a raised right hemidiaphragm as well as a large hiatus hernia; supine plain abdominal radiography revealed dilated small bowel loops. A computed tomography (CT) pulmonary angiogram demonstrated a dilated thoracic esophagus, hiatus hernia, and a large paraesophageal herniation of the stomach. The patient was resuscitated and treated for type 1 respiratory failure. However, during a period of 1 week, it was noted that the patient was unable to tolerate oral fluids. After a review by the upper gastrointestinal surgeons, the patient was taken to the operating room. A combined laparoscopic reduction of the large PH and esophagogastroduodenoscopy (EGD) with PEG insertion was performed. The patient made an uneventful postoperative recovery and was discharged 3 days later, eating and drinking normally.

Case 2

An 89-year-old woman was admitted under the medical team after a fall. On admission, the patient began to have persistent emesis. Her past medical history included dementia, arthritis, bilateral total hip replacement, anemia, type 2 diabetes, hypertension, and hypothyroidism. On examination, the patient was hemodynamically stable, with oxygen saturations of 95% on room air, and afebrile. Abdominal examination revealed a tender smooth swelling in the LUQ and a “succussion splash” (succussion splash is another name for ‘gastric splash’, i.e. the audible presence of fluid and air in an obstructed organ). Blood tests were unremarkable, the erect chest radiograph revealed a large hiatus hernia, and a plain abdominal radiograph was normal. An abdomen/pelvis CT demonstrated a dilated and tortuous esophagus with a large sliding hiatus hernia in the left side of the chest. An EGD was performed, which demonstrated a large hiatus hernia as well as a partial gastric volvulus. Because of persistent vomiting, a decision was made to operate. A laparoscopy was performed, and the large hiatus hernia was reduced. EGD and PEG insertion under general anesthesia was

performed. The patient was started on a PEG feed and made an uneventful recovery. She was discharged back to a nursing home.

Case 3

A 76-year-old woman was admitted under the general surgeons with an acute onset of chest pain radiating to the abdomen with associated emesis and shortness of breath. Past medical history included a previous laparoscopic cholecystectomy, an open appendicectomy, asthma, hypothyroidism, hypercholesterolemia, hypertension, stroke, and atrial fibrillation. On examination, the patient was hemodynamically stable, with oxygen saturations of 96% on room air, and afebrile. The abdomen was soft, the LUQ and epigastrium were tender, and digital rectal examination was unremarkable. Routine blood tests were normal. A nasogastric tube was placed, and 400 mL of gastric contents was aspirated. An abdomen/pelvis CT was undertaken, and a large hiatus hernia with a gastric volvulus was demonstrated. An EGD was attempted but this was abandoned due to the gastric volvulus. The patient was taken to the operating room, and a combined laparoscopic reduction of the hiatus hernia and EGD with 2-point fixation using PEG tubes was performed. The patient made an uneventful recovery and was discharged, eating and drinking normally. At 3-month follow-up, the patient’s PEG tubes had fallen out. However, because the patient well and was maintaining a normal diet, no further management was undertaken.

Case 4

A 71-year-old woman presented to the emergency department with epigastric pain and vomiting. The patient

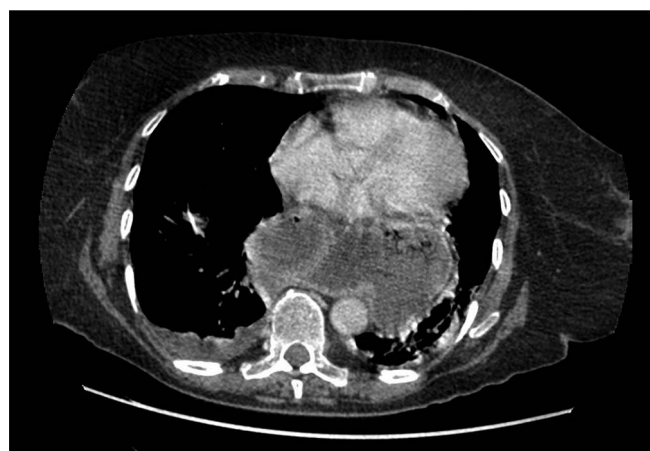


Figure 1. Sagittal CT view of a large para-esophageal hernia with most of the stomach in the Mediastinum.

reported a 2-week history of intermittent nausea and abdominal pain. She had multiple past medical comorbidities. On examination, the patient was tachycardic and hypoxic on room air, and there was tenderness in the epigastrium. On auscultation of the chest, there were reduced breath sounds on the right side. Investigations revealed a raised white blood cell count and C-reactive protein. An erect chest radiograph demonstrated a raised right hemidiaphragm as well as a large hiatus hernia. A CT demonstrated a large hiatus hernia with herniation of the

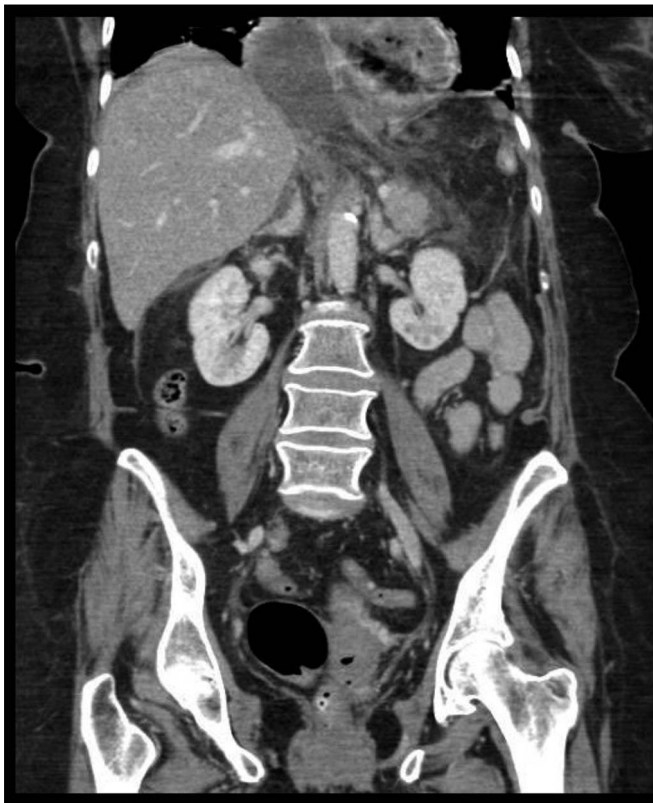

Figure 2. Coronal plane view of the large para-esophageal hernia.

distended gastric fundus. The appearances raise the possibility of complex volvulus. The patient was resuscitated and treated for type 1 respiratory failure and then taken to the operating room. A combined laparoscopic reduction of the large PH and EGD with 2-point PEG insertion was performed. The patient made an uneventful postoperative recovery and was discharged 3 days later, eating and drinking normally.

Case 5

An 85-y-old woman with a background diagnosis of metastatic breast cancer (bone and lung) presented with dysphagia, shortness of breath, abdominal pain, and progressive weight loss. The patient was only able to tolerate small volumes of liquid and no solids. Abdominal examination demonstrated tenderness in the epigastrium, a heart rate of 85, SaO_2 of 98%, blood pressure of 140/80 bpm, and a respiratory rate of 20/min. An EGD was performed, but the stomach could not be intubated because of a owing to a gastroesophageal junction stricture. A CT scan (**Figures 1** and **2**) demonstrated a large PH. The patient underwent laparoscopic reduction of the hernia and a 2-point fixation, similar to the previous cases described here. The patient made a good postoperative recovery and was able to eat and drink normally 4 days later.

DISCUSSION

Our case series of 5 patients describes a safe, effective, and quick technique to treat PH in high-risk elderly patients who are otherwise unsuitable candidates for a definitive surgical repair, with no associated morbidity or mortality. Our series demonstrates that even high-risk elderly patients with multiple morbidities are candidates for a suture-less technique for PH reduction and fixation. The procedure is successful in relieving symptoms and preventing recurrence and progression to

Table 1.
Characteristics and Outcome of the 5 Patients Who Underwent Gastropexy

Patient	Age, y	Gender	ASA	O ₂ Saturation, %	Length of Stay, d	PEG Removal
1	78	Female	4	89	3	Yes
2	89	Female	4	95	7	No
3	76	Female	4	96	4	Yes
4	71	Female	3	90	3	Yes
5	85	Female	4	98	4	Yes

complications and is extremely well tolerated. A review of the literature revealed a total of 8 publications describing the use of PEG or combined PEG/laparoscopy in the treatment of PHs, the largest of which was a case series involving 6 patients as described by Kercher and colleagues.¹

A similar technique to ours was described by Xenos in only a single patient with a good outcome.⁶ Although Kercher et al. and Tsujimoto et al. describe a similar approach, our technique differs in that we do not use sutures to anchor the stomach but instead rely on the double PEG tube insertion to provide fixation of the stomach, forming a permanent gastropexy.^{1,9} A large retrospective study of 354 patients who had undergone laparoscopic PH repairs demonstrated that patients older than 70 y or with an ASA of 3 or 4 were found to have significantly higher morbidity and mortality, respectively, than patients younger than 70 y.² The reasons for this are probably related to the high incidence of comorbidities in this age group and the physiological stress of the laparoscopic surgery in and around the chest. The patients presented in our case series had a mean age of 80 and ASA grade of 3.6. They all had numerous comorbidities and were unlikely to withstand formal hernia repairs and gastropexy. The average length of the operations was 1.5 h, and it is likely that this short time under general anesthesia contributed to their good recoveries. Suturing of the stomach to the anterior abdominal wall, although reasonable, will increase the operating time and is probably unnecessary in this high-risk group of patients. The technique used in this case series resulted in resolution of symptoms in all patients and the ability to return to a normal diet in 4 of 5 patients, the other patient being successfully fed through the PEG. Our case series revealed that the mean ASA is 3.6 and that the symptomatic PH had a significant effect on gaseous exchange with mean oxygen saturation of 90% (range 89%–96%). Furthermore, our data highlight that after our procedure, even these high-risk patients were symptom free very rapidly post-procedure and were discharged back to their usual residence in 3.4 d (**Table 1**).

Similar, successful rates of reduction have been reported in the literature using minimal tissue dissection and 2-point fixation using a PEG tube. Almost all of these patients have been able to continue oral feeds.^{10–15} Other authors have used a double-lumen “Funada” style device,⁹ which permits a successful gastropexy with a relatively low risk of PEG site infection.¹⁶

From our case series and the limited reports in the literature, a combined laparoscopic reduction and PEG fixation permits a safe reduction of the hiatal hernia and PEG gastropexy with minimal morbidity in patients who are otherwise, because of their existing comorbidities, unsuitable or high-risk candidates for a definitive surgical procedure. Given the high rate of morbidity and mortality associated with a complete surgical repair of large complex PH in high-risk elderly patients, the laparoscopic/PEG approach should be considered as an alternative.

References:

1. Kercher KW, Matthews BD, Ponsky JL, et al. Minimally invasive management of paraesophageal herniation in the high-risk surgical patient. *Am J Surg*. 2001;182:510–514.
2. Larusson HJ, Zingg U, Hahnloser D, Delpont K, Seifert B, Oertli D. Predictive factors for morbidity and mortality in patients undergoing laparoscopic paraesophageal hernia repair: age, ASA score and operation type influence morbidity. *World J Surg*. 2009;33:980–985.
3. Oddsdóttir M. Paraesophageal hernia. *Surg Clin North Am*. 2000;80:1243–1252.
4. Lebenthal A, Waterford SD, Fisichella PM. Treatment and controversies in paraesophageal hernia repair. *Front Surg*. 2015; 2:13.
5. Draaisma WA, Gooszen HG, Tournoij E, Broeders IAMJ. Controversies in paraesophageal hernia repair: A review of literature. *Surg Endosc*. 2005;19:1300–1308.
6. Xenos ES. Percutaneous endoscopic gastrostomy in a patient with a large hiatal hernia using laparoscopy. *JLS*. 2000;4:231–233.
7. Kohn GP, Price RR, DeMeester SR, et al. Guidelines for the management of hiatal hernia. *Surg Endosc*. 2013;27:4409–4428.
8. Gauderer MW, Ponsky JL, Izant RJ. Gastrostomy without laparotomy: A percutaneous endoscopic technique. *J Pediatr Surg*. 1980;15:872–875.
9. Tsujimoto H, Yaguchi Y, Kumano I, Matsumoto Y, Yoshida K, Hase K. Laparoscopy-assisted percutaneous gastrostomy tube placement along with laparoscopic gastropexy. *Dig Surg*. 2011; 28:163–166.
10. Ho CK-M, Cheung FK-Y, Yien RL-C, Li MK-W. Minimally-invasive approach to paraoesophageal hernia in high surgical-risk patients. *Surg Pract*. 2014;18:87–89.
11. Hamai Y, Hihara J, Tanabe K, et al. Laparoscopic repair and percutaneous endoscopic gastrostomy to treat giant esophageal hiatal hernia with gastric obstruction: A case report. *Hiroshima J Med Sci*. 2015;64:27–30.

12. Lee HY, Park JH, Kim SG. Chronic gastric volvulus with laparoscopic gastropexy after endoscopic reduction: A case report. *J Gastric Cancer*. 2015;15:147–150.
13. Jamil LH, Huang BL, Kunkel DC, Jayaraman V, Soffer EE. Successful gastric volvulus reduction and gastropexy using a dual endoscope technique. *Case Rep Med*. 2014;2014:136381.
14. Newman RM, Newman E, Kogan Z, Stien D, Falkenstien D, Gouge TH. A combined laparoscopic and endoscopic approach to acute primary gastric volvulus. *J Laparoendosc Adv Surg Techniques A*. 1997;7:177–181.
15. Petzinger C, Parmely J. Laparoscopic paraesophageal hernia reduction with two point fixation via Ponsky PEG tube in a patient in their early 90s. *Spartan Med Res J*. 2017;2:74–85.
16. Dormann AJ, Wejda B, Kahl S, Huchzermeyer H, Ebert MP, Malfertheiner P. Long-term results with a new introducer method with gastropexy for percutaneous endoscopic gastrostomy. *Am J Gastroenterol*. 2006;101:1229–1234.