

[CASE REPORT]

Plummer-Vinson Syndrome with Esophageal Web Formation in which Detailed Endoscopic Images Were Obtained

Takashi Hirose¹, Kohei Funasaka¹, Kazuhiro Furukawa¹, Takeshi Yamamura², Takuya Ishikawa¹, Eizaburo Ohno¹, Masanao Nakamura¹, Hiroki Kawashima¹, Ryoji Miyahara¹ and Yoshiki Hirooka²

Abstract:

Plummer-Vinson syndrome is a rare entity, characterized by dysphagia, esophageal web formation, and iron deficiency anemia. The patient was a 63-year-old woman with a clinical history of iron deficiency anemia and glossitis in her 20s to 40s and who had experienced swallowing difficulties for the past 20 years. A membranous stricture was found in the cervical esophagus during a fluoroscopic examination. An endoscopic examination conducted under general anesthesia revealed an oblique linear scar on the proximal surface of the stricture. Sequential balloon dilation was performed successfully. We suggest that the esophageal web formation might have been related to the healing of an esophageal ulcer.

Key words: Plummer-Vinson syndrome, esophageal web, balloon dilation

(Intern Med 58: 785-789, 2019)

(DOI: 10.2169/internalmedicine.1628-18)

Introduction

Plummer-Vinson syndrome (PVS), which is also known as Paterson-Brown Kelly syndrome, involves a triad of iron deficiency anemia, dysphagia, and esophageal web formation (1). PVS most commonly occurs in post-menopausal women (2, 3). In addition to the abovementioned triad, patients with PVS sometimes present with atrophic glossitis and koilonychia.

An esophageal web is a thin membranous structure, which obstructs the esophageal lumen. They often occur in the cervical esophagus and are considered to be a cause of dysphagia. While anemia can be ameliorated via iron repletion, patients with symptomatic esophageal webs need to undergo esophageal dilation; however, PVS is now quite rare in developed countries because of the availability of iron replacement therapy (4-6). The endoscopic findings of esophageal webs are reported to include smooth and thin mem-

branes. However, the pathogenic mechanism responsible for esophageal web formation remains largely unknown (7).

Case Report

A 63-year-old woman with a clinical history of iron deficiency anemia and glossitis in her second to fourth decades of life visited a clinic for a medical health check-up. A medical interview revealed that she had difficulty swallowing and had taken a long time to eat meals for the past 20 years. A screening examination was conducted using an ultrathin endoscope, but the scope could not pass through the cervical esophagus due to stenosis. Thus, the patient was referred to our hospital.

On physical examination, her body weight was found to be only 40 kg, and her body mass index (BMI) was 15.0 (kg/m²). No koilonychia, glossitis, or stomatitis was detected. Laboratory studies revealed a hemoglobin level of 12.8 g/dL, a hematocrit level of 38.4%, and a mean corpus-

¹Department of Gastroenterology and Hepatology, Nagoya University Graduate School of Medicine, Japan and ²Department of Endoscopy, Nagoya University Hospital, Japan

Received: June 4, 2018; Accepted: August 26, 2018; Advance Publication by J-STAGE: November 19, 2018

Correspondence to Dr. Kohei Funasaka, k-funa@med.nagoya-u.ac.jp

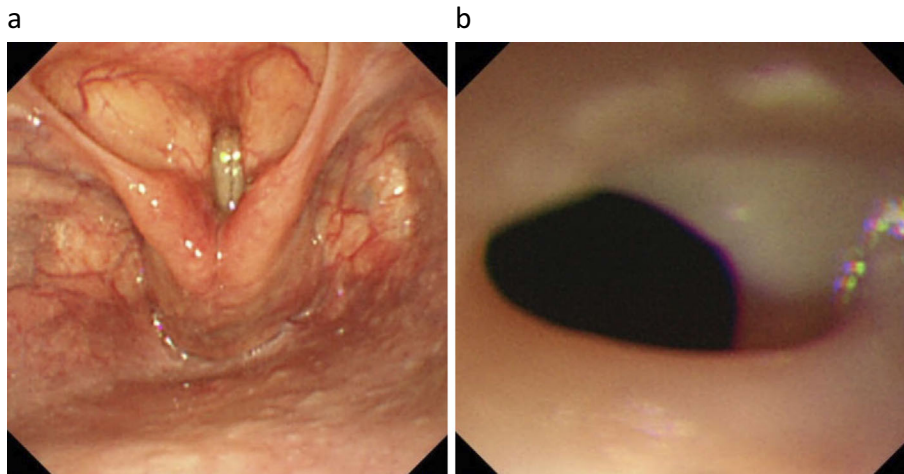


Figure 1. (a) No endoscopic abnormalities were found in the laryngopharynx during the Valsalva maneuver. (b) An endoscopic view of the entrance of the cervical esophagus. An ultrathin endoscope could not pass through the constricted region.

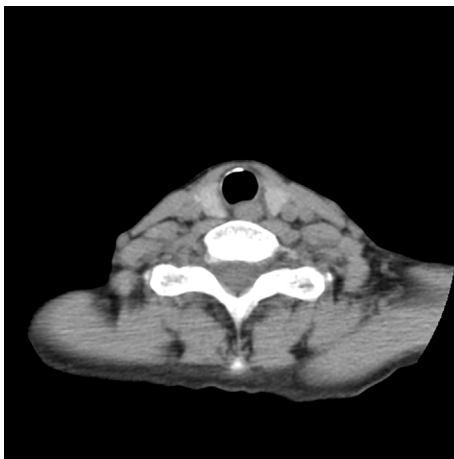


Figure 2. Contrast-enhanced computed tomography did not show any abnormalities around the cervical esophagus.

cular volume of 87.3 fl. The patient's serum iron level was 85 ug/dL, and her serum ferritin level was 19 ng/mL. No evidence of iron deficiency anemia was seen on admission.

During an esophagogastroduodenoscopy (EGD) examination, in which the Valsalva maneuver was performed, no lesions were found in the laryngopharynx (Fig. 1a). Although we subsequently tried to insert an ultrathin endoscope into the esophagus, it was not possible to pass the endoscope through the entrance of the esophagus due to resistance (Fig. 1b). The examination had to be stopped because oxygen desaturation occurred due to saliva aspiration during the examination. Contrast-enhanced computed tomography did not show any abnormalities around the cervical esophagus (Fig. 2). However, barium esophagography revealed a membranous protrusion in the cervical esophagus. Barium extrusion from the oral side to the anal side of the constriction (the so-called jet phenomenon), was confirmed (Fig. 3). In combination with the patient's clinical history of iron deficiency anemia and glossitis, the EGD and fluoroscopy find-

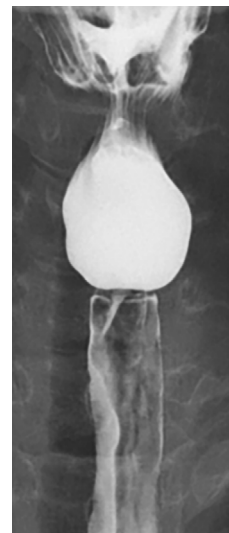


Figure 3. Barium esophagography. This examination revealed a membranous protrusion and the "jet phenomenon" (barium extrusion from the oral side to the anal side of the constricted region).

ings led to a final diagnosis of an esophageal web associated with PVS.

Even though the patient's anemia had already improved, the dysphagia remained. Thus, endoscopic esophageal balloon dilation was scheduled under general anesthesia to prevent oxygen desaturation.

Using a combination of a WEERDA distending diverticuloscope, which was operated by an otolaryngologist, and an endoscope, it was possible to observe the pyriform sinus and the cervical esophagus in detail (Fig. 4a). Severe stenosis was clearly visualized at the esophageal entrance, and an oblique linear scar extended to the proximal side of the stricture. The estimated diameter of the lumen was approximately 2 mm (Fig. 4b). No findings that were indicative of malignancy were seen on image-enhanced endoscopy

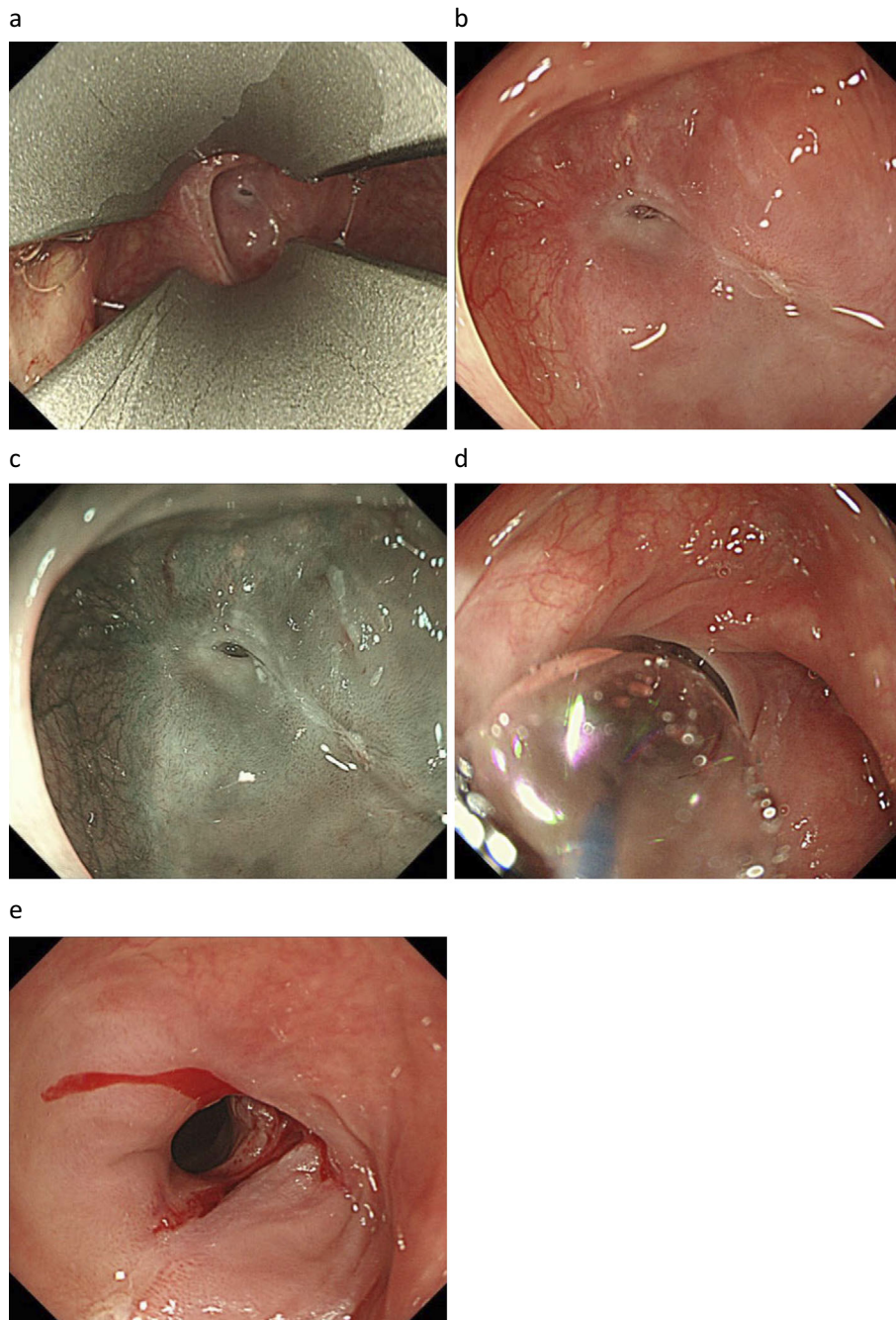


Figure 4. (a) The endoscopic view obtained with a WEERDA distending diverticuloscope. The pyriform sinus and cervical esophageal constriction were observed in detail. (b) Severe stenosis was clearly visualized just beyond the esophageal entrance, and an oblique linear scar was found on the posterior side of the stenotic lesion. (c) Image-enhanced endoscopy showed no findings that were indicative of malignancy. (d) The endoscopic view during balloon dilation. The dilation procedure (from 6 mm to 12 mm) was performed under radiography using a CRE balloon dilatation catheter. (e) The endoscopic view after balloon dilation. This treatment was completed without any complications.

(Fig. 4c). Ultrasonography using a 20-MHz miniature probe did not show any tumors around the esophageal stricture. After excluding other diseases, endoscopic balloon dilation (from 6 mm to 12 mm) was performed under radiography using a CRE[®] balloon dilatation catheter (Boston Scientific, Marlborough, USA) (Fig. 4d). We completed this treatment without any complications (Fig. 4e). After the treatment, the patient's dysphagia was relieved. Three years later, her body

weight had increased from 40 kg to 52 kg, and her BMI had increased from 15.0 to 19.6. Despite the clinical efficacy of this procedure, the esophageal web remained; however, it was possible to pass an ultrathin endoscope into the esophagus. No additional treatments have been performed and the patient has remained symptom-free.

Discussion

PVS typically consists of dysphagia, upper esophageal web formation, and iron deficiency anemia (1). The causes of dysphagia and esophageal web formation in PVS are still unknown. In general, the onset of dysphagia occurs gradually, and symptom progression is extremely slow. Symptoms tend to be ameliorated by diet modification (8). In the present case, the patient had suffered iron deficiency anemia for more than 20 years. However, she had not complained of dysphagia and had managed to eat soft foods by eating slowly. Some patients with dysphagia find that their symptoms can be improved via iron repletion alone, whereas others continue to suffer from dysphagia despite their iron deficiency anemia being ameliorated. In the current case, the esophageal web was detected incidentally during a medical health check-up, and the patient's anemia and glossitis had already improved by this point. In refractory cases, endoscopic balloon dilation is used to resolve strictures (4-6). Recent improvements in endoscopes and accessory devices have made balloon dilation safer and more effective. On the other hand, it is important to monitor the patient's respiratory condition during such procedures. We conducted balloon dilation under general anesthesia to prevent oxygen desaturation and aspiration pneumonia. Consequently, we were able to examine the esophageal web in detail with an endoscope, which revealed an oblique linear scar on the proximal mucosa.

Several hypotheses regarding the mechanism responsible for esophageal web formation in PVS have been proposed (8). Reduction in the activity of iron-dependent oxidative enzymes induce muscle degradation and atrophication of the mucosa. In addition, the cervical esophagus is subjected to high pressure during the swallowing of solid boluses. Under such conditions, the impaired atrophic mucosa can easily be damaged which might lead to esophageal web formation. However, no definitive conclusions have been reached about how esophageal webs develop. Based on the tissue changes induced by iron deficiency (9), and the oblique linear scar seen in the present case, we hypothesized that the esophageal webs in PVS form via the following mechanism. Iron deficiency anemia induces disorder in the kinetics of various cells and causes mucosal ulceration as it reduces the patient's capacity for mucosal repair. As the mucosal damage heals, the surrounding mucosa is pulled towards the scar, and a narrow deformity develops in the lumen. The therapeutic effectiveness of iron repletion in such cases is generally limited and it is unclear why iron repletion is effective in some cases, but not in others. If our hypothesis is correct, the efficacy of iron supplementation should be associated with the grade of iron deficiency-induced mucosal damage, such as the width or depth of such defects (i.e., mild mucosal damage would not affect the esophageal lumen, but severe mucosal damage would narrow the lumen), and hence, a dilation procedure would be

required. This indicates that the early administration of iron is important for relieving symptoms in patients with PVS who are not treated with endoscopic intervention.

Esophageal webs are usually diagnosed when barium esophagography and/or EGD is performed to evaluate dysphagia. The endoscopic findings of esophageal webs include a smooth, thin membrane that protrudes into the lumen, covered by a squamous epithelium. Esophageal webs most commonly arise on the anterior side of the cervical esophagus. The cervical esophagus is generally compressed by the surrounding tissue. Thus, detailed endoscopic examinations are quite difficult without additional devices. In the current case, we were able to examine the esophageal web in detail under general anesthesia. Moreover, a WEERDA distending diverticuloscope enabled us to observe the lesion within a stable field. To the best of our knowledge, no other studies have reported the endoscopic findings of esophageal webs in detail. Thus, our report is the first to describe an esophageal web in detail based on high-quality imaging.

Based on the endoscopic findings of the present case, we suggested a possible mechanism for esophageal web formation in PVS. However, the speculative nature of this hypothesis is a limitation of this report. To clarify this mechanism further, the mucosal ulceration in the cervical esophagus of PVS patients should be directly examined. However, the incidence of PVS exhibits in developed countries is low, as the widespread use of iron repletion has made the condition extremely rare. Thus, we have few chances to experience similar cases. In addition, it is difficult to perform endoscopic examinations in the cervical esophagus. To overcome this, a transparent endoscope tip attachment would offer a greater field of view. We recommend carefully observing the cervical esophagus with a transparent hood when performing endoscopy in PVS patients with dysphagia.

In general, esophageal webs do not recur once they have been disrupted, and they are rarely refractory to esophageal dilation. Our patient was successfully treated with a single session of balloon dilation and has been asymptomatic and recurrence-free for 5 years. PVS is reported to be a major risk factor for squamous cell carcinoma. It is said that approximately 3-15% of patients with PVS present with esophageal or pharyngeal carcinoma. Thus, annual EGD-based surveillance for esophageal squamous cell carcinoma has been suggested, and long-term follow-up is recommended in such cases (10, 11).

Conclusion

We found an esophageal web with an oblique linear scar on the proximal mucosa. This is the first report to provide detailed images of an esophageal web. Based on the findings of the present case, we propose that esophageal webs might form during the healing of iron deficiency-induced mucosal injuries in patients with PVS.

The authors state that they have no Conflict of Interest (COI).

Acknowledgement

The authors wish to thank the otolaryngologists Dr. Yasushi Fujimoto and Dr. Mariko Hiramatsu for their valuable help.

References

1. Novacek G. Plummer-Vinson syndrome. *Orphanet J Rare Dis* **1**: 36, 2006.
2. Hoffman RM, Jaffe PE. Plummer-Vinson syndrome. A case report and literature review. *Arch Intern Med* **155**: 2008-2011, 1995.
3. Okamura H, Tsutsumi S, Inaki S, Mori T. Esophageal web in Plummer Vinson syndrome. *Laryngoscope* **98**: 994-998, 1988.
4. Beyler AR, Yurdaydin C, Bahar K, et al. Dilation therapy of upper esophageal webs in two cases of Plummer-Vinson syndrome. *Endoscopy* **28**: 266-267, 1996.
5. Enomoto M, Kohmoto M, Arafa UA, et al. Plummer-Vinson syndrome successfully treated by endoscopic dilation. *J Gastroenterol Hepatol* **22**: 2348-2351, 2007.
6. Seo MH, Chun HJ, Jeon YT, et al. Esophageal web resolved by endoscopic incision in a patient with Plummer-Vinson syndrome. *Gastrointest Endosc* **74**: 1142-1143, 2011.
7. Gude D, Bansal D, Malu A. Revisiting Plummer Vinson syndrome. *Ann Med Health Sci Res* **3**: 119-121, 2013.
8. Goel A, Bakshi SS, Soni N, et al. Iron deficiency anemia and Plummer-Vinson syndrome: current insights. *J Blood Med* **8**: 175-184, 2017.
9. Jacobs A. Tissue changes in iron deficiency. *Br J Haematol* **16**: 1-4, 1969.
10. Dinler G, Tander B, Kalayci AG, et al. Plummer-Vinson syndrome in a 15-years-old boy. *Turk J Pediatr* **51**: 384-386, 2009.
11. Messmann H. Squamous cell cancer of the esophagus. *Best Pract Res Clin Gastroenterol* **15**: 249-265, 2001.

The Internal Medicine is an Open Access journal distributed under the Creative Commons Attribution-NonCommercial-NoDerivatives 4.0 International License. To view the details of this license, please visit (<https://creativecommons.org/licenses/by-nc-nd/4.0/>).