

## Surgical Management of Aorto-Esophageal Fistula as a Late Complication after Graft Replacement for Acute Aortic Dissection

Jae-Hong Lee, M.D., Bubse Na, M.D., Yoohwa Hwang, M.D., Yong Han Kim, M.D.,  
In Kyu Park, M.D., Kyung-Hwan Kim, M.D., Ph.D.

A 49-year-old male presented with chills and a fever. Five years previously, he underwent ascending aorta and aortic arch replacement using the elephant trunk technique for DeBakey type 1 aortic dissection. The preoperative evaluation found an esophago-paraprostatic fistula between the prosthetic graft and the esophagus. Multiple-stage surgery was performed with appropriate antibiotic and antifungal management. First, we performed esophageal exclusion and drainage of the perigraft abscess. Second, we removed the previous graft, debrided the abscess, and performed an in situ re-replacement of the ascending aorta, aortic arch, and proximal descending thoracic aorta, with separate replacement of the innominate artery, left common carotid artery, and extra-anatomical bypass of the left subclavian artery. Finally, staged esophageal reconstruction was performed via transthoracic anastomosis. The patient's postoperative course was unremarkable and the patient has done well without dietary problems or recurrent infections over one and a half years of follow-up.

Key words: 1. Fistula  
2. Aorta  
3. Surgery  
4. Esophagus

### CASE REPORT

A 49-year-old male was referred to Seoul National University Hospital due to a one-month history of fever and chills. Five years previously, he underwent graft replacement of the ascending aorta and total arch for DeBakey type 1 aortic dissection with a 24-mm Dacron graft using the elephant trunk technique. Chills and febrile sense were the only symptoms; dysphagia, chest pain, and hematemesis were not evident. Physical examination demonstrated an abscess on the left forearm and a pansystolic murmur at the right upper sternal border. *Peptostreptococcus anaerobius* was isolated from

blood culture studies, and blood tests revealed a leukocyte count of  $14.2 \times 10^3 / \mu\text{L}$  (normal range, 4.0 to  $10.0 \times 10^3 / \mu\text{L}$ ) and a C-reactive protein level of 21.23 mg/dL (normal range, 0 to 0.5 mg/dL). Thoracoabdominal computed tomography revealed a perigraft abscess with an esophago-paraprostatic fistula (EPPF; a communication between the space around the prosthetic graft and the esophagus), bilateral complicated pleural effusion, a paravertebral abscess at the T7 to L1 levels, and an abscess in the left buttock (Fig. 1). Transthoracic echocardiography showed no evidence of infective endocarditis.

With the diagnosis of EPPF, intravenous antibiotics were started promptly and a multi-stage operation was planned for

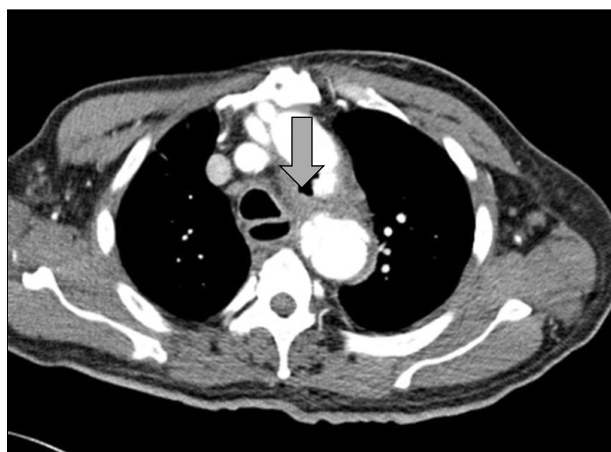Department of Thoracic and Cardiovascular Surgery, Seoul National University Hospital

Received: April 6, 2015, Revised: June 30, 2015, Accepted: July 3, 2015, Published online: February 5, 2016

Corresponding author: Kyung-Hwan Kim, Department of Thoracic and Cardiovascular Surgery, Seoul National University Hospital, Seoul National University College of Medicine, 101 Daehak-ro, Jongno-gu, Seoul 03080, Korea  
(Tel) 82-2-2072-3971 (Fax) 82-2-765-7117 (E-mail) [kkh726@snu.ac.kr](mailto:kkh726@snu.ac.kr)

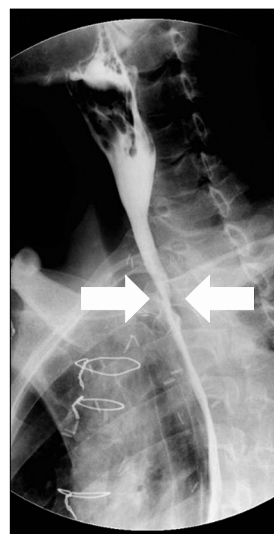
© The Korean Society for Thoracic and Cardiovascular Surgery. 2016. All right reserved.

© This is an open access article distributed under the terms of the Creative Commons Attribution Non-Commercial License (<http://creativecommons.org/licenses/by-nc/4.0>) which permits unrestricted non-commercial use, distribution, and reproduction in any medium, provided the original work is properly cited.



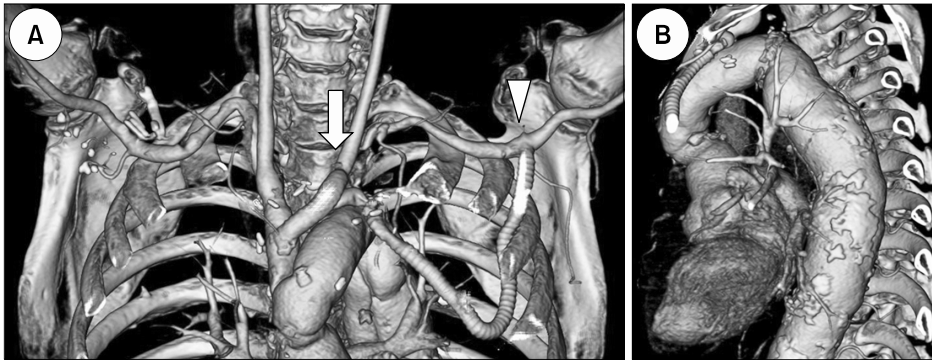
**Fig. 1.** Thoracoabdominal computed tomography revealed a perigraft abscess with an esophago-paraprostatic fistula (arrow).

definitive treatment. The first step was elimination of the focus of infection by excluding the esophagus and draining the perigraft abscess. The operation was performed in the supine and extended neck position after induction of general anesthesia with single-lumen intubation. Left oblique cervicotomy and upper median laparotomy were performed. After division of the distal cervical esophagus and esophago-gastric junction, esophageal mucosal stripping was performed. The esophageal-side wall of the perigraft abscess and the fibrotic esophageal wall were removed. Both vagal trunks were preserved during division of the esophago-gastric junction, and the short gastric arteries were also divided. Cervical esophagostomy was performed at the mid-portion of the cervical incision and two Jackson-Pratt drainage catheters were inserted around the abscess after irrigation. Feeding gastrostomy was performed at the anterior wall of the stomach body. After *Candida albicans* was isolated from cultures of abscess swabs obtained during the operation, an intravenous antifungal agent was added to the antibiotic regimen. After two weeks of antibiotic/antifungal treatment and appropriate nutritional support, the second stage of the operation was performed. The previous aortic graft was removed with debridement of the abscess around the aorta and esophagus. The ascending aorta, aortic arch, and proximal descending thoracic aorta were replaced using a 28-mm Dacron graft with a 10-mm side branch (Intergard Woven Hemabridge 28 mm; Maquet, San Jose, CA, USA). Next, separate replacement of the innominate artery and left



**Fig. 2.** Esophagography performed two weeks after esophageal reconstruction demonstrated no leakage or stricture at the anastomosis site (arrow).

common carotid artery was carried out with a custom 12×8 mm single Y-graft using the Spielvogel technique. Finally, the left subclavian artery was bypassed extra-anatomically using an 8-mm ringed Gore-Tex graft (W. L. Gore and Associates, Flagstaff, AZ, USA). The distal part of the graft was anastomosed to the left subclavian artery on the outside of the thoracic cavity and positioned to enter the thoracic cavity via the second intercostal space. The proximal part of the graft was anastomosed to the stump of the 10-mm Hemabridge graft in order to avoid manipulation of the infected area abutting the lesser curvature of the aortic arch that was revealed on computed tomography (Fig. 1). The patient was discharged after five weeks with a prescription for oral antibiotics. Antibiotic and antifungal treatments were recommended for eight weeks and four weeks, respectively. Four months after the second operation, once the patient's general condition had improved, esophageal reconstruction was performed. In the supine position, takedown of the cervical esophagostomy and dissection of the cervical esophagus were performed. A 25-mm anvil of circular stapler was secured at the stump of the cervical esophagus and inserted into the right posterior mediastinum after dissection of the thoracic inlet. Gastric conduit preparation and feeding jejunostomy were performed through a median laparotomy. The previous gastrostomy was



**Fig. 3.** A postoperative computed tomographic angiogram performed one year after aortic reconstruction revealed a stable state with no significant stenosis of the bypass graft. (A) Coronal view and (B) sagittal view. Separate replacement of the innominate artery and left common carotid artery (arrow). Extra-anatomical bypass of the left subclavian artery (arrow head).

repaired by single layer of interrupted sutures. After completion of the cervical and abdominal procedures, the patient was turned to the left lateral decubitus position and muscle-sparing thoracotomy was performed on the right fifth intercostal space. After adhesiolysis and dissection of posterior mediastinum along with resection of the remaining esophageal wall, the gastric conduit was brought into the thoracic cavity and end-to-end esophagogastrostomy was performed with a circular stapler.

The patient's postoperative course was uneventful, except for abdominal wound dehiscence requiring secondary closure. Esophagography demonstrated no leakage or stricture at the anastomosis site (Fig. 2). Postoperative computed tomography revealed a stable state of aortic dissection from the descending thoracic aorta to the abdominal aorta and no significant stenosis of the bypass graft (Fig. 3). The patient was discharged after six weeks, approximately six months after his first presentation. The patient has been well over one and half years of follow-up, without any hemodynamic or dietary problems.

## DISCUSSION

The case involved EPPF caused by the development of a pseudoaneurysm at the descending thoracic aorta after replacement of the ascending aorta and aortic arch with a 24-mm Dacron graft using the elephant trunk technique for DeBakey type 1 aortic dissection.

Aorto-esophageal fistula (AEF) is a relatively rare and usually life-threatening condition. The classic clinical triad of AEF comprises mid-thoracic chest pain, sentinel arterial hem-

orrhage, and fatal hemorrhage, which are referred to as aorto-esophageal syndrome [1,2]. The main causes of AEF are ruptured aortic aneurysm, foreign body ingestion, and advanced esophageal malignancy. Some cases of AEF occur as complications after the surgical prosthetic repair of an aneurysm or thoracic endovascular aortic repair (TEVAR) [1-4]. AEF is classified as primary (communication between the untreated diseased thoracic aorta and the adjacent esophagus) or secondary (communication between the repaired aorta and the esophagus) [2,3,5]. The incidence of secondary AEF after surgery is relatively low (4.8%). Secondary AEF between the interposed prosthetic aortic graft and the adjacent esophagus is defined as EPPF. Typically, patients with EPPF display sepsis and massive hematemesis, with an extremely poor prognosis if untreated [3,5,6].

After confirmation of the diagnosis of AEF, conservative medical treatment has a poor prognosis. The standard treatment of choice for AEF is graft replacement of the torn aorta and esophagectomy with subsequent reconstruction, which are usually completed in multiple-stage surgery to improve the outcomes and to allow adequate nutritional replenishment. Aggressive surgery involving esophageal resection, debridement, and aortic graft replacement or extra-anatomic bypass (EAB) grafting offers the best likelihood of a cure [1-7].

Orthotopic in situ aortic reconstruction should be performed, although EAB grafting may be an alternative to reconstruction with the prosthesis in situ. Several options are available for aortic replacement, including the implantation of a prosthetic graft with or without antibiotic treatment, cryopreserved aortic allografts, or a bovine pericardial roll [1-3,5-8]. Esophageal defects can be treated surgically in two

ways: primary repair of the esophagus or esophageal exclusion followed by delayed reconstruction. Primary repair of the esophagus can be considered in patients with a small esophageal defect, less esophageal wall necrosis, and no significant mediastinitis. Esophageal exclusion with delayed esophageal reconstruction is preferable in patients with large esophageal defects or extensive esophageal wall necrosis [1,2,4,7]. Infection control is critical in the treatment of AEF. Esophageal exclusion is more effective in controlling contamination because significant morbidity is associated with the breakdown of primary repair of the esophageal defect. Esophageal exclusion consists of subtotal esophagectomy, ligation of the distal esophagus, cervical esophagostomy, and concomitant gastrostomy or jejunostomy to allow enteral nutrition. Esophageal exclusion may increase surgical trauma, but eliminates the risk of dehiscence of the primary esophageal repair, intrathoracic sepsis, and re-infection of the new aortic graft. Radical debridement is essential. Omentopexy is another option for the surgical treatment of AEF, possibly preventing infective complications because of the high resistance to infection resulting from high vascularity and neovascularization potential [1-3,5,6]. Another important point is antibiotic therapy. Antibiotic treatment has been reported to be the only factor significantly associated with a lower mortality rate after aorta surgery [2,4]. Although no specific guidelines exist regarding the duration of antibiotic therapy, we considered the long-term maintenance of antibiotic therapy to be necessary.

Recently, TEVAR has emerged as a bridge therapy for hemodynamic stabilization, followed by delayed durable open surgical repair. After controlling the bleeding by TEVAR, the patient should receive intensive medical support and adequate nutritional support. Once the patient's clinical condition improves, open surgery should be performed as soon as possible. TEVAR should only be considered as a stop-gap measure to achieve short-term hemostasis until the start of definitive treatment by conventional surgery within a few hours or days [1,4,7,8].

In our case, we planned multiple-stage surgery because the clinical diagnosis was EPPF and the patient's physical status was poor. Esophagectomy, esophageal mucosal stripping, cervical esophagostomy, and feeding gastrostomy were per-

formed to remove the focus of the infection and to enable sufficient enteral nutritional support. Due to mediastinitis and infection at the artificial aortic graft, we considered a definitive infection control strategy to be the most important step in treating EPPF, preventing aortic erosion, and preventing recurrent infection after re-replacement of the aorta. Thus, esophageal exclusion was performed instead of primary repair of the esophagus or an esophageal stent. Esophageal mucosal stripping was performed because it was possible to close the proximal end of the remnant thoracic esophagus after exclusion. Esophageal mucosal stripping was easier and safer than transhiatal esophagectomy in this patient and had the benefit of preserving the vagus nerves. After medical management, including antibiotics and antifungal treatment, aortic reconstruction was performed. Aortic allografts are more resistant to infection, but were not used in this case due to the limited availability of allografts. As an alternative to reconstruction with aortic allografts, EAB grafting between the left subclavian artery and the prosthetic bridge graft was used to reduce the risk by routing the graft away from the infected areas.

In the final stage of the operation, esophageal reconstruction was successfully performed after the patient's medical condition had improved and stabilized. With regard to reconstruction of the esophagus, delayed reconstruction of the gastrointestinal continuity by means of an esophago-gastric anastomosis in the cervical area or pedicled colon interposition through the antesternal route may follow [1]. In this case, the posterior mediastinal route was used instead of the substernal route for esophageal reconstruction because the artificial aortic grafts were located in the substernal area, and also because severe adhesion was present. Transthoracic anastomosis was performed instead of cervical anastomosis because it was not feasible to bring the gastric conduit to the neck through a narrow fibrotic thoracic inlet for anastomosis. We placed an anvil during the cervical phase and anastomosed in the thoracic phase. Thus, the esophagogastric anastomosis site was located at the thoracic inlet.

We report a case of the successful surgical management of secondary AEF caused by graft infection after ascending aorta and aortic arch replacement. We hope that this approach may extend the therapeutic options for treating secondary AEF.

## CONFLICT OF INTEREST

No potential conflict of interest relevant to this article was reported.

## REFERENCES

1. Okita Y, Yamanaka K, Okada K, et al. *Strategies for the treatment of aorto-oesophageal fistula*. Eur J Cardiothorac Surg 2014;46:894-900.
2. Reardon MJ, Brewer RJ, LeMaire SA, Baldwin JC, Safi HJ. *Surgical management of primary aorto-esophageal fistula secondary to thoracic aneurysm*. Ann Thorac Surg 2000;69:967-70.
3. Saito A, Motomura N, Hattori O, et al. *Outcome of surgical repair of aorto-esophageal fistulas with cryopreserved aortic allografts*. Interact Cardiovasc Thorac Surg 2012;14:532-7.
4. Canaud L, Ozdemir BA, Bee WW, Bahia S, Holt P, Thompson M. *Thoracic endovascular aortic repair in management of aorto-esophageal fistulas*. J Vasc Surg 2014;59:248-54.
5. Kobayashi K, Ohata T, Ueda H, Shichinohe T. *Management of secondary aorto-esophageal fistula without graft extraction*. J Thorac Cardiovasc Surg 2013;145:e5-6.
6. Kawamoto S, Saiki Y, Oda K, et al. *Successful management of esophagoparaprostatic fistula after aortic surgery*. Ann Thorac Surg 2008;85:1449-51.
7. Munakata H, Yamanaka K, Okada K, Okita Y. *Successful surgical treatment of aorto-esophageal fistula after emergency thoracic endovascular aortic repair: aggressive debridement including esophageal resection and extended aortic replacement*. J Thorac Cardiovasc Surg 2013;146:235-7.
8. De Masi M, Amabile P, Bal L, Piquet P. *Management of endograft infection coupled with aorto-esophageal fistula: extra-anatomic aortic bypass and endograft explantation*. J Thorac Cardiovasc Surg 2013;146:e11-3.