

Available online at [www.sciencedirect.com](http://www.sciencedirect.com)

ScienceDirect

journal homepage: [www.elsevier.com/locate/radcr](http://www.elsevier.com/locate/radcr)

## Case Report

# Missed lateral end clavicle fracture in adolescent patients: The value of undertaking additional clavicle radiographic views <sup>☆</sup>

Lena Al-Hilfi, MBChB, MSc\*, Lily Mclean, MBBS, Sarkhell Radha, MBA, MRCS Ed, FRCS (Tr. & Orth)

Croydon University Hospital, UK

## ARTICLE INFO

## Article history:

Received 29 September 2022

Revised 11 October 2022

Accepted 13 October 2022

## Keywords:

Clavicle

Oblique views

Fracture

## ABSTRACT

Clavicle fractures are extremely common, accounting for 5%-10% of all pediatric fractures. Due to the increased radiation dose, additional radiographic views are less frequently performed, particularly in skeletally immature patients. In Trauma and Orthopedic practice, it is well known that 2 radiographic views are essential for any fracture assessment, with additional views such as oblique views for selected cases. Oblique views are recommended, especially for extremity trauma as this has shown to reduce the incidence of missed diagnoses. Although 2 views of the clavicle, A-P and 45° cephalic tilt are recommended, it is the usual practice in most radiology departments to undertake A-P view of clavicle only. We report a case of a lateral end displaced clavicle fracture in a 16-year-old sustained following football injury. This was completely missed at the initial encounter and the patient later presented with pain and difficulty to move his right shoulder. We believe if this patient had a 45° cephalic tilt view at the time of presentation, the fracture would have been identified and appropriate treatment would have been instituted. Awareness of obtaining a minimum of 2 radiographic views for lateral clavicle fractures will reduce the incidence of missed clavicle fractures.

Crown Copyright © 2022 Published by Elsevier Inc. on behalf of University of Washington.

This is an open access article under the CC BY-NC-ND license

(<http://creativecommons.org/licenses/by-nc-nd/4.0/>)

## Case report

A 16-year-old boy admitted to our institution with history of right shoulder pain and limitation of movement following a fall while playing football. He was seen in the Emergency Department and clinical examination showed tenderness around lateral half of clavicle. An A-P radiograph was

taken (Fig. 1) and subsequently reassured and discharged. One month later the patient re-presented due to continued pain around lateral clavicle with small palpable lump. During this visit, further radiograph of clavicle obtained (Fig. 2), which showed a displaced physal injury to lateral end of clavicle. Subsequently, a magnetic resonance imaging scan was performed to assess the extent of the injury (Fig. 3). Given that this case was missed and presented late, a multidisciplinary

<sup>☆</sup> Competing Interests: This study received no specific grant from any funding agency.

\* Corresponding author.

E-mail address: [lena.al-hilfi@nhs.net](mailto:lena.al-hilfi@nhs.net) (L. Al-Hilfi).

<https://doi.org/10.1016/j.radcr.2022.10.041>

1930-0433/Crown Copyright © 2022 Published by Elsevier Inc. on behalf of University of Washington. This is an open access article under the CC BY-NC-ND license (<http://creativecommons.org/licenses/by-nc-nd/4.0/>)

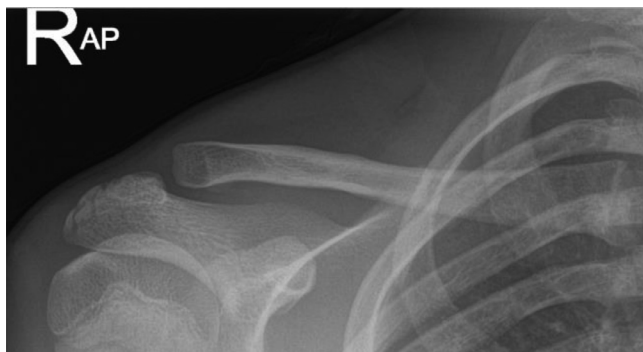

Fig. 1 – AP view.

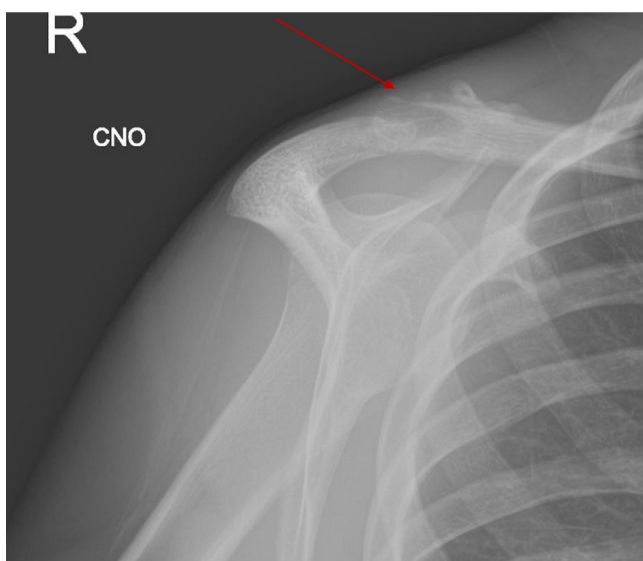


Fig. 2 – Radiograph 4 weeks post-injury.

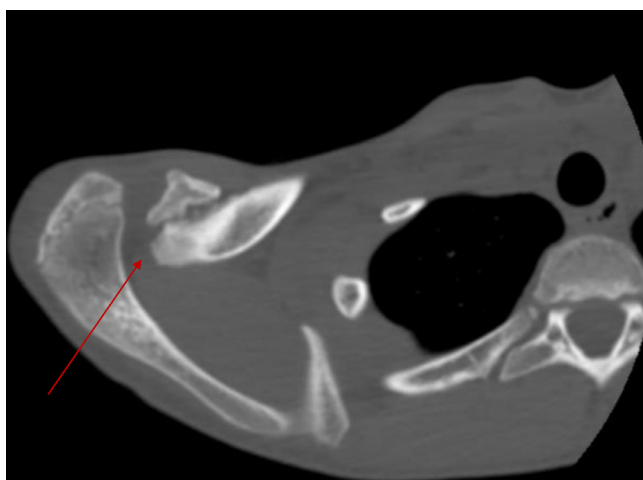


Fig. 3 – MRI scan of the clavicle.

team meeting decision was made to accept the deformity and treat non-operatively.

## Discussion

Although Widner [1] recommends 2 clavicle views, A-P and 45° cephalic tilt, additional radiographic views are less commonly performed, especially in skeletally immature patients, due to increased radiation dose [2]. Lateral end of clavicle injuries account for about 10% of pediatric clavicle fractures [3]. This injury, which is usually Salter–Harris type 2, can be difficult to detect and are commonly misinterpreted as dislocations of the acromioclavicular joint [4]. Clavicle fractures are often considered to be benign, especially in pediatric and adolescent age groups. Nevertheless, the diagnosis of a clavicle fracture is important as it may have implications on return to activities such as sport in this age group. Furthermore, non-union and mal-union can occur secondary to inadequate initial immobilization [5,6]. Although 2 views of the clavicle - A-P and 45° cephalic tilt, are recommended by Winder, it is standard practice in most emergency departments to undertake a single A-P view [7]. In our case, it is possible that this fracture would not have been missed had a 45° cephalic tilt view been obtained. We recommend that where there is clinical suspicion of a fracture of the clavicle in pediatric patients, further views should be obtained. Irrespective of whether or not the radiographs show a clavicular fracture, patients should be treated as though one is present, and be asked to re-attend within 1 week for further assessment, either with or without repeat radiographs on arrival.

## Patient consent

I, Dr Lena Al-Hilfi, confirm that a written informed consent was obtained from the patient and parents for publication of this case report and any accompanying images. A copy of the written consent is available for review by the editors of this journal.

## Acknowledgments

Not applicable.

## REFERENCES

- [1] Widner LA, Riddewood HO. The value of the lordotic view in diagnosis of fractured clavicle. *Int Radiol* 1980;5:69–70.
- [2] Rockwood CA, Wilkin KE, Beaty JH. *Rockwood fractures in children*, 3. Philadelphia: JB Lippincott; 1984.
- [3] Green NE, Swiontkowski MF, editors. *Skeletal trauma in children*. Third ed.. Philadelphia: Elsevier; 2003.
- [4] Ogden J. Distal clavicular physeal injury. *Clin Orthop Relat Res* 1984;188:68–73.

- [5] Falstie-Jensen S, Mikkelsen P. Pseudodislocation of the acromioclavicular joint. *J Bone Joint Surg [Br]* 1982;64-B:368-9.
- [6] Dameron TB, Rockwood CA. Fractures and dislocations of the shoulder. In: Rock-wood CA, Wilkins KE, King RE, editors. *Fractures in children*. Philadelphia: JB Lippincott; 1984. p. 624-53.
- [7] Simpson NS, Jupiter JP. Clavicle non-union and malunion: evaluation and surgical management. *J Am Acad Orthop Surg* 1993;4:1-8.