



Molecular typing of lung adenocarcinoma with computed tomography and CT image-based radiomics: a narrative review of research progress and prospects

Jing-Wen Ma[^], Meng Li

Department of Diagnostic Radiology, National Cancer Center/National Clinical Research Center for Cancer/Cancer Hospital, Chinese Academy of Medical Sciences and Peking Union Medical College, Beijing, China

Contributions: (I) Conception and design: M Li; (II) Administrative support: M Li; (III) Provision of study materials or patients: None; (IV) Collection and assembly of data: None; (V) Data analysis and interpretation: None; (VI) Manuscript writing: Both authors; (VII) Final approval of manuscript: Both authors.

Correspondence to: Meng Li, MD. Department of Diagnostic Radiology, National Cancer Center/National Clinical Research Center for Cancer/Cancer Hospital, Chinese Academy of Medical Sciences and Peking Union Medical College, Beijing 100021, China. Email: lmcams@163.com.

Objective: The purpose of this paper was to perform a narrative review of current research evidence on conventional computed tomography (CT) imaging features and CT image-based radiomic features for predicting gene mutations in lung adenocarcinoma and discuss how to translate the research findings to guide future practice.

Background: Lung cancer, especially lung adenocarcinoma, is the leading cause of cancer-related deaths. With advances in the diagnosis and treatment of lung adenocarcinoma with the emergence of molecular testing, the prediction of oncogenes and even drug resistance gene mutations have become key to individualized and precise clinical treatment in order to prolong survival and improve quality of life. The progress of imageological examination includes the development of CT and radiomics are promising quantitative methods for predicting different gene mutations in lung adenocarcinoma, especially common mutations, such as epidermal growth factor receptor (EGFR) mutation, anaplastic lymphoma kinase (ALK) mutation and Kirsten rat sarcoma viral oncogene (KRAS) mutation.

Methods: The PubMed electronic database was searched along with a set of terms specific to lung adenocarcinoma, radiomics (including texture analysis), CT, computed tomography, EGFR, ALK, KRAS, rearranging transfection (RET) rearrangement and c-ros oncogene 1 (ROS-1), v-raf murine sarcoma viral oncogene homolog B1 (BRAF), and human epidermal growth factor receptor 2 (HER2) mutations *et al.* This review has been reported in compliance with the Narrative Review checklist guidelines. From each full-text article, information was extracted regarding a set of terms above.

Conclusions: Research on the application of conventional CT features and CT image-based radiomic features for predicting the gene mutation status of lung adenocarcinoma is still in a preliminary stage. Noninvasively determination of mutation status in lung adenocarcinoma before targeted therapy with conventional CT features and CT image-based radiomic features remains both hopes and challenges. Before radiomics could be applied in clinical practice, more work needs to be done.

Keywords: Lung adenocarcinoma; epidermal growth factor receptor (EGFR); Kirsten rat sarcoma viral oncogene (KRAS); anaplastic lymphoma kinase (ALK); conventional CT features; CT image-based radiomics

Submitted Jun 16, 2021. Accepted for publication Sep 03, 2021.

doi: 10.21037/tcr-21-1037

View this article at: <https://dx.doi.org/10.21037/tcr-21-1037>

[^] ORCID: 0000-0002-0966-9179.

Introduction

Lung cancer remains the leading cause of cancer-related mortality worldwide (1,2). Many studies have shown that the incidence rate of lung cancer in non-smoking women and the detection rate of lung cancer, especially lung adenocarcinoma, after the implementation of lung cancer screening program are both increasing year by year, and lung adenocarcinoma has become the most common subtype of lung cancer and has the highest gene mutation rate (3-8). In recent decades, the discovery of cancer driver genes and their functions in predicting targeted therapy effects have led to great success in developing methods for the diagnosis and treatment of advanced lung adenocarcinoma. Alterations in driver genes are closely related to the prognosis of patients (9-18), and the accurate identification of oncogenic gene mutations is essential for patients with lung adenocarcinoma. Therefore, research on the molecular mechanism of lung adenocarcinoma at the micro level is further increased. The driver genes of lung adenocarcinoma mainly include epidermal growth factor receptor (EGFR), anaplastic lymphoma kinase (ALK), and Kirsten rat sarcoma viral oncogene (KRAS). Rare gene alterations include rearranging transfection (RET) rearrangement and c-ros oncogene 1 (ROS-1), v-raf murine sarcoma viral oncogene homolog B1 (BRAF), and human epidermal growth factor receptor 2 (HER2) mutations. To detect these mutations, pathological biopsy is still the “gold standard”. Of note, biopsy cannot assess all cancer lesions; repetitive biopsies increase the risk of local metastasis of tumours (19,20), the economic burden of patients and the tolerance of patients. In view of these limitations, there is an urgent need for a noninvasive, repeatable, and cost-effective technique for detecting driver gene mutations in lung adenocarcinoma.

Imaging examination, especially CT, is the most important noninvasive examination of lung cancer. There are many imaging features used to describe the conventional CT findings of lung adenocarcinoma. Ground glass opacity (GGO) is used to depict lung lesions that appear as hazy regions of increased opacity in the lung with preservation of bronchial and vascular margins, which is an important feature of lung adenocarcinoma (21,22). There are still some other features, such as bubble-like lucency (23,24), pleural retraction (25), and air bronchogram (22), which are also the common imaging descriptions for lung adenocarcinoma. However, conventional imaging features are subjective and lack quantitative objective basis, and some features overlap

and lack specificity.

Radiomics, as a new detection technique used to predict gene mutations, combines conventional imaging technology with an advanced computer algorithm and changes the conventional reading method that extracts imaging information in a subjective and semiquantitative way, directly translating visual image information into quantitative characteristics (26). Radiomics has revealed that the macroscopic imaging characteristics of tumours are closely related to microscopic genetic changes (27,28), which provides opportunities for molecular gene prediction in lung adenocarcinoma. The process of radiomics for molecular typing of lung adenocarcinomas includes six steps: (I) acquiring the images, (II) identifying the volumes of interest, (III) segmenting the volumes (i.e., delineating the borders of the volume with computer-assisted contouring), (IV) extracting and qualifying descriptive features from the volume, (V) using these to populate a searchable database, and (VI) mining these data to develop classifier models to predict outcomes either alone or in combination with additional information, such as clinical and conventional CT features (*Figure 1*). Radiomic features are divided into two categories: semantic features and agnostic features (29). Semantic features are those commonly used by radiologists to describe lesions, such as size, shape, location, and necrosis, while agnostic features are those that attempt to capture lesion heterogeneity through quantitative descriptors, such as histogram (skewness, kurtosis), Haralick textures, laws textures, wavelets, Laplacian transforms, Minkowski functionals, and fractal dimensions (29) (*Table 1*).

In recent years, there are many studies on predicting gene mutation phenotype of lung adenocarcinoma with conventional CT imaging features and CT image-based radiomic features. Therefore, in this article, we review the current research evidence on conventional CT imaging features and CT image-based radiomic features for predicting gene mutations in lung adenocarcinoma and discuss how to translate the research evidence to guide future practice. We present the following article in accordance with the Narrative Review reporting checklist (available at <https://dx.doi.org/10.21037/tcr-21-1037>).

Conventional CT imaging features and CT image-based radiomic features predict EGFR, its subtypes, and drug resistance gene mutations in lung adenocarcinoma

As the most common and most concerning oncogenic gene

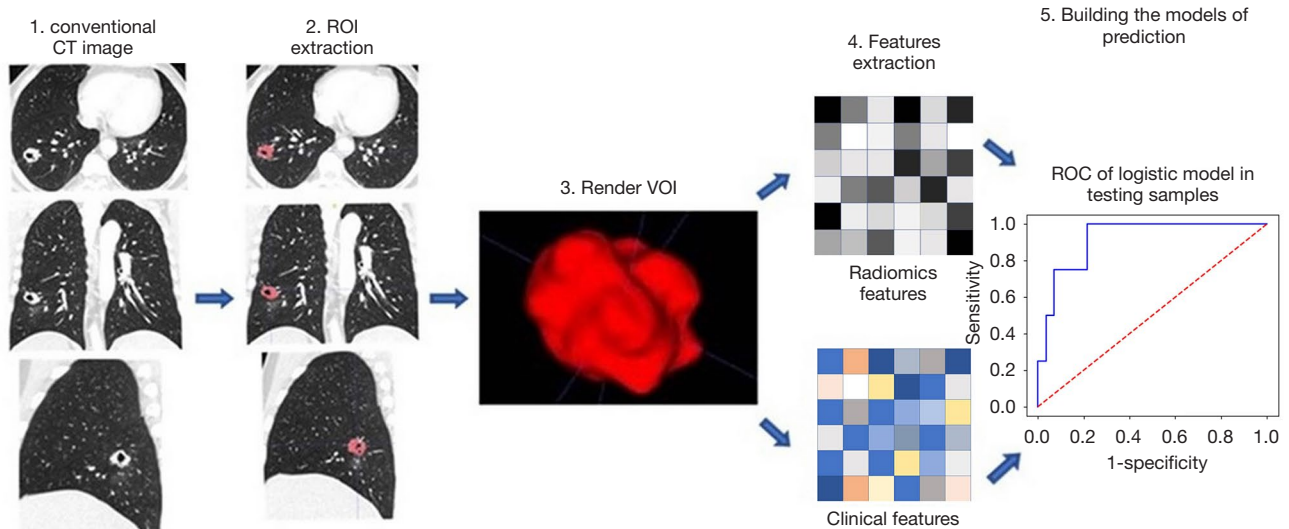


Figure 1 The flowchart shows the prediction process of radiomics. The first step is to obtain high-quality conventional CT images. The second step is to outline the lesion area from the high-quality images. The third step is to segment the region of interest (ROI) which is eventually rendered in three dimensions (3D) with specific software. The fourth step is to extract the quantitative features from these rendered volumes. The fifth step is to place the radiomic features in a database along with other data, such as clinical data. These data will be integrated, statistically analyzed, and finally mined into the optimal prediction model.

Table 1 Examples of Semantic and Agnostic Features of Radiomics (29)

Semantic	Agnostic
Size	Histogram (skewness, kurtosis)
Shape	Haralick textures
Location	Laws textures
Vascularity	Wavelets
Spiculation	Laplacian transforms
Necrosis	Minkowski functionals
Attachments or lepidics	Fractal dimensions

mutation, EGFR mutation has the highest mutation rate in lung adenocarcinoma and is common in Asian patients, female patients, and nonsmokers (25,30-32). Globally, EGFR is considered the most effective predictive biomarker for treatment outcomes with first-line epidermal growth factor receptor tyrosine kinase inhibitors (EGFR-TKIs). The prognosis of lung adenocarcinoma patients with EGFR mutations is better than that of those without EGFR mutations (10,33). The common EGFR mutation subtypes often occur within the EGFR exons 18 to 21, among which deletion in exon 19 and substitution of leucine for

arginine (L858R) in exon 21 account for approximately 90% of EGFR oncogenic mutation subtypes (34), both of which are sensitive to EGFR-TKI treatment (35-38). In the treatment, exon 19 deletion was associated with better outcomes than exon 21 L858R substitution (35,36).

In lung adenocarcinoma, conventional CT imaging features ground-glass opacity (GGO), and a small tumour size indicate better survival (39-45). Most have shown that GGOs and smaller tumour volumes are the most prominent imaging features of lung adenocarcinoma with EGFR mutations than wild-type EGFR mutations (25,46-55). In lung adenocarcinoma with different EGFR mutation subtypes, lesions with exon 19 deletion and exon 21 L858R substitution are related to a higher GGO proportion than other mutation subtypes, and the viewpoints that which of the two has higher GGO proportion are inconsistent in different studies (47,50,56-59). In our index, the Area under curve (AUC) values of conventional CT images for predicting EGFR mutation status were mostly lower than 0.8 (46,51,59). Moreover, studies have showed that conventional CT imaging features of lung adenocarcinoma combined with clinical variables could better classify EGFR mutation status than clinical variables alone (25,53,59). In Liu *et al.*'s study, the use of clinical variables combined with conventional

CT imaging features (AUC =0.778) was superior to the use of clinical variables alone (AUC =0.690) (25). In Han *et al.*'s study, AUC values of 0.647 and 0.712 for clinical-only or combined CT imaging features, respectively, for the prediction of EGFR mutations, led to a similar conclusion and revealed a significant difference between them ($P=0.0344$) (53). However, there are still some studies showing no significant correlation between GGO status and EGFR mutations (60,61). The reason the above results are different may be that the reading of conventional CT imaging features is easily affected by subjective factors, different methods of analysing GGO, a small sample size, and different grouping methods among studies.

CT image-based radiomic features can sensitively distinguish between EGFR-positive and EGFR-negative mutations in lung adenocarcinomas (62-71). Moreover, CT image-based radiomics has the capacity to distinguish EGFR subtype mutation exon 19 deletion and exon 21 L858R substitution (64,68). In some studies, the predictive performance of CT image-based radiomics in the identification of EGFR mutations in lung adenocarcinoma was better than that for EGFR subtype mutations (64,72), which may be due to the inclusion of clinical variables in the EGFR mutation groups. In another study, after deep learning of CT image-based radiomic features, the prediction model recognized EGFR mutation status with AUCs of 0.910 and 0.841 for the internal and external test cohorts, respectively (73), with outstanding performance. In addition, most studies show that the combination of CT image-based radiomic features and clinical variables has a better prediction effect than either approach alone (62,64-70,74,75), and moreover, CT image-based radiomic features combined with clinical and conventional CT features or pathological types can better identify EGFR mutations (63,67-70,76). In most studies, clinical features generally include mean age, sex and smoking history. Lu *et al.* (67) combined CT image-based radiomic features with clinicopathological features to predict EGFR, with an AUC of 0.894 for the test cohort, which had the best distinguishing ability compared with the combined clinicopathological and conventional CT imaging features (AUC for the test dataset =0.768) and CT image-based radiomic features (AUC for the test dataset =0.837) alone. To date, their study had the best prediction result to predict EGFR mutation status in lung adenocarcinoma with a radiomic model (AUC =0.90±0.02 for the training, 0.88±0.11 for the verification, 0.894 for the test dataset). Moreover, we note that in the prediction of EGFR

mutation status and its subtypes in patients with lung adenocarcinoma, CT image-based radiomic features are better than conventional CT imaging features alone and the combined clinical and conventional CT imaging features (66-68,70). In Digumarthy *et al.*'s study (70), the AUC values for radiomic features and conventional CT imaging features for predicting EGFR mutations were 0.725 and 0.553, respectively. In Zhang *et al.*'s study (76), the AUC values for radiomic features and the combined clinical and conventional CT imaging features for predicting EGFR mutation were 0.81 and 0.796, respectively.

Of note, drug resistance can occur along with treatment, leading to treatment failure. Substitution of threonine 790 with methionine (T790M) is a main drug resistance mutation in non-small cell lung cancer. The T790M mutation accounts for approximately half of all resistance to EGFR inhibitors such as gefitinib and erlotinib (77,78). A limited number of studies suggest that CT image-based radiomics can be used to predict EGFR T790M mutation (79,80). Cucchiara *et al.* measured the copy number of EGFR mutations in body fluid and analysed the correlation between EGFR mutations and CT image-based radiomic features. The results showed that CT image-based radiomic signatures could detect the appearance of the T790M mutation with an AUC of 0.84 (79). In a recent study (80), one hundred and nine patients fit the inclusion criteria (including three aspects: histological diagnosis, suitability for segmentation of CT images before treatment, and clinical and radiological follow-up of EGFR-mutant patients), among whom, 21 patients were positive for EGFR mutations. Among the EGFR-mutant patients, 19 patients were evaluated for the T790M mutation. In this study, compared with those patients who did not develop the T790M mutation, patients who developed the T790M resistance mutation during TKI treatment showed statistically significant differences in 17 CT image-based radiomic features.

The prediction of EGFR mutation and its mutation subtypes in lung adenocarcinoma by conventional CT imaging features and CT image-based radiomics is a hot topic. The conventional CT imaging features are low-dimensional, and the prediction effect is limited. Radiomics provides a new quantitative analysis method for the prediction of EGFR gene mutations in lung adenocarcinoma, showing positive predictive value and the potential to become an alternative biomarker for identifying EGFR mutation, its subtypes and drug resistance gene mutations. However, it is worth noting that

not all prediction signature models of CT image-based radiomics show particularly good performance. In some studies, the prediction performance of EGFR mutation status is not ideal with CT image-based radiomics alone (66,69,74) and the AUC values of some articles are lower than 0.8 (64,69,72,75), which may be related to the fact that the images were not preprocessed before data extraction. It is consistent that the predictive efficiency for EGFR mutation of the radiomic features combined with the clinical features has been improved in lung adenocarcinoma. Some studies have compared the predictive performance of radiomic features for EGFR mutation genes with that of conventional CT imaging features. According to these studies, the predictive performance of radiomic predictive models is better than that of conventional CT imaging features (67,70,76). Even if clinical features are integrated into conventional CT features, their predictive performance is still inferior to that of the radiomic prediction model (67,76).

Conventional CT imaging features and CT image-based radiomic features predict ALK rearrangement genes in lung adenocarcinoma

ALK rearrangement is another important molecular mutation (81), and it is also an important target for therapy (82,83). Compared with chemotherapy, TKIs improved the prognosis of ALK-positive NSCLC patients (84,85). Studies have shown that ALK rearrangement is common in young patients with lung adenocarcinoma, and lesions with ALK rearrangement are shown as solid nodules on CT images (51-53,60,86-89). The use of clinical variables combined with CT imaging features was superior to the use of clinical variables alone (51,53,59) in predicting the ALK mutation status in lung adenocarcinoma. Conventional CT imaging features can identify ALK-positive lung adenocarcinoma with reasonably strong accuracy (88). Moreover, studies revealed that lesions with ALK rearrangement were prone to lymph node, pleural, and pericardial metastasis (51,52,87).

Some studies also indicate that CT image-based radiomic features have good performance in predicting ALK mutation (74,90). The research results showed that CT image-based radiomic features combined with clinical features can better identify ALK mutations in lung adenocarcinoma (74,91,92). Moreover, the standard post-contrast CT classifier had better performance in predicting ALK mutations than the pre-contrast CT classifier (92). The ALK and EGFR mutation statuses in patients with

lung adenocarcinoma can be discriminated by the combined model incorporating CT image-based radiomic and clinical features or CT image-based radiomics alone (74,90).

Owing to the low prevalence of ALK-positive lung tumours (93), their imaging characteristics and their relationship to molecular phenotypes are less known than those of EGFR-positive tumours. In terms of imaging methods with positive prediction of ALK rearrangement, there are relatively small studies on conventional CT imaging features and CT image-based radiomic features, but they still show good application prospects. Further studies with big data and prospective research are needed.

Conventional CT imaging features and CT image-based radiomic features predict KRAS mutation in lung adenocarcinoma

KRAS mutation is another common mutation in lung adenocarcinoma and more common in smokers and the Western population (10,94). For many years, targeted drugs for KRAS gene mutations have been a research hotspot, but no effective clinical drugs have been developed, and KRAS is considered a type of mutation with no response to targeted therapy; it is associated with TKI resistance (95) and often indicates poor prognosis (96). However, it has been reported recently that sotorasib showed encouraging anticancer activity in patients with heavily pretreated advanced solid tumours harbouring the KRAS p.G12C mutation (97). On conventional CT images, solid and rounded masses are the main features (51,52,61). Intrapulmonary and pleural metastases are rare in cases with KRAS mutation (52).

Studies predicting the KRAS mutation of lung adenocarcinoma by CT image-based radiomics are very limited. We found that the only study was guided by Rios Velazquez *et al.* (66). They conducted a multicentric study with four independent, large-scale cohorts to predict KRAS mutations by CT image-based radiomics. The results showed that CT image-based radiomic features were not effective in predicting KRAS mutations, and the AUC was 0.63. In this experiment, the combination of CT image-based radiomic and clinical features (AUC =0.69) to predict KRAS mutation status had higher predictive power than CT image-based radiomics (AUC =0.63) but lower predictive power than clinical features (AUC =0.75), which is different from the situation of EGFR and ALK mutation status. It is worth mentioning that the combination of clinical features and radiomic features effectively distinguished EGFR and

KRAS mutations, with an AUC of 0.86 (66).

There are only a few studies on the prediction of KRAS mutation by CT image-based radiomics, which may be related to the lack of corresponding targeted drugs. However, existing studies show that conventional CT imaging and CT image-based radiomic features still have value in predicting KRAS mutations in lung adenocarcinoma. Conventional CT imaging features of the above three relatively common gene mutations in lung adenocarcinoma are summarized in *Table 2*. Predicting the above three relatively common gene mutations with CT image-based radiomic features are summarized in *Table 3*.

Conventional CT imaging features and CT image-based radiomic features predict other rare mutations in adenocarcinoma

There are also some rare types of mutations in lung adenocarcinoma, such as RET rearrangement and ROS-1, BRAF, and HER2 mutations. Targeted therapy aimed at these rare mutations is still being studied. In terms of conventional CT imaging features, these rare mutations are characterized by solid nodules (89,98-102), and each mutation has its own detailed CT characteristics in lung adenocarcinoma. ROS1-rearranged adenocarcinoma appeared as solid tumours and was associated with young age (89), pericardial metastases, and advanced nodal metastases (102). Masses with RET rearrangement have a rounded or lobulated margin and are less likely to have lymph node metastasis and commonly have pleural, lung, bone, and brain metastases (98,99). BRAF mutation are often located in the peripheral lung field with burrs (100). In the peripheral lung field, pleural traction, and lymph node metastasis are common in lung adenocarcinoma of HER2 mutation, which indicates that this kind of mutation type has higher invasive potential (101). We have not found studies of CT image-based radiomic features to predict these rare mutations in lung adenocarcinoma.

Shortcomings and challenges in radiomics

In the past five years, there have been more studies predicting mutated genes with CT image-based radiomics than with conventional CT images. The high-dimensional CT image-based radiomic features produced superior identifying performance compared with that of low-dimensional conventional CT images for distinguishing the gene mutation status in lung adenocarcinoma (76).

However, the predicted results of CT image-based radiomics are partly not satisfactory (74,75) and are even worse than the predicted results of clinical features alone (66,70). The reasons for the instability of CT image-based radiomic performance come from many aspects of the whole process of radiomics which are also the shortcomings and challenges in radiomics. (I) Image acquisition and reconstruction protocols lack standardization. The differences of parameters of acquisition and image reconstruction algorithm can introduce changes that are not due to underlying biological effects when images are analysed numerically, where the heterogeneity of radiomic study design mainly lies in studies. To achieve reproducibility, the same or similar scanning parameters, including layer thickness, tube voltage and tube current, are needed, and the reconstruction algorithm should be standardized and generalized. However, there is still no unified CT scanning protocol or image reconstruction standard. We need further study to establish image acquisition and reconstruction protocol standardization. (II) There is no unified method for the accurate segmentation of regions of interest (ROIs). Segmenting the nodule from the adjacent region accurately is the most critical, challenging, and contentious component of radiomics, so an accurate and repeatable nodule segmentation method is needed. Some scholars believe that the combination of computer-aided edge detection and manual segmentation can achieve the best results, but there is no consensus on which method is better (29,103). (III) In application, the specific algorithm of radiomics cannot be explained. The feature extraction part is not transparent. How to make clinicians trust this tool is another problem. (IV) Most of the studies based on radiomics are retrospective studies with small sample sizes, which is another reason for the heterogeneity of study design in studies. There is a lack of multiple-site, large-cohort, prospective studies. Ideally, current studies should be combined to provide a meta-analysis, which is what our research team intends to do next.

Summary and prospect

In general, conventional CT images provide some information for predicting lung adenocarcinoma gene mutations, however, some features overlap and lack specificity, and it is subjective and lacks objective basis. CT image-based radiomics provides a potential noninvasive method for the prediction of different gene mutations in lung adenocarcinoma when surgery and

Table 2 Conventional CT features of different mutated genes in lung adenocarcinoma

Study	Patient selection	Mutation genes	CT features
Liu, <i>et al.</i> Radiology 2016 (25)	385 surgically resected patients	EGFR	Smaller tumour GGO Bubblelike lucency Homogeneous enhancement Pleural retraction
Hong, <i>et al.</i> Eur Radiol 2016 (50)	250 consecutive patients	EGFR	High proportion of GGO GGO in exon 19 or 20 mutation
Rizzo, <i>et al.</i> Eur Radiol 2016 (51)	285 patients	EGFR	EGFR-air bronchogram Pleural retraction Small lesion size Absence of fibrosis
Han, <i>et al.</i> Sci Rep 2021 (59)	827 surgically resected patients	ALK	ALK-pleural effusion
		KRAS	KRAS-Round lesion shape
		EGFR	EGFR-GGO Air bronchograms Pleural retraction GGO in exon 21 mutation higher than in the exon 19 mutation
Zhang, <i>et al.</i> Transl Oncol 2021 (46)	302 patients	EGFR	ALK-Solid tumours Bubble-like lucency Pleural attachment Thickened adjacent bronchovascular bundles
Suh, <i>et al.</i> Lung Cancer 2018 (47)	864 surgically resected patients	EGFR	Smaller tumour GGO (in exon 21 mutation higher than in the exon 19 mutation)
Zou, <i>et al.</i> Thorac cancer 2017 (48)	209 surgically resected patients	EGFR	GGO (similar between the exon 21 and 19 mutations)
Usuda, <i>et al.</i> Asian Pac J Cancer Prev 2014 (54)	148 patients	EGFR	GGO
Yano, <i>et al.</i> J Thorac Oncol 2006 (55)	135 surgically resected patients	EGFR	GGO Small peripheral adenocarcinoma
Han, <i>et al.</i> Cancer Imaging 2020 (53)	137 lung adenocarcinomas	EGFR	EGFR-GGO Less lymph node metastasis
		ALK	ALK-Solid nodule
Zheng, <i>et al.</i> Oncol Lett 2020 (89)	1,120 patients	ALK/ROS-1	Solid nodule

Table 2 (continued)

Table 2 (continued)

Study	Patient selection	Mutation genes	CT features
Park, <i>et al.</i> PLoS One 2016 (52)	265 patients	EGFR	EGFR-GGO
			Lung metastasis
		ALK	ALK-Lymphadenopathy Extranodal invasion Lymphangitis
		KRAS	KRAS- Solid nodule Less likely lung and pleura metastasis
Kim, <i>et al.</i> Ann Thorac Surg 2016 (86)	497 surgically resected patients	ALK	Solid nodule Lobulated margin Hypoattenuation at contrast-enhanced CT scan $AUC_{ALK} = 0.832$
Choi, <i>et al.</i> Radiology 2015 (87)	198 patients	ALK	Solid nodule Lobulated margin Lymphangitic metastasis Advanced lymph node metastasis Pleural or pericardial metastasis $AUC_{ALK} = 0.855$
Kim, <i>et al.</i> Ann Thorac Surg 2016 (86)	497 surgically resected patients	ALK	Solid lesion Lobulated margin Hypoattenuation at contrast-enhanced CT scan $AUC = 0.832$
Yamamoto, <i>et al.</i> Radiology 2014 (88)	172 patients	ALK	Central tumour location Absence of pleural tail Large pleural effusion
Sugano, <i>et al.</i> Oncol Rep 2011 (61)	136 surgically resected patients	KRAS	Tumour diameter ≥ 3 mm
Zhou, <i>et al.</i> Eur Radiol 2015 (60)	346 patients	ALK	Solid nodule

CT, computed tomography; EGFR, epidermal growth factor receptor; GGO, ground glass opacity; ALK, anaplastic lymphoma kinase; KRAS, Kirsten rat sarcoma viral oncogene; AUC, Area Under the Curve.

biopsy are not available and radiomics models comparing clinical features could help to make treatment decisions. Artificial intelligence is an irreversible trend of medical development. As a primary part of artificial intelligence, in recent years, radiomics studies have been repeated without new breakthroughs. The author believes that the precise automatic recognition of artificial intelligence will replace the manual sketch of radiomics, the process that the sketched region of interest submitted to radiomics company

for processing will be replaced by one click analysis software, and deep learning, such as the neural network, will replace simple machine learning in the classification of gene mutation in lung adenocarcinoma. Research on the application of conventional CT imaging features and CT image-based radiomic features for predicting the gene mutation status of lung adenocarcinoma is still in a preliminary stage. Although there is some hope that radiomics could be applied in clinical practice, more work

Table 3 Predicting different mutated genes with CT image-based radiomic features

Study	Mutation gene	Patient selection	Radiomic parameters	Results
Zhang, <i>et al.</i> Am J Cancer Res 2021 (76)	EGFR	420	1,468 radiomic features	Radiomics: AUC _{EGFR} =0.81 CT + clinical features: AUC _{EGFR} =0.796 Combination: Development cohort AUC _{EGFR} =0.849, validation cohort AUC _{EGFR} =0.835
Zhang, <i>et al.</i> Front Oncol 2020 (73)	EGFR	914	1037 radiomic features	Internal test cohort: AUC _{EGFR} =0.910 External test cohort: AUC _{EGFR} =0.841
Zhao, <i>et al.</i> Front Oncol 2019 (68)	EGFR Subtypes (EGFR exon 19 deletion and exon 21 L858R substitution)	637	475 radiomic features (50 grey-level histogram features, 325 GLCM features, 100 GLRLM features)	Radiomics-based nomogram: validation cohort AUC _{EGFR} =0.734, AUC _{EGFR subtypes} =0.757
Liu, <i>et al.</i> Transl Lung Cancer Res 2020 (64)	EGFR Subtypes (EGFR exon 19 deletion and exon 21 L858R substitution)	263	10 most relevant radiomic features	Radiomics: AUC _{EGFR} =0.73 Radiomics: AUCexon 19 deletion =0.70 Radiomics: AUCexon 21 L858R substitution =0.65
Li, <i>et al.</i> Med Phys 2020 (72)	EGFR Subtypes (EGFR exon 19 deletion and exon 21 L858R substitution)	438	474 radiomic features (48 Histogram features, 56 intensity features, 330 2D GLCM, 33 2D GLRLM, 8 Laplacian of Gaussian filters, 5 2D NIDM, 18 3D Shape) EGFR-12 radiomic features EGFR subtypes-7 radiomic features	Training cohort AUC _{EGFR} =0.8, Accuracy _{EGFR} =0.75 Validation cohort AUC _{EGFR} =0.79, Accuracy _{EGFR} =0.72 AUC _{subtypes} =0.73
Lu, <i>et al.</i> Phys Med Biol 2020 (67)	EGFR	104	13 features extracted from 1025 features	Radiomics-based nomogram: training cohort AUC _{EGFR} =0.9, validation cohort AUC _{EGFR} =0.88, text cohort AUC _{EGFR} =0.894 CT + clinical: AUC _{EGFR} =0.768 Radiomics: AUC _{EGFR} =0.837
Hong, <i>et al.</i> Front Oncol 2020 (63)	EGFR	201	21 features extracted from 396 features	Validation cohort AUC _{EGFR} =0.851 Training cohort C-index =0.908 Validation cohort C-index =0.835
Jia, <i>et al.</i> Eur Radiol 2019 (62)	EGFR	503	94 radiomic features (8 first-order statistics, 3 shape and size based features, 5 textural features, 78 wavelet features)	Radiomic features: AUC _{EGFR} =0.802 Radiomic + clinical features: AUC _{EGFR} =0.828 Accuracy _{radiomic + clinical features} =77.2% Specificity _{radiomic + clinical features} =85.1%
Yang, <i>et al.</i> Oncologist 2019 (65)	EGFR	467	1,063 radiomic features	Radiomic + clinical features: Training cohort AUC _{EGFR} =0.831, Validation cohort AUC _{EGFR} =0.789 Clinical features: Training cohort AUC _{EGFR} =0.687, Validation cohort AUC _{EGFR} =0.665
Mei, <i>et al.</i> Cancer Imaging 2018 (75)	EGFR	296	94 texture features (19 first-order features, 27 GLCM features, 16 GLRLM features, 16 GLSZM features, 16 shape features)	Radiomic + clinical features: AUC _{EGFR} =0.664 AUC _{exon 19 deletion} =0.655 AUC _{exon 21 L858R substitution} =0.675

Table 3 (continued)

Table 3 (continued)

Study	Mutation gene	Patient selection	Radiomic parameters	Results
Rios Velazquez, et al. Cancer Res 2017 (66)	EGFR KRAS	763	26 radiomic features (tumour intensity features, textural features, shape features, wavelet features, Laplacian of Gaussian features) EGFR-16 radiomic features KRAS-10 radiomic features EGFR/KRAS-14 radiomic features	Radiomics: $AUC_{EGFR}=0.69$, $AUC_{KRAS}=0.63$, $AUC_{EGFR/KRAS}=0.80$ Radiomics + clinical features: $AUC_{EGFR}=0.75$ $AUC_{KRAS}=0.69$ $AUC_{EGFR/KRAS}=0.86$ Clinical features: $AUC_{KRAS}=0.75$
Liu, et al. Clin Lung Cancer 2016 (69)	EGFR	298	11 radiomic features (shape, location, air space, pixel intensity histogram, run length & co-occurrence, laws texture, wavelets)	Radiomics: $AUC_{EGFR}=0.667$ Radiomics + clinical features: $AUC_{EGFR}=0.709$
Digumarthy, et al. Medicine (Baltimore) 2019 (70)	EGFR	93	Skewness, kurtosis, entropy, mean Positive Pixel, normalized SD	Radiomics: $AUC_{EGFR}=0.725$ Clinical features: $AUC_{EGFR}=0.794$ Conventional CT images: $AUC_{EGFR}=0.553$ Radiomics + clinical features + conventional CT images: $AUC_{EGFR}=0.863$ $AUC_{EGFR}=0.83$
Li, et al. Sci Rep 2018 (71)	EGFR	51	1,695 radiomic features	
Choe, et al. Eur J Radiol 2021 (74)	EGFR ALK	503	85 intratumoural radiomic features (shape, tumour intensity, texture feature) 78 peritumoural radiomic features (tumour intensity, texture feature)	Radiomics: Development cohort $AUC_{EGFR}=0.64$, Validation cohort $AUC_{EGFR}=0.62$ Development cohort $AUC_{ALK}=0.77$, Validation cohort $AUC_{ALK}=0.68$ Development cohort $AUC_{EGFR/ALK}=0.72$, Validation cohort $AUC_{EGFR/ALK}=0.63$ Radiomics + Clinical features: Development cohort $AUC_{EGFR}=0.68$, Validation cohort $AUC_{EGFR}=0.64$ Development cohort $AUC_{ALK}=0.79$, Validation cohort $AUC_{ALK}=0.70$ Development cohort $AUC_{EGFR/ALK}=0.82$, Validation cohort $AUC_{EGFR/ALK}=0.75$ Independent test cohort: global accuracy =81.76%
Agazzi, et al. Radio Med 2021 (90)	EGFR ALK	84	171 radiomic features (mean grey level intensity, SD, entropy, mean of positive pixels, skewness, kurtosis, normalized SD)	
Song, et al. Front Oncol 2020 (91)	ALK	335	1,218 radiomic features (first-order features, shape features, GLCM features, GLSZM features, GLRLM features, GLDM features)	Radiomics + clinical features + conventional CT images: Validation cohort $AUC_{ALK}=0.83-0.88$, Test cohort $AUC_{ALK}=0.80-0.88$ Radiomics: $AUC_{ALK}=0.83$
Ma, et al. Onco Targets Ther 2020 (92)	ALK	140	851 radiomic features (shape, first-order, GLCM, GLSZM, GLRLM, Neighbouring Grey Tone Difference Matrix, GLDM)	Pre-Contrast: Training cohort $AUC_{ALK}=0.859$, Validation cohort $AUC_{ALK}=0.801$, Test cohort $AUC_{ALK}=0.801$ Post-Contrast: Training cohort $AUC_{ALK}=0.911$, Validation cohort $AUC_{ALK}=0.8285$, Test cohort $AUC_{ALK}=0.829$

EGFR, epidermal growth factor receptor; AUC, area under the curve; 2D, 2 dimensions; GLCM, grey level co-occurrence matrix; GLRLM, grey level run length matrix; NIDM, neighbourhood intensity-difference matrix; 3D, 3 dimensions; GLSZM, grey level size zone matrix; GLDM, grey level dependence matrix; SD, standard deviation; KRAS, Kirsten rat sarcoma viral oncogene; ALK, anaplastic lymphoma kinase.

needs to be done.

Acknowledgments

Funding: None.

Footnote

Reporting Checklist: The authors have completed the Narrative Review reporting checklist. Available at <https://dx.doi.org/10.21037/tcr-21-1037>

Peer Review File: Available at <https://dx.doi.org/10.21037/tcr-21-1037>

Conflicts of Interest: Both authors have completed the ICMJE uniform disclosure form (available at <https://dx.doi.org/10.21037/tcr-21-1037>). The authors have no conflicts of interest to declare.

Ethical Statement: The authors are accountable for all aspects of the work in ensuring that questions related to the accuracy or integrity of any part of the work are appropriately investigated and resolved.

Open Access Statement: This is an Open Access article distributed in accordance with the Creative Commons Attribution-NonCommercial-NoDerivs 4.0 International License (CC BY-NC-ND 4.0), which permits the non-commercial replication and distribution of the article with the strict proviso that no changes or edits are made and the original work is properly cited (including links to both the formal publication through the relevant DOI and the license). See: <https://creativecommons.org/licenses/by-nc-nd/4.0/>.

References

- Safiri S, Sohrabi MR, Carson-Chahhoud K, et al. Burden of Tracheal, Bronchus, and Lung Cancer and Its Attributable Risk Factors in 204 Countries and Territories, 1990 to 2019. *J Thorac Oncol* 2021;16:945-59.
- Siegel RL, Miller KD, Fuchs HE, et al. Cancer Statistics, 2021. *CA Cancer J Clin* 2021;71:7-33.
- Yu YW, Wang CP, Han YF, et al. Meta-analysis on related risk factors regarding lung cancer in non-smoking Chinese women. *Zhonghua Liu Xing Bing Xue Za Zhi* 2016;37:268-72.
- Lin KF, Wu HF, Huang WC, et al. Propensity score analysis of lung cancer risk in a population with high prevalence of non-smoking related lung cancer. *BMC Pulm Med* 2017;17:120.
- Detterbeck FC, Nicholson AG, Franklin WA, et al. The IASLC Lung Cancer Staging Project: Summary of Proposals for Revisions of the Classification of Lung Cancers with Multiple Pulmonary Sites of Involvement in the Forthcoming Eighth Edition of the TNM Classification. *J Thorac Oncol* 2016;11:639-50.
- Subramanian J, Govindan R. Lung cancer in never smokers: a review. *J Clin Oncol* 2007;25:561-70.
- Wu FZ, Chen PA, Wu CC, et al. Semiquantitative Visual Assessment of Sub-solid Pulmonary Nodules ≤ 3 cm in Differentiation of Lung Adenocarcinoma Spectrum. *Sci Rep* 2017;7:15790.
- Wu FZ, Huang YL, Wu CC, et al. Assessment of Selection Criteria for Low-Dose Lung Screening CT Among Asian Ethnic Groups in Taiwan: From Mass Screening to Specific Risk-Based Screening for Non-Smoker Lung Cancer. *Clin Lung Cancer* 2016;17:e45-56.
- Rosell R, Carcereny E, Gervais R, et al. Erlotinib versus standard chemotherapy as first-line treatment for European patients with advanced EGFR mutation-positive non-small-cell lung cancer (EURTAC): a multicentre, open-label, randomised phase 3 trial. *Lancet Oncol* 2012;13:239-46.
- Guan JL, Zhong WZ, An SJ, et al. KRAS mutation in patients with lung cancer: a predictor for poor prognosis but not for EGFR-TKIs or chemotherapy. *Ann Surg Oncol* 2013;20:1381-8.
- Meng D, Yuan M, Li X, et al. Prognostic value of K-RAS mutations in patients with non-small cell lung cancer: a systematic review with meta-analysis. *Lung Cancer* 2013;81:1-10.
- Woo T, Okudela K, Yazawa T, et al. Prognostic value of KRAS mutations and Ki-67 expression in stage I lung adenocarcinomas. *Lung Cancer* 2009;65:355-62.
- Li P, Gao Q, Jiang X, et al. Comparison of Clinicopathological Features and Prognosis between ALK Rearrangements and EGFR Mutations in Surgically Resected Early-stage Lung Adenocarcinoma. *J Cancer* 2019;10:61-71.
- Tao H, Cai Y, Shi L, et al. Analysis of clinical characteristics and prognosis of patients with anaplastic lymphoma kinase-positive and surgically resected lung adenocarcinoma. *Thorac Cancer* 2017;8:8-15.
- Liu Y, Ye X, Yu Y, et al. Prognostic significance of anaplastic lymphoma kinase rearrangement in patients

- with completely resected lung adenocarcinoma. *J Thorac Dis* 2019;11:4258-70.
16. Dong Y, Li Y, Jin B, et al. Pathologic subtype-defined prognosis is dependent on both tumor stage and status of oncogenic driver mutations in lung adenocarcinoma. *Oncotarget* 2017;8:82244-55.
 17. Hsiao SH, Lin HC, Chou YT, et al. Impact of epidermal growth factor receptor mutations on intracranial treatment response and survival after brain metastases in lung adenocarcinoma patients. *Lung Cancer* 2013;81:455-61.
 18. Kosaka T, Yatabe Y, Onozato R, et al. Prognostic implication of EGFR, KRAS, and TP53 gene mutations in a large cohort of Japanese patients with surgically treated lung adenocarcinoma. *J Thorac Oncol* 2009;4:22-9.
 19. Robertson EG, Baxter G. Tumour seeding following percutaneous needle biopsy: the real story! *Clin Radiol* 2011;66:1007-14.
 20. Shyamala K, Girish HC, Murgod S. Risk of tumor cell seeding through biopsy and aspiration cytology. *J Int Soc Prev Community Dent* 2014;4:5-11.
 21. Pascoe HM, Knipe HC, Pascoe D, et al. The many faces of lung adenocarcinoma: A pictorial essay. *J Med Imaging Radiat Oncol* 2018;62:654-61.
 22. Hansell DM, Bankier AA, MacMahon H, et al. Fleischner Society: glossary of terms for thoracic imaging. *Radiology* 2008;246:697-722.
 23. Gaikwad A, Gupta A, Hare S, et al. Primary adenocarcinoma of lung: a pictorial review of recent updates. *Eur J Radiol* 2012;81:4146-55.
 24. Yoshida T, Harada T, Fuke S, et al. Lung adenocarcinoma presenting with enlarged and multiloculated cystic lesions over 2 years. *Respir Care* 2004;49:1522-4.
 25. Liu Y, Kim J, Qu F, et al. CT Features Associated with Epidermal Growth Factor Receptor Mutation Status in Patients with Lung Adenocarcinoma. *Radiology* 2016;280:271-80.
 26. Balagurunathan Y, Gu Y, Wang H, et al. Reproducibility and Prognosis of Quantitative Features Extracted from CT Images. *Transl Oncol* 2014;7:72-87.
 27. Zhou M, Leung A, Echeagaray S, et al. Non-Small Cell Lung Cancer Radiogenomics Map Identifies Relationships between Molecular and Imaging Phenotypes with Prognostic Implications. *Radiology* 2018;286:307-15.
 28. Aerts HJ, Velazquez ER, Leijenaar RT, et al. Decoding tumour phenotype by noninvasive imaging using a quantitative radiomics approach. *Nat Commun* 2014;5:4006.
 29. Gillies RJ, Kinahan PE, Hricak H. Radiomics: Images Are More than Pictures, They Are Data. *Radiology* 2016;278:563-77.
 30. Yatabe Y, Kerr KM, Utomo A, et al. EGFR mutation testing practices within the Asia Pacific region: results of a multicenter diagnostic survey. *J Thorac Oncol* 2015;10:438-45.
 31. Shigematsu H, Lin L, Takahashi T, et al. Clinical and biological features associated with epidermal growth factor receptor gene mutations in lung cancers. *J Natl Cancer Inst* 2005;97:339-46.
 32. da Cunha Santos G, Shepherd FA, Tsao MS. EGFR mutations and lung cancer. *Annu Rev Pathol* 2011;6:49-69.
 33. Tan CS, Gilligan D, Pacey S. Treatment approaches for EGFR-inhibitor-resistant patients with non-small-cell lung cancer. *Lancet Oncol* 2015;16:e447-59.
 34. Zhu JQ, Zhong WZ, Zhang GC, et al. Better survival with EGFR exon 19 than exon 21 mutations in gefitinib-treated non-small cell lung cancer patients is due to differential inhibition of downstream signals. *Cancer Lett* 2008;265:307-17.
 35. Zhou J, Ben S. Comparison of therapeutic effects of EGFR-tyrosine kinase inhibitors on 19Del and L858R mutations in advanced lung adenocarcinoma and effect on cellular immune function. *Thorac Cancer* 2018;9:228-33.
 36. He Q, Xin P, Zhang M, et al. The impact of epidermal growth factor receptor mutations on the prognosis of resected non-small cell lung cancer: a meta-analysis of literatures. *Transl Lung Cancer Res* 2019;8:124-34.
 37. Rosell R, Moran T, Queralt C, et al. Screening for epidermal growth factor receptor mutations in lung cancer. *N Engl J Med* 2009;361:958-67.
 38. Mok TS, Wu YL, Thongprasert S, et al. Gefitinib or carboplatin-paclitaxel in pulmonary adenocarcinoma. *N Engl J Med* 2009;361:947-57.
 39. Mao R, She Y, Zhu E, et al. A Proposal for Restaging of Invasive Lung Adenocarcinoma Manifesting as Pure Ground Glass Opacity. *Ann Thorac Surg* 2019;107:1523-31.
 40. Wilshire CL, Louie BE, Manning KA, et al. Radiologic Evaluation of Small Lepidic Adenocarcinomas to Guide Decision Making in Surgical Resection. *Ann Thorac Surg* 2015;100:979-88.
 41. Takahashi M, Shigematsu Y, Ohta M, et al. Tumor invasiveness as defined by the newly proposed IASLC/ATS/ERS classification has prognostic significance for pathologic stage IA lung adenocarcinoma and can be predicted by radiologic parameters. *J Thorac Cardiovasc Surg* 2014;147:54-9.

42. Tsubochi H, Sakaguchi H, Yamasaki N, et al. Clinicopathologic analysis of small-sized non-small cell lung cancer. *Kyobu Geka* 2012;65:4-10.
43. Asamura H, Suzuki K, Watanabe S, et al. A clinicopathological study of resected subcentimeter lung cancers: a favorable prognosis for ground glass opacity lesions. *Ann Thorac Surg* 2003;76:1016-22.
44. Cibas ES, Melamed MR, Zaman MB, et al. The effect of tumor size and tumor cell DNA content on the survival of patients with stage I adenocarcinoma of the lung. *Cancer* 1989;63:1552-6.
45. Lee SY, Jeon JH, Jung W, et al. Predictive Factors for Lymph Node Metastasis in Clinical Stage I Part-Solid Lung Adenocarcinoma. *Ann Thorac Surg* 2021;111:456-62.
46. Zhang G, Zhang J, Cao Y, et al. Nomogram based on preoperative CT imaging predicts the EGFR mutation status in lung adenocarcinoma. *Transl Oncol* 2021;14:100954.
47. Suh YJ, Lee HJ, Kim YJ, et al. Computed tomography characteristics of lung adenocarcinomas with epidermal growth factor receptor mutation: A propensity score matching study. *Lung Cancer* 2018;123:52-9.
48. Zou J, Lv T, Zhu S, et al. Computed tomography and clinical features associated with epidermal growth factor receptor mutation status in stage I/II lung adenocarcinoma. *Thorac Cancer* 2017;8:260-70.
49. Hasegawa M, Sakai F, Ishikawa R, et al. CT Features of Epidermal Growth Factor Receptor-Mutated Adenocarcinoma of the Lung: Comparison with Nonmutated Adenocarcinoma. *J Thorac Oncol* 2016;11:819-26.
50. Hong SJ, Kim TJ, Choi YW, et al. Radiogenomic correlation in lung adenocarcinoma with epidermal growth factor receptor mutations: Imaging features and histological subtypes. *Eur Radiol* 2016;26:3660-8.
51. Rizzo S, Petrella F, Buscarino V, et al. CT Radiogenomic Characterization of EGFR, K-RAS, and ALK Mutations in Non-Small Cell Lung Cancer. *Eur Radiol* 2016;26:32-42.
52. Park J, Kobayashi Y, Urayama KY, et al. Imaging Characteristics of Driver Mutations in EGFR, KRAS, and ALK among Treatment-Naïve Patients with Advanced Lung Adenocarcinoma. *PLoS One* 2016;11:e0161081.
53. Han X, Fan J, Gu J, et al. CT features associated with EGFR mutations and ALK positivity in patients with multiple primary lung adenocarcinomas. *Cancer Imaging* 2020;20:51.
54. Usuda K, Sagawa M, Motono N, et al. Relationships between EGFR mutation status of lung cancer and preoperative factors - are they predictive? *Asian Pac J Cancer Prev* 2014;15:657-62.
55. Yano M, Sasaki H, Kobayashi Y, et al. Epidermal growth factor receptor gene mutation and computed tomographic findings in peripheral pulmonary adenocarcinoma. *J Thorac Oncol* 2006;1:413-6.
56. Lee HJ, Kim YT, Kang CH, et al. Epidermal growth factor receptor mutation in lung adenocarcinomas: relationship with CT characteristics and histologic subtypes. *Radiology* 2013;268:254-64.
57. Yoshida Y, Kokubu A, Suzuki K, et al. Molecular markers and changes of computed tomography appearance in lung adenocarcinoma with ground-glass opacity. *Jpn J Clin Oncol* 2007;37:907-12.
58. Yang Y, Yang Y, Zhou X, et al. EGFR L858R mutation is associated with lung adenocarcinoma patients with dominant ground-glass opacity. *Lung Cancer* 2015;87:272-7.
59. Han X, Fan J, Li Y, et al. Value of CT features for predicting EGFR mutations and ALK positivity in patients with lung adenocarcinoma. *Sci Rep* 2021;11:5679.
60. Zhou JY, Zheng J, Yu ZF, et al. Comparative analysis of clinicoradiologic characteristics of lung adenocarcinomas with ALK rearrangements or EGFR mutations. *Eur Radiol* 2015;25:1257-66.
61. Sugano M, Shimizu K, Nakano T, et al. Correlation between computed tomography findings and epidermal growth factor receptor and KRAS gene mutations in patients with pulmonary adenocarcinoma. *Oncol Rep* 2011;26:1205-11.
62. Jia TY, Xiong JF, Li XY, et al. Identifying EGFR mutations in lung adenocarcinoma by noninvasive imaging using radiomics features and random forest modeling. *Eur Radiol* 2019;29:4742-50.
63. Hong D, Xu K, Zhang L, et al. Radiomics Signature as a Predictive Factor for EGFR Mutations in Advanced Lung Adenocarcinoma. *Front Oncol* 2020;10:28.
64. Liu G, Xu Z, Ge Y, et al. 3D radiomics predicts EGFR mutation, exon-19 deletion and exon-21 L858R mutation in lung adenocarcinoma. *Transl Lung Cancer Res* 2020;9:1212-24.
65. Yang X, Dong X, Wang J, et al. Computed Tomography-Based Radiomics Signature: A Potential Indicator of Epidermal Growth Factor Receptor Mutation in Pulmonary Adenocarcinoma Appearing as a Subsolid Nodule. *Oncologist* 2019;24:e1156-64.
66. Rios Velazquez E, Parmar C, Liu Y, et al. Somatic Mutations Drive Distinct Imaging Phenotypes in Lung

- Cancer. *Cancer Res* 2017;77:3922-30.
67. Lu X, Li M, Zhang H, et al. A novel radiomic nomogram for predicting epidermal growth factor receptor mutation in peripheral lung adenocarcinoma. *Phys Med Biol* 2020;65:055012.
 68. Zhao W, Wu Y, Xu Y, et al. The Potential of Radiomics Nomogram in Non-invasively Prediction of Epidermal Growth Factor Receptor Mutation Status and Subtypes in Lung Adenocarcinoma. *Front Oncol* 2020;9:1485.
 69. Liu Y, Kim J, Balagurunathan Y, et al. Radiomic Features Are Associated With EGFR Mutation Status in Lung Adenocarcinomas. *Clin Lung Cancer* 2016;17:441-448.e6.
 70. Digumarthy SR, Padole AM, Gullo RL, et al. Can CT radiomic analysis in NSCLC predict histology and EGFR mutation status? *Medicine (Baltimore)* 2019;98:e13963.
 71. Li Y, Lu L, Xiao M, et al. CT Slice Thickness and Convolution Kernel Affect Performance of a Radiomic Model for Predicting EGFR Status in Non-Small Cell Lung Cancer: A Preliminary Study. *Sci Rep* 2018;8:17913.
 72. Li S, Luo T, Ding C, et al. Detailed identification of epidermal growth factor receptor mutations in lung adenocarcinoma: Combining radiomics with machine learning. *Med Phys* 2020;47:3458-66.
 73. Zhang B, Qi S, Pan X, et al. Deep CNN Model Using CT Radiomics Feature Mapping Recognizes EGFR Gene Mutation Status of Lung Adenocarcinoma. *Front Oncol* 2021;10:598721.
 74. Choe J, Lee SM, Kim W, et al. CT radiomics-based prediction of anaplastic lymphoma kinase and epidermal growth factor receptor mutations in lung adenocarcinoma. *Eur J Radiol* 2021;139:109710.
 75. Mei D, Luo Y, Wang Y, et al. CT texture analysis of lung adenocarcinoma: can Radiomic features be surrogate biomarkers for EGFR mutation statuses. *Cancer Imaging* 2018;18:52.
 76. Zhang G, Cao Y, Zhang J, et al. Predicting EGFR mutation status in lung adenocarcinoma: development and validation of a computed tomography-based radiomics signature. *Am J Cancer Res* 2021;11:546-60.
 77. Kosaka T, Yatabe Y, Endoh H, et al. Analysis of epidermal growth factor receptor gene mutation in patients with non-small cell lung cancer and acquired resistance to gefitinib. *Clin Cancer Res* 2006;12:5764-9.
 78. Balak MN, Gong Y, Riely GJ, et al. Novel D761Y and common secondary T790M mutations in epidermal growth factor receptor-mutant lung adenocarcinomas with acquired resistance to kinase inhibitors. *Clin Cancer Res* 2006;12:6494-501.
 79. Cucchiara F, Del Re M, Valleggi S, et al. Integrating Liquid Biopsy and Radiomics to Monitor Clonal Heterogeneity of EGFR-Positive Non-Small Cell Lung Cancer. *Front Oncol* 2020;10:593831.
 80. Rossi G, Barabino E, Fedeli A, et al. Radiomic Detection of EGFR Mutations in NSCLC. *Cancer Res* 2021;81:724-31.
 81. Zhao R, Zhang J, Han Y, et al. Clinicopathological Features of ALK Expression in 9889 Cases of Non-small-Cell Lung Cancer and Genomic Rearrangements Identified by Capture-Based Next-Generation Sequencing: A Chinese Retrospective Analysis. *Mol Diagn Ther* 2019;23:395-405.
 82. Minguet J, Smith KH, Bramlage P. Targeted therapies for treatment of non-small cell lung cancer--Recent advances and future perspectives. *Int J Cancer* 2016;138:2549-61.
 83. Thai AA, Solomon BJ. Treatment of ALK-positive nonsmall cell lung cancer: recent advances. *Curr Opin Oncol* 2018;30:84-91.
 84. Zhang YC, Zhou Q, Wu YL. Efficacy of crizotinib in first-line treatment of adults with ALK-positive advanced NSCLC. *Expert Opin Pharmacother* 2016;17:1693-701.
 85. Wu YL, Lu S, Lu Y, et al. Results of PROFILE 1029, a Phase III Comparison of First-Line Crizotinib versus Chemotherapy in East Asian Patients with ALK-Positive Advanced Non-Small Cell Lung Cancer. *J Thorac Oncol* 2018;13:1539-48.
 86. Kim TJ, Lee CT, Jheon SH, et al. Radiologic Characteristics of Surgically Resected Non-Small Cell Lung Cancer With ALK Rearrangement or EGFR Mutations. *Ann Thorac Surg* 2016;101:473-80.
 87. Choi CM, Kim MY, Hwang HJ, et al. Advanced adenocarcinoma of the lung: comparison of CT characteristics of patients with anaplastic lymphoma kinase gene rearrangement and those with epidermal growth factor receptor mutation. *Radiology* 2015;275:272-9.
 88. Yamamoto S, Korn RL, Oklu R, et al. ALK molecular phenotype in non-small cell lung cancer: CT radiogenomic characterization. *Radiology* 2014;272:568-76.
 89. Zheng J, Zhou J, Liu J, et al. Quantitative volumetric assessment of the solid portion percentage on CT images to predict ROS1/ALK rearrangements in lung adenocarcinomas. *Oncol Lett* 2020;20:2987-96.
 90. Agazzi GM, Ravanelli M, Roca E, et al. CT texture analysis for prediction of EGFR mutational status and ALK rearrangement in patients with non-small cell lung cancer. *Radiol Med* 2021;126:786-94.
 91. Song L, Zhu Z, Mao L, et al. Clinical, Conventional CT

- and Radiomic Feature-Based Machine Learning Models for Predicting ALK Rearrangement Status in Lung Adenocarcinoma Patients. *Front Oncol* 2020;10:369.
92. Ma DN, Gao XY, Dan YB, et al. Evaluating Solid Lung Adenocarcinoma Anaplastic Lymphoma Kinase Gene Rearrangement Using Noninvasive Radiomics Biomarkers. *Onco Targets Ther* 2020;13:6927-35.
 93. Pan Y, Zhang Y, Li Y, et al. ALK, ROS1 and RET fusions in 1139 lung adenocarcinomas: a comprehensive study of common and fusion pattern-specific clinicopathologic, histologic and cytologic features. *Lung Cancer* 2014;84:121-6.
 94. Eberhard DA, Johnson BE, Amler LC, et al. Mutations in the epidermal growth factor receptor and in KRAS are predictive and prognostic indicators in patients with non-small-cell lung cancer treated with chemotherapy alone and in combination with erlotinib. *J Clin Oncol* 2005;23:5900-9.
 95. Massarelli E, Varella-Garcia M, Tang X, et al. KRAS mutation is an important predictor of resistance to therapy with epidermal growth factor receptor tyrosine kinase inhibitors in non-small-cell lung cancer. *Clin Cancer Res* 2007;13:2890-6.
 96. Lohinai Z, Klikovits T, Moldvay J, et al. KRAS-mutation incidence and prognostic value are metastatic site-specific in lung adenocarcinoma: poor prognosis in patients with KRAS mutation and bone metastasis. *Sci Rep* 2017;7:39721.
 97. Hong DS, Fakih MG, Strickler JH, et al. KRASG12C Inhibition with Sotorasib in Advanced Solid Tumors. *N Engl J Med* 2020;383:1207-17.
 98. Plodkowski AJ, Drilon A, Halpenny DE, et al. From genotype to phenotype: Are there imaging characteristics associated with lung adenocarcinomas harboring RET and ROS1 rearrangements? *Lung Cancer* 2015;90:321-5.
 99. Digumarthy SR, Mendoza DP, Lin JJ, et al. Imaging Features and Patterns of Metastasis in Non-Small Cell Lung Cancer with RET Rearrangements. *Cancers (Basel)* 2020;12:693.
 100. Villaruz LC, Socinski MA, Abberbock S, et al. Clinicopathologic features and outcomes of patients with lung adenocarcinomas harboring BRAF mutations in the Lung Cancer Mutation Consortium. *Cancer* 2015;121:448-56.
 101. Sawan P, Plodkowski AJ, Li AE, et al. CT features of HER2-mutant lung adenocarcinomas. *Clin Imaging* 2018;51:279-83.
 102. Woo JH, Kim TJ, Kim TS, et al. CT features and disease spread patterns in ROS1-rearranged lung adenocarcinomas: comparison with those of EGFR-mutant or ALK-rearranged lung adenocarcinomas. *Sci Rep* 2020;10:16251.
 103. Heye T, Merkle EM, Reiner CS, et al. Reproducibility of dynamic contrast-enhanced MR imaging. Part II. Comparison of intra- and interobserver variability with manual region of interest placement versus semiautomatic lesion segmentation and histogram analysis. *Radiology* 2013;266:812-21.

Cite this article as: Ma JW, Li M. Molecular typing of lung adenocarcinoma with computed tomography and CT image-based radiomics: a narrative review of research progress and prospects. *Transl Cancer Res* 2021;10(9):4217-4231. doi: 10.21037/tcr-21-1037