

Cone-beam computed tomography in the management of dentigerous cyst of the jaws: A report of two cases

Lakshminarayanan Vidya, Kannan Ranganathan¹, B Praveen, Rajan Gunaseelan, S Shanmugasundaram²

Chennai Dental Research Foundation, Dr. R. K. Salai, Mylapore, Chennai, ¹Department of Oral and Maxillofacial Pathology, Ragas Dental College and Hospital, Uthandi, Chennai, ²Rajan Dental Institute, Dr. R. K. Salai, Mylapore, Chennai, Tamilnadu, India

Correspondence: Dr. Kannan Ranganathan, Department of Oral and Maxillofacial Pathology, Ragas Dental College and Hospital, 2/102, East Coast Road, Uthandi, Chennai - 600 109, Tamil Nadu, India. E-mail: dr.ranganathan@gmail.com

Abstract

Cone-beam computed tomography (CBCT) is an emerging technology finding application in all branches of dentistry. The current series highlights the application of CBCT in the preoperative assessment of dentigerous cyst of the jaws.

Key words: Cone-beam computed tomography; dentigerous cyst; impacted teeth; inferior alveolar nerve; odontogenic cyst

Introduction

Cone-beam computed tomography (CBCT) is an emerging technology in three-dimensional digital imaging and is finding application in all branches of dentistry. It was initially developed as an imaging aid for performing angiography and has subsequently found application in guided radiotherapy, mammography, and dentistry.^[1]

The CBCT scanner, mounted on a rotating gantry, produces a cone-shaped beam of ionizing radiation from the source, which passes through the field of interest to reach the detector on the opposite end. The source and the detector rotate around the field on a fulcrum to produce sequential, complete or partial projections of images. The images are acquired by dedicated computers attached to the CBCT setup, and individually computed voxel (three-dimensional pixel or volumetric pixel) measurements are used for three-dimensional reconstruction with the software provided by the

manufacturer. The software is also used for volumetric rendering of the three-dimensional images through selective integration and measurement of adjacent voxels in the display.^[2,3]

Odontogenic lesions are common pathologies encountered in the jaw. Dentigerous cysts, the most frequently encountered developmental odontogenic cysts, develop by the accumulation of cystic fluid around the crown of unerupted, impacted, or partially erupted tooth. The cyst is mostly seen in the second to third decades of life and is commonly observed in the mandibular third molar or in the maxillary canine region. These cysts may be asymptomatic, but can cause expansion of the jaws and facial asymmetry. Periapical radiographs or orthopantomographs (OPG) usually reveal well-circumscribed unilocular cystic lesions associated with the crown of the unerupted tooth. Histological examination usually reveals the cystic cavity lined by two to four layers of cuboidal epithelial cells and surrounded by a fibrous connective tissue wall. Occasionally, mucus or goblet cells or pseudostratified ciliated columnar cells (usually in maxillary dentigerous cysts) can be observed in the cystic lining. Complications encountered in long-standing cysts include the development of ameloblastoma, mucoepidermoid carcinoma, or squamous cell carcinoma.^[4]

Radiographic evaluation is an important diagnostic procedure necessary to (a) detect the extent of large

Access this article online

Quick Response Code:



Website:
www.ijri.org

DOI:
10.4103/0971-3026.125614

lesions, (b) identify anatomical relationships, and (c) assess the margins of the lesion to ascertain the presence of infiltrative growth suggestive of development of an aggressive lesion. The current series describes the use of CBCT in the localization of the lesions and in the planning and management of two patients with cystic lesions of the jaws.

Case Reports

Case 1

A 17-year-old male patient was referred by an orthodontist for evaluation of a cystic radiolucency surrounding the crown of impacted 47 observed on a routine OPG [Figure 1A]. The OPG showed an unerupted 47 with a well-demarcated radiolucency around the coronal portion of the tooth, suggestive of a dentigerous cyst. The

tip of the roots of forty seven appeared to be impinging on the inferior alveolar canal. Also, the margins of the lesion were in close proximity to the distal root of 46 and the mesial root of forty eight. The patient was asymptomatic and examination did not reveal any abnormalities. He was advised surgical removal of the cyst along with impacted tooth and was prescribed a CBCT as part of the presurgical workup to aid in preserving the adjacent teeth and preventing nerve damage.

Based on the findings of CBCT study, the nerve was traced carefully and identified lingual to the roots and just touching the apex of the roots of forty seven. Also, the tip of the distal root of 46 was seen close to the lesion and hence an intentional RCT was performed. Tooth 48 was preserved and kept under observation. The CBCT images revealed that the roots of the impacted tooth

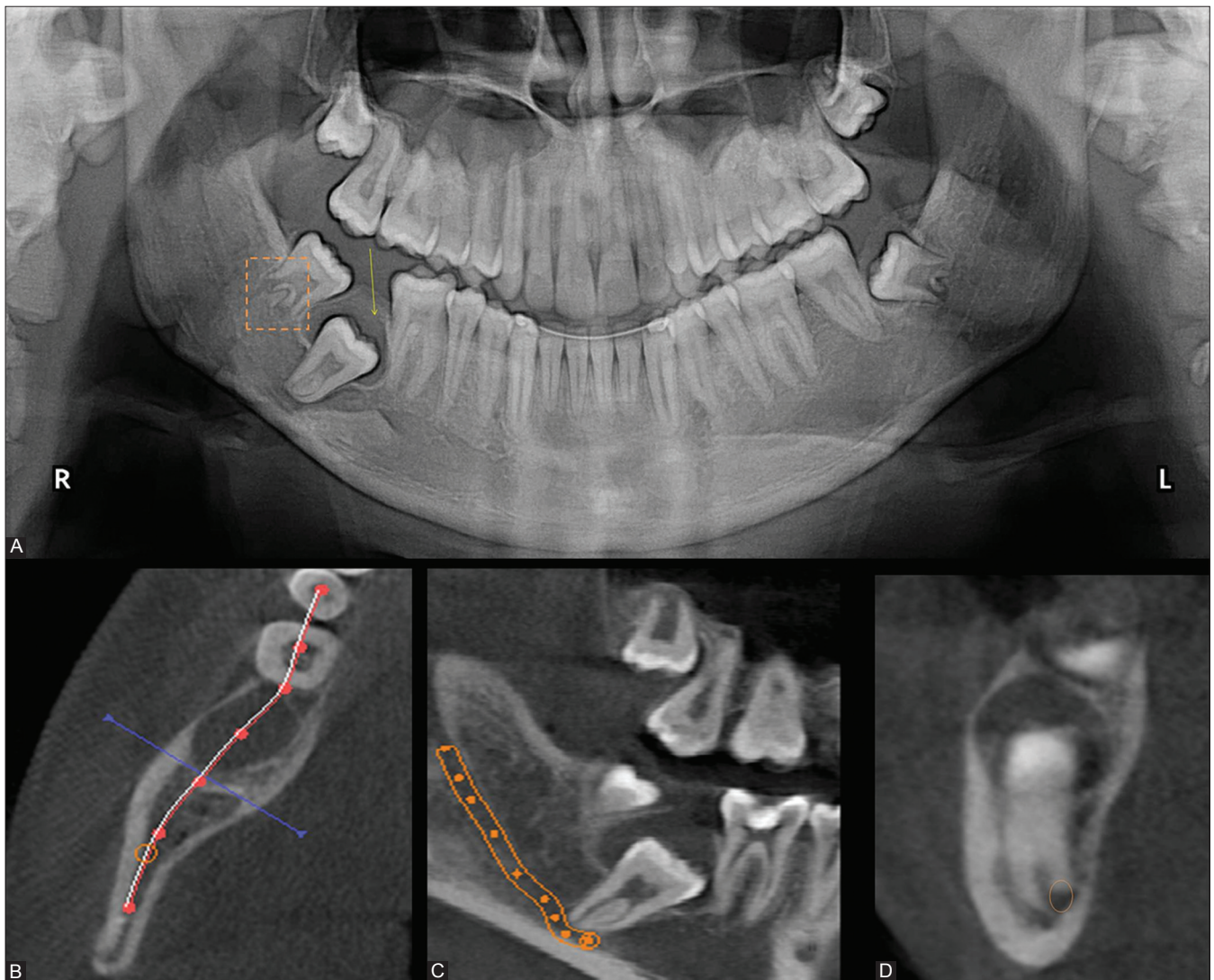


Figure 1(A-D): Radiographic examination in case 1: (A) Orthopantomograph reveals the crown of impacted thirty one surrounded by a radiolucent lesion (arrow), incomplete root formation in thirty two (square), (B-D) CBCT images reveal the course of the inferior alveolar nerve and the intimate association of the roots of thirty one with the nerve

were intimately associated with the inferior alveolar canal. This information, which was not revealed on the OPG [Figure 1B-D], enabled the surgeon to employ the necessary high level of intrasurgical care and dissect the tooth with minimal trauma to the nerve.

The cyst was enucleated and fixed in 10% formalin. Histological examination identified it as a dentigerous cyst. There were no postoperative complications and on a recent follow-up visit, the patient did not exhibit any symptoms of neural damage such as anesthesia/paresthesia or tingling or burning sensation.

Case 2

A 23-year-old male patient reported with a complaint of mild continuous pain and swelling of the left cheek. The mild swelling had been first noticed by the patient 2 years back but it had been asymptomatic. Extraorally, a nontender, firm, diffuse swelling of the left malar region, causing mild facial asymmetry, was observed. Intraorally, no swelling was detected. The maxillary left third molar (28) was unerupted, the gingival, alveolar, and palatal mucosa appeared normal.

The OPG revealed a radiolucent lesion, with the impacted tooth displaced to the region of the inferior orbital rim [Figure 2A]. The patient was advised a CBCT scan [Figure 2B-E]. The CBCT image revealed the presence of a unilocular radiolucent lesion, measuring 24.3 mm × 26.6 mm × 32.5 mm in its largest dimension, occupying most of the left maxillary sinus. The lesion had well-defined sclerotic borders, except at the inferolateral wall of the sinus and the crestal region of twenty eight. The lesion caused slight expansion of the antrum and left lateral wall of the maxillary sinus. A well-defined radiodensity, morphologically resembling a tooth with open apices, was observed embedded in the lateral wall of the middle meatus.

During surgery, a vestibular flap was raised from twenty three to twenty seven and a 1-cm window was made in the anterolateral wall of the sinus. The cyst lining was lifted and the cyst was enucleated, and the impacted tooth was also removed. The cyst was diagnosed as a dentigerous cyst on histopathological examination. There were no postoperative complications. The patient had recovered well on a recent follow-up.

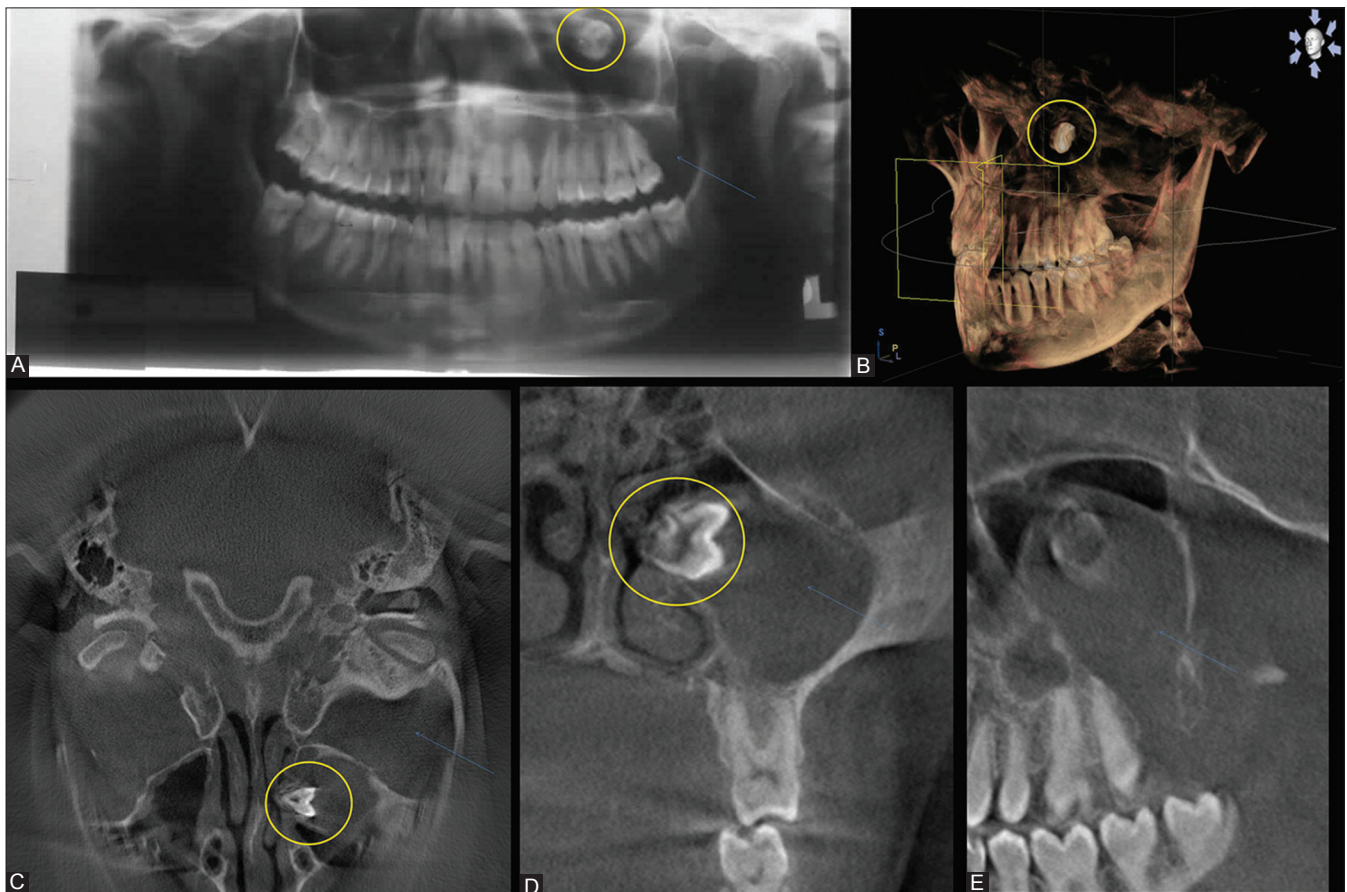


Figure 2 (A-E): Radiographic examination in case 2: (A) Orthopantomograph reveals 16 impacted in the region of the orbit, (B-E) Cone-beam computed tomography images with three-dimensional reconstruction (B) location of impacted tooth in the middle meatus on lateral wall of the nose (circle), and radiolucent lesion in the maxillary sinus (arrow)

Discussion

Dentigerous cysts associated with impacted teeth are frequently encountered pathologies and require surgical management. One of the frequent complications of surgical extraction of impacted mandibular teeth is injury to the inferior alveolar nerve due to pressure on the nerve during elevation of the tooth, inadvertent damage by the surgical drill, or bleeding into the canal following traumatic tooth removal. Depending on the severity of the injury, the damage may be transient or permanent. The common symptoms of nerve injury are a tingling sensation, numbness, or altered sensation.^[5,6]

The actual relationship of the tooth root to the inferior alveolar nerve canal in an OPG is often not clearly discernible due to differential magnification in the two-dimensional image of the curved jaws.^[7] In the current instance, the OPG was not useful for determining the proximity of the mandibular roots to the inferior alveolar canal. CBCT, however, assisted the localization through multiple views in various planes. Ghaemina, *et al.* reported that CBCT sections enable appreciation of the buccolingual position of the inferior alveolar canal, which allows the surgeon to determine the surgical approach least likely to cause pressure on the nerve during the procedure.^[8]

Dentigerous cysts of the maxilla are not uncommon and are more often associated with the maxillary canine than the maxillary molar.^[9] Maxillary impacted teeth have shown displacement to the sinus or orbit, and it has been stated that insufficient surgical planning could result in further displacement of the tooth into the infratemporal fossa.^[10,11] The OPG evaluation in our second case was misleading, which demonstrates the need to use advanced imaging aids on a routine basis during presurgical evaluation. CBCT scan not only provides an accurate picture of spatial relationships but also provides information on the margins and the interior of the lesion.^[12] In our patient, the CBCT images revealed that the impacted tooth was displaced and embedded in the middle meatus of the nose. The CBCT images also showed that the lining of the cyst was incomplete in the region of the floor of the sinus and the crestal region of 28. In the current instance, this was attributed to inflammation, but in the case of large long-standing lesions, it could also indicate malignant change. There are a few reports on the use of CBCT in odontogenic lesions, but the predominant opinion is that volumetric rendering of the images permits better understanding of localization, cortical destruction, and association with surrounding anatomic structures.^[13,14] CBCT has significant advantages over multidetector computational tomography or medical CT: (a) there is significantly less radiation exposure to the patient with CBCT; (b) CBCT uses a single rotation of the scanner around the fulcrum to capture images; (c) the patient can be

seated during the scanning procedure; and (d) the scanner is small enough – similar to the OPG machine – to be placed in a dental hospital or core dental facility. The main disadvantage of the CBCT images – apart from the problem of artifacts generated from the cone-beam effect, scanner artifact, patient movement, or undersampling – is the relatively poor tissue contrast, which makes identification of small calcified structures difficult.^[15]

Conclusion

There is an increasing demand for three-dimensional imaging in dentistry. The current series describes the significant contribution of CBCT in the planning and successful surgical management of dentigerous cysts and associated impacted teeth.

Acknowledgment

We thank Dr. N. R. Krishnaswamy and Dr. Anand for their valuable contribution.

References

1. Robb RA. The dynamic spatial reconstructor: An X-Ray video-fluoroscopic CT scanner for dynamic volume imaging of moving organs. *IEEE Trans Med Imaging* 1982;1:22-33.
2. Gupta R, Grasmuck M, Suess C, Bartling SH, Schmidt B, Stierstorfer K, *et al.* Ultra-high resolution flat-panel volume CT: Fundamental principles, design architecture, and system characterization. *Eur Radiol* 2006;16:1191-205.
3. Miracle AC, Mukherji SK. Conebeam CT of the head and neck, Part 2: Clinical applications. *AJNR Am J Neuroradiol* 2009;30:1285-92.
4. Neville BW, Damm DD, Allen CM, Bouquot JE. Odontogenic cysts and tumors. In: Neville BW, Damm DD, Allen CM, Bouquot JE, editors. *Oral and Maxillofacial Pathology*. 2nd ed. Philadelphia:WB Saunders; 2002. p. 589-642
5. Brann CR, Brickley MR, Shepherd JP. Factors influencing nerve damage during lower third molar surgery. *Br Dent J* 1999;186:514-6.
6. Bui CH, Seldin EB, Dodson TB. Types, frequencies, and risk factors for complications after third molar extraction. *J Oral Maxillofac Surg* 2003;61:1379-89
7. Angelopoulos C, Thomas SL, Hechler S, Parisis N, Hlavacek M. Comparison between digital panoramic radiography and cone-beam computed tomography for the identification of the mandibular canal as part of presurgical dental implant assessment. *J Oral Maxillofac Surg* 2008;66:2130-5.
8. Ghaemina H, Meijer GJ, Soehardi A, Borstlap WA, Mulder J, Vlijmen OJ, *et al.* The use of cone beam CT for the removal of wisdom teeth changes the surgical approach compared with panoramic radiography: A pilot study. *Int J Oral Maxillofac Surg* 2011;40:834-9.
9. Ramachandra P, Maligi P, Raghuvver H. A cumulative analysis of odontogenic cysts from major dental institutions of Bangalore city: A study of 252 cases. *J Oral Maxillofac Pathol* 2011;15:1-5.
10. Litvin M, Caprice D, Infranco L. Dentigerous cyst of the maxilla with impacted tooth displaced into orbital rim and floor. *Ear Nose Throat J* 2008;87:160-2.
11. Avitia S, Hamilton JS, Osborne RF. Dentigerous cyst presenting as orbital proptosis. *Ear Nose Throat J* 2007;86:23-4.

12. Araki M, Matsumoto K, Matsumoto N, Honda K, Ohki H, Komiyama K. Unusual radiographic appearance of ossifying fibroma in the left mandibular angle. *Dentomaxillofac Radiol* 2010;39:314-9.
13. Singer SR, Mupparapu M, Philipone E. Cone beam computed tomography findings in a case of plexiform ameloblastoma. *Quintessence Int* 2009;40:627-30.
14. Simon JH, Enciso R, Malfaz JM, Roges R, Bailey-Perry M, Patel A. Differential diagnosis of large periapical lesions using cone-beam computed tomography measurements and biopsy. *J Endod* 2006;32:833-7.
15. Boeddinghaus R, Whyte A. Current concepts in maxillofacial imaging. *Eur J Radiol* 2008;66:396-418.

Cite this article as: Vidya L, Ranganathan K, Praveen B, Gunaseelan R, Shanmugasundaram S. Cone-beam computed tomography in the management of dentigerous cyst of the jaws: A report of two cases. *Indian J Radiol Imaging* 2013;23:342-6.

Source of Support: Nil, **Conflict of Interest:** None declared.