



# Comparison between Freeze-dried and Ready-to-use AlloDerm in Alloplastic Breast Reconstruction

James C. Yuen, MD\*

Connie J. Yue, BA†

Stephen W. Erickson, PhD‡

Shannon Cooper, APN\*

Cristiano Boneti, MD§

Ronda Henry-Tillman, MD¶

Suzanne Klimberg, MD¶

**Background:** AlloDerm, a brand of acellular dermal matrix, is commonly used as an internal hammock to support the tissue expander or permanent implant in breast reconstruction. The aim of our study is to evaluate the complication rates associated with the freeze-dried (FD) AlloDerm and the ready-to-use (RTU) AlloDerm.

**Methods:** This institutional review board–approved retrospective study involved 103 patients who underwent immediate postmastectomy breast reconstructions from June 2011 to August 2012. The first 51 patients underwent 96 immediate breast reconstructions with FD AlloDerm. The subsequent 52 patients underwent 100 immediate breast reconstructions with RTU AlloDerm. Patient demographics, postoperative complication rates in study cohort, and complication rates stratified by body mass index (BMI) were analyzed.

**Results:** Multiple patient demographics in the 2 cohorts are closely matched ( $P > 0.05$ ). RTU AlloDerm was associated with higher rates of seroma and cellulitis compared with FD AlloDerm (22.0% vs 18.8%,  $P = 0.599$  and 21.0% vs 12.5%,  $P = 0.129$ , respectively). Significantly higher rates of seroma and cellulitis were found in patients with BMI  $\geq 30$  compared with BMI  $< 30$  (34.5% vs 9.2%,  $P < 0.001$  and 29.9% vs 6.4%,  $P < 0.001$ , respectively). A generalized linear mixed model shows that obesity and RTU AlloDerm are statistically significant predictors of cellulitis (adjusted odds ratio = 10.413,  $P < 0.001$  and adjusted odds ratio = 3.712,  $P = 0.011$ , respectively).

**Conclusions:** Our study demonstrates a clinically higher postoperative complication rate in immediate breast reconstruction with RTU AlloDerm compared with FD AlloDerm and highlights the unfavorable risk factor correlation with significant obesity. (*Plast Reconstr Surg Glob Open* 2014;2:e119; doi: 10.1097/GOX.0000000000000061; Published online 14 March 2014.)

**H**uman acellular dermal matrix (HADM) is commonly used during implant-based breast reconstruction. In the procedure, the HADM is sutured to the lower border of the pectoralis major muscle and the lower border of the HADM is sutured to the chest wall to create an internal hammock over

the tissue expander or permanent breast implant. There are many advantages to using HADM, such as providing support to the implant at the lower pole, allowing for higher volume expansions, and providing an extra protective layer between the skin flap and the implant. AlloDerm (LifeCell, Branchburg, N.J.)

From the \*Division of Plastic Surgery, University of Arkansas for Medical Sciences, Little Rock, Ark.; †College of Medicine, University of Arkansas for Medical Sciences, Little Rock, Ark.; ‡Department of Biostatistics, University of Arkansas for Medical Sciences, Little Rock, Ark.; §Division of Plastic Surgery, University of Alabama, Birmingham, Ala.; and ¶Division of Surgical Oncology, University of Arkansas for Medical Sciences, Little Rock, Ark.

Received for publication December 15, 2013; accepted January 13, 2014.

Copyright © 2014 The Authors. Published by Lippincott Williams & Wilkins on behalf of The American Society of Plastic Surgeons. *PRSGO* is a publication of the American Society of Plastic Surgeons. This is an open-access article distributed under the terms of the Creative Commons Attribution-NonCommercial-NoDerivatives 3.0 License, where it is permissible to download and share the work provided it is properly cited. The work cannot be changed in any way or used commercially.

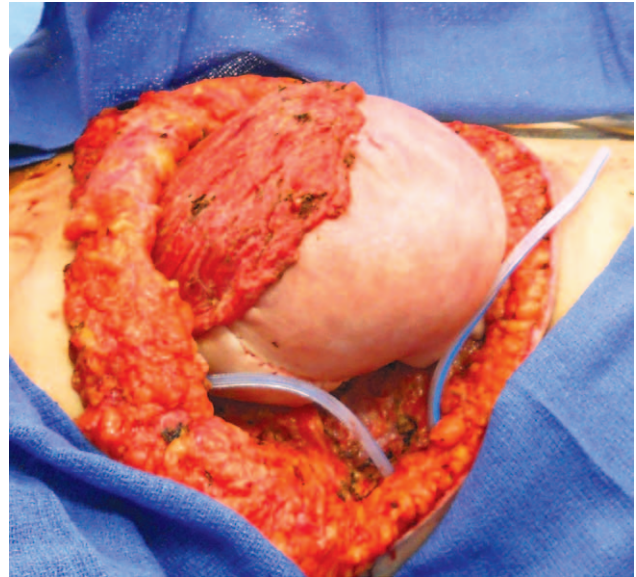
DOI: 10.1097/GOX.0000000000000061

is one of the first brands of HADM used in breast reconstruction. In 2012, LifeCell introduced a new version of AlloDerm, called ready-to-use (RTU), which eliminates the 30-minute intraoperative rehydration process. The processing method is different in the 2 HADMs: freeze-dried (FD) AlloDerm is stored in cryoprotective solution and freeze-dried, whereas RTU AlloDerm is stored in preservative solution and terminally sterilized with radiation. The objective of this study is to analyze the complication rates of the original cryopreserved (freeze-dried) AlloDerm vs the new RTU AlloDerm.

### PATIENTS AND METHODS

This is an institutional review board–approved retrospective study of 103 consecutive patients who underwent immediate single- or 2-stage implant-based breast reconstruction with the use of AlloDerm. All cases of breast reconstruction were performed by a single plastic surgeon at the University of Arkansas for Medical Sciences. The mastectomies were performed by 3 breast surgeons. When RTU AlloDerm was introduced, 52 consecutive patients underwent 100 breast reconstructions using this new HADM from February through August 2012. For a historical control, we reviewed the charts of 51 prior consecutive patients who underwent the insertion of FD AlloDerm in 96 breasts (June 2011 through January 2012). Patient demographics and complication rates, such as seroma formation, cellulitis, and explantation, were compared between these 2 groups. We used Fisher's exact test for the analysis of categorical variables and Wilcoxon rank sum test for numerical variables. In addition, a multivariable generalized linear mixed model was used to estimate the risk associated with obesity, preoperative chemotherapy, RTU AlloDerm, and FD AlloDerm as independent predictors of cellulitis formation.

For medium-sized breasts, the plastic surgeon typically inserted 2 pieces of the 8×12 cm AlloDerm, secured into position with 3-0 and 2-0 PDS sutures (Ethicon, New Brunswick, N.J.). Larger breasts received 10×20 cm piece sutures, also tailored to exact size needed to create the internal hammock over the lower one-third to one-half of the expander or breast implant (Fig. 1). One or two number 15 Blake drains (Ethicon, New Brunswick, N.J.) were employed per breast. Patients with preexisting bra cup size of D



**Fig. 1.** Intraoperative photograph of AlloDerm (FD) creating an internal hammock in a large-breasted patient after skin-sparing mastectomy.

or larger acquired 2 drains, as were patients who oozed more than usual. If only one drain was used, the drain traversed both the space above and below the AlloDerm. The drains stayed in place for 10 days. In addition to preoperative antibiotics, patients received oral antibiotics while drains were in place. Patients typically were discharged on postoperative day 1 or 2. Mean follow-up time for the FD and RTU cohorts was 436 and 293 days, respectively.

The first author performed all of the reconstructions personally, each in its entirety, with no change in surgical technique or operative environment during the period studied.

### RESULTS

The 2 study cohorts were appropriately matched with no significant difference in nearly all comorbidities, such as diabetes, hypertension, smoking history, radiation treatment, and chemotherapy status in Table 1 ( $P > 0.05$ ). There was a greater percentage of patients with body mass index (BMI)  $\geq 30$  in the FD group than in the RTU group (53% vs 37%), but the difference does not strongly suggest nonrandom selection between cohorts ( $P = 0.115$ ). The per-breast comparison of postoperative complication rates of seroma formation, cellulitis, and explantation in the study cohort is shown in Table 2. All explantations in the study were due to infection. The result shows higher rates of seroma and cellulitis in RTU group compared with FD group, but not at a statistically significant level (22% vs 18.8%,  $P = 0.599$  and 21% vs 12.5%,  $P = 0.129$ , respectively).

**Disclosure:** *The authors have no financial interest to declare in relation to the content of this article. The Article Processing Charge was paid for by the authors.*

**Table 1. Patient Characteristics by Type of AlloDerm**

Characteristic	Type of AlloDerm		P*
	Ready-to-use (n = 52)	Freeze-dried (n = 51)	
Mean age, y (SD)	51.2 (10.3)	50.5 (10.8)	0.754
Mean BMI (SD)	30.2 (9.9)	30.3 (6.4)	0.235
BMI			0.115
<30	33 (63%)	24 (47%)	
≥30	19 (37%)	27 (53%)	
Race			1.000
African American	9 (17%)	8 (16%)	
Asian	1 (2%)	1 (2%)	
White	42 (81%)	42 (82%)	
Diabetes	3 (6%)	4 (8%)	0.715
Hypertension	12 (23%)	20 (39%)	0.091
Family history of breast cancer	22 (42%)	23 (45%)	0.844
Preoperative bra size			0.883
A or B	10 (19%)	13 (25%)	
C or D	21 (40%)	19 (37%)	
DD or larger	13 (25%)	11 (22%)	
Not reported	8 (15%)	8 (16%)	
Chemotherapy			0.836
Prereconstruction only	10 (19%)	11 (22%)	
Postreconstruction only	7 (13%)	4 (8%)	
Pre- and postreconstruction	6 (12%)	5 (10%)	
None	29 (56%)	31 (61%)	
Prereconstruction radiation	2 (4%)	5 (10%)	0.269
Postreconstruction radiation with TE	5 (10%)	5 (10%)	1.000
Postreconstruction radiation second stage	0 (0%)	4 (8%)	0.057
Type of mastectomy			0.107
Bilateral TSSM	29 (75%)	28 (55%)	
Single breast TSSM	8 (15%)	13 (25%)	
Bilateral SSM	3 (6%)	5 (10%)	
Single breast SSM	1 (2%)	0 (0%)	
Bilateral mixed types	1 (2%)	5 (10%)	
Type of reconstruction			0.906
Bilateral single-staged	6 (12%)	6 (12%)	
Bilateral with TE	42 (81%)	39 (76%)	
Bilateral single-staged and TE	0 (0%)	1 (2%)	
Single breast with TE	4 (8%)	5 (10%)	

\*Based on Fisher’s exact test (categorical variables) and Wilcoxon rank sum test (numerical variables). SSM, skin-sparing mastectomy; TE, tissue expander; TSSM, total skin-sparing mastectomy.

In Table 3, we compared the per-breast rate of complications in patients with BMI ≥ 30 and BMI < 30. The result shows that obesity was significantly associated with all 3 complications. The rate of seroma was 9.2% in cohort with BMI < 30 vs 34.5% in BMI ≥ 30, *P* < 0.001; the rate of cellulitis was 6.4% vs 29.9%, *P* < 0.001; and the rate of explantation was 2.8% vs 11.5%, *P* = 0.02.

In Table 4, we analyzed per-breast rate of complication vs type of AlloDerm, stratified by obesity status. The higher rate of obese patients in the FD cohort (Table 1) obscured the relationship between

type of AlloDerm and complications. Table 4 shows a statistically significant relationship (42.9% RTU vs 21.2% FD, *P* = 0.035) between the cohorts in the development of cellulitis among obese patients. There was also a higher rate, although not statistically significant, among obese patients in the RTU group in both developing seroma and needing explantation compared with the FD group (45.7% vs 26.9% for seroma; 17.1% vs 7.7% for explantation).

The effect of preoperative chemotherapy and radiation treatment were summarized in Tables 5 and 6, respectively. As shown in Table 5, preoperative

**Table 2. Per-breast Rates of Complications by Type of AlloDerm**

Complication	Ready-to-use (n = 100)	Freeze-dried (n = 96)	P*
Seroma	22 (22.0%)	18 (18.8%)	0.599
Cellulitis	21 (21.0%)	12 (12.5%)	0.129
Explantation	6 (6.0%)	7 (7.3%)	0.780

\*Fisher’s exact test.

**Table 3. Per-breast Rates of Complications by BMI**

Complication	BMI < 30 (n = 109)	BMI ≥ 30 (n = 87)	P*
Seroma	10 (9.2%)	30 (34.5%)	<0.001
Cellulitis	7 (6.4%)	26 (29.9%)	<0.001
Explantation	3 (2.8%)	10 (11.5%)	<0.020

\*Fisher’s exact test.

**Table 4. Per-breast Rates of 3 Complications vs Type of AlloDerm Stratified by Obesity Status**

Complication	Among Patients with BMI ≥ 30			Among Patients with BMI < 30		
	Ready-to-use (n = 35)	Freeze-dried (n = 52)	P*	Ready-to-use (n = 65)	Freeze-dried (n = 44)	P*
Seroma	16 (45.7%)	14 (26.9%)	0.107	6 (9.2%)	4 (9.1%)	1.000
Cellulitis	15 (42.9%)	11 (21.2%)	0.035	6 (9.2%)	1 (2.3%)	0.238
Explantation	6 (17.1%)	4 (7.7%)	0.192	0 (0.0%)	3 (6.8%)	0.063

\*Fisher’s exact test.

chemotherapy was associated with higher rates of seroma, cellulitis, and explantation, but with  $P > 0.05$ . There were only 7 out of 103 patients who underwent preoperative radiation treatments, and due to this small sample size, the effect of preoperative radiation treatment on postoperative infections cannot be established here.

We fitted a generalized linear mixed model with patient-level random intercepts to simultaneously estimate the contributions of AlloDerm type, obesity, and preoperative chemotherapy to the per-breast risk of cellulitis. As shown in Table 6, the greatest predictor of cellulitis was obesity (adjusted odds ratio, AOR = 10.413,  $P < 0.001$ ), but RTU AlloDerm was also a substantial and statistically significant predictor (AOR = 3.712,  $P = 0.011$ ). There was a positive but not statistically significant association between preoperative chemotherapy and cellulitis (AOR = 1.781,  $P = 0.252$ ).

### DISCUSSION

To our knowledge [Medline database 1966–2013 (National Library of Medicine, Bethesda, Md.): key word searches included AlloDerm + cryopreserved + free-dried + sterile + ready-to-use], this is the second comparative study evaluating the complication rates between cryopreserved AlloDerm and its new ready-to-use version.<sup>1</sup> AlloDerm was first used in breast surgery in 2001 and its use in breast reconstruction was first published in 2005.<sup>2–4</sup> The original version of AlloDerm, cryopreserved AlloDerm, has been widely published. The newer version, ready-to-use, was introduced in 2011 and by default is not well published because of its relatively recent introduction. The manufacturer claims that this product was

designed to provide the same benefit as the original product. In a primate study, revascularization and cellular repopulation of implanted AlloDerm RTM *Ready To Use* has been demonstrated to be similar to AlloDerm RTM.<sup>5</sup> AlloDerm RTU, which undergoes a terminal sterilization process that includes electron beam irradiation, is sterile to a sterility assurance level of  $10^{-3}$ . RTU AlloDerm denotes more convenience during surgery by avoiding the timely rehydration process. Gabriel et al<sup>6</sup> in his initial experience outcome study in 160 breasts utilizing  $8 \times 16$  cm acellular dermal matrix (ADM) and low or moderate height tissue expander found the RTU AlloDerm to be safe and effective.

From their experience with the original version of AlloDerm, plastic surgeons have found this ADM to be relative safe from a tissue integration standpoint (Fig. 2). In a meta-analysis article, the authors found an infection rate of 5.3% and a seroma rate of 4.8% among 19 studies between 2005 and 2011 with 2037 HADM reconstructions. There was a slight increased tendency in complications compared to traditional submuscular tissue expander placement without HADM.<sup>7</sup> Isolated individual series do report a much higher complication rate.<sup>8–10</sup> Chun et al<sup>9</sup> compared 269 reconstructions using tissue expander or permanent implant with AlloDerm to 146 reconstructions without ADM. Both the seroma and the infection rate were higher with ADM (14.1% vs 2.7%,  $P = 0.0003$  and 8.9% vs 2.1%,  $P = 0.0328$ , respectively). Lanier et al<sup>10</sup> reported a 28.9% rate of infection and 15.4% rate of seroma in 52 patients in whom ADM (several brands including AlloDerm) was used vs 12.0% rate of infection and 6.7% rate of seroma in 75 patients in whom ADM was not used.

In this study, the infection rate with cryopreserved AlloDerm was 12.5% per breast, while the seroma rate was 18.8%. Our study reports a lower rate of infection and seroma compared with the study by Lanier et al.<sup>10</sup> However, with ready-to-use, the rate of seroma was 22.0% and the rate of infection was 21.0%, higher than with cryopreserved AlloDerm. Bivariate analysis of complications due to type of AlloDerm, however, is confounded by the higher rate of obesity in the FD cohort. Obesity has been shown

**Table 5. Per-breast Rates of Complications by Preoperative Chemotherapy Status**

Complication	No Preoperative Chemotherapy (n = 134)	Preoperative Chemotherapy (n = 62)	P*
Seroma	23 (17.2%)	17 (27.4%)	0.127
Cellulitis	20 (14.9%)	13 (21.0%)	0.310
Explantation	7 (5.2%)	6 (9.7%)	0.354

\*Fisher’s exact test.

**Table 6. Generalized Linear Mixed Model of Cellulitis**

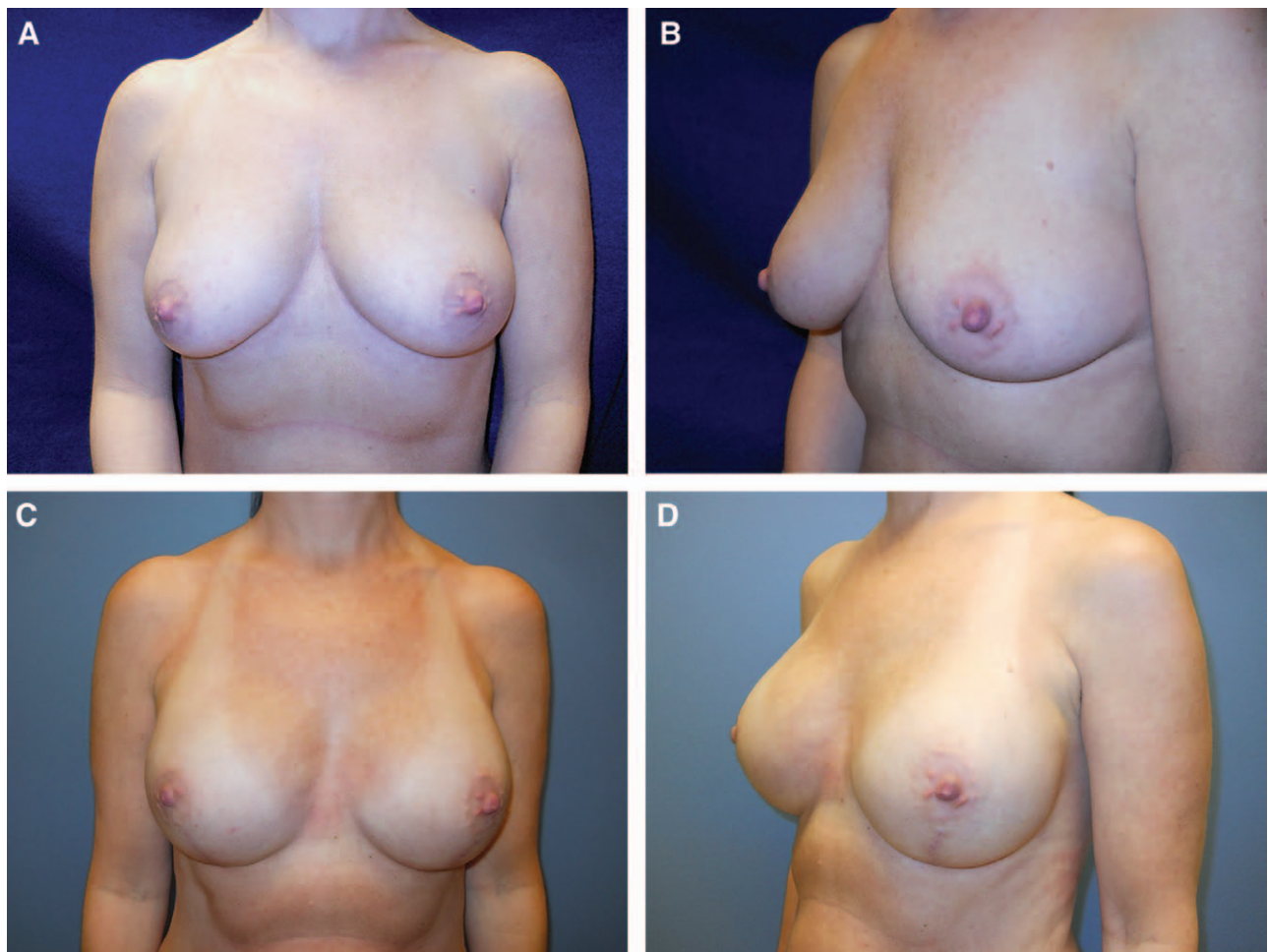
	Estimate	Standard Error	Z	P	AOR	95% CI
Intercept	-4.115	0.687	-5.992	<0.001		
Ready-to-use	1.312	0.518	2.531	0.011	3.712	1.344–10.252
BMI $\geq$ 30	2.343	0.568	4.129	<0.001	10.413	3.424–31.670
Preoperative chemotherapy	0.577	0.504	1.146	0.252	1.781	0.664–4.779

CI, confidence interval. AOR, adjusted odds ratio.

to significantly increase the rate of complications in implant-based breast reconstruction.<sup>11</sup> A generalized linear mixed model, which simultaneously computes the individual contributions of RTU, obesity, and preoperative chemotherapy to risk of cellulitis, shows a 3.7-fold increased odds of infection with RTU compared with FD AlloDerm (Table 6). Therefore, although the greatest predictor of cellulitis was obesity (AOR = 10.413,  $P < 0.001$ ), RTU was also a substantial and statistically significant predictor (AOR = 3.712,  $P = 0.011$ ). When controlling for obesity (Tables 4 and 6), RTU is significantly associated with higher risk of cellulitis.

There was a positive but not statistically significant association between preoperative chemotherapy and cellulitis (Table 6). Eliminating for the contribution of preoperative chemotherapy, the mean infection risk for nonobese patients increases from 1.6% with FD to 5.7% with RTU (relative risk = 3.5), while the mean infection risk for obese patients increases from 14.5% with FD to 38.7% with RTU (relative risk = 2.7).

To this date, the world's literature is devoid of randomized trials with the use of ADM in breast reconstruction. Hajifathalian et al<sup>12</sup> scrutinized the meta-analysis of 19 studies of Kim et al, stating that



**Fig. 2.** Before bilateral total skin-sparing mastectomy (A, B) and after bilateral immediate reconstruction with tissue expander and AlloDerm and subsequent exchange to silicone gel implant (6 mo postoperation) (C, D).

the authors used uncontrolled cohort studies in their analysis. There was a significant amount of heterogeneity among the studies; pooling of results was questioned. The pooled infection rate was a respectable 5.3%, but there is a wide variation in published outcome data. Comparatively, the infection rate in this study for the same AlloDerm employed (FD) was 12.5%. However, when looking at patients with BMI under 30 in the present study, the infection rate per breast was only 2.3% with FD AlloDerm. Therefore, by using FD AlloDerm for patients with BMI under 30, the complication rate is considered favorable (Table 4). In the same subpopulation (FD AlloDerm) with BMI over 30, the rate of infection increased significantly to 21.2%. For the RTU AlloDerm in BMI over 30, the cellulitis rate of 42.9% (15 in 35 breasts) is not acceptable. In obese patients, while the infection rate was high at 21.2% in FD, only 7.7% required explantation. With RTU in obese patients, the explantation went up to 17.1%. Because of a relatively small number of patients in this study, this *P* value was not statistically significant. Similarly, the overall rate of infection between FD (12.5%) and RTU (21.0%) in this study was not statistically significant.

What was statistically significant was the cellulitis rate between RTU and FD in the obese patient. When fitting a generalized linear mixed model with patient-level random intercepts to estimate the contribution of AlloDerm type, independent to other risk variables (Table 6), the overall higher cellulitis rate with RTU AlloDerm compared to FD AlloDerm was statistically significant. Based on these preliminary data, we are no longer using RTU AlloDerm in our institution.

Our results are opposite to that of Weichman et al.<sup>1</sup> Her group looked at 90 breast reconstructions using cryopreserved (“aseptic”) AlloDerm and 105 breasts with RTU. Their infection rate was 20% with FD and 8.5% with RTU. Again, the heterogeneity of patient population and surgical technique would explain for the disparity of outcome data. For example, over 80% of our mastectomy was total skin-sparing mastectomy, also known as nipple-sparing mastectomy. In the series by Weichman et al,<sup>1</sup> the nipple-areolar-sparing mastectomy percentage was 27.7% for FD AlloDerm and 49.2% for the RTU. Bilaterality was comparable in our study, which was over 65% of the mastectomy. The mean BMI of both of our cohorts was 30, signifying a more generalized obese population. The mean BMI for the study by Weichman et al<sup>1</sup> was 26.6 and 24.92 for their cohorts of freeze-dried (aseptic) and sterile (ready-to-use) AlloDerm, respectively.

All 3 parameters (total skin-sparing mastectomy, bilateral surgery, and obesity) in our cohorts are asso-

ciated with longer and/or more complicated surgery. Mastectomy through a relatively small incision with preservation of all of the breast skin (total skin-sparing mastectomy, also called nipple-areolar-sparing mastectomy) requires more operative time. More skin is also predisposed to postoperative ischemia. Furthermore, reconstruction through a small incision means less exposure and longer operative time. In summary, although we saw a higher rate of complications with RTU AlloDerm vs FD AlloDerm in a retrospective study of closely matched (except for obesity) cohorts, the authors believe that prospective, randomized, controlled trials are still needed to delineate the safety profile of these 2 types of ADM. When such level I data become available, the next step should look at the potential untoward side effects of radiation in the preparatory process for RTU AlloDerm.

## CONCLUSION

HADM has become popular in the field of breast reconstructions with tissue expanders or breast implants for its various benefits. Different types of HADM are designed to improve its quality and to facilitate its application. However, our study suggests a clinically higher infection rate in immediate breast reconstruction with the new version of AlloDerm, RTU, compared with the cryopreserved AlloDerm. This study should provide additional insight to the plastic surgeon when choosing between the 2 available types of AlloDerm to be employed in implant-based breast reconstruction. Furthermore, this study confirms a significantly higher postoperative complication rate associated with obesity. Our series should potentially challenge other centers to perform randomization in study design to confirm our retrospective study. However, in our center, based on these preliminary data and until further studies are established, we have resumed the use of AlloDerm strictly in its cryopreserved preparation.

**James C. Yuen, MD**

Division of Plastic Surgery  
University of Arkansas for Medical Sciences  
Slot 720, 4301 West Markham Street  
Little Rock, AR 72205  
E-mail: yuenjamesc@uams.edu

## REFERENCES

1. Weichman KE, Wilson SC, Saadeh PB, et al. Sterile “ready-to-use” AlloDerm decreases postoperative infectious complications in patients undergoing immediate implant-based breast reconstruction with acellular dermal matrix. *Plast Reconstr Surg*. 2013;132:725–736.
2. Duncan DI. Correction of implant rippling using allograft dermis. *Aesthet Surg J*. 2001;21:81–84.

3. Hochberg J, Margulies A, Yuen JC, et al. AlloDerm (acellular human dermis) in breast reconstruction with tissue expansion. *Plast Reconstr Surg*. 2005;116(Suppl 3):126–128.
4. Salzberg CA. Nonexpansive immediate breast reconstruction using human acellular tissue matrix graft (AlloDerm). *Ann Plast Surg*. 2006;57:1–5.
5. Gabriel A. *AlloDerm® RTM Ready To Use Clinical Case Series*. Branchburg, NJ: LifeCell Corporation; 2011.
6. Gabriel A, O’Shaughnessy K, Jacobson SR, et al. Immediate breast reconstruction following mastectomy using sterilized acellular dermal matrix: initial experience outcomes study. *Plast Reconstr Surg*. 2012;130(5 Suppl 1):34.
7. Kim JY, Davila AA, Persing S, et al. A meta-analysis of human acellular dermis and submuscular tissue expander breast reconstruction. *Plast Reconstr Surg*. 2012;129:28–41.
8. Seth AK, Persing S, Conner CM, et al. A comparative analysis of cryopreserved versus prehydrated human acellular dermal matrices in tissue expander breast reconstruction. *Ann Plast Surg*. 2013;70:632–635.
9. Chun YS, Verma K, Rosen H, et al. Implant-based breast reconstruction using acellular dermal matrix and the risk of postoperative complications. *Plast Reconstr Surg*. 2010;125:429–436.
10. Lanier ST, Wang ED, Chen JJ, et al. The effect of acellular dermal matrix use on complication rates in tissue expander/implant breast reconstruction. *Ann Plast Surg*. 2010;64:674–678.
11. Arver B, Isaksson K, Atterhem H, et al. Bilateral prophylactic mastectomy in Swedish women at high risk of breast cancer: a national survey. *Ann Surg*. 2011;253:1147–1154.
12. Hajifathalian K, Zacharias DG, Gonzalez-Gonzalez LA, et al. A meta-analysis of human acellular dermis and submuscular tissue expander breast reconstruction. *Plast Reconstr Surg*. 2012;130:896e; author reply 896e–898e.