

Usefulness and role of magnetic resonance imaging in a case of complete androgen insensitivity syndrome

Daniela Grasso, MD; Camela Borreggine, MD; Caterina Campanale, MD; Antonio Longo, MD; Gianpaolo Grilli, MD; and Luca Macarini, Prof. Dr.

Complete androgen insensitivity syndrome (CAIS) is an X-linked, recessive disorder caused by mutations of the androgen receptor (AR), in which genetic males (46,XY) show female external genitalia. Individuals with CAIS have mostly normal external genitalia, lack of Müllerian structures (Fallopian tubes, uterus, proximal portion of the vagina) and undescended testes (intra-abdominal, inguinal, or labial). Management and diagnosis of CAIS should be undertaken by a multidisciplinary team of experts in sexual development disorders. Gonadectomy represents a standard therapeutic choice to prevent testicular malignancy in the prepubertal period, with subsequent hormonal replacement therapy, or in late adolescence, after completion of pubertal development. Imaging examinations play a pivotal role in the diagnosis, assessment, and detection of the gonads before surgical treatments. Magnetic resonance imaging (MRI) is the gold standard to diagnose and locate the gonads, and to plan laparoscopic gonadectomy and gonadic surveillance, in particular in the increasingly large number of patients who decide to delay or ultimately not to undergo gonadectomy. We present a case of a 14-year-old female with primary amenorrhea.

Case report

A 14-year-old phenotypic female was referred to our hospital with primary amenorrhea and delayed pubertal development. She was 172 cm tall (above the 95th percentile) and weighed 88.5 kg (above the 95th percentile); her BMI was 29.9 kg/m² (growth above the genetic target and the normal female population). The patient, born at term

by spontaneous delivery, reported repeated episodes of narcolepsy and lipothymia during physical activities and a single episode of plausible vaginal bleeding at 10 years. A physical exam revealed Tanner stage B3P2, with little pubic and axillary hair. The pelvic exam demonstrated hypoplastic labia majora, a blind-ended vagina, and the absence of uterus and cervix. Laboratory tests showed typical hormonal changes for age, sex, and pubertal stage: high testosterone (26.3 ng/dl), DHEAS (205.9 µg/dl), and LH (121 mUI/ml), with low FSH (12 mUI/ml) and normal estradiol (16 pg/ml); the karyotype analysis was 46,XY.

A transabdominal ultrasonography exam of the pelvis, performed in another hospital, demonstrated the absence of the uterus and gonadal structures. MRI (Achieva®, Philips Medical System, Eindhoven, the Netherlands, 1.5 T) was performed with axial T1W, axial and sagittal T2W turbo spin echo HR (high resolution), and coronal STIR TSE and axial diffusion-weighted imaging (DWI) (b values: 0 and 1000 s/mm²) sequences. Conventional sequences demonstrated two homogeneous ovoid solid masses, hypointense on T1 and iso-hyperintense on T2, in the ingui-

Citation: Grasso D, Borreggine C, Campanale C, Longo A, Grilli G, Macarini L. Usefulness and role of magnetic resonance imaging in a case of complete androgen insensitivity syndrome. *Radiology Case Reports*. (Online) 2015;10(2):1119.

Copyright: © 2015 The Authors. This is an open-access article distributed under the terms of the Creative Commons Attribution-NonCommercial-NoDerivs 2.5 License, which permits reproduction and distribution, provided the original work is properly cited. Commercial use and derivative works are not permitted.

Drs. Grasso, Borreggine, and Macarini are in the Department of Diagnostic Imaging, and Drs. Campanale and Longo are in the Department of Pediatrics, all at the University of Foggia, Foggia, Italy. Dr. Grilli is in the Operative Unit of Radiodiagnosics at the Ospedali Riuniti, Foggia, Italy. Contact: Dr. Grasso at daniela.grasso@hotmail.it.

Competing Interests: The authors have declared that no competing interests exist.

DOI: 10.2484/rcr.v10i2.1119

Usefulness and role of MRI in a case of complete androgen insensitivity syndrome

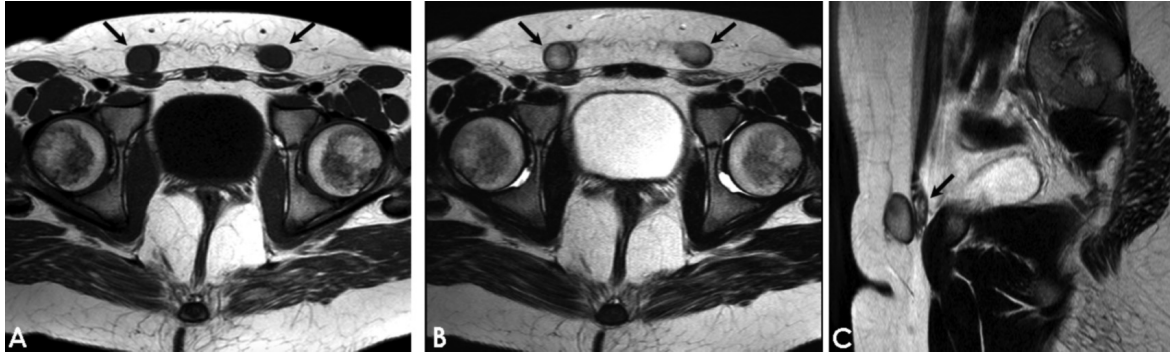


Fig. 1. (A-B) Axial T1- and T2-weighted images reveal bilateral solid nodular structures with homogeneous, mild hyperintensity in the anterior lower pelvic wall, adjacent to the external inguinal ring, compatible with testes (black arrow); (C) Sagittal T2 TSE image shows subtle, hyperintense, tubular structure similar to atrophic epididymides behind the gonads (black arrow).

nal canal close to the external ring, consistent with testes (Fig. 1, A-B). The right gonad measured 1.8x1.9x3.1 cm, and the left measured 1.7x2.4x2.9 cm. Tubular, subtle, T2-hyperintense structures, adjacent to the gonads, were seen; they appeared to be similar in size and shape to atrophic epididymides (Fig. 1C). There was no evidence of the uterus in the pelvis; sagittal T2W TSE demonstrated the presence of a short, blind-ended vagina between the bladder and (posteriorly) the rectum. In the recto-uterine pouch, there was free fluid collection (Fig. 2). DWI (b=1000) showed hyperintense extrapelvic gonads due to restricted diffusion, and low values on the ADC map (0.8 mm²/s on the right and 0.9 mm²/s on the left) (Fig. 3). The patient subsequently underwent hormonal replacement therapy and received psychosocial support.

Commonly included in the differential diagnosis are other causes of primary amenorrhea, in particular the Mayer-Rokitansky-Kuster-Hauser (MRKH) syndrome, characterized by Müllerian duct anomalies (congenital absence of the upper part of the vagina, uterine agenesis, or

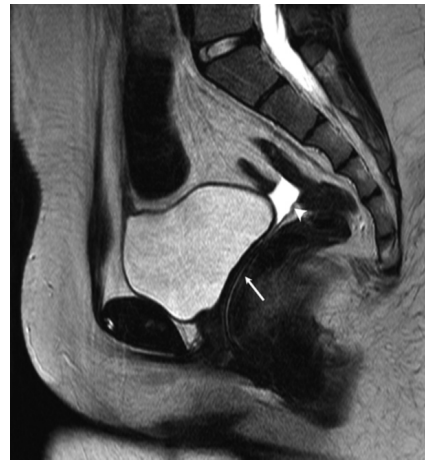

Fig. 2. Sagittal T2 TSE shows a blind-ended vagina (white arrow) between the bladder and the rectum posteriorly and the absence of Müllerian structures, such as the uterus; a fluid collection fills the Douglas pouch (white arrowhead).

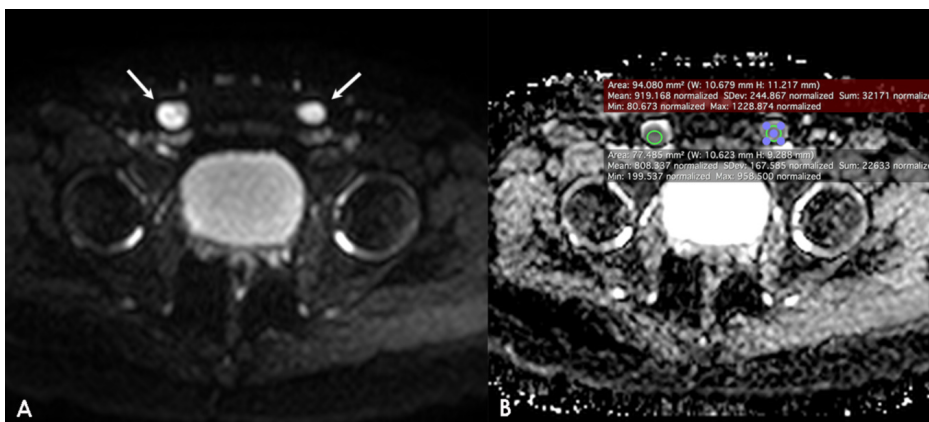


Fig. 3. DWI demonstrates hyperintense signal of the extrapelvic gonads; ADC map shows bilateral low signal intensity with 0.8 mm²/s on the right and 0.9 mm²/s on the left. No signs of malignant degeneration are detected.

the presence of a rudimentary uterus), a female karyotype, normal female external genitalia, normal breast development, and normal axillary and pubic hair. In Swyer syndrome (or 46,XY complete gonadal dysgenesis), the patient presents with normal female external genitalia, lack of breast development, and short stature with completely undeveloped (“streak”) gonads and the presence of Müllerian structures. Partial androgen insensitivity syndrome

Usefulness and role of MRI in a case of complete androgen insensitivity syndrome

(PAIS) differs from CAIS because of the presence of a microphallus or bifid scrotum with descended or undescended testes; in mild androgen insensitivity syndrome (MAIS), there is impaired spermatogenesis in the absence of male genital anomalies.

Discussion

CAIS is one of the most frequent disorders of sex development (DSD), described for the first time in 1953 by John Morris (1), an American gynecologist, and called "testicular feminization syndrome" (supposing that the testicles of these patients could produce estrogenic hormones with a feminizing effect on the body). CAIS is a rare, recessive X-linked disorder caused by mutations of the androgen receptor (AR), in which genetic males (46,XY) show phenotypic female external genitalia. The estimated prevalence is between 1/20,000 and 1/65,000 or 1-5/100,000 genetic males. More than 1,000 different AR mutations have been reported, in particular on the proximal long arm of the X chromosome (Xq11-12) (2). According to the typology of AR mutations, the sexual development disorder can be complete (CAIS), partial (PAIS), or mild (MAIS).

CAIS can be detected by chance during the first few days of life as a result of a discrepancy between the prenatal sex prediction and the phenotype at birth, or in the case of monolateral or bilateral inguinal hernia in a young girl containing testes, or in the case of a pelvic tumor in adults. Mostly, CAIS patients remain unrecognized until puberty, when they present with primary amenorrhea. Typically, patients with CAIS have a male karyotype and, despite normal testicular production of testosterone and dihydrotestosterone, do not develop male genitalia or male secondary sexual characteristics due to the androgen-receptor-impaired function. In these patients, the Wolffian duct (androgen dependent) does not develop into the epididymis, the vas deferens, and the seminal vesicles. Also, due to the production of Müllerian-inhibiting factor (MIF) by testicular Sertoli cells, the Müllerian duct does not develop fallopian tubes, uterus, and two-thirds of the proximal vagina. The testes can be located in the inguinal canal, intra-abdominal or labial; quite commonly, they are close to small cystic structures considered remnants of the Müllerian or Wolffian ducts. CAIS individuals typically show a female gender identity, breast development consistent with age (for the peripheral aromatization of testosterone), little pubic and axillary hair, primary amenorrhea, and a short, blind-ended vagina. Actually, only 35% of the patients demonstrate vaginal hypoplasia at physical examination and require vaginal dilatation or surgical reconstruction.

CAIS patients are usually taller than the normal female population but shorter than males and have a decreased bone mineral density before and after gonadectomy that can be corrected by estrogen replacement therapy and calcium or vitamin D supplements. CAIS women do not seem to have an increased risk of fractures (3).

Serum testosterone levels are within or above the normal range for males, and luteinizing hormone (LH) and estradiol concentrations are higher than in males but lower than

in females without CAIS, due to the androgen insensitivity and the lack of negative feedback on the hypothalamic-pituitary axis (4).

The intra-abdominal position of the testes is a well-known predisposing condition to gonadal tumors: prepubertal tumors are rare, with an incidence of 0.8% in CAIS patients due to normal and not dysgenetic testes, while in adults, the risk increases to 14% (5).

Traditional management of CAIS includes early gonadectomy in infancy and puberty induction with subsequent hormonal replacement therapy, or delayed gonadectomy in late adolescence after completion of puberty. The timing of gonadectomy is becoming controversial, and many women prefer to delay or deny the surgical procedure for a variety of reasons including psychological factors, surgical risk, preservation of fertility potential, and refusal of lifelong therapy (6).

Imaging examinations play a pivotal role in the diagnosis, assessment, and detection of the gonads before surgical treatments. Transabdominal ultrasonography (US) represents the first-line examination in evaluating the absence of Müllerian structures and the location of the testes, with a high sensitivity at the level of the inguinal canal.

MRI is the gold standard for diagnosis and localization of the gonads and for the evaluation of Müllerian abnormalities (accuracy, 100%) due to detailed anatomic information, superior tissue characterization, and multiplanar capability. In particular, MRI has higher sensitivity than US for the intra-abdominal and pelvic localization of the gonads.

MRI plays a key role in the planning of laparoscopic gonadectomy and seems to be useful in the gonadic surveillance ("watchful waiting") in the increasingly large number of patients who decide to delay or not undergo gonadectomy (7). Conventional axial and sagittal T1 and T2 sequences can demonstrate the absence of the uterus, the length of the vagina, and the presence and location of the testes; they also help to show gonadic malignant degeneration. Normal testes appear hypointense on T1 sequences and homogeneously hyperintense on T2 sequences; malignant degeneration can appear as low signal intensity foci with the disappearance of the testicular septa (8).

Individuals with CAIS have testes that differ from healthy males in terms of size, location, and signal intensity, and they are more similar to retained testes in terms of morphology and signal intensity due to atrophy and fibrosis. Several reports demonstrate the presence of immature and atrophic seminiferous tubules and fibrotic stroma when these testes undergo histologic examination (2, 9). Atrophy and fibrosis would be directly involved in the reduction of the testes' mean volume in CAIS patients (9.2cm³) compared to average testicular volume in a European man (18 cm³; range, 12-30 cm³). Common findings at MRI of testes in patients with CAIS are cystic structures, as benign paratesticular simple cysts or serous gonadal cysts, and Sertoli cell adenomas that can mimic malignant germ-cell tumors (10).

Usefulness and role of MRI in a case of complete androgen insensitivity syndrome

Furthermore, in our case, we perform an axial DWI (b values: 0 and 1000 s/mm²) sequence that shows a homogeneous hyperintense signal of the gonads, with a mean ADC value ranging from 0.8 to 0.9 mm²/s and with no evidence of focal areas of altered signal. Due to the lack of specificity of tumoral markers, it seems crucial to find screening and diagnostic tools for early identification of gonadic, malignant lesions. DWI, as a complementary sequence, could contribute to early detection of malignant lesions and could be helpful in monitoring retained testes in CAIS patients.

In conclusion, MRI is a useful technique to assess gonadectomy and to monitor patients who refuse or delay surgical treatment.

References

1. Morris JM. The syndrome of feminization in male pseudohermaphrodites. *Am J Obstet Gynecol*, 1953; 65:1192-121. [[PubMed](#)]
2. Brinkmann AO, Faber PW, van Rooij HC, Kuiper GG, Ris C, Klaassen P, van der Korput JA et al. The human androgen receptor: domain structure, genomic organization and regulation of expression. *Journal of Steroid Biochemistry* 1989; 34:1-6,307-310. [[PubMed](#)]
3. Danilovic DLS, Correa PHS, Costa EMF, Melo KFS, Mendonca BB, I. Arnhold JP. Height and bone mineral density in androgen insensitivity syndrome with mutations in the androgen receptor gene. *Osteoporosis International* 2007; 18: 3, 369-374. [[PubMed](#)]
4. Hughes IA, Davies JD, Bunchetal TI. Androgen insensitivity syndrome. *The Lancet*, 2012; 380;9851:1419-1428. [[PubMed](#)]
5. Deans R, Creighton SM, Liao LM, Conway GS. Timing of gonadectomy in adult women with complete androgen insensitivity syndrome (CAIS): patient preferences and clinical evidence. *Clinical Endocrinology* 2012; 76,894-898. [[PubMed](#)]
6. Nakhil RS, Hall-Craggs M, Freeman A, Kirkham A, Conway GS, Arora G, Woodhouse CR et al. Evaluation of retained testes in adolescent girls and women with complete androgen insensitivity syndrome. *Radiology* 2013; 268:153-160. [[PubMed](#)]
7. Nezzo M, De Visschere P, T'Sjoen G, Weyers S, Villeirs G. Role of imaging in the diagnosis and management of complete androgen insensitivity syndrome in adults. *Case Reports in Radiology* 2013. [[PubMed](#)]
8. Kanemoto K, Hayashi Y, Kojima Y, Maruyama T, Ito M, Kohri K. Accuracy of ultrasonography and magnetic resonance imaging in the diagnosis of non-palpable testis. *International Journal of Urology* 2005; 12:7,668-672. [[PubMed](#)]
9. Hannema SE, Scott IS, Rajpert-De Meyts E, Skakkebaek NE, Coleman N, Hughes IA. Testicular development in the complete androgen insensitivity syndrome. *J Pathol* 2006, 208:518-527. [[PubMed](#)]
10. Sohaib SA, Cook G, Koh D. Imaging studies for germ cell tumors. *Hematology/Oncology Clinics of North America* 2011; 25:3,487-502. [[PubMed](#)]