




Contents lists available at ScienceDirect

American Journal of Ophthalmology Case Reports

journal homepage: www.ajocasereports.com/

Reperfusion of retinal ischemia in retinal occlusive vasculitis with nicotinic acid and infliximab in Adamantiades-Behçet's disease

Ahmad Al-Moujahed^{a,1}, Doan Luong Hien^{a,b,1}, Amir Akhavanrezayat^a, Brandon Huy Pham^a,
 Than Trong Tuong Ngoc^{a,b}, Huy Luong Doan^c, Çigdem Yaşar^a, Sherin Lajevardi^a,
 Huy Vu Nguyen^a, Quan Dong Nguyen^{a,*}

^a Byers Eye Institute, Stanford University, Palo Alto, CA, USA

^b Pham Ngoc Thach University of Medicine, Saigon, Viet Nam

^c Kansas City University of Medicine and Biosciences, Kansas City, MO, USA

ARTICLE INFO

Keywords:

Retinal ischemia
 Vaso-occlusive retinal vasculitis
 Behçet's disease
 Nicotinic acid
 Niacin

ABSTRACT

Purpose: To describe a case of ischemic retinal vasculitis in Adamantiades-Behçet disease (ABD) that demonstrated significant resolution of retinal ischemia following treatment with nicotinic acid and infliximab. **Observations:** A 12-year-old male with a history of recurrent oral ulcers, fevers, and failure to thrive was admitted to the hospital with fever, oral and perirectal mucositis, and poor oral intake one month before presentation to uveitis clinic. He was suspected to have ABD and was treated with three doses of intravenous (IV) methylprednisolone (30 mg/kg/day) which led to improvement in his systemic symptoms. One week after admission, he complained of decreased vision in both eyes (OU), during which he was found to have anterior uveitis in OU and was referred to the Uveitis Clinic. Upon examination, his visual acuity was 20/80 in OU. Intraocular pressures were within normal limits. Anterior chamber evaluation revealed 0.5+ cells and 1.5+ flare in OU. Posterior examination revealed pale optic nerve, sclerosis and vascular sheathing of retinal arteries, and collateral vessels in OU. Fluorescein angiography (FA) showed optic disc leakage and widespread retinal ischemia in OU. The patient was diagnosed with retinal occlusive vasculitis associated with ABD. He was initially treated with infliximab (5 mg/kg), systemic methylprednisolone, and mycophenolate mofetil. Three months later, his BCVA improved to 20/70 OU with slight improvement of retinal ischemia on FA. Nicotinic acid was added to his treatment regimen. Due to logistic challenges, he did not receive infliximab treatment during the subsequent three months. However, three months after beginning nicotinic acid therapy, FA revealed significant improvement of his retinal ischemia OU. **Conclusion:** To our knowledge, the index report is the first to show that nicotinic acid may improve retinal ischemia in vaso-occlusive retinal vasculitis and be an integral part of the treatment regimen of this sight-threatening condition.

1. Introduction

Adamantiades-Behçet disease (ABD) is a rare systemic vasculitis that is characterized by recurrent attacks of oral aphthous ulcers, genital ulcers, and ocular lesions. Additional clinical features include dermatological, cardiovascular, gastrointestinal, and neurological manifestations.¹ Ocular involvement is one of the most disabling complications of ABD and occurs in approximately 70% of these patients.² Relapsing and remitting panuveitis and retinal vasculitis, which occur in 22% of eyes with ocular ABD(2), are typical ocular findings in ABD.³ Vaso-occlusive

retinal vasculitis is common in patients with ocular ABD and is associated with an increased risk of severe visual loss.⁴⁻⁶

Retinal vasculitis is an inflammation of the retinal vessels, which can be either idiopathic or secondary to infective, inflammatory, autoimmune, or neoplastic conditions. It can be classified into non-occlusive or occlusive subtypes.^{4,7} In the non-occlusive subtype, there is focal, segmental, or diffuse retinal perivascular proliferation of lymphoplasmacytic infiltrates that can lead to vision loss.⁷ In the vaso-occlusive subtype, on the other hand, retinal ischemia is the main cause of vision loss. This is a major concern in patients with retinal

* Corresponding author. Spencer Center for Vision Research, Byers Eye Institute at Stanford University, 2452 Watson Court, Suite 200, Palo Alto, CA 94303, USA.
 E-mail address: ndquan@stanford.edu (Q.D. Nguyen).

¹ The two authors (AA and DLH) have contributed equally in the preparation of this manuscript, and therefore both serve as co-first authors.

<https://doi.org/10.1016/j.ajoc.2021.101027>

Received 15 September 2020; Received in revised form 24 November 2020; Accepted 1 February 2021

Available online 5 February 2021

2451-9936/© 2021 The Authors.

Published by Elsevier Inc.

This is an open access article under the CC BY-NC-ND license

(<http://creativecommons.org/licenses/by-nc-nd/4.0/>).

vasculitis due to serious sight-threatening complications, such as macular ischemia, macular edema, neovascularization (NV) of the optic disc (NVD) or elsewhere in the retina (NVE) that can result in vitreous hemorrhage, fibrovascular proliferation leading to tractional retinal detachment, rubeosis iridis, and neovascular glaucoma(4, 5). Therefore, vaso-occlusive retinal vasculitis generally portends a poorer prognosis than the non-occlusive subtype(4). Despite the progress achieved in treating retinal vasculitis using corticosteroids and multiple classes of steroid-sparing agents, management of retinal ischemia remains challenging with no effective medical therapy thus far(4, 5).

We herein report a case of ischemic retinal vasculitis in a patient with ABD who demonstrated improvement of retinal ischemia following treatment with nicotinic acid and anti-inflammatory therapy.

2. Case report

A 12-year old Vietnamese-American boy with a history of recurrent aphthous and genital ulcers, fevers multiple times per year, and failure to thrive was admitted to the hospital with fever, oral and perirectal

mucositis, and poor oral intake one month prior to his presentation to the uveitis clinic. On admission, he was treated initially with amoxicillin, nystatin, and intravenous (IV) acyclovir; however, there was little clinical improvement. Several days later, due to concern of ABD, he was treated with 3 doses of IV methylprednisolone (30 mg/kg/day) and subsequently placed on oral prednisone, which improved his systemic symptoms of aphthous and genital ulcers as well as fever. His past ocular and family history was noncontributory. One week after admission, he complained of decreased vision in both eyes (OU) and was found to have anterior uveitis in OU. Therefore, he was treated with topical prednisolone by a pediatric ophthalmologist.

On examination, the best-corrected visual acuity (BCVA) was 20/80 in OU. The intraocular pressures (IOP) were normal at 17 mm Hg and 18 mm Hg in the right (OD) and left (OS) eyes, respectively. Pupillary examinations were within normal limits OU. Anterior chamber evaluation revealed 0.5+ anterior chamber cells and 1.5+ flare in OU. Posterior examination revealed pale optic nerve, sclerosis of the superior nasal retinal arteries, collateral vessels in peripheral retina (Fig. 1 A, B). Spectral domain optical coherence

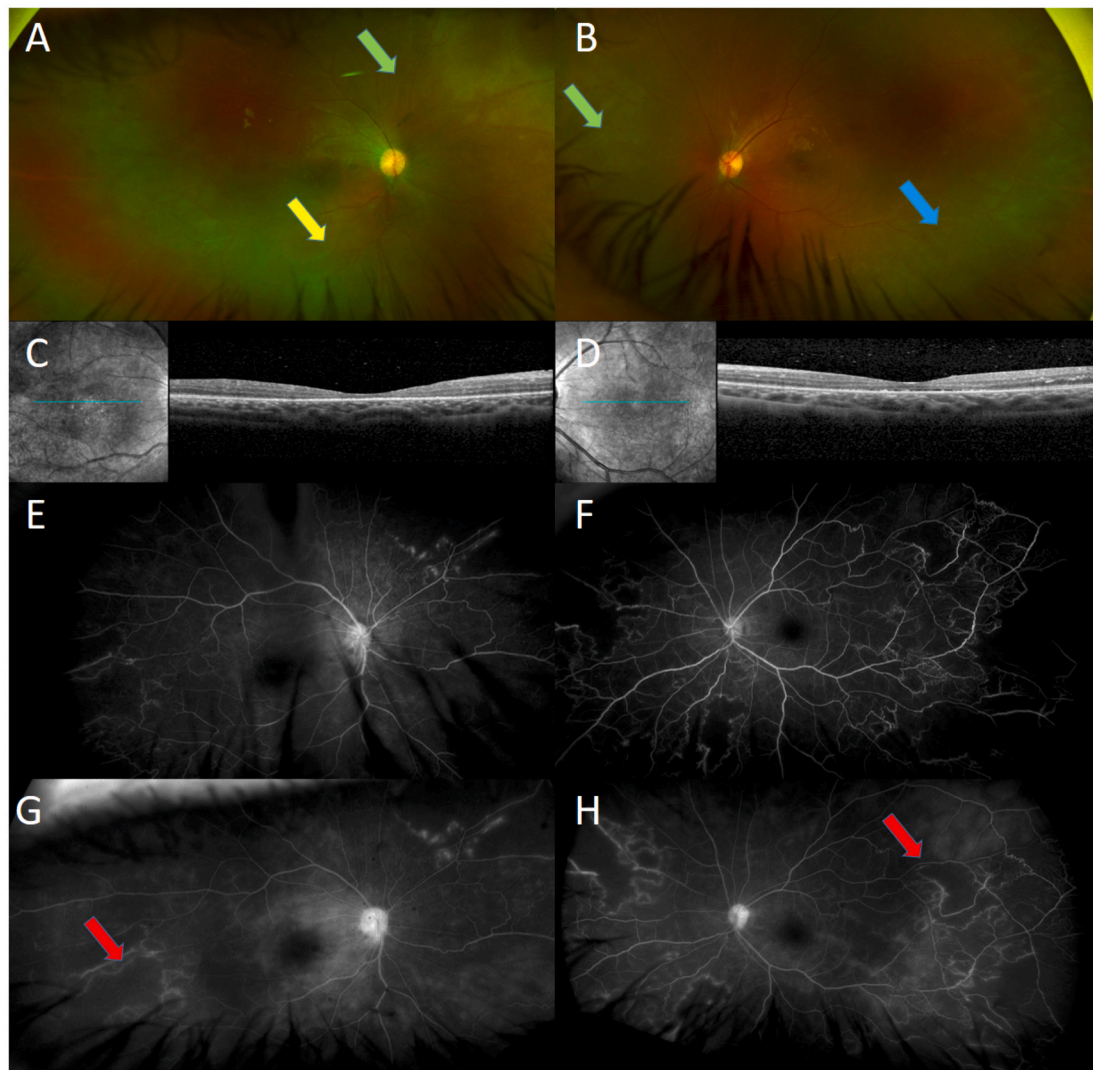


Fig. 1. Wide-field fundus photographs (A, B) at the time of presentation showing pale optic nerve, sclerosis of the superior nasal retinal arteries (green arrows), vascular sheathing of temporal inferior arteries arcade (yellow arrow), and collateral vessels in peripheral retina (blue arrow). SD-OCT horizontal cross-sections through the fovea (C) showing sub- and intra-retinal deposits, disruption of ellipsoid zone, and reduced foveal thickness in the right eye and (D) sub-retinal fluid with hyper reflective material in the left eye. Early and late fluorescein angiography of the right (E and G) and left (F and H) eyes showing optic disc and vascular leakage and widespread retinal ischemia (red arrows). (For interpretation of the references to colour in this figure legend, the reader is referred to the Web version of this article.)

tomography (SD-OCT) of the macula demonstrated sub- and intraretinal deposits, ellipsoid zone disruption, reduced foveal thickness in OD, and sub-retinal fluid with hyper-reflective material in OS (Fig. 1 C, D). Fluorescein angiography (FA) showed optic disc and vascular leakage (Fig. 1 G, H) and widespread retinal ischemia in OU (Fig. 1 E, F). Initial work-up showed slightly elevated white blood cell count ($19.3 \times 10^3/\mu\text{L}$) and erythrocyte sedimentation rate (ESR) (105 mm/hr; normal range: 0–10 mm/hr). The remainder of the laboratory evaluations and work-up, including complete chemistry panel, urinalysis, HLA-B51, antinuclear antibodies, anti-phospholipid antibody, C-reactive protein, QuantiFERON-Tuberculosis Gold test, herpes simplex virus (HSV) testing, syphilis antibody screen, MRI of the brain, and chest x-ray were negative, non-reactive, or within normal limits.

Based on the history, clinical course, signs, and the international criteria for ABD,⁸ the patient was diagnosed with retinal occlusive vasculitis associated with ABD. Because of the severity of the retinal condition, multi-drug treatment with IV infliximab (5 mg/kg) monthly and IV methylprednisolone (500 mg) for three consecutive days each month and mycophenolate mofetil was initiated. Three months later, the patient returned to the clinic with improvement in both ocular and systemic symptoms. His BCVA improved to 20/70 OU. Anterior chamber evaluation revealed no active inflammation (no cells and no flare). FA demonstrated stable retinal vasculitis and slight improvement of the optic disc leakage (Fig. 2 C, D) and of retinal ischemia in OU (Fig. 3 B, E, H). The dose of infliximab was increased from 5 mg/kg to 7.5 mg/kg monthly and the frequency of methylprednisolone infusions was

decreased from 3 to 2 days each month to minimize the risk of steroid-associated adverse effects. Furthermore, given the significant retinal ischemia, the patient was started on oral nicotinic acid 250 mg 3 times per day. Due to logistic challenges, he did not receive infliximab treatment during the subsequent three months. On examination three months later, his BCVA had improved to 20/60 in OD and slightly decreased to 20/100 in OS. FA demonstrated slight decrease in optic disc leakage, stable perivascular leakage (Fig. 2 E, F), and significant improvement in retinal ischemia in OU (Fig. 3 C, F, I). Due to this successful clinical response, the patient continues therapy with IV infliximab (7.5 mg/kg), IV methylprednisolone, nicotinic acid, and mycophenolate mofetil.

3. Discussion

3.1. Generating a diagnosis

We have presented a case of a 12-year old male with retinal occlusive vasculitis associated with ABD. According to the International Criteria for Behçet's Disease (ICBD),⁸ ocular lesions including anterior uveitis, posterior uveitis, and retinal vasculitis, oral aphthosis, and genital aphthosis are each assigned 2 points, while skin lesions, central nervous system involvement, and vascular manifestations are each assigned 1 point. A score of at least 4 is consistent with ABD. Our patient had ocular lesions and genital aphthosis and therefore had a score of 4 according to the ICBD. His oral aphthosis recurred only twice per year (at least 3

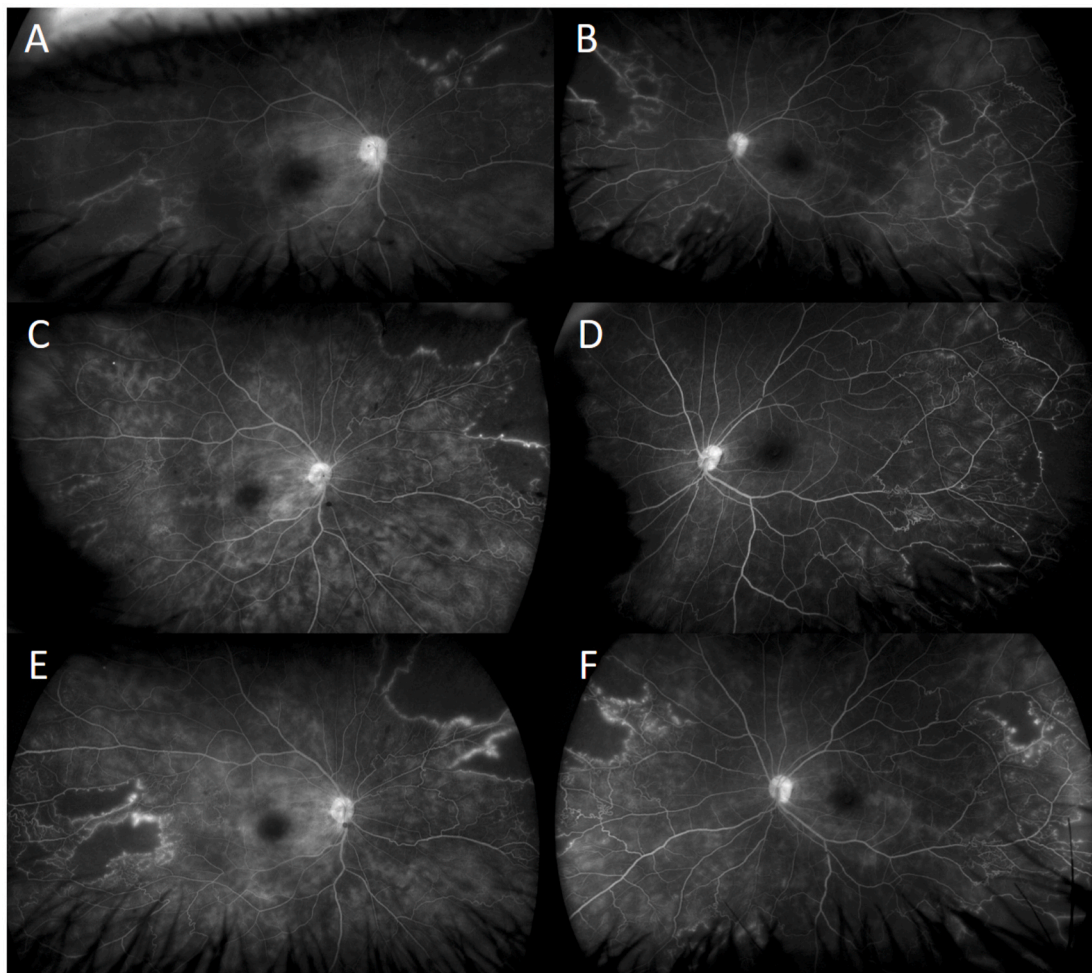


Fig. 2. Late phase of fluorescein angiography. At presentation (A and B); 3 months after starting treatment with infliximab and systemic steroids showing mild improvement of the optic disc and stable vascular leakage (C and D); and 3 months after starting treatment with nicotinic acid (without infliximab) showing stable optic disc and stable peri-vascular leakage (E and F).

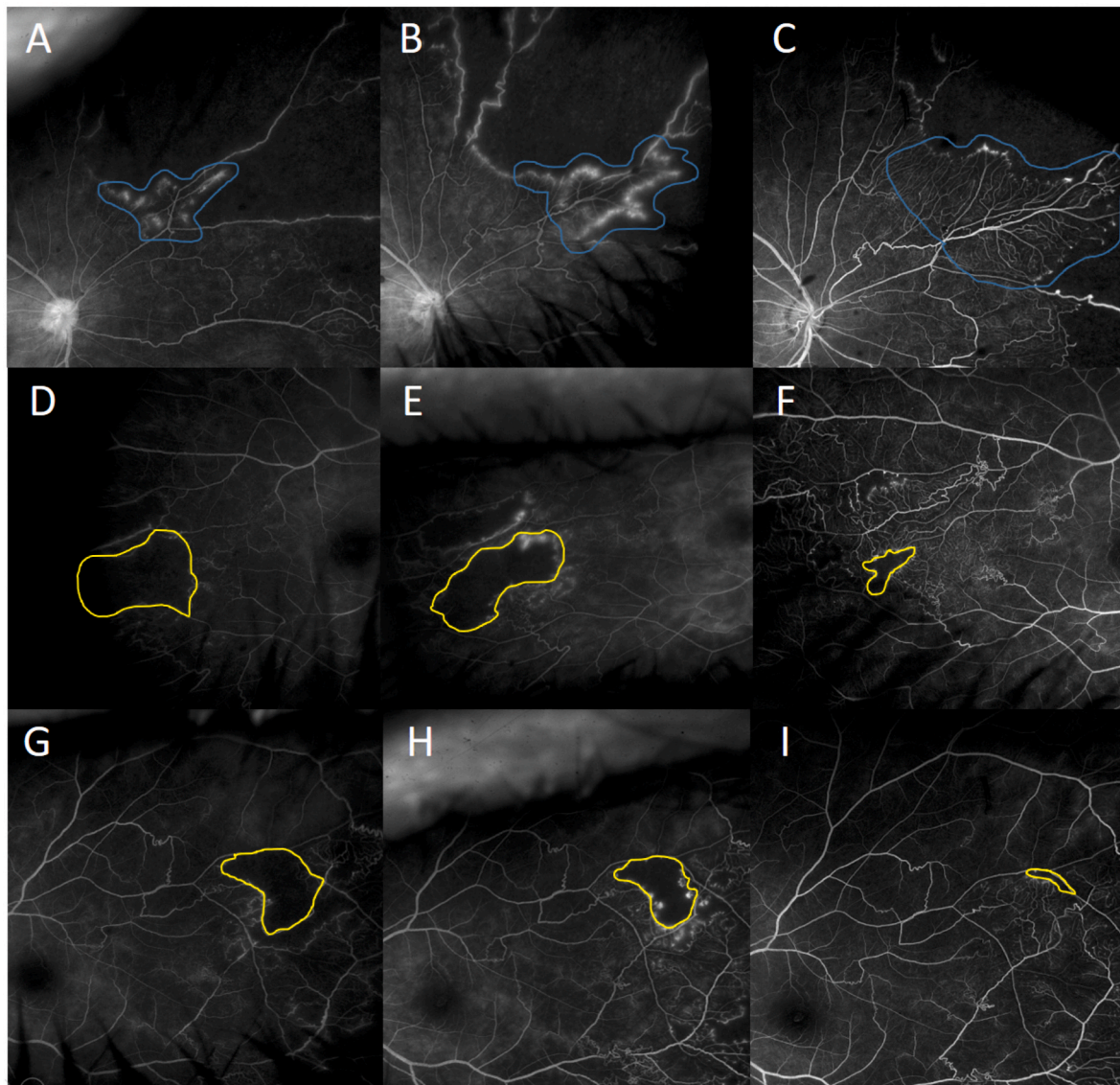


Fig. 3. Venous phases fundus angiography of the nasal retina (**first row**) and temporal retina (**second row**) of the right eye, and nasal retina (**third row**) of the left eye. At presentation (**A**, **D**, and **G**) showing widespread retinal ischemia; 3 months after starting treatment with infliximab and systemic steroids showing slight increase in the perfused area (blue outlines in **B**) and slight decrease of non-perfused area (yellow outlines in **E** and **H**); 3 months after starting treatment with nicotinic acid (without infliximab) showing significant increase in perfused area (blue outlines in **C**) and significant decrease in non-perfused area (yellow outlines in **F** and **I**). (For interpretation of the references to colour in this figure legend, the reader is referred to the Web version of this article.)

recurrences per year are needed for 2 points).

The differential diagnosis for occlusive retinal vasculitis includes systemic vasculitis and connective tissue diseases such as ABD, multiple sclerosis, granulomatosis with polyangiitis, and systemic lupus erythematosus, among others(4). There are also many infectious etiologies that can lead to occlusive vasculitis, including tuberculosis, herpes, and syphilis. In this index case, there were no retinochoroidal lesions, systemic manifestations, or abnormalities in blood evaluations to suggest a systemic or infectious etiology. Another possibility is Eales disease, which is a bilateral idiopathic obliterative vasculopathy that usually involves the peripheral retina of young male adults; however, there was no evidence of vitreous hemorrhage or peripheral neovascularization in our patient. Given the exclusion of other possible etiologies of retinal vasculitis, this index patient was diagnosed with retinal occlusive vasculitis associated with ABD.

3.2. Current treatments for retinal vasculitis and retinal ischemia associated with ABD

A combination of azathioprine, cyclosporine-A, and systemic corticosteroids were originally suggested as the initial choice for the treatment of ocular involvement in ABD, especially in posterior segment disease, according to the European League Against Rheumatism (EULAR) recommendations.⁹ More recently, tumor necrosis factor-alpha (TNF- α) inhibitors, such as infliximab and adalimumab, have been recommended as first-line therapy with systemic corticosteroids to manage initial or recurrent episodes of acute sight-threatening uveitis.⁸⁻¹⁴ Other promising therapies, including tocilizumab,^{15,16} golimumab,¹⁷ anakinra,¹⁸ canakinumab,¹⁹ and rituximab,²⁰ have demonstrated efficacy in small case reports. Other therapies, however, such as secukizumab (SHIELD study),²¹ gevokizumab (EYEGUARD B study),²² ustekizumab (STELABEC study),²³ and etanercept²⁴ have shown insufficient evidence for efficacy are not currently employed in the management of uveitis in ABD.

Given the severity of the disease in our patient and his relatively young age, infliximab at the doses of 5 mg/kg and intravenous steroid monthly were initiated. Infliximab can be escalated to 7.5, 10, or 20 mg/kg²⁵⁻²⁷ every 4-8 weeks or tapered based on the clinical response. In addition, mycophenolate mofetil was added to his therapy to provide long-term immunosuppression after infliximab had been weaned. After 3 months of treatment, retinal vasculitis was stable and slight reperfusion of retinal ischemia in OU was observed (Fig. 2 C, D, E). Therefore, to provide better control of retinal vasculitis and hasten reperfusion of retinal ischemia, the dose of infliximab was increased to 7.5 mg/kg and nicotinic acid was added to the treatment regimen.

3.3. What is nicotinic acid and why did we begin this treatment?

Nicotinic acid (niacin, vitamin B3) is an established treatment for dyslipidemia and was the first monotherapy to significantly reduce cardiovascular mortality.^{28,29} It increases levels of high-density lipoprotein cholesterol (HDL-C) and lowers levels of low-density lipoprotein cholesterol (LDL-C), non-HDL-C, and triglycerides.^{30,31} Nicotinic acid induces flushing due to cutaneous capillaries vasodilation that results from its concomitant activation of its receptor in dermal Langerhans cells, leading to increased production of prostaglandins, including prostaglandin D2 (PGD2) and prostaglandin E2 (PGE2).³¹ It also dilates other blood vessels, including capillaries, by relaxing pericytes. In fact, therapeutic doses of nicotinic acid (500 mg three times daily) have been shown to cause vasodilatation of retinal arterioles,³² dilate choroidal vessels by 39% for 90 minutes, and increase the relative choroidal blood velocity in age-related macular degeneration (AMD) patients.³³

Retinal ischemia can be seen in many entities, such as retinal vein occlusion (RVO), diabetic retinopathy (DR), retinal artery occlusion (RAO), and retinal occlusive vasculitis. The pathogenesis of ischemia in retinal vasculitis is not clear, but can be either thrombotic or obliterative secondary to the infiltration of inflammatory cells. Histologically, vascular changes in uveitis are characterized by perivascular infiltration of lymphocytes resulting in perivasculitis, rather than a true vasculitis of the vessel wall.³⁴⁻³⁶ Thrombotic vascular changes can occur due to local endothelial injury or increased prothrombin activity, as observed in ABD.³⁷

The retina has a uniquely high metabolic demand for oxygen that is normally met by a highly efficient vascular supply. Retinal vascular obstruction leads to ischemia that promotes the production of vascular endothelial growth factor (VEGF), which increases vascular permeability and can lead to macular edema and NV.³⁸ Therefore, the severity of retinal ischemia can be assessed either directly by observing the area of ischemia by FA and OCT angiography (OCTA), or indirectly by observing the progression of NV and cystoid macular edema (CME). However, indirect observation can be inaccurate as it reflects only the oxygen requirements of the retina. Indeed, oxygen therapy and nicotinic acid decrease retinal oxygen requirements by increasing the blood oxygen concentration and increasing retinal perfusion. These therapies have been shown to be able to resolve CME.³⁹⁻⁴² However, the recurrence after treatment cessation suggests that retinal ischemia is not fully reversed and that VEGF production is still increased. Unfortunately, these studies offer no serial FA or OCTA to evaluate the ischemic retinal area over time.

Unlike retinal ischemia caused by vasculitis, the loss of pericytes in diabetic retinopathy leads to leukocyte adhesion to retinal blood vessel walls and induces endothelial cell death. Pericyte loss and vascular closure lead to ischemia.^{43,44} The loss of pericytes is permanent with no known treatment to restore them in DR. In RVO, pericytes and endothelial cells are also damaged.⁴⁵ In addition to increased retinal interstitial fluid and protein increases the interstitial oncotic pressure through Starling's law, perpetuating tissue edema.⁴⁶ Such loss of blood flow decreases oxygen supply to pericytes and endothelial cells, and ultimately leads to permanent loss of retinal capillaries. Blood flow cannot be reestablished until collateral vessels develop. However, the

majority of collaterals develop at least 6 months after disease onset,⁴⁷ though some develop within 6 months.^{48,49} In retinal occlusive vasculitis, however, there is usually acute obstruction without permanent damage to pericytes and endothelial cells, at least in some areas of the retina. In this case, the cause of the obstruction can be treated with anti-inflammatory therapy. In transitional areas where capillaries remain intact, but not actively perfused, reperfusion can be reestablished after the resolution of vasculitis. In our patient, the initial treatment with infliximab and IV steroids for 3 months led to stabilization of vasculitis and likely slight reperfusion with improvement of retinal ischemia (Fig. 3 B,E,H). Subsequently, the addition of nicotinic acid likely had synergistic effects leading to significant reperfusion of the capillaries and improvement of retinal ischemia, as evident by FA, though the patient did not receive infliximab in the second 3-month period while on nicotinic acid. Although the half-life of infliximab is 10 days and its effects may persist for up to 2 months,⁵⁰ we suspect that this significant improvement of retinal ischemia is due, at least in part, to nicotinic acid and its possible role in "re-inflating" the occluded capillaries. Another explanation for the formation of new capillaries (Fig. 3 C,F,I) aside from re-inflating occluded capillaries is re-activating embryonic angiogenesis, though this is not observed even in retinopathy of prematurity. We observed new collateral capillaries after 3 months of treatment with nicotinic acid, an interesting finding that could also explain the improvement of ischemia. Further studies are needed to confirm whether nicotinic acid can induce collateral vessel formation.

Although it remains unclear whether infliximab and methylprednisolone alone, or their combination with nicotinic acid, could have contributed to this significant improvement of retinal ischemia, there is very limited evidence that infliximab and methylprednisolone by themselves can improve ischemia. Infliximab has not been shown, to our knowledge, to improve retinal ischemia, except for one report in which it was used at the appropriate dose and for an extended period of time.⁵¹ On the other hand, while intravitreal steroids may transiently reverse retinal ischemia in very limited cases of certain conditions,⁵² systemic steroids, to our knowledge, have not been reported to improve retinal ischemia. Additional studies are needed to further evaluate the effects of combining nicotinic acid with anti-inflammatory medications to treat ischemia from occlusive retinal vasculitis.

4. Conclusion

Our report indicates that anti-inflammatory therapies with the addition of nicotinic acid as an adjuvant may improve retinal ischemia in vaso-occlusive retinal vasculitis and can be an integral part of the treatment regimen of this sight-threatening condition.

Patient consent

Verbal and written consents have been obtained from the patient.

Funding

Research to Prevent Blindness Departmental Challenge Award, National Eye Institute of the National Institutes of Health P30 Grant (EY026877), and an unrestricted educational grant from the Ocular Imaging Research and Reading Center (OIRRC) have been awarded to the Byers Eye Institute at Stanford University.

Authorship

All authors attest that they met the current ICMJE criteria.

Declaration of competing interest

The authors declare that there are no conflicts of interest related to this article.

References

- Greco A, De Virgilio A, Ralli M, et al. Behçet's disease: new insights into pathophysiology, clinical features and treatment options. *Autoimmun Rev*. 2018;17(6):567–575.
- Kaçmaz RO, Kempen JH, Newcomb C, et al. Ocular inflammation in Behçet disease: incidence of ocular complications and of loss of visual acuity. *Am J Ophthalmol*. 2008;146(6):828–836.
- Ozyazgan Y, Ucar D, Hatemi G, Yazici Y. Ocular involvement of Behçet's syndrome: a comprehensive review. *Clin Rev Allergy Immunol*. 2015;49(3):298–306.
- Talat L, Lightman S, Tomkins-Netzer O. Ischemic retinal vasculitis and its management. *Journal of ophthalmology*. 2014;2014.
- El-Asrar AMA, Herbort CP, Tabbara KF. Differential diagnosis of retinal vasculitis. *Middle East Afr J Ophthalmol*. 2009;16(4):202.
- Palmer H, Stanford M, Sanders M, Graham E. Visual outcome of patients with idiopathic ischaemic and non-ischaemic retinal vasculitis. *Eye*. 1996;10(3):343–348.
- Walton RC, Ashmore ED. Retinal vasculitis. *Curr Opin Ophthalmol*. 2003;14(6):413–419.
- Davatchi F, Assaad-Khalil S, Calamia K, et al. The International Criteria for Behçet's Disease (ICBD): a collaborative study of 27 countries on the sensitivity and specificity of the new criteria. *J Eur Acad Dermatol Venereol*. 2014;28(3):338–347.
- 2018 Hatemi G, Christensen R, Bang D, et al. Update of the EULAR recommendations for the management of Behçet's syndrome. 2018;77(6):808–818.
- Keino H, Okada AA, Watanabe T, Nakayama M, Nakamura T. Efficacy of infliximab for early remission induction in refractory uveoretinitis associated with Behçet disease: a 2-year follow-up study. *Ocul Immunol Inflamm*. 2017;25(1):46–51.
- Sfikakis PP, Arida A, Ladas DS, Markomichelakis N. Induction of ocular Behçet's disease remission after short-term treatment with infliximab: a case series of 11 patients with a follow-up from 4 to 16 years. *Clin Exp Rheumatol*. 2019;37(121):S137–S141.
- Hassan M, Karkhur S, Bae JH, et al. New therapies in development for the management of non-infectious uveitis: a review. *Clin Exp Ophthalmol*. 2019;47(3):396–417.
- Suhler EB, Lowder CY, Goldstein DA, et al. Adalimumab therapy for refractory uveitis: results of a multicentre, open-label, prospective trial. *Br J Ophthalmol*. 2013;97(4):481–486.
- Mohammadi M, Shahram F, Shams H, Akhlaghi M, Ashofteh F, Davatchi F. High-dose intravenous steroid pulse therapy in ocular involvement of Behçet's disease: a pilot double-blind controlled study. *International journal of rheumatic diseases*. 2017;20(9):1269–1276.
- Atienza-Mateo B, Calvo-Río V, Beltrán E, et al. Anti-interleukin 6 receptor tocilizumab in refractory uveitis associated with Behçet's disease: multicentre retrospective study. *Rheumatology*. 2018;57(5):856–864.
- Alokaily F, Al Saati A, Jawad A. Successful treatment of Behçet's uveitis with Tocilizumab. *Saudi Journal of Ophthalmology*. 2017;31(1):42–44.
- Santos-Gómez M, Calvo-Río V, Blanco R, et al. The effect of biologic therapy different from infliximab or adalimumab in patients with refractory uveitis due to Behçet's disease: results of a multicentre open-label study. *Clin Exp Rheumatol*. 2016;34(6 Suppl 102):S34–S40.
- Cantarini L, Vitale A, Scalini P, et al. Anakinra treatment in drug-resistant Behçet's disease: a case series. *Clin Rheumatol*. 2015;34(7):1293–1301.
- Ugurlu S, Ucar D, Seyahi E, Hatemi G, Yurdakul S. Canakinumab in a patient with juvenile Behçet's syndrome with refractory eye disease. *Ann Rheum Dis*. 2012;71(9):1589–1591.
- Sadreddini S, Noshad H, Molaefard M, Noshad R. Treatment of retinal vasculitis in Behçet's disease with rituximab. *Mod Rheumatol*. 2008;18(3):306.
- Dick AD, Tugal-Tutkun I, Foster S, et al. Secukinumab in the treatment of noninfectious uveitis: results of three randomized, controlled clinical trials. *Ophthalmology*. 2013;120(4):777–787.
- Tugal-Tutkun I, Pavesio C, De Cordoue A, Bernard-Poenuro O, Gül A. Use of gevokizumab in patients with Behçet's disease uveitis: an international, randomized, double-masked, placebo-controlled study and open-label extension study. *Ocul Immunol Inflamm*. 2018;26(7):1023–1033.
- Pepple KL, Lin P. Targeting interleukin-23 in the treatment of noninfectious uveitis. *Ophthalmology*. 2018;125(12):1977–1983.
- Sfikakis P. Behçet's disease: a new target for anti-tumour necrosis factor treatment. *Ann Rheum Dis*. 2002;61(suppl 2):ii51–i53.
- Rajaraman RT, Kimura Y, Li S, Haines K, Chu DS. Retrospective case review of pediatric patients with uveitis treated with infliximab. *Ophthalmology*. 2006;113(2):308–314.
- Kahn P, Weiss M, Imundo LF, Levy DM. Favorable response to high-dose infliximab for refractory childhood uveitis. *Ophthalmology*. 2006;113(5):860–864. e2.
- Sukumaran S, Marzan K, Shaham B, Reiff A. High dose infliximab in the treatment of refractory uveitis: does dose matter? *ISRN rheumatology*. 2012;2012.
- Group CDPR. Clofibrate and niacin in coronary heart disease. *J Am Med Assoc*. 1975;231:360–381.
- Canner PL, Berge KG, Wenger NK, et al. Fifteen year mortality in Coronary Drug Project patients: long-term benefit with niacin. *J Am Coll Cardiol*. 1986;8(6):1245–1255.
- Gille A, Bodor ET, Ahmed K, Offermanns S. Nicotinic acid: pharmacological effects and mechanisms of action. *Annu Rev Pharmacol Toxicol*. 2008;48:79–106.
- Kamanna V, Ganji S, Kashyap M. The mechanism and mitigation of niacin-induced flushing. *Int J Clin Pract*. 2009;63(9):1369–1377.
- Barakat M, Metelitsina T, DuPont J, Grunwald J. Effect of niacin on retinal vascular diameter in patients with age-related macular degeneration. *Curr Eye Res*. 2006;31(7-8):629–634.
- Metelitsina T, Grunwald J, DuPont J, Ying G. Effect of niacin on the choroidal circulation of patients with age related macular degeneration. *Br J Ophthalmol*. 2004;88(12):1568–1572.
- Gass JD, Olson CL. Sarcoidosis with optic nerve and retinal involvement. *Archives of ophthalmology (Chicago, Ill : 1960)*. 1976;94(6):945–950.
- Eichenbaum JW, Friedman AH, Mamelok AE. A clinical and histopathological review of intermediate uveitis ("pars planitis"). *Bull N Y Acad Med*. 1988;64(2):164–174.
- Talat L, Lightman S, Tomkins-Netzer O. Ischemic retinal vasculitis and its management. *J Ophthalmol*. 2014;2014:197675.
- Hughes EH, Dick AD. The pathology and pathogenesis of retinal vasculitis. *Neuropathol Appl Neurobiol*. 2003;29(4):325–340.
- Rosenbaum DM, Rosenbaum PS, Gupta A, Michaelson MD, Hall DH, Kessler JA. Retinal ischemia leads to apoptosis which is ameliorated by aurintricarboxylic acid. *Vis Res*. 1997;37(24):3445–3451.
- Nguyen QD, Shah SM, Van Anden E, Sung JU, Vitale S, Campochiaro PA. Supplemental oxygen improves diabetic macular edema: a pilot study. *Investig Ophthalmol Vis Sci*. 2004;45(2):617–624.
- Rahimy E, Gaynon MW, Paulus YM, Alexander JL, Mansour SE. Potentially reversible effect of niacin therapy on edema from retinal vein occlusion. *JAMA Ophthalmol*. 2016;134(7):839–840.
- Gaynon MW, Paulus YM, Rahimy E, Alexander JL, Mansour SE. Effect of oral niacin on central retinal vein occlusion. *Graefes Arch Clin Exp Ophthalmol*. 2017;255(6):1085–1092.
- Abrishami MZ-GS, Mousavi MN, Banaee T, Zarei-Ghanavati M. Nicotinic acid treatment for retinal vein occlusion. *Patient Saf Qual Improv*. 2014;2(1):36–43.
- Bandello F, Lattanzio R, Zucchiatti I, Del Turco C. Pathophysiology and treatment of diabetic retinopathy. *Acta Diabetol*. 2013;50(1):1–20.
- Shin ES, Sorenson CM, Sheibani N. Diabetes and retinal vascular dysfunction. *J Ophthalmic Vis Res*. 2014;9(3):362–373.
- Dominguez E, Raoul W, Calippe B, et al. Experimental branch retinal vein occlusion induces upstream pericyte loss and vascular destabilization. *PLoS One*. 2015;10(7):e0132644.
- Karia N. Retinal vein occlusion: pathophysiology and treatment options. *Clin Ophthalmol*. 2010;4:809.
- Christoffersen NL, Larsen M. Pathophysiology and hemodynamics of branch retinal vein occlusion. *Ophthalmology*. 1999;106(11):2054–2062.
- Pieris SJ, Hill DW. Collateral vessels in branch retinal vein occlusion. *Trans Ophthalmol Soc U K*. 1982;102(Pt 1):178–181.
- Lee HE, Wang Y, Fayed AE, Fawzi AA. Exploring the relationship between collaterals and vessel density in retinal vein occlusions using optical coherence tomography angiography. *PLoS One*. 2019;14(7):e0215790-e.
- Clinical pharmacokinetics of TNF antagonists: how do they differ? In: Nestorov I, ed. *Seminars in Arthritis and Rheumatism*. Elsevier; 2005.
- Baneros-Rojas P, Berrozpe-Villabona C, Peraza-Nieves J, Díaz-Valle D. Early treatment with infliximab in bilateral occlusive vasculitis as a presenting manifestation of Behçet' disease. *Arch Soc Esp Oftalmol*. 2015;90(6):285–288.
- Verma A, Khetan V. Transient reversal of macular ischemia with intravitreal steroid implant injection in a case of radiation maculopathy. *Indian J Ophthalmol*. 2018;66(3):468.